

Retinal and other Manifestations of Incontinentia Pigmenti (Bloch-Sulzberger syndrome)

Morton F. Goldberg, MD, LCDR, Peter H. Custis, MC, USN

Background: One of the largest series of patients with incontinentia pigmenti who have undergone detailed ophthalmologic examination is reported here, including previously unrecognized findings with visually disabling consequences.

Methods: Thirteen females with incontinentia pigmenti from eight unrelated families were evaluated. The diagnosis of incontinentia pigmenti had been established previously by a referring pediatrician or dermatologist in 12 patients and by the authors in one other patient on the basis of retinal findings and history of characteristic skin manifestations.

Results: Abnormalities of the eye, central nervous system, skeleton, teeth, and hair develop in a majority of patients. The authors describe the evolution of retinal vascular abnormalities, and, for the first time, document foveal hypoplasia (in 4 of their 13 patients). The authors also provide the first report of a child with a normal brain shown on computed tomographic scan at 3 days old, which evolved to devastating cerebral ischemia, edema, and cortical blindness beginning at 6 days old.

Conclusions: Incontinentia pigmenti should be included in the differential diagnosis of patients with peripheral retinal vascular nonperfusion, preretinal neovascularization, infantile retinal detachment, or foveal hypoplasia, particularly if there is evidence of characteristic dermatologic or other systemic manifestations. In infants with incontinentia pigmenti, retinal vascular anomalies are best detected by examination under anesthesia using fluorescein angiography. *Ophthalmology* 1993;100:1645-1654

Incontinentia pigmenti is a rare X-linked disease characterized by lethality in most male embryos.¹ Females account for 97% of living patients. The first case report was described by Garrod² in 1906, and the syndrome

was later named after the contributions of Bloch³ and Sulzberger.⁴

Patients have a characteristic clinical and histopathologic dermatosis beginning at or shortly after birth. The skin disorder evolves through four stages, with the definitive diagnosis relying on stage 1 characteristic clinical and pathognomonic biopsy examinations. Stage 1 lesions develop in approximately 90% of affected patients.⁵ These lesions often are mistaken for a viral exanthem, consisting of erythematous macules, papules, and bullae randomly dispersed on the extremities and trunk without respecting lines of cleavage or nerve distribution. Biopsy results demonstrate intraepithelial vesicles filled with eosinophils. Stage 2 verrucous lesions often are overlooked before the onset of stage 3 hyperpigmented whorls and streaks, occurring between 3 and 6 months of age in 98% of affected patients.⁵ Incontinentia pigmenti is named for the histologic absence, or

Originally received: February 19, 1993.

Revision accepted: May 17, 1993.

From the Wilmer Ophthalmological Institute, The Johns Hopkins University, Baltimore.

Presented as a poster at the American Academy of Ophthalmology Annual Meeting, Dallas, November 1992.

Supported in part by an unrestricted grant from Research to Prevent Blindness, Inc, New York, New York, and core grant M.28.6057 from the National Eye Institute, Bethesda, Maryland.

LCDR Peter H. Custis is on active duty in the United States Navy. The views expressed herein do not represent official policy on the part of the Navy.

Reprint requests to Morton F. Goldberg, MD, The Wilmer Ophthalmological Institute, 600 N. Wolfe St. Baltimore, MD 21205.

incontinence, of pigment in the basal epithelium of stage 3 lesions. As stage 3 lesions fade in the childhood years, stage 4 atrophic hypopigmented patches and streaks may emerge, but may be difficult to detect in adult life. The pathogenesis of the various dermatologic findings and their relationship to systemic or ocular manifestations remain unknown.

Affected infants may be healthy, but systemic manifestations are seen in up to 80% of patients,⁵ with most becoming apparent in the first 4 months of life. The most common abnormalities are dental (65%).⁵ Disorders of the eye (35%)⁵ and central nervous system (30%)⁵ account for the complications that are most apt to preclude a normal life. Central nervous system abnormalities include cerebral ischemia, edema, and subsequent atrophy, as well as hemorrhagic necrosis and hydrocephalus. Severe mental retardation, spastic paresis, and seizures may ensue. Included in the series of patients reported herein is the first example of documented progression from a normal brain shown on computed tomographic (CT) scan at 3 days old, to profound ischemia and edema of the brain at 6 days old, with subsequent widespread atrophy and cortical blindness.

Ophthalmic manifestations may be divided into retinal and nonretinal findings. Nonretinal associations include strabismus (18%),⁵ conjunctival pigmentation,⁶ cataracts,⁵ and optic atrophy.⁷⁻¹⁰ Retinal abnormalities (Table 1) can be subdivided into those in the periphery and those in the posterior pole; the former are more frequent. In this article, we provide ophthalmic and retinal details of our 13 patients. We angiographically document extensive, spontaneous, and recurrent peripheral vascular remodeling in one patient's retinas, and, for the first time, provide evidence of foveal hypoplasia as part of this syndrome.

Subjects and Methods

The study population consisted of 13 patients from eight unrelated families. Baseline information collected for all patients was derived from a medical and genetic history, as well as systemic and ophthalmic physical examinations. The history included detailed information as to how the diagnosis was established, evolution of the skin findings, presence or absence of low birth weight, neonatal oxygen exposure, possible involvement of family members (including history of miscarriages), developmental delay/retardation, paresis, dental abnormalities, and a review of previous medical consultations and procedures. Physical examination included thorough inspection of the skin, hair, nails, teeth and palate, skeletal structures, and a neurologic survey. Examination of the eyes emphasized external inspection, determination of visual acuity or function, and ophthalmoscopic inspection of the optic nerves, maculae, and entire retinal vasculatures through dilated pupils. Of the six children 3 years of age or younger (Table 2), five had at least one examination under general anesthesia with scleral depression. The parents of one child (case 11) declined to have anesthesia performed. Fluoro-

Table 1. Previously Reported and Newly Defined Retinal Abnormalities

Peripheral Abnormalities	Posterior Pole Abnormalities
Peripheral avascular zone	Foveal hypoplasia*
Tortuous, irregular vessels with arborizing arteriovenous anastomoses at the junction of vascular and avascular retina	Paramacular vascular dilations and aneurysms
Aneurysmal-like dilation and neovascular changes	Neovascularization
Exudates	Vitreous hemorrhage
Vitreous hemorrhage	Preretinal fibrosis
Preretinal fibrovascular proliferation	Retinal detachment
Retinal detachment	RPE mottling/granularity
RPE mottling/granularity	RPE hypopigmentation/coloboma
RPE hypopigmentation/coloboma	

RPE = retinal pigment epithelium.
* Newly defined in this series.

rescein angiography was obtained on seven patients (cases 1, 2, 5, 6, 7, 8, and 12). Confirmational skin biopsies on stage 1 lesions had been performed on five patients (cases 6, 8, 9, 11, and 13). In addition to our examinations, four patients (cases 1, 2, 3, and 4) had cytogenetic studies which demonstrated the selective elimination of cells expressing incontinentia pigmenti mutations from fibroblast cultures.¹¹

Three patients were examined more than once: case 6 has had six examinations under general anesthesia between 7 and 28 months of age; case 8 was first seen at 3 months of age and underwent an examination under general anesthesia at 10 months of age; and case 12 had an examination under general anesthesia at 6 and 10 months of age. All patients are white with the exception of case 10, who is black.

Results

Table 2 summarizes the findings from our case series. Patients' ages at the time of our first examination ranged from 6 weeks to 53 years. None of the patients were born prematurely, nor did they have a low birth weight. Only one patient had neonatal oxygen exposure, which was very limited (see case 13 report below). While only five patients had skin biopsies of stage 1 vesicular lesions (all of which were confirmatory for the diagnosis), every patient had a strong history and/or clinical findings consistent with one or more of the dermatologic stages. Biopsies were not performed in the remainder of our patients, be-

Table 2. Summary of Clinical Findings in Incontinentia Pigmenti*

Patient No.	1	2	3	4	5	6	7	8	9	10	11	12	13	Total
Age at time of examination (yrs)	53	28	21	33	25	0.2-2	25	0.2-.8	0.1	16	3	0.5-.8	1	
Family history	+	+	+	+	+	+	+	+	-	-	-	-	-	8/13
Skin biopsy	NP	NP	NP	NP	NP	+	NP	+	+	NP	+	NP	+	5/13
CNS	-	-	-	+	-	-	-	-	-	+	+	-	+	4/13
Alopecia	+	+	+	+	-	-	-	-	-	+	+	-	-	6/13
Best-corrected visual acuity														
OD	20/20	20/20	20/20	NLP	20/25	F	20/20	FF	F	20/20	FF	NLP	NLP	
OS	20/20	20/20	20/20	FF	20/25	20/FF	20/20	FF	F	20/20	FF	FF	NLP	
Strabismus, nystagmus	-	-	-	-	-	S	-	-	-	-	-	S	S + N	3/13
Optic nerve atrophy	-	-	-	+OD	-	-	-	-	-	-	-	-	+OU	2/13
Foveal hypoplasia	-	-	-	+OD	-	+OU	-	+OU	-	-	-	+OS	-	4/13
RPE abnormality	+OS	+OU	-	+OD	+OU	-	+OD	+OU	-	+OD	-	-	-	7/13
Retinal vascular nonperfusion	-	-	-	+OU	-	+OU	-	+OU	-	-	-	+OU	-	4/13
Retinal detachment	-	-	-	+OD	-	-	-	-	-	-	-	+OD	-	2/13

* - = normal or absent; + = abnormal and compatible with incontinentia pigmenti.

NP = not performed; CNS = central nervous system; OD = right eye; NLP = no light perception; F = fixates; FF = fix and follow; OS = left eye; S = strabismus; N = nystagmus; OU = both eyes; RPE = retinal pigment epithelium.

cause the characteristic stage 1 lesions had resolved before the diagnosis of incontinentia pigmenti was considered. However, there was no doubt regarding the accuracy of the diagnosis when factors such as family history and systemic findings were considered in conjunction with the dermatologic abnormalities.

One or more nonocular manifestations were detected in 12 (92%) of our patients. Dental findings were the most common, affecting six of seven patients who were old enough to permit evaluations. These included partial anodontia (cases 1, 2, 4, 5, and 7) and malformations of incisors and canines (cases 1, 2, 4, 5, 7, and 10) such as pegged, coned, or widely spaced teeth. Alopecia was present in its typical vertex location in six (47%) patients (cases 1, 2, 3, 4, 10, and 11).

Central nervous system abnormalities were present in four (31%) patients, with seizure activity in three (cases 4, 11, and 13), developmental delay in four (cases 4, 10, 11, and 13), and asymmetric generalized paresis in three (cases 4, 11, and 13). Case 4, 33 years of age, never had had sufficient cognitive ability to attend school and was almost completely bedridden. Neuro-radiologic studies had been performed in cases 11 and 13 (see case report below). Patient 11 underwent sequential magnetic resonance imaging and CT scanning beginning at 3 days old as a result of acute encephalopathy.¹² A progressive destructive process of hemorrhagic necrosis and brain edema was observed. A needle biopsy of the right frontal lobe during the acute encephalopathy

showed only a few eosinophils and macrophages without infectious, inflammatory, or vascular abnormalities. A stain for iron was negative.

Intraocular findings were noted in nine (69%) patients. Visual acuity or function was generally very good, except in some eyes with ophthalmoscopic evidence of foveal hypoplasia and/or optic nerve atrophy (cases 4, 6, 12, and 13). Foveal hypoplasia, characterized by an absent foveolar pit, abnormal pigmentation, and/or abnormal perifoveal vascularization, was documented by color photographs and fluorescein angiography in three patients (cases 6, 8, and 12) as well as by clinical examination. In one other patient (case 4), foveal hypoplasia was detected by clinical examination alone. Foveal hypoplasia was unilateral in two patients (cases 4 and 12) and bilateral in two others (cases 6 and 8).

Prominent optic nerve atrophy was noted in two patients (cases 4 and 13), both of whom had extensive central nervous system complications, including mental retardation, seizures, and spastic paresis. In one of them (case 4), the optic nerve atrophy was unilateral and was associated with ipsilateral foveal hypoplasia, generalized retinal arterial narrowing, peripheral retinal nonperfusion, and peripheral retinal pigment epithelium mottling, suggestive of a spontaneously resolved localized retinal detachment in the temporal periphery. The other patient (case 13) had bilateral optic nerve atrophy without foveal, vascular, or peripheral retinal changes, but was affected by widespread

cerebral ischemia and edema, documented by neuroangiologic techniques.

Bilateral retinal vascular abnormalities were found in four patients (31%). In three of these patients (cases 4, 6, and 8), there was bilateral peripheral nonperfusion, but no associated retinal detachment. Unilateral temporal tractional retinal detachment with a posterior fold through the macula was present in only one patient (case 12). Surgery was considered, but not strongly recommended because of the relatively favorable appearance of the retina in the fellow eye. Over 4 months, the eye with the partial detachment evolved to a total retinal detachment, having a closed funnel configuration. The fellow eye has peripheral retinal nonperfusion and foveal hypoplasia, but no evidence of retinal detachment. The vascular abnormalities of all four patients often were subtle and sometimes invisible by ophthalmoscopy, and were much more readily detected by both fluorescein angiography and angiography. The temporal retina was more commonly involved than nasal, and asymmetric involvement between eyes was common. Evolving peripheral vascular changes, with evidence of simultaneous involution and progression in different parts of the same fundus were observed in one patient in whom repetitive angiographic follow-up was possible (case 6; see case report). None of our patients received laser photocoagulation or cryotherapy.

Abnormalities of the retinal pigment epithelium were present in seven patients; bilateral in three (cases 2, 5, and 8), and unilateral in 4 (cases 1, 4, 7, and 10). They varied from diffuse fine mottling (Fig 1, top left) (cases 5, 8, and 10) to localized areas of prominent hyperpigmentation and/or hypopigmentation ranging in size from approximately 200 to 3000 μm (Fig 1, top right and center) (cases 1, 2, 4, and 7). There was no clear correlation between any of these changes and the presence of foveal hypoplasia, retinal vascular abnormalities, or optic nerve atrophy.

Esotropia was observed in two patients. One had foveal hypoplasia of the esotropic eye (case 6) and the other had esotropia associated with ipsilateral retinal detachment (case 12). Another patient had nystagmus and exotropia associated with bilateral optic nerve atrophy (case 13). Interestingly, strabismus has not developed in one patient with bilateral foveal hypoplasia (case 8) as of her most recent follow-up at 10 months of age.

Selected Case Reports

Case 6. A 10-week-old girl was referred by the Departments of Pediatrics and Dermatology with the diagnosis of incontinentia pigmenti having been made 1 day before our initial examination. This baby was the product of a full-term uncomplicated vaginal delivery, weighed 6 lb 10 oz, had no neonatal oxygen exposure, and was healthy except for numerous erythematous macules and vesicles on her extremities and trunk. Her family history was remarkable for newly recognized stage 4 skin lesions in the mother (case 5). The mother has had two other pregnancies: one spontaneous abortion (allegedly a male) and a daughter who has had no signs of in-

continentia pigmenti. Case 6's dermatologic manifestations were noted a few days after birth. Other than one self-limited febrile seizure at 19 months of age, the patient has developed normally, with the exception of her eyes. At 6 months of age, peripheral vascular arteriovenous anastomoses were first detected. Her examinations under general anesthesia were performed with fluorescein angiography at 7, 10, 12, 18, and 28 months of age. Foveal hypoplasia in the right eye was first recognized during her first examination under general anesthesia at 7 months of age (Fig 2). The onset of 30- to 40-prism diopter right esotropia was noted at 12 months. The esotropia has not responded to corrective lenses (+4.50 sphere in the right eye, +3.00 sphere in the left eye) and attempts at occlusive therapy in the left eye. Sequential examinations under general anesthesia have been performed to monitor the patient's distinctive and potentially disabling peripheral retinal vascular anomalies. On the initial examination under general anesthesia, there was widespread peripheral nonperfusion and anastomoses. Tortuous irregular vessels arborized at the junction between perfused and nonperfused retina. At 10 (Fig 3, top) and 12 months of age (Fig 3, second row), there was evidence of vascular remodeling, characterized by areas of new vessel formation that were incompetent to fluorescein, while at the same time there were adjacent areas in which spontaneous involution of abnormal vessels was apparent. By 18 months of age (Fig 3, third row), we noted a significant reduction in the late fluorescein leakage, but even at 28 months of age (Fig 3, bottom) the remodeling apparently has not fully ceased. The evolution of these vascular changes would have been virtually impossible to witness had it not been for the aid of sequential fluorescein angiography.

Case 13. A 10-month-old girl with a diagnosis of incontinentia pigmenti within the first few weeks of life was referred for examination. There is no family history of incontinentia pigmenti, and two older sisters are healthy. This baby was the product of a full-term vaginal delivery, but the pregnancy was notable for significant first-term bleeding in which the spontaneous abortion of another fetus could not be ruled out. Birth weight was 9 lb 3 oz. A vesicular rash was present on the extremities and the trunk at 1 to 2 days old, and skin biopsy within the first week confirmed the diagnosis of incontinentia pigmenti. On day 3, tonic/clonic seizure activity developed with apnea, cyanosis, and oxygen desaturation. A CT of the brain on this day showed normal findings (Fig 4, top left). She was intubated on room air through day 7, but never received additional ventilation or oxygen exposure thereafter. Phenobarbital and phenytoin (Dilantin) were required to control her focal seizures. A repeat CT scan at 6 days old (Fig 4, top right) demonstrated diffuse cerebral edema with bilateral ischemic changes most prominent in the parietal and occipital lobes. At 2 months of age (Fig 4, bottom), CT studies demonstrated prominent atrophy and calcific changes of both hemispheres, left more than right. Seizure activity continues intermittently, and there is marked physical and cognitive developmental delay.

Visually, the child has been functionally blind since shortly after birth. The first ophthalmologic consultation at 3 months of age showed bilateral optic nerve atrophy and slow pendular horizontal nystagmus. By 8 months of age, variable 20- to 30-prism diopter exotropia was apparent. A diagnosis of cortical blindness was based, in part, on a visual-evoked potential test which showed no repeatable waveforms. On our examination, there was no pupillary or behavioral response to light in either eye, suggesting widespread abnormalities in the central nervous system. Both optic nerves were pale. There were no abnormalities of the fovea, retinal vasculature, or retinal pigment epithelium.

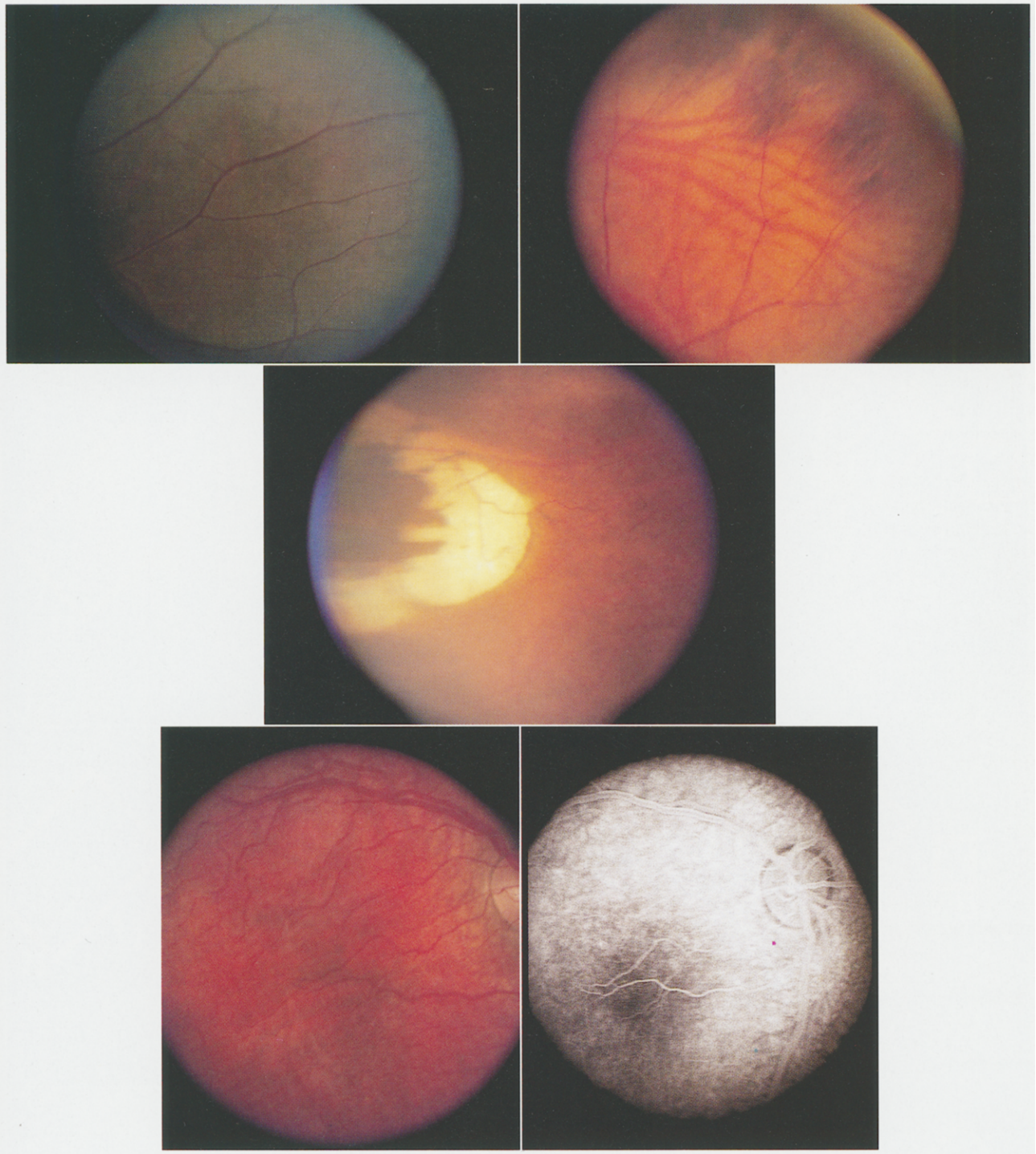


Figure 1. **Top left**, diffuse fine mottling of the retinal pigment epithelium in a 16-year-old black girl (case 10). **Top right**, peripheral retinal pigment epithelial mottled hyperpigmentation in a 25-year-old white woman (case 5). **Center**, large peripheral localized "coloboma," or hypopigmented lesion, in a 25-year-old woman (case 7) in the horizontal meridian.

Figure 2. **Bottom left**, the right eye of a patient (case 6) with foveal hypoplasia, characterized by abnormal pigmentation, an absent foveal light reflex, and abnormal central blood vessels. **Bottom right**, fluorescein angiogram of the macular region of the same patient demonstrates an anomalous retinal vascular pattern surrounding and possibly in the fovea.

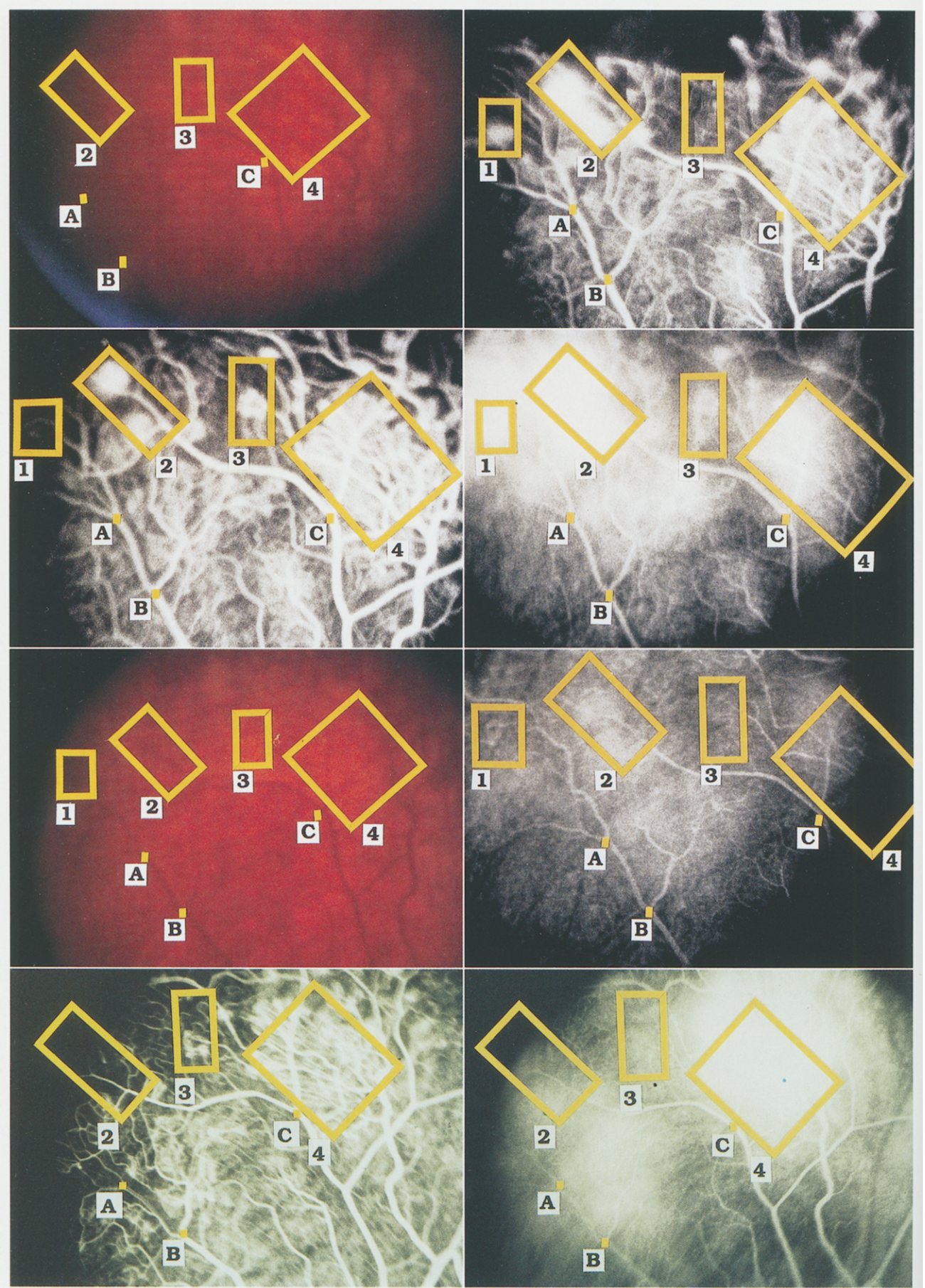


Figure 3. Vascular remodeling in the temporal periphery of the right eye between 10 and 28 months of age (case 6). Points A, B, and C are corresponding anatomic landmarks. Boxes 1 to 4 are corresponding areas of vascular remodeling. Boxes 1 and 2 demonstrate relative involution of leakage between 10 and 12 months of age. Box 3 shows new vessel growth evolving between 10 and 12 months of age. Box 4 illustrates persistent new vessel activity between 10 and 12 months of age. By 18 months of age, all four boxes have marked spontaneous involution of fluorescein incompetence. However, even at 28 months of age there is still fluorescein leakage. Notice the difficulty in identifying vascular anomalies with plain ophthalmoscopy. **Top**, peripheral fundus at 10 months of age and corresponding fluorescein angiography (27.8 seconds). **Second row**, fluorescein angiography (55 and 206 seconds) of the same area at 12 months. Notice that some areas of apparent new vessels are progressing, whereas adjacent areas are regressing. **Third row**, same area of the fundus at age 18 months with color photograph and fluorescein angiography (377 seconds). Note the overall reduction in fluorescein leakage. **Bottom**, fluorescein angiography of the same area at 28 months of age (24 and 315 seconds). Notice the continued and more prominent fluorescein leakage compared with that at 18 months of age.

Discussion

Peripheral retinal vascular anomalies in incontinentia pigmenti have been noted before, but the extent, type, and duration of remodeling have not been emphasized previously. The peripheral remodeling and subsequent events are somewhat reminiscent of the retinal vascular evolutions in retinopathy of prematurity, familial exudative vitreoretinopathy, Eales' disease, and sickle cell retinopathy, despite marked differences in etiology and pathogenesis. Exudation, hemorrhage, preretinal gliosis, and tractional retinal detachment in up to 10% of patients with incontinentia pigmenti^{13,14} may follow the initial remodeling phase. The entire evolution may occur slowly over the course of years,¹⁴⁻¹⁷ or quickly within the first few months of life. Spontaneous involution has been reported previously.⁹ Fluorescein angiography is extremely valuable in detecting and monitoring changes in the retinal vasculature, because many of the known changes described in case 6 were invisible to us with ordinary ophthalmoscopy, despite our awareness of angiographic abnormalities.

Although a predilection for a peripheral retinal location for vascular changes in incontinentia pigmenti is well established, the posterior pole can be affected by similar findings.^{14,16,18,19} Moreover, to the best of our knowledge, we have been able to demonstrate for the first time angiographic and ophthalmoscopic evidence for abnormal foveal development. If this structural abnormality proves to be a regular feature of incontinentia pigmenti, it could well provide a basis for understanding the poor vision and associated strabismus seen in some patients, such as cases 6 and 12. It is interesting that strabismus or nystagmus have not developed in two patients with foveal hypoplasia (cases 4 and 8). Currently, we can offer no explanation for the foveal hypoplasia, but the retina, as part of the central nervous system, may be participating in an abnormal developmental or destructive process similar to events occurring in the brain. Whether the retinal vascular abnormalities are primary or secondary to changes in the retinal tissue is open to speculation. It would be valuable to know if similar vascular events are occurring elsewhere in the central nervous system.

As in our series, reported retinal pigment epithelial abnormalities can vary from diffuse mottling^{6,8,9} to localized

areas of hypopigmentation.^{20,21} We are unable to correlate the retinal pigment epithelial changes in our patients with observed retinal vascular abnormalities. Histologic studies of the retinal pigment epithelium in other reports²² have shown retinal pigment epithelial hyperplasia and nodular accumulations of macrophages which contain melanin and lipofuscin.

The relationship of optic nerve atrophy to the retinal pigment epithelium and retinal changes also is uncertain. Optic atrophy is known to occur in approximately 5% of patients with incontinentia pigmenti.⁷⁻¹⁰ Our observation in case 13 of bilateral optic atrophy without any retinal vascular abnormalities suggests that the nerve damage in some patients may be primary or similar to intracranial pathologic events, rather than secondary to retinal atrophy.

Although the genetics of incontinentia pigmenti are becoming reasonably well established,²³⁻³⁰ the pathogenesis of its cutaneous and retinal abnormalities are far from understood. It has been suggested³¹ that the manifestations of incontinentia pigmenti are the result of an abnormal DNA sequence on the X chromosome which impairs production of an enzyme or other protein needed for cell differentiation. The lack of the enzyme or protein would result in death for the hemizygous male embryo. Males with Klinefelter's syndrome (47, XXY), having one normal X chromosome, would be expected to be viable. This has been documented in 5 of the 29 known cases of males with incontinentia pigmenti.^{14,32-35} The majority of the other male cases did not have karyotype analysis, so the incidence of 47, XXY may be higher. Heterozygous females may be variably mosaic, accounting for differences in clinical manifestations.

Michael et al (unpublished data; presented at the 1992 ARVO annual meeting) recently determined that newborn mammalian retinas are relatively deficient in anti-oxidant enzymes, perhaps leading to a local increase in retinal oxygen concentration. If a threshold for deficiency of such an enzyme were exceeded, this might cause oxygen-induced vaso-occlusion in the immature peripheral retina, analogous to that occurring in retinopathy of prematurity. Vaso-occlusion, in turn, might initiate the vascular remodeling so characteristic of many vaso-occlusive and proliferative retinopathies. If patients with incontinentia pigmenti had an inherited deficiency or abnormality in an enzymatic oxygen detoxication system,

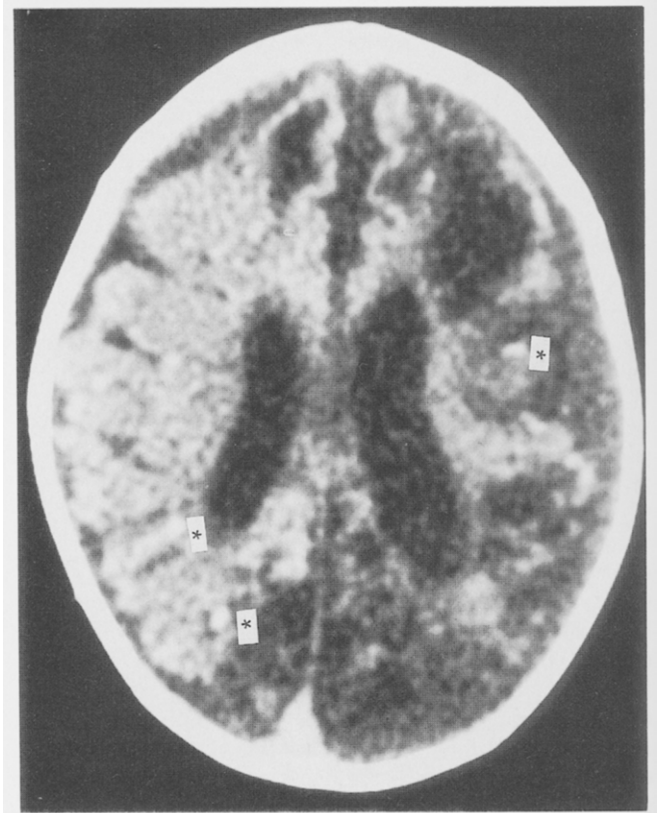
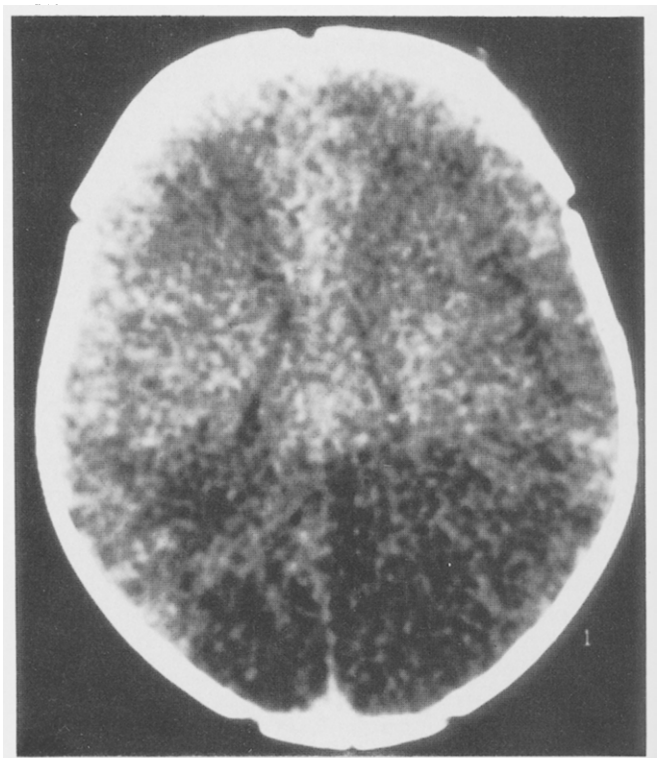
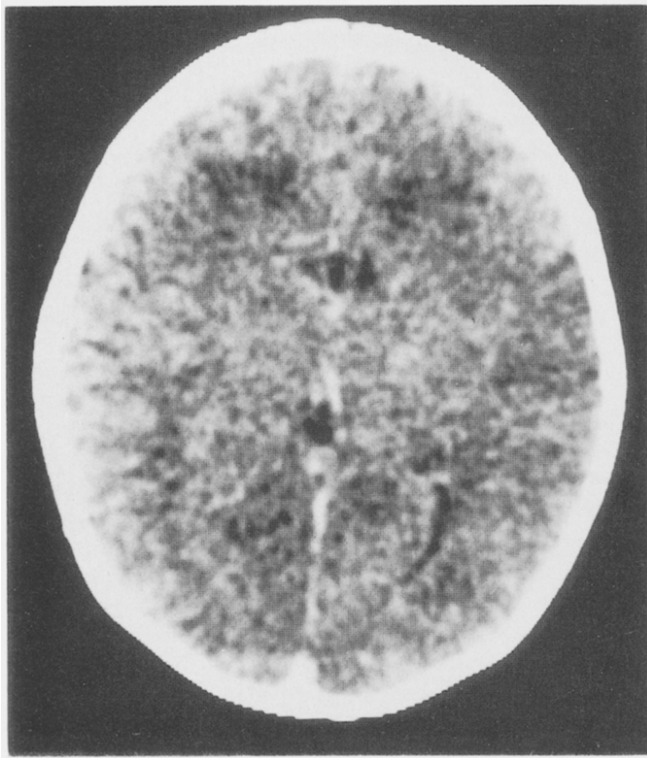


Figure 4. **Top left**, cranial computed tomographic scan at 3 days old demonstrates normal differentiation of gray-white matter for the patient's age (case 13). **Top right**, cranial computed tomographic scan in the same patient at 6 days old, with loss of normal gray-white differentiation, diffuse edema, and possible ischemia of the occipital, parietal, and temporal lobes. **Bottom**, cranial computed tomographic scan of the same patient at 2 months of age demonstrates widespread atrophy and early dystrophic calcification (asterisk) of both cerebral hemispheres.

the result could be a deleterious effect characterized by oxygen-induced or sustained vaso-occlusive events (and subsequent vascular remodeling) in the retina. Currently, no direct evidence supports these or other pathogenic speculations.

With respect to possible treatment of the peripheral avascular retina, photocoagulation^{7,9} and cryotherapy¹⁵ have been used in a few patients. None of our patients have received treatment for peripheral vascular changes. It is difficult to establish prophylactic or therapeutic guidelines, because the relatively small number of cases has precluded careful study of the natural history. In advanced cases of total retinal detachment, vitrectomy recently has been performed with some success.³⁶

The retinopathy of incontinentia pigmenti covers a broad continuum of severity. Groups of reported cases, such as our own, are subject to bias of ascertainment. Most of our cases were initially identified because of their cutaneous, rather than their ophthalmic, manifestations. Thus, the severity of the ocular findings in our patients is substantially less than that of other case series that were ascertained because of visual disturbances. With continued follow-up, more significant ocular abnormalities might develop in some of the younger patients in our series. Indeed, the eyes reported by Wald et al³⁶ were complicated by retinal detachment and were purposely referred to those authors for surgical therapy of advanced retinal disease. Those retinas represent the most severe manifestations of incontinentia pigmenti and are similar to one eye of our case 12. Quantification of the relative incidence of various retinal manifestations of incontinentia pigmenti will require study of a substantially larger number of cases.

Acknowledgment. The authors thank David Valle, MD, for referral of several of the patients reported in this article. Case 12 is reported through the courtesy of Michael Repka, MD, Wilmer Eye Institute, Baltimore.

References

1. Lenz W. Zur Genetik der Incontinentia pigmenti. *Ann Paediatr* 1961;196:149-65.
2. Garrod AE. Peculiar pigmentation of the skin of an infant. *Tr Clin Soc Lond* 1906;39:216.
3. Bloch B. Eigentümliche, bisher nicht beschriebene Pigmentaffektion (Incontinentia pigmenti). *Schweiz Med Wochenschr* 1926;7:404-5.
4. Sulzberger MB. Über eine bisher nicht beschriebene congenitale Pigmentanomalie (Incontinentia pigmenti). *Arch Dermatol Syph (Berlin)* 1928;154:19-32.
5. Carney RG. Incontinentia pigmenti. A world statistical analysis. *Arch Dermatol* 1976;112:535-42.
6. McCrary JA III, Smith JL. Conjunctival and retinal incontinentia pigmenti. *Arch Ophthalmol* 1968;79:417-22.
7. Watzke RC, Stevens TS, Carney RG Jr. Retinal vascular changes of incontinentia pigmenti. *Arch Ophthalmol* 1976;94:743-6.
8. François J. Incontinentia pigmenti (Bloch-Sulzberger syndrome) and retinal changes. *Br J Ophthalmol* 1984;68:19-25.
9. Nishimura M, Oka Y, Takagi I, et al. The clinical features and treatment of the retinopathy of Bloch-Sulzberger syndrome (incontinentia pigmenti). *Jpn J Ophthalmol* 1980;24:310-19.
10. Catalano RA, Lopatynzsky M, Tasman WS. Treatment of proliferative retinopathy associated with incontinentia pigmenti [letter]. *Am J Ophthalmol* 1990;110:701-2.
11. Migeon BR, Axelman J, de Beur SJ, et al. Selection against lethal alleles in females heterozygous for incontinentia pigmenti. *Am J Hum Genet* 1989;44:100-6.
12. Shuper A, Bryan RN, Singer HS. Destructive encephalopathy in incontinentia pigmenti: a primary disorder? *Pediatr Neurol* 1990;6:137-40.
13. Carney RG, Carney RG Jr. Incontinentia pigmenti. *Arch Dermatol* 1970;102:157-62.
14. Fowell SM, Greenwald MJ, Prendiville JS, Jampol LM. Ocular findings of incontinentia pigmenti in a male infant with Klinefelter syndrome. *J Pediatr Ophthalmol Strabismus* 1992;29:180-4.
15. Nix RR, Apple DJ. Proliferative retinopathy associated with incontinentia pigmenti. *Retina* 1981;1:156-61.
16. Jain RB, Willets GS. Fundus changes in incontinentia pigmenti (Bloch-Sulzberger syndrome): a case report. *Br J Ophthalmol* 1978;62:622-6.
17. Rahi J, Hungerford J. Early diagnosis of the retinopathy of incontinentia pigmenti: successful treatment by cryotherapy. *Br J Ophthalmol* 1990;74:377-9.
18. Brown CA. Incontinentia pigmenti: the development of pseudoglioma. *Br J Ophthalmol* 1988;72:452-5.
19. Lieb WA, Guerry D III. Fundus changes in incontinentia pigmenti. *Am J Ophthalmol* 1958;45:265-71.
20. Yell JA, Walshe M, Desai SN. Incontinentia pigmenti associated with bilateral cleft lip and palate. *Clin Exp Dermatol* 1991;16:49-50.
21. Rosenfeld SI, Smith ME. Ocular findings in incontinentia pigmenti. *Ophthalmology* 1985;92:543-6.
22. Mensheha-Manhart O, Rodrigues MM, Shields JA, et al. Retinal pigment epithelium in incontinentia pigmenti. *Am J Ophthalmol* 1975;79:571-7.
23. Hodgson SV, Neville B, Jones RWA, et al. Two cases of X/autosome translocation in females with incontinentia pigmenti. *Hum Genet* 1985;71:231-4.
24. de Grouchy J, Turleau C, Doussau de Bazignan M, et al. Incontinentia pigmenti (IP) and r(x). Tentative mapping of the IP locus to the X juxtacentromeric region. *Ann Genet* 1985;28:86-9.
25. Cannizzaro LA, Hecht F. Gene for incontinentia pigmenti maps to band Xp11 with an (X:10)(p11;q22) translocation. *Clin Genet* 1987;32:66-9.
26. Crolla JA, Gilgenkrantz S, de Grouchy J, et al. Incontinentia pigmenti and X-autosome translocations. Non-isotopic in situ hybridization with an X-centromere-specific probe (pSV2X5) reveals a possible X-centromeric breakpoint in one of five published cases. *Hum Genet* 1989;81:269-72.
27. Gorski JL, Burright EN, Harnden CE, et al. Localization of DNA sequences to a region within Xp11.21 between incontinentia pigmenti (IP1) X-chromosomal translocation breakpoints. *Am J Hum Genet* 1991;48:53-64.
28. Sefiani A, Abel L, Heuertz S, et al. The gene for incontinentia pigmenti is assigned to Xq28. *Genomics* 1989;4:427-9.
29. Sefiani A, M'rad R, Simard L, et al. Linkage relationship between incontinentia pigmenti (IP2) and nine

- terminal X long arm markers. *Hum Genet* 1991; 86:297-9.
30. Gorski JL, Stein CK, Glover TW. A somatic cell hybrid panel to facilitate identification of DNA sequences in the vicinity of the incontinentia pigmenti locus (IP1). *Cytogenet Cell Genet* 1989;52:90-2.
 31. Catalano RA. Incontinentia pigmenti. *Am J Ophthalmol* 1990;110:696-700.
 32. Omerod AD, White MI, McKay E, Johnston AW. Incontinentia pigmenti in a boy with Klinefelter's syndrome. *J Med Genet* 1987;24:439-41.
 33. Prendiville JS, Gorski JL, Stein CK, Esterly NB. Incontinentia pigmenti in a male infant with Klinefelter syndrome. *J Am Acad Dermatol* 1989;20:937-40.
 34. Garcia-Dorado J, de Unamuno P, Fernandez-Lopez E, et al. Incontinentia pigmenti: XXY male with a family history. *Clin Genet* 1990;38:128-38.
 35. Kunze J, Frenzel UH, Huttig E, et al. Klinefelter's syndrome and incontinentia pigmenti Bloch-Sulzberger. *Hum Genet* 1977;35:237-40.
 36. Wald KJ, Mehta MC, Katsumi O, et al. Retinal detachments in incontinentia pigmenti. *Arch Ophthalmol* 1993;111: 614-7.