

# Hemiplegia Due to Posterior Cerebral Artery Occlusion

Kathryn North, FRACP; Alex Kan, FRCPA; Merl de Silva, FRACR;  
Robert Ouvrier, MD, FRACP

**Background:** Hemiplegia is a rare manifestation of posterior cerebral artery occlusion. The acute clinical picture may be difficult to differentiate from occlusion of the middle cerebral artery. A mechanism for the hemiplegia has not been conclusively determined.

**Case Description:** We describe a patient with hemiplegia secondary to posterior cerebral artery occlusion by an embolized fragment of a prosthetic valve. Computed tomographic scan showed the foreign body just distal to the origin of the posterior cerebral artery with infarction of its vascular territory. These findings were later confirmed at autopsy. There was no radiological or autopsy evidence of involvement of the other cerebral arteries or their territories.

**Conclusions:** The patient provides further evidence that occlusion of the posterior cerebral artery just distal to its junction with the posterior communicating artery may produce contralateral hemiplegia without oculomotor nerve nucleus involvement. (*Stroke*. 1993;24:1757-1760.)

**KEY WORDS** • hemiplegia • posterior cerebral artery • stroke

Occlusion of the posterior cerebral artery is usually characterized by homonymous visual field defects, hemisensory loss, and neuropsychological deficits without associated weakness. There are few recorded cases of hemiplegia in posterior cerebral artery occlusion,<sup>1-3</sup> and even fewer are verified by imaging or autopsy.

We describe a patient with posterior cerebral artery occlusion due to an embolized fragment of a prosthetic heart valve. The patient presented with severe hemiplegia and aphasia, and in the acute period the deficit could not be distinguished clinically from a middle cerebral artery occlusion. Localization of the lesion on computed tomographic (CT) scan was confirmed by autopsy findings, and indirect evidence for the mechanism of hemiplegia in posterior cerebral artery occlusion is thus provided.

## Case Report

The patient was a right-handed Tongan boy who was well until 9 years of age (January 1986), when he developed rheumatic fever treated with penicillin. After recovery from the acute illness, he presented again in June 1986 with congestive cardiac failure and was treated with digoxin and furosemide. He was found at echocardiography to have a dilated left ventricle and decreased left ventricular function with aortic incompetence and mitral incompetence. In August of that year, he had a

double prosthetic valve replacement and was anticoagulated. The postoperative course was uncomplicated.

In September 1991 (age 15), he again presented with acute onset of pulmonary edema and cardiomegaly. An echocardiogram showed mitral stenosis and mitral incompetence. At operation, the posterior leaflet of the prosthetic mitral valve was found to be disconnected, and there was significant mitral valve regurgitation. The aortic valve functioned well, and there were no clots or vegetations. The mitral valve was replaced.

The surgical procedure was uncomplicated, and the patient had a good hemodynamic recovery postoperatively. He was weaned from muscle relaxants and sedation and was extubated within 48 hours. After extubation, a severe right hemiplegia and hemianesthesia were noted.

At this time the patient was drowsy but responsive and hemodynamically stable. His head and eyes were deviated to the left, and he had a severe right hemiplegia, including the face. There was decreased pain sensation on the right and a severe right homonymous hemianopia; his right plantar response was upgoing. He responded to simple commands but did not speak. His prothrombin index was 65%, and he had a normal platelet count. The CT scan (Fig 1) taken 3 days postoperatively showed an acute nonhemorrhagic infarct involving the left posterior temporal and occipital lobes. A foreign body was visible in the left posterior cerebral artery.

During the next 48 hours, there was rapid improvement in the right-sided weakness; the head and eye deviation resolved. He became alert, responsive, and cooperative, and simple speech returned. Within 1 week he was walking with slight residual right-sided weakness. There was a severe right homonymous hemianopia and diminished pain sensation on the right with right-

Received December 18, 1992; final revision received May 25, 1993; accepted June 9, 1993.

From the Departments of Neurology (K.N., R.O.), Pathology (A.K.), and Radiology (M. de S.), Children's Hospital, Camperdown, Sydney, Australia.

Reprint requests to Dr K. North, Genetics Division, Enders 5, Children's Hospital, 300 Longwood Ave, Boston, MA 02115.

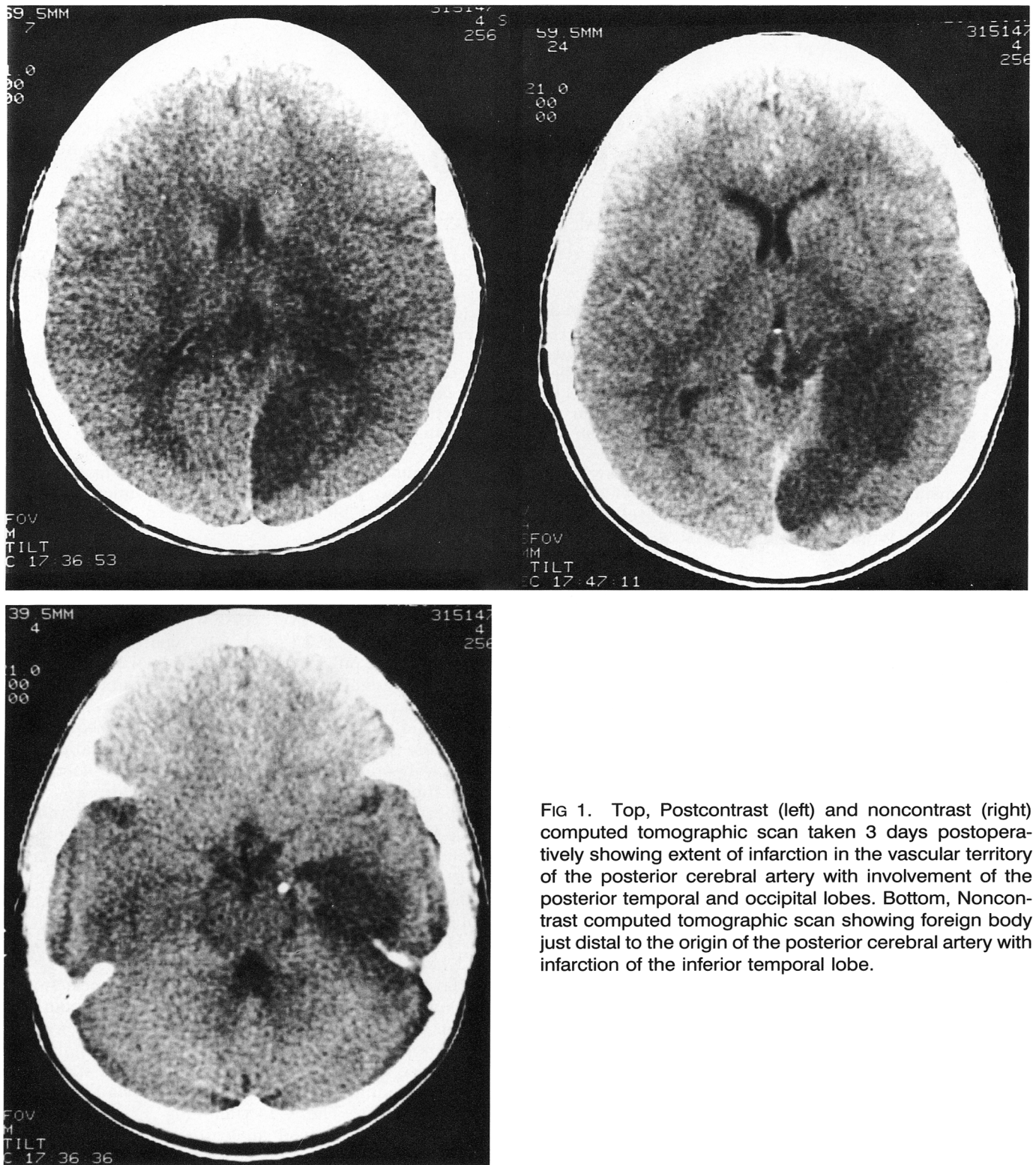


FIG 1. Top, Postcontrast (left) and noncontrast (right) computed tomographic scan taken 3 days postoperatively showing extent of infarction in the vascular territory of the posterior cerebral artery with involvement of the posterior temporal and occipital lobes. Bottom, Noncontrast computed tomographic scan showing foreign body just distal to the origin of the posterior cerebral artery with infarction of the inferior temporal lobe.

sided neglect. On clinical and detailed neuropsychological assessment, he demonstrated decreased voice volume, severe verbal specific memory disturbance with relatively normal memory for nonverbal material, decreased comprehension of complex verbal material, and significant anomia with diminished verbal fluency. Repetition and automatic speech were intact, and he had no agnosia, constructional problems, or right-left disorien-

tation. Reading, spelling, and comprehension skills were impaired, and he had difficulty writing, out of proportion to his residual weakness. Concentration and mathematical abilities were normal. His affect was muted; he demonstrated no frustration with his reduced abilities.

By 6 weeks after infarction, the patient had excellent recovery of strength with minimal distal weakness and a



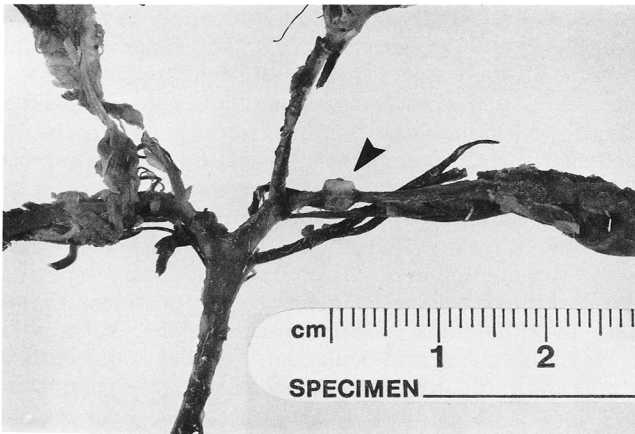


FIG 2. Photograph of autopsy specimen of circle of Willis showing foreign body within the posterior cerebral artery distal to its origin (arrow).

severe residual hemianopia. His verbal memory, naming skills, and reading ability were slowly improving. Ten months later he continued to have residual right-sided weakness, a severe right hemianopia, and significant problems with reading, writing, word finding, and memory for complex verbal instructions.

The patient was readmitted in August 1992 with intermittent high fever. CT scan demonstrated the embolized fragment of valve at the same position within the posterior cerebral artery. No vegetation was visible on echocardiography, but blood cultures were positive for *Corynebacterium diphtheroides*, and antibiotics were started. He deteriorated suddenly 1 week after admission with decerebrate posturing and fixed pupils. Repeat CT scan showed a large intracerebral bleed in the area of the previous infarction. He died 2 days later.

At autopsy a fragment of valve with associated fibrosis was present in the posterior cerebral artery distal to its origin and distal to the midline branches to the oculo-

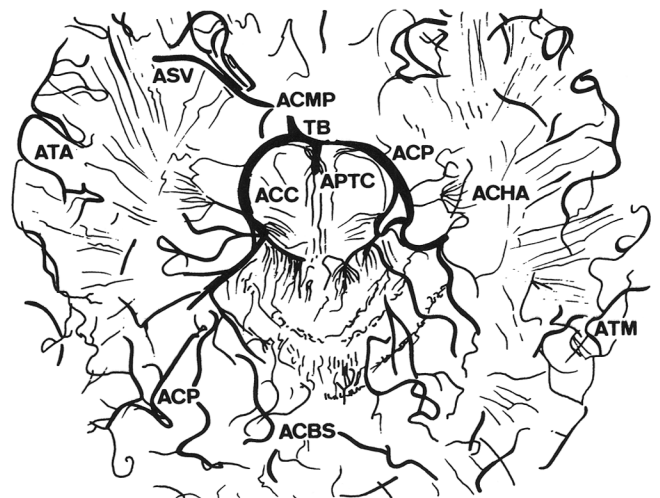
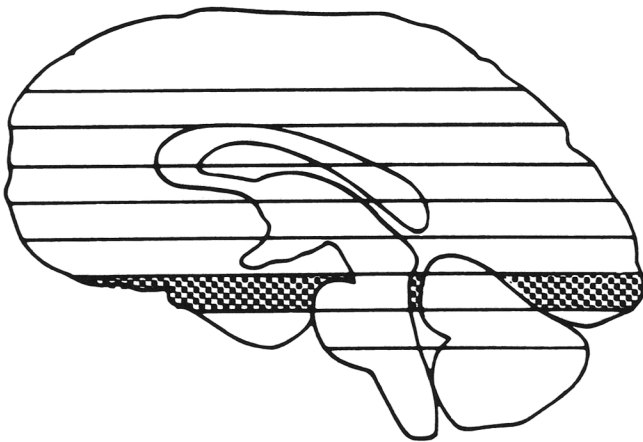
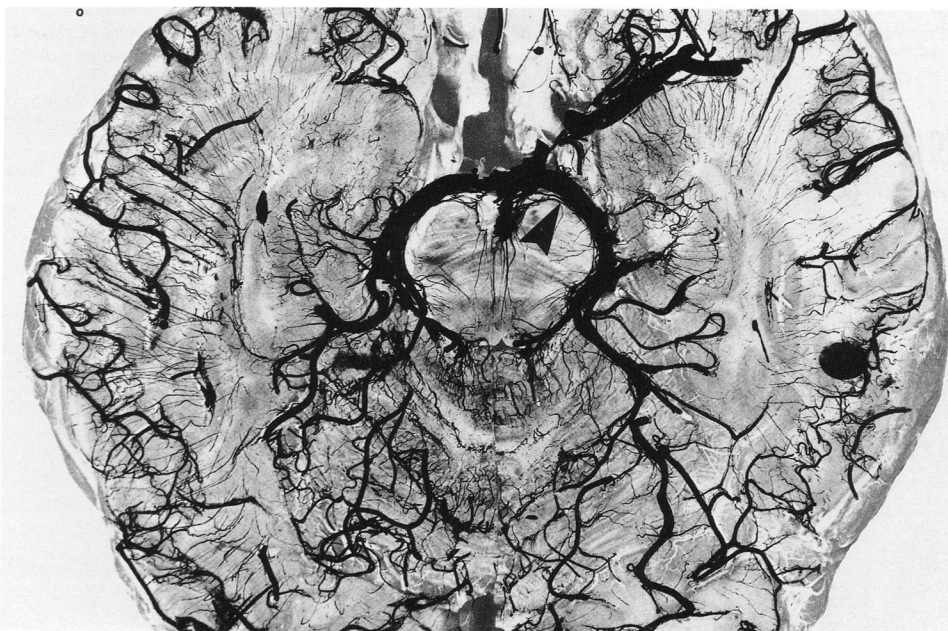

FIG 3. Vascular territory of the posterior cerebral artery at the level of the midbrain. Top left, Diagrammatic representation of level of axial section. Bottom left, Photograph of axial section of brain showing branches of the posterior cerebral artery. Arrow shows site of arterial occlusion. Top right, Diagrammatic representation of bottom left panel, showing perforating branches of the posterior cerebral artery to the lateral midbrain and cerebral peduncles. ACBS indicates superior cerebellar artery; ACC, short circumferential (pontine) arteries; ACHA, anterior chorioid artery; ACMP, posterior communicating artery; ACP, posterior cerebral artery; APTC, perforating (pontine) arteries; ASV, sylvian artery; ATA, anterior temporal artery; ATM, middle temporal artery; and TB, basilar artery. From Salamon.<sup>5</sup>



motor nucleus, but proximal to the perforating branches to the midbrain (Fig 2). A large recent antemortem hemorrhage extended from the left lateral ventricle to the convexity of the left cerebral hemisphere in the distribution of the previous infarct, destroying most of the parietal and occipital lobes and the posterior part of the temporal lobe. The hemorrhage was thought to be secondary to a septic focus eroding the vessel wall at the site of previous occlusion. Macroscopically there was no evidence of aneurysm formation adjacent to the site of occlusion. No infarct was identifiable in the territory of the middle cerebral artery. The cerebral peduncles showed recent softening, and hemorrhages were seen in the swollen brain stem.

### Discussion

In this patient occlusion of the posterior cerebral artery occurred in the perioperative period and was due to embolism of a fragment of the prosthetic mitral valve. Acutely the clinical picture (hemiplegia, hemisensory loss, aphasia, alexia, neglect, hemianopia, head and eye deviation) was difficult to differentiate from middle cerebral artery occlusion; however, the distribution of the infarction on CT scan and the later pattern of neuropsychological deficit were characteristic. The infarction involved the dominant hemisphere. A fragment of the disconnected prosthetic valve was well visualized just distal to the origin of the posterior cerebral artery on CT scan. The fragment was still present at that site 1 year later and at autopsy. There was no radiological or autopsy evidence of involvement of the other cerebral arteries or their territories.

The vascular territory of the branches of the posterior cerebral artery and functional correlations of occlusion of each of these branches are well described.<sup>4</sup> Persisting deficits in this case correlate well with posterior cerebral artery occlusion with predominant involvement of the more distal hemispheric and callosal branches. The homonymous hemianopia was most likely due to involvement of the calcarine cortex. The nominal aphasia and verbal specific memory disturbance were due to involvement of the temporal lobe and hippocampus in the dominant hemisphere. There was no evidence of parietal involvement as seen in middle cerebral artery occlusion.

Hemiplegia in association with posterior cerebral artery occlusion is more difficult to explain. Hommel et al<sup>3</sup> reviewed four patients with hemiplegia due to pos-

terior cerebral artery occlusion confirmed on neuroimaging. In each case the hemiplegia was associated with aphasia, alexia, neglect, hemianopia, hemisensory loss, and conjugate deviation of the head and eyes toward the side of the lesion, without cranial nerve involvement. In each case the hemiplegia was associated with an infarct in the lateral midbrain. Sensation was decreased secondary to thalamic or midbrain lemniscal involvement. It was hypothesized that an arterial occlusion just distal to the origin of the posterior cerebral artery (sparing the proximally arising branches to the posterior thalamus, hypothalamus, subthalamic nucleus, substantia nigra, red nucleus, and oculomotor nerve) could induce lateral midbrain infarction, hemiplegia, and hemisensory loss without third nerve palsy due to selective involvement of the perforating branches to the lateral midbrain (Fig 3). An occlusion at this level could also result in posterior thalamic infarction due to involvement of the more distal thalamogeniculate branches, as well as involvement of the callosal and hemispheric branches.

The CT scan and autopsy findings in this case (Figs 1 and 2) localize the site of posterior cerebral artery occlusion to a point distal to its origin. These findings support the hypothesis of Hommel et al<sup>3</sup> concerning the site of posterior artery occlusion associated with hemiplegia. The proximal branch of the posterior cerebral artery supplying the oculomotor nucleus has been spared, with occlusion of its more distal branches to the lateral midbrain, which supply the pyramidal tracts, medial lemniscus, and posterior nuclei of the thalamus. We were not able to demonstrate lateral midbrain infarction on CT scan or at autopsy, but the precise localization of the arterial occlusion in this patient provides indirect evidence for the mechanism of hemiplegia in posterior cerebral artery occlusion.

### References

1. Benson DS, Tomlinson EB. Hemiplegic syndrome of the posterior cerebral artery. *Stroke*. 1971;2:559-564.
2. Caplan LR, DeWitt LD, Pessin S, Gorelick PB, Adelman L. Lateral thalamic infarcts. *Arch Neurol*. 1988;45:959-964.
3. Hommel N, Bessom G, Pollak P, Kahane P, Le Bas JF, Perret J. Hemiplegia in posterior cerebral artery occlusion. *Neurology*. 1990; 40:1496-1499.
4. Hayman LA, Berman SA, Hinck VC. Correlation of CT cerebral vascular territory with function, II: posterior cerebral artery. *AJR*. 1981;137:13-19.
5. Salamon G. *Atlas de la vascularisation arterielle du cerveau chez l'homme*. Paris, France: Sandoz; 1971:162-163.

## Hemiplegia due to posterior cerebral artery occlusion.

K North, A Kan, M de Silva and R Ouvrier

*Stroke*. 1993;24:1757-1760

doi: 10.1161/01.STR.24.11.1757

*Stroke* is published by the American Heart Association, 7272 Greenville Avenue, Dallas, TX 75231

Copyright © 1993 American Heart Association, Inc. All rights reserved.

Print ISSN: 0039-2499. Online ISSN: 1524-4628

The online version of this article, along with updated information and services, is located on the World Wide Web at:

<http://stroke.ahajournals.org/content/24/11/1757>

**Permissions:** Requests for permissions to reproduce figures, tables, or portions of articles originally published in *Stroke* can be obtained via RightsLink, a service of the Copyright Clearance Center, not the Editorial Office. Once the online version of the published article for which permission is being requested is located, click Request Permissions in the middle column of the Web page under Services. Further information about this process is available in the [Permissions and Rights Question and Answer](#) document.

**Reprints:** Information about reprints can be found online at:  
<http://www.lww.com/reprints>

**Subscriptions:** Information about subscribing to *Stroke* is online at:  
<http://stroke.ahajournals.org/subscriptions/>