

Hemibody Tremor Related to Stroke

Sophie Dethy, MD; André Luxen, PhD; Luc M. Bidaut, PhD; Serge Goldman, MD

Background: Hemibody tremor is an uncommon manifestation of stroke. We describe a case investigated by both brain magnetic resonance imaging and positron emission tomography using [¹⁸F]fluorodeoxyglucose.

Case Description: Three months after a pure motor stroke, a 65-year-old man developed a right arm and leg tremor. The tremor was of large amplitude, intermittent at rest; its frequency was 5 to 6 Hz. Neither rigidity nor akinesia was detected, and administration of L-dopa was ineffective. Brain magnetic resonance imaging revealed an ischemic lesion in the left centrum semiovale and a left caudate lacunar infarction. We suspected that the resting unilateral tremor was related to this lacunar lesion. Positron emission tomography demonstrated glucose hypermetabolism in the left sensorimotor cortex.

Conclusions: This case suggests that unilateral tremor may be related to a lacunar stroke in the caudate nucleus and may be accompanied by an increased glucose metabolism in the contralateral sensorimotor cortex. (*Stroke*. 1993;24:2094-2096.)

KEY WORDS • lacunar infarction • tomography, emission-computed • tremor

Tremor caused by a lacunar stroke is a very infrequent neurological feature. Few cases of hand tremor after caudate or thalamic infarcts have been reported.¹ We describe one patient with a delayed-onset hemibody tremor after cerebral infarction.

Case Report

A 65-year-old hypertensive man abruptly developed a right-sided weakness. The hemiparesis gradually improved, but 3 months later he noticed a tremor of the right hand and foot, which subsequently extended to the right forearm and leg. Administration of L-dopa (200 mg with 50 mg benserazid, both four times daily) and orphenadrine (150 mg daily) was ineffective. After the appearance of the tremor, the patient developed behavioral disturbances characterized by anxiety and agitation; he received haloperidol, which was stopped after a few months. The neuroleptic treatment did not modify the tremor, but involuntary movements of the tongue appeared. The tremor remained unchanged for 5 years.

The patient was evaluated in our department 6 years after the initial stroke. Neurological examination showed mild dysarthria, orofacial dyskinesias, right Babinski's sign, and right-hand clumsiness. There was a right arm and leg tremor, intermittent at rest, which was not modified by posture or worsened with action. Its amplitude was large and increased by anxiety. At rest, the main component of this unilateral tremor consisted of rhythmic (5 to 6 Hz) flexion-extension movements of the elbow, wrist, and fingers in the right upper limb and flexion-extension movements of the knee and ankle in

the right lower limb. Neither rigidity nor bradykinesia was detected in the right hemibody. Laboratory studies and electroencephalogram were normal. Brain computed tomographic scan showed an ischemic lesion in the left centrum semiovale. Brain magnetic resonance imaging (MRI) showed the same ischemic lesion in the left centrum semiovale (Fig 1, top panel) and an additional lacunar infarction in the left caudate nucleus (Fig 1, bottom panel).

Positron emission tomography (PET) using [¹⁸F]fluorodeoxyglucose (FDG) was performed on a CTI-Siemens 933/08/12 PET tomograph (Knoxville, Tenn) with fifteen 7-mm-thick adjacent slices. In-plane spatial resolution (full width at half maximum) was approximately 5 mm. Images were corrected for attenuation using a transmission scan. To evaluate metabolic asymmetry in specific gray matter structures, neuroanatomy-based regions of interest were drawn manually on reconstructed PET slices in the prefrontal cortex, the sensorimotor cortex, the superior parietal cortex, the basal ganglia, and the cerebellum. Asymmetry indexes were calculated as $(\text{left} - \text{right}/\text{left}) \times 100$ in the patient and in a group of nine young normal volunteers 30 to 37 years of age. In the reference group, the asymmetry indexes were expressed in absolute values, and a mean and standard deviation were calculated.

Positron emission tomographic images in the patient showed glucose hypermetabolism in a limited portion of the left sensorimotor cortex where the asymmetry index was 19% for a mean \pm SD value of $5 \pm 3\%$ in the reference group (Fig 2, left panel). At the level of the thalamus and the cerebellum, glucose metabolism was slightly higher on the left side, but the asymmetry indexes calculated in these regions were within 2 SDs above the mean value in the reference group. No significant change was detected in extrarolandic cortical areas or at the level of the caudate or lenticular nuclei (Fig 2, right panel).

Received May 28, 1993; final revision received July 17, 1993; accepted August 3, 1993.

From the PET/Biomedical Cyclotron Unit, Hôpital Erasme, Université Libre de Bruxelles, Brussels, Belgium.

Correspondence to Dr S. Dethy, PET/Biomedical Cyclotron Unit, ULB-Hôpital Erasme, 808, route de Lennik, B-1070 Brussels, Belgium.

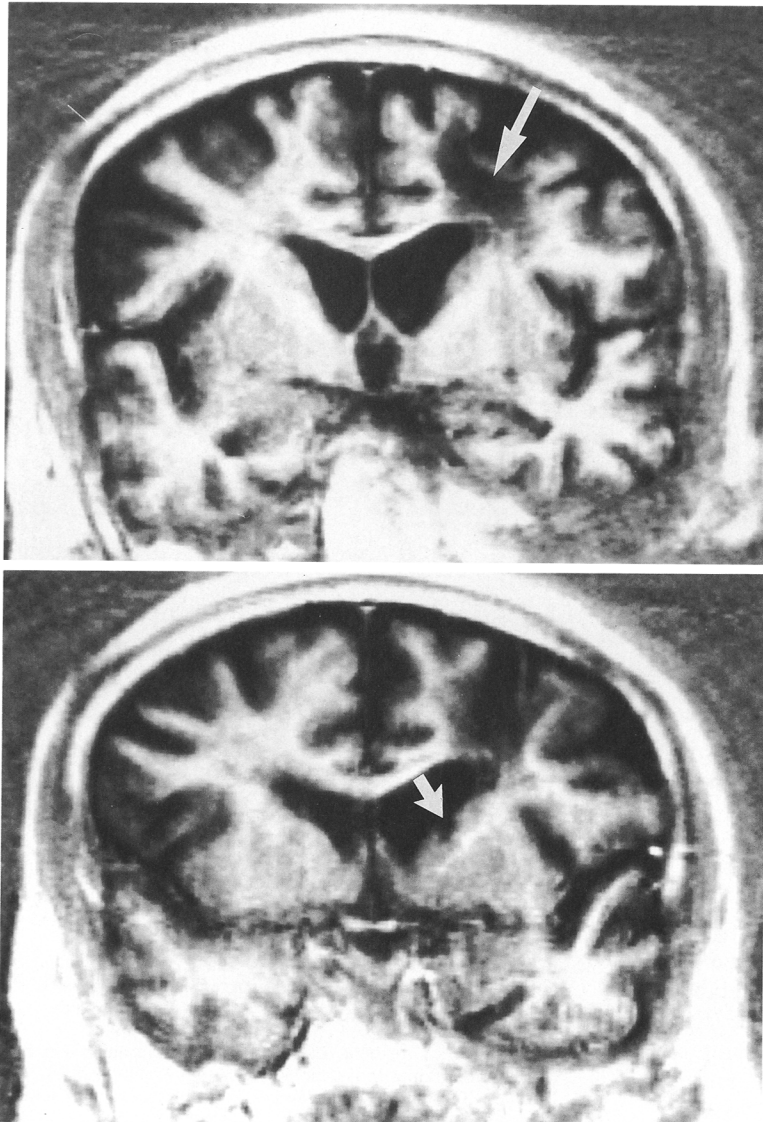


FIG 1. Coronal section of T2-weighted magnetic resonance imaging showing an ischemic lesion in the left centrum semiovale (top) and a lacune in the left caudate nucleus (bottom).

Discussion

Our patient developed right hemibody tremor as a chronic manifestation of stroke. This very unusual neurological manifestation of stroke has been previously described in only one report of three cases of lacunar infarction localized in the contralateral caudate nucleus in two cases and in the contralateral thalamus in one.¹ As in these cases, the unilateral tremor in our patient appeared several months after the symptoms of the initial stroke. In addition to a large ischemic lesion in the left centrum semiovale, MRI revealed a lacunar lesion in the left caudate nucleus. We suspected that the unilateral tremor in our patient was related to the lacunar lesion in the contralateral caudate nucleus. The occurrence at rest was indeed suggestive of a disruption of the nigrostriatal dopaminergic pathways, and the frequency was compatible with this pathogeny. Implication of nigrostriatal disturbances in the production of isolated resting tremor has been recently supported by the finding of reduced [¹⁸F]fluorodopa uptake in the striatum of patients with sporadic isolated resting tremor.² The role of caudate lesions in the physiopathogenesis of tremor may be indirect, with the origin of the

tremor, for instance, in the thalamic or the olivary-cerebellorubral circuitry.³ It is important to note that the left caudate lesion in this hypertensive patient may not be the unique cause of the tremor: other nondetected lacunar lesions, for instance in the brain stem, could possibly participate in the production of this symptom. In the primate, resting tremor is indeed produced by combined lesions of nigrostriatal and rubrospinal tracts.³ We do not suspect that the ischemic lesion in the centrum semiovale has played a role in the production of the resting tremor in our patient. Indeed, reports on extrastriatal hemispheric lesions inducing parkinsonian symptoms concern brain tumors, usually in the frontal lobe, which probably produce reversible dysfunction of the basal ganglia by local increased tissue pressure, as suggested in one case studied by PET before and after surgery.⁴

In our patient, PET using FDG showed a limited zone of hypermetabolism in the left sensorimotor cortex, which probably represented a remote effect of the tremor-inducing lesion. Comparatively, increased neuronal activity in the sensorimotor cortex was also described in a PET study of blood flow changes related to

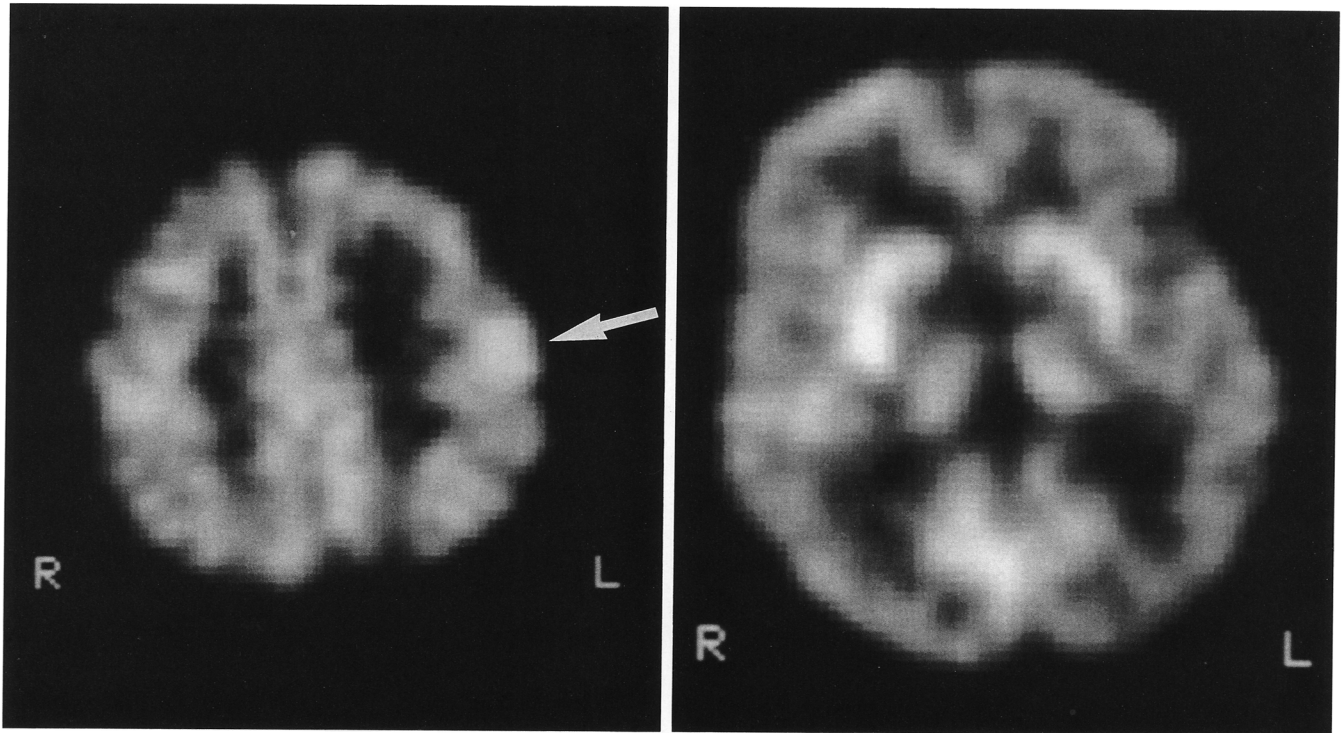


FIG 2. Positron emission tomography with [^{18}F]fluorodeoxyglucose image showing elevated glucose metabolism in the left upper sensorimotor cortex (left) and absence of substantial asymmetry in thalamic and striatal glucose metabolism (right).

unilateral essential tremor.⁵ In our case of resting tremor, we found signs of increased neuronal activity in the cerebellar cortex, as was described in a blood flow study on essential tremor,⁵ but the cerebellar metabolic asymmetry was not significant in our single case. Early neuropathological studies have led to the assumption that lacunar infarcts limited to the caudate nucleus produced no neurological deficit.⁶ Recently, authors have described pure caudate lesions causing behavioral and neurological manifestations^{7,8} and in particular movement disorders, such as chorea^{9,10} and dystonia.¹¹ This case, like two of the three cases previously described,¹ suggests that unilateral tremor may be a clinical manifestation of a lacunar stroke in the caudate nucleus.

Acknowledgments

This study was supported by grants from the Belgian National Lottery and the Belgian National Fund for Scientific Research (Nos. 3.4565.88 and 9.4503.87). Dr Dethy is Research Assistant of the Belgian National Fund for Scientific Research. We thank Dr S. Przedborski and Dr D. Zegers de Beyl for their help in the preparation of this manuscript.

References

1. Kim JS. Delayed onset hand tremor caused by cerebral infarction. *Stroke*. 1992;23:292-294.
2. Brooks DJ, Playford ED, Ibanez V, Sawle GV, Thompson PD, Findley LJ, Marsden CD. Isolated tremor and disruption of the nigrostriatal dopaminergic system: an ^{18}F -dopa PET study. *Neurology*. 1992;42:1554-1560.
3. Pechadre JC, Larochelle L, Poirier LJ. Parkinsonian akinesia, rigidity, and tremor in the monkey. *J Neurol Sci*. 1976;28:147-157.
4. Leenders KL, Findley LJ, Cleeves L. PET before and after surgery for tumor-induced parkinsonism. *Neurology*. 1986;36:1074-1078.
5. Colebatch JG, Findley LJ, Frackowiak RS, Marsden CD, Brooks DJ. Preliminary report: activation of the cerebellum in essential tremor. *Lancet*. 1990;336:1028-1030.
6. Fisher CM. Lacunar strokes and infarcts: a review. *Neurology*. 1982;32:871-876.
7. Caplan LR, Schmahmann JD, Kase CS, Feldmann E, Baquis G, Greenberg JP, Gorelick PB, Helgason C, Hier DB. Caudate infarcts. *Arch Neurol*. 1990;47:133-143.
8. Mendez MF, Adams NA, Lewandowski KS. Neurobehavioral changes associated with caudate lesion. *Neurology*. 1989;39:349-354.
9. Goldblatt D, Markesbery W, Reeves AG. Recurrent hemichorea following striatal lesions. *Arch Neurol*. 1974;31:51-54.
10. Kawamura M, Takahashi N, Hirayama K. Hemichorea and its denial in a case of caudate infarction diagnosed by magnetic resonance imaging. *J Neurol Neurosurg Psychiatry*. 1988;51:590-591.
11. Grime JD, Hassan MN, Quarrington AM, D'Alton J. Delayed-onset posthemiplegic dystonia: CT demonstration of basal ganglia pathology. *Neurology*. 1982;32:1033-1035.

Hemibody tremor related to stroke.
S Dethy, A Luxen, L M Bidaut and S Goldman

Stroke. 1993;24:2094-2096

doi: 10.1161/01.STR.24.12.2094

Stroke is published by the American Heart Association, 7272 Greenville Avenue, Dallas, TX 75231

Copyright © 1993 American Heart Association, Inc. All rights reserved.

Print ISSN: 0039-2499. Online ISSN: 1524-4628

The online version of this article, along with updated information and services, is located on the
World Wide Web at:

<http://stroke.ahajournals.org/content/24/12/2094>

Permissions: Requests for permissions to reproduce figures, tables, or portions of articles originally published in *Stroke* can be obtained via RightsLink, a service of the Copyright Clearance Center, not the Editorial Office. Once the online version of the published article for which permission is being requested is located, click Request Permissions in the middle column of the Web page under Services. Further information about this process is available in the [Permissions and Rights Question and Answer](#) document.

Reprints: Information about reprints can be found online at:
<http://www.lww.com/reprints>

Subscriptions: Information about subscribing to *Stroke* is online at:
<http://stroke.ahajournals.org/subscriptions/>