

# Involuntary Tonic Spasms of a Limb Due to a Brain Stem Lacunar Infarction

David K. Kaufman, MD; Robert D. Brown, Jr, MD; William E. Karnes, MD

**Background and Purpose** Although repetitive involuntary movements are a well-recognized manifestation of carotid occlusive disease, similar movements have not been reported with a lacunar infarction outside of the basal ganglia or subthalamic nucleus. We describe a man with tonic spasms associated with a lacunar infarction in the right ventral pons.

**Case Description** Involuntary tonic spasms of a paretic limb developed acutely in a 69-year-old hypertensive man with a clinical presentation of pure motor hemiparesis. Magnetic resonance imaging demonstrated a lacunar infarction of the

ventral pons. There was no evidence for carotid occlusive disease. An electroencephalogram recorded during the movements showed no abnormality. The abnormal movements responded well to treatment with oral diazepam.

**Conclusions** A brain stem lacunar infarction may be associated with involuntary tonic limb spasms clinically similar to those reported as paroxysmal symptoms of multiple sclerosis. (*Stroke*. 1994;25:217-219.)

**Key Words** • brain stem • lacunar infarction • motor activity

Involuntary movements due to cerebral ischemia have been documented in previous reports.<sup>1-5</sup> These phenomena have been attributed to intermittent cerebral ischemia due to carotid occlusive disease. To our knowledge, there have been no prior reports of involuntary movements due to a lacunar infarction that does not involve the basal ganglia or subthalamic nucleus. We report a case of involuntary tonic spasms of a mildly paretic limb due to a pontine lacunar infarction.

## Case Report

The patient was a 69-year-old right-handed man with treated hypertension, coronary artery disease, and a 25-pack-year history of smoking. His symptoms began when he awoke with a dull occipital headache 4 days before admission. During that and subsequent days he was aware of gait difficulty and intermittent weakness of the left upper extremity. Family members noticed that the left side of his mouth drooped and his speech was different. During the 2 nights before admission, he was unable to sleep because of brief, painless, intermittent "jerks" of his left leg that recurred every 30 seconds. This symptom continued regardless of leg position and was present when he attempted to ambulate in an effort to "walk it off." He recalled a brief period when there was a simultaneous "jerking" of the left shoulder as well. The right leg was never involved. This activity resolved almost entirely during the day, only to resume again at night. He had never experienced similar symptoms previously. He denied loss of consciousness, diplopia, dysphagia, and sensory abnormalities. His only medication on admission was nifedipine 30 mg daily.

Examination revealed an alert, overweight man with a resting blood pressure of 172/88, no cardiac murmurs, and no carotid bruits. There was a mild to moderate left hemiparesis of the arm and face, with the leg only mildly affected. Mild hyperreflexia, pronator drift, and a Babinski sign were present on the left. The speech was mildly dysarthric, and tandem gait was impaired. The remainder of the neurological examination was normal.

Laboratory studies on admission, including complete blood count, electrolytes, glucose, prothrombin time, and partial thromboplastin time, were normal. A computed tomographic scan of the head was normal. The patient was started on intravenous heparin. During the hospitalization, several periods of abnormal movement of the left leg were observed. These were 2- to 3-second episodes of sudden-onset, stereotyped, tonic contractions of the agonist and antagonist muscles of the proximal and distal left lower extremity. While supine, the muscles of the limb would suddenly contract synchronously with the hip and knee remaining extended and the ankle becoming plantar extended. The movement repeated every 30 seconds regardless of position and was present when the patient attempted to ambulate. During the movements, there was no change in the patient's level of consciousness or mental status, and the left upper extremity was unaffected. Between the spasms the leg returned to baseline. This activity was temporarily abolished with a 5-mg dose of oral diazepam but returned a few hours later.

An electroencephalogram (EEG) while awake and asleep was performed with a surface accelerometer attached to the left tibialis anterior muscle (Fig 1). The recorded movements were not associated with any change in the EEG. Carotid ultrasound and Doppler examinations of the vertebral arteries were normal. A transthoracic echocardiogram was normal. A magnetic resonance imaging (MRI) examination of the head with gadolinium (Fig 2) revealed a discrete focus of increased T2 signal within the ventral right pons consistent with a lacunar infarction. There were several other

Received July 30, 1993; final revision received September 13, 1993; accepted September 13, 1993.

From the Department of Neurology, Mayo Clinic and Mayo Foundation, Rochester, Minn.

Reprint requests to Robert D. Brown, Jr, MD, Department of Neurology, Mayo Clinic, Rochester, MN 55905.

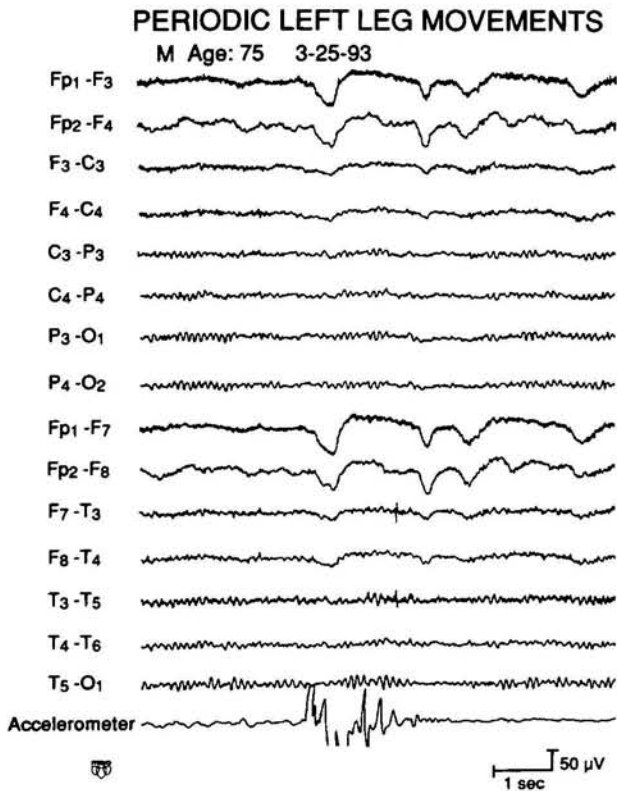


FIG 1. An electroencephalogram (EEG) while awake and asleep was normal. The EEG was performed with a surface accelerometer placed on the left tibialis anterior muscle. Tonic spasms as reflected on the accelerometer were unassociated with any electrographic discharge on the EEG.

much smaller areas of increased T2 signal within the white matter of both cerebral hemispheres that were of uncertain significance. No other areas of infarction were noted.

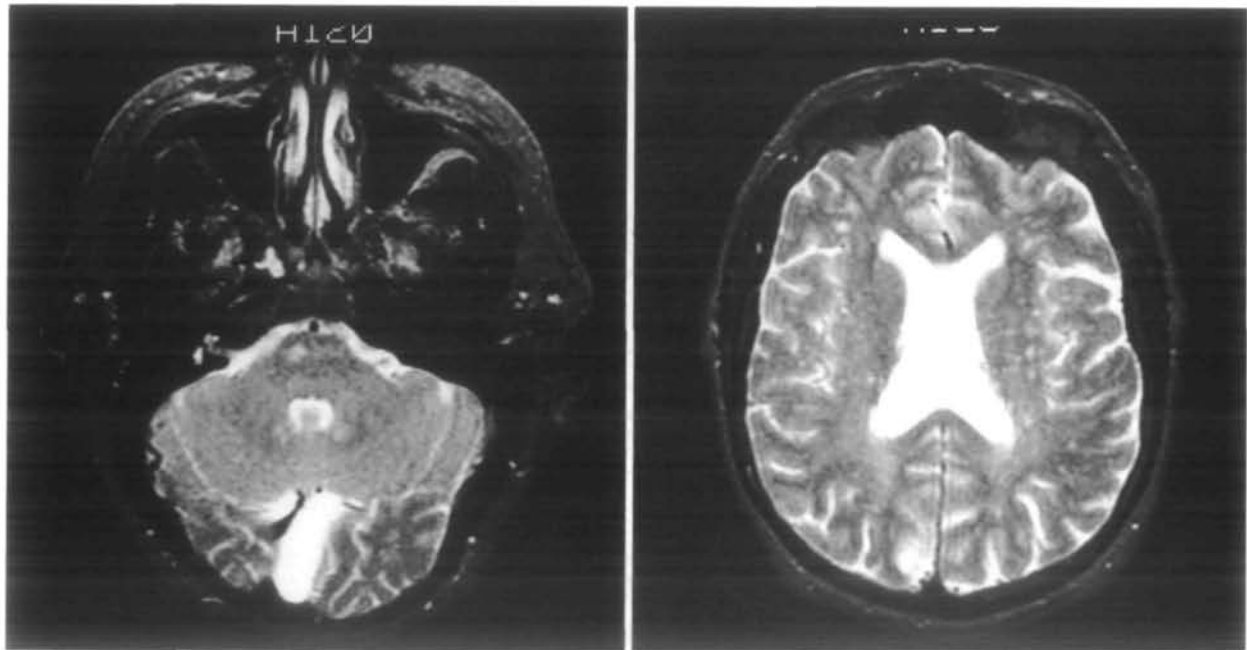


FIG 2. Magnetic resonance image scanning of the head revealed a discrete focus of increased T2 signal within the ventral right pons consistent with lacunar infarction. Multiple tiny areas of increased T2 signal were noted within the deep white matter bilaterally.

The intravenous heparin was stopped, and the patient was dismissed on one aspirin daily. The tonic spasms became less frequent during 3 days of hospitalization and ceased altogether after the first night at home.

**Discussion**

Repetitive involuntary movements (RIMs) are a well-established manifestation of carotid artery disease. Fisher<sup>1</sup> first described involuntary motor manifestations of transient ischemic attack (TIA) such as “trembling, shaking and twisting” of an affected body part, emphasizing that such movements were not convulsive in nature. Others have reported the clinical characteristics and surgical outcomes of patients with RIMs associated with severe carotid artery disease.<sup>3,4</sup> Clinical features include brief, irregular, or rhythmic jerking or shaking of extremities contralateral to a severely stenotic or occluded carotid artery. Postural dependence, being precipitated by abrupt standing or walking and relieved by laying supine, has been variably reported. EEGs performed during the symptoms in two patients revealed focal slowing in an appropriate area but no epileptiform activity. Resolution was common after surgical correction of the carotid stenosis. The mechanism of the movement disorder was presumed to be cerebral ischemia. Using cerebral blood flow studies, Tatemichi et al<sup>5</sup> supported this concept by demonstrating perfusion insufficiency in a patient at rest with limb-shaking TIAs. The focal perfusion deficit improved and the patient’s symptoms resolved after carotid endarterectomy.

Clonic limb movements have been described in patients with basilar artery occlusive disease.<sup>6</sup> Ropper described eight patients with convulsive limb movements, some of which were associated with incontinence, unresponsiveness, and confusion; at least one patient maintained alertness. Four patients were autopsied; three had extensive pontine infarctions, and

one had an infarct of the midbrain tegmentum. The other four had radiological imaging with nonlacunar thalamic or brain stem infarctions. No patients had an EEG at the time of the movements. The movements tended to be more prominent on the side contralateral to the hemiparesis, allowing a hypothesis of ischemia in the spared corticospinal tract.

Our patient presented clinically with a pure motor hemiparesis according to the classification of Fisher.<sup>7</sup> Chimowitz et al<sup>8</sup> demonstrated that such a presentation is highly predictive of a lesion involving the internal capsule, corona radiata, or pons. Boiten and Lodder<sup>9</sup> also showed the high predictive value of the major lacunar syndromes as a clinical test for the diagnosis of lacunar infarcts. These authors distinguished four lacunar syndromes on clinical grounds, which included pure motor stroke, sensorimotor stroke, pure sensory stroke, and ataxic hemiparesis including dysarthria-clumsy hand cases. The MRI of our patient demonstrated an appropriate lesion of the basis pontis contralateral to his hemiparesis. The subsequent development of involuntary tonic spasms in the patient's paretic limb might be attributed to the pontine lacunar infarction that is both anatomically and temporally correlated. Furthermore, the temporary presence of symptoms that occurred in the patient's paretic arm simultaneously with the leg spasms further supports this correlation.

The involuntary limb spasms in this patient are in many ways reminiscent of the tonic seizures experienced by multiple sclerosis (MS) patients as a paroxysmal symptom.<sup>10-16</sup> According to Matthews,<sup>10</sup> tonic seizures are "brief, frequent, often intensely painful episodes in which the limbs on one side adopted the tetanic posture." The symptoms are often triggered by movement, sensory stimulation, or hyperventilation and resolve after a few weeks. The spells are generally stereotyped, brief (30 seconds or less), and recurrent (up to hundreds of times per day).<sup>11</sup> Osterman and Westerberg<sup>13</sup> have suggested transversely spreading ephaptic activation of axons within a partially demyelinated lesion of the central nervous system as a possible mechanism for the tonic seizures as well as for other paroxysmal disorders in MS. The symptoms typically respond well to carbamazepine.<sup>14</sup>

It is unclear what mechanism caused involuntary tonic spasms in the paretic limb of this patient with a pontine lacunar infarction. The absence of any change on the EEG during a typical spell argues against an epileptic phenomenon. The involuntary tonic spasms in this patient are not typical of the rhythmic jerking and shaking episodes that characterize the RIMs and limb-shaking TIAs of carotid occlusive disease.<sup>3,4</sup> Furthermore, the symptoms were not precipitated by assuming an upright posture, and no evidence was found for significant carotid artery disease. These features make it unlikely that this movement disorder was a manifesta-

tion of transient cortical or subcortical ischemia. The involuntary movements in our patient are most similar to the tonic seizures of MS, although key features of associated sensory symptoms and triggering factors are not present. One might envision the lacunar infarct in this patient causing a disturbance of corticospinal tract function in the same way an MS plaque would cause an abnormality in the same location. It unclear whether it is electrophysiologically possible for an area of infarction (or the surrounding ischemic penumbra) to induce local ephaptic transmission of otherwise normal axonal impulses. Alternatively, the lesion may interfere with descending inhibitory fibers affecting the anterior horn cells of the involved limb. The therapeutic effectiveness of the  $\gamma$ -aminobutyric acid-facilitating drug diazepam would support the theory that the lesion is interfering with inhibitory control.

Lacunar infarcts are rarely associated with movement disorders.<sup>6</sup> Hemiballismus is classically due to an infarct of the subthalamic semilunar nucleus of Luys. Acute dystonia may result from a thalamic lacunar infarction. To the best of our knowledge, involuntary movements have not been previously described in association with a lacunar infarction occurring outside of the basal ganglia.

## References

1. Fisher CM. Concerning recurrent transient cerebral ischemic attacks. *Can Med Assoc J.* 1962;86:1091-1099.
2. Ross Russell RW, Page NGR. Critical perfusion of brain and retina. *Brain.* 1983;106:419-434.
3. Yanagihara T, Piepgras DG, Klass DW. Repetitive involuntary movement associated with episodic cerebral ischemia. *Ann Neurol.* 1985;18:244-250.
4. Baquis GD, Pessin MS, Scott RM. Limb shaking: a carotid TIA. *Stroke.* 1985;16:444-448.
5. Tatemichi TK, Young WL, Prohovnik I, Gitelman DR, Correll JW, Mohr JP. Perfusion insufficiency in limb-shaking transient ischemic attacks. *Stroke.* 1990;21:341-347.
6. Ropper AH. 'Convulsions' in basilar artery occlusion. *Neurology.* 1988;38:1500-1501.
7. Fisher CM. Lacunar strokes and infarcts. *Neurology.* 1982;32:871-876.
8. Chimowitz MI, Furlan AJ, Sila CA, Paranandi L, Beck GJ. Etiology of motor and sensory stroke: a prospective study of the predictive value of clinical and radiologic features. *Ann Neurol.* 1991;30:519-525.
9. Boiten J, Lodder J. Lacunar infarcts: pathogenesis and validity of the clinical syndromes. *Stroke.* 1991;22:1374-1378.
10. Matthews WB. Tonic seizures in disseminated sclerosis. *Brain.* 1958;81:193-206.
11. Matthews WB. Paroxysmal symptoms in multiple sclerosis. *J Neurol Neurosurg Psychiatry.* 1975;38:617-623.
12. Ekbom KA, Westerberg C-E, Osterman PO. Focal sensory-motor seizures of spinal origin. *Lancet.* 1968;1:67. Abstract.
13. Osterman PO, Westerberg C-E. Paroxysmal attacks in multiple sclerosis. *Brain.* 1975;98:189-202.
14. Espir MLE, Millac P. Treatment of paroxysmal disorders in multiple sclerosis with carbamazepine (Tegretol). *J Neurol Neurosurg Psychiatry.* 1970;33:528-531.
15. Espir MLE, Watkins SM, Smith HV. Paroxysmal dysarthria and other transient neurologic disturbances in disseminated sclerosis. *J Neurol Neurosurg Psychiatry.* 1966;29:323-330.
16. Heath PD, Nightingale S. Clusters of tonic spasms as an initial manifestation of multiple sclerosis. *Ann Neurol.* 1982;12:494-495.