

SIMPLE FORMED HALLUCINATIONS CONFINED TO THE AREA OF A SPECIFIC VISUAL FIELD DEFECT

by JAMES W. LANCE

*(From the Division of Neurology, The Prince Henry Hospital, Sydney, and the
School of Medicine, University of New South Wales)*

INTRODUCTION

UNFORMED visual hallucinations, such as flashes of white or coloured lights, are known to originate from the retina or from the primary receptive area for vision in the occipital cortex (area 17 of Brodmann). Foerster (1931) observed that electrical stimulation of areas 17 and 18 caused patients to see flashes of light and colour before their eyes and that organized images were obtained by stimulation of area 19, the visual association cortex. In spite of this important experimental evidence the source of formed hallucinations in cerebral disorders remains controversial.

Horrax (1923) summarized cases previously recorded, starting with a report by Westphal in 1879. Most of the patients projected their images in a single lateral direction, corresponding to impairment of vision in the visual field opposite to the lesion and it was concluded by the early writers that the source of hallucinations was the calcarine area or the neighbouring occipital region. Horrax also mentioned cases of Hughlings Jackson, Foster Kennedy and others in whom visual hallucinations were associated with tumours of the temporal lobe. He proceeded with an analysis of 17 patients (out of a total of 72 patients with temporal lobe tumours) from Cushing's clinic who had visual hallucinations of some sort, 12 of whom described formed images. Of the 6 patients with detailed documentation of the nature of hallucinations and visual field defects, 3 had a left homonymous hemianopia, 2 had an upper quadrantanopia and one was 'almost blind.' The latter was unusual in that the hallucinations were projected to the side of the lesion, but the tumour was a glioma which was seen to extend at least to the mid-line at autopsy. From the hemianopic nature of the field defect in 3 of the patients, it is apparent that some of the lesions were not confined to the temporal lobe.

Weinberger and Grant (1940) reviewed the previous literature on visual hallucinations and reported that 28 of 223 patients with tumours affecting the optic nerves or chiasm had experienced such disturbances. Sixteen of these

patients clearly described their symptoms, which the authors reported in detail. Mostly the sensations comprised unformed or simple hallucinations such as stars, sparks, rockets, rotating wheels, bubbles or balloons, but 6 patients described people and scenes. Weinberger and Grant concluded that visual hallucinations have no localizing value and may be provoked by lesions at any level of the neuro-optic apparatus and that there was no constant relation between the part of the visual field into which the hallucinations are projected and the objectively blind areas. Their conclusions, however, are open to criticism. Of their 6 patients with complex imagery, one had hypothalamic symptoms and the visions were preceded by dizziness, suggesting that the temporal lobe may have been implicated; one had a left homonymous hemianopia which was not satisfactorily explained; one had a post-operative convulsion before the visions and 2 patients complained of visions only after they were completely blind. The evidence that complex hallucinations may arise as an irritative phenomenon from the visual pathways proximal to the cortex is therefore unconvincing.

Symonds and Mackenzie (1957) reported visual hallucinations in 3 of their 9 patients with bilateral loss of vision from infarction of the occipital cortex, a syndrome commonly associated with vertebrobasilar insufficiency.

Mooney, Carey, Ryan and Bofin (1965) described a patient whose initial symptom was the appearance of unformed hallucinations in the right visual field. He was found to have an incomplete right homonymous hemianopia, sparing the macula and part of the upper quadrants. Investigation disclosed a large left parasagittal parieto-occipital meningioma. After removal of the tumour, the patient complained of formed visual hallucinations as well as perseveration of vision (paliopsia, palinopsia) and distortion of images (metamorphopsia) in the right visual fields, which subsided when he was treated with phenobarbitone.

Critchley (1951) had previously noted the occurrence of formed hallucinations with palinopsia in one of his patients with a deep-seated tumour, while Bender and Kanzer (1941) had recorded the association of hallucinations and metamorphopsia with an extensive temporoparietal tumour. The interest of the report by Mooney *et al.* lies in the fact that the lesion responsible for formed visual hallucinations was remote from the temporal lobe.

The coincidence of seeing 4 patients in six months with formed hallucinations localized to the site of visual field defects which appeared to arise from the parieto-occipital area led to a brief report on this condition being made to the Australian Association of Neurologists (Lance, Cooper and Misbach, 1974). As a result of this, some of my neurological and neurosurgical colleagues referred patients with similar visual hallucinations or made available to me carefully detailed case histories of patients who had been under their care. Because this particular type of visual hallucination is unusual and is a distinctive clinical syndrome, examples experienced by 13 patients are presented here in an endeavour to clarify their nature and site of origin.

THE PATIENTS

There were 5 male and 8 female patients. Case histories are presented, albeit briefly, so as not to miss some of the picturesque phrases and vivid imagery of the original descriptions. The first 4 patients each had a different cause for their visual disturbances with radiological assistance in localizing the lesion in 2 cases (porencephalic cyst, angioma). The remaining 9 patients had a vascular basis for their disorder, cerebral embolism in one and presumed thrombotic infarction in 8 patients, of whom 3 had symptoms of underlying vertebrobasilar insufficiency. The site of the infarction was confirmed by isotope brain scan in 6 patients.

CASE HISTORIES

Miscellaneous Group

Case 1. Epileptogenic focus (right parietal). A schoolboy aged 13 years had experienced odd attacks from one to four times each day since the age of 8 years. These episodes lasted for about thirty seconds and consisted of blurring of vision in the left half-field. During this time he could see himself as a prisoner behind bars looking downwards and to the left where he could see little people with horns who looked like men from outer space. While the attack was in progress, his left pupil was constricted, which was observed by his mother and confirmed by his physician, Dr. D. A. Curran. The attacks were not accompanied by headache or other migrainous features, although his sister suffered from migraine. He was found to have a peripheral defect in his left visual fields, mainly in the lower quadrant, but no other abnormality. The electroencephalogram demonstrated 4-5 Hz waves in the right temporoparietal region with sharp waves and spike components in the right parietal area. Right carotid and vertebral angiograms and a pneumoencephalogram were normal. The visual hallucinations ceased when he was prescribed phenytoin 200 mg daily but recurred after three months and other anticonvulsants were added to his medication. The attacks were again suppressed for some months but returned and continue once a day as a transient left homonymous hemianopia without any accompanying hallucinations. When anticonvulsants were suspended on one occasion he experienced twenty attacks in one day. His visual field defect has now resolved and repeated cerebral scans have been normal.

Case 2. Porencephalic cyst (right occipital). A man aged 23 years, referred to me for examination by Mr. R. A. Money, had suffered episodes from the age of 5 years which recurred from twice to ten times daily, lasting for ten to fifteen seconds on each occasion. In these attacks his head turned to the left while, at the same time, he saw three men standing on his left side. They were smaller than normal. On some occasions the images were grouped in the form of a statue with one large man and three smaller men. On examination he had a complete left homonymous hemianopia. Pneumoencephalography showed that the right occipital pole was almost completely replaced by a porencephalic cyst (fig. 1). There was also an abnormal accumulation of air in the posterior fossa. A right occipital spike focus was a constant feature of the EEG. At craniotomy when the patient was aged 10 years, electrocorticography demonstrated spike discharges superior and medial to the cyst and an area of gliosis was excised. Seizures continued post-operatively but hallucinations consisted of white lines, circles or columns of black, red and blue for some years afterwards when they vanished, leaving only the motor component of his seizures. A right occipital spike focus persisted in the EEG post-operatively.

Case 3. Probable viral encephalitis (mainly left parietal). A nursing sister aged 28 years, a patient of Dr. G. L. Coffey, became drowsy and developed fever, neck stiffness, expressive dysphasia, right hemiparesis and a right visual field defect, the extent of which was uncertain because of the patient's difficulty in co-operating with examination. Electroencephalography showed bilateral slow activity,

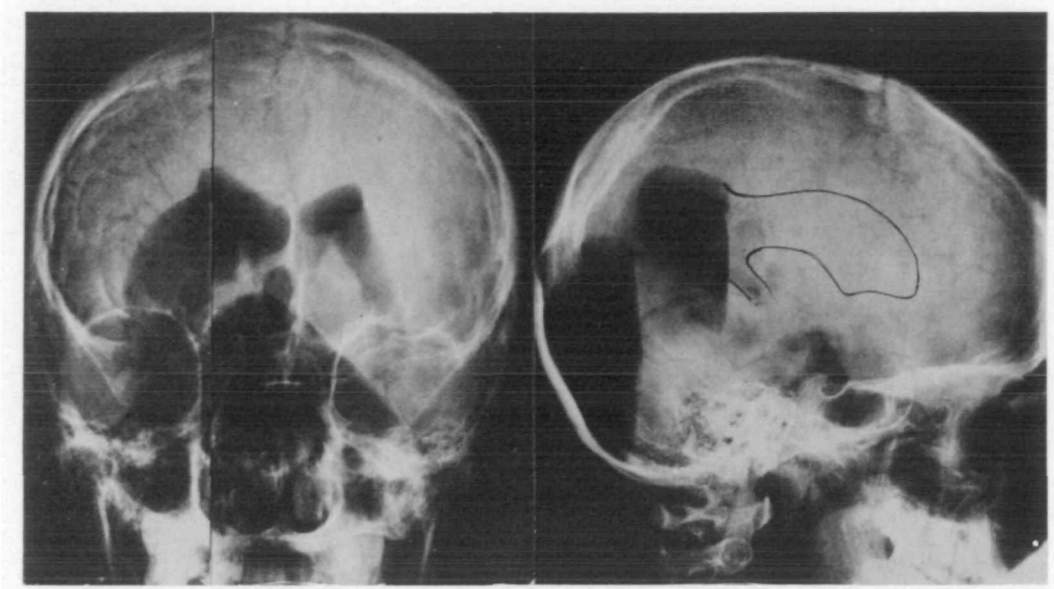


FIG. 1. Porencephalic cyst occupying the right occipital area in Case 2, demonstrated by air encephalography. Antero-posterior film is a composite of two radiographs.

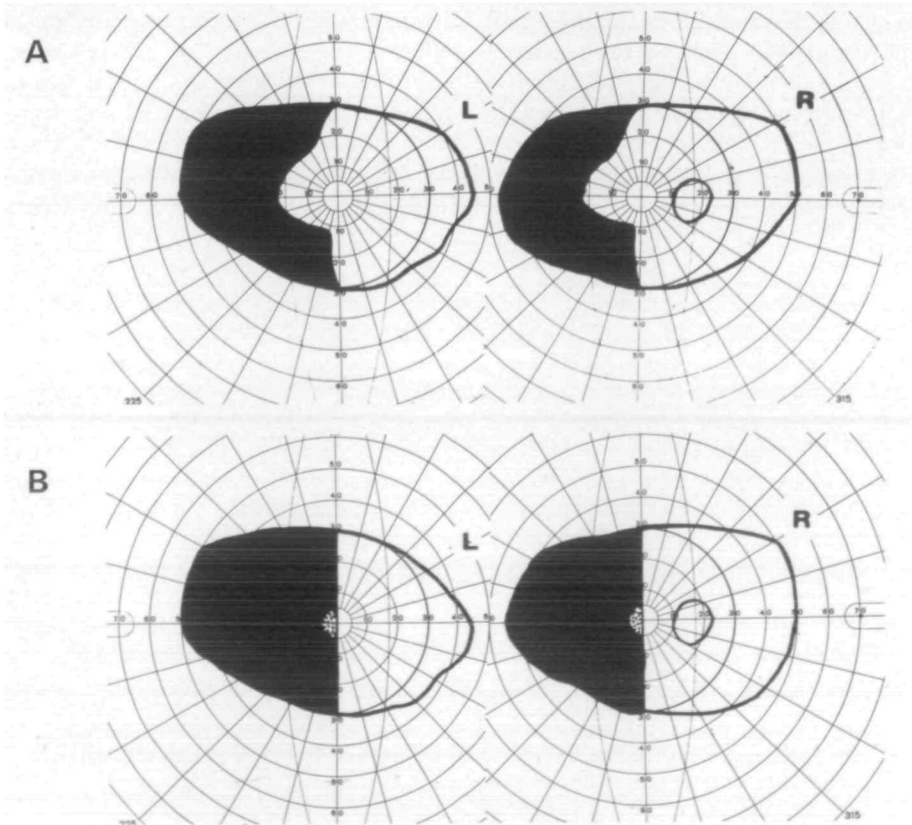


FIG. 2. Visual fields of Case 4. A, before operation, sparing macula; B, after removal of right parieto-occipital angioma, splitting macula.

maximal over the left hemisphere. Brain scan and left carotid arteriogram were normal but her cerebrospinal fluid contained 44 lymphocytes/mm³. She recovered progressively over the course of one week with resolution of her visual field defect and was left with only minimal dysphasia and defect in short-term memory when she became aware of visual hallucinations. These consisted of tiny perfectly formed animals such as giraffes and hippopotamuses, seen on the right side of the pillow or over the right shoulder, and appeared mainly in the late afternoon and early evening. The hallucinations settled on treatment with phenytoin and did not recur when this medication was suspended after some weeks. She has remained well since.

Case 4. Angioma (right parieto-occipital). A woman aged 58 years had suffered from epilepsy since the age of 25. Her attacks recurred several times each month in spite of anticonvulsant medication and consisted of sensations of a flash of light 'like lightning' followed by a tingling in the left leg and sometimes left arm, after which she would lose consciousness and have a typical major seizure. On examination she was found to have a left homonymous hemianopia, sparing the macular area (fig. 2A). A brain scan showed an area of increased uptake of isotope in the right parieto-occipital area and angiography demonstrated an angioma in this area (fig. 3). Since her epilepsy had been unresponsive to large doses

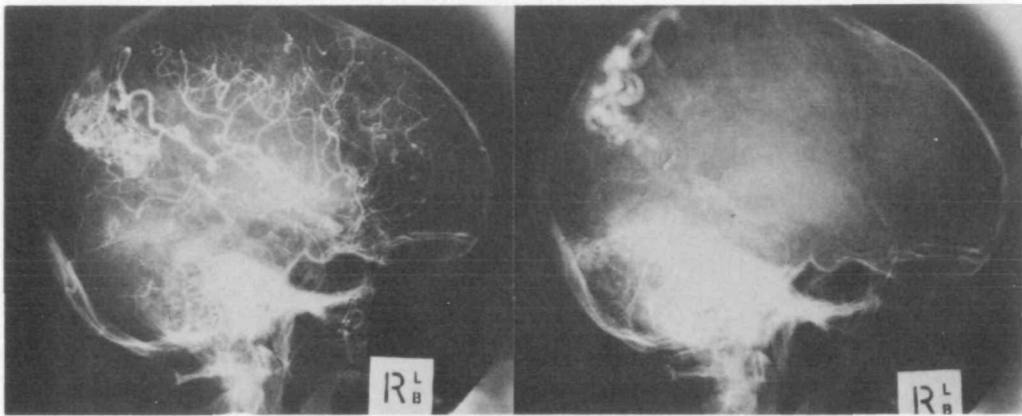


FIG. 3. Right parieto-occipital angioma in Case 4 demonstrated by angiography.

of anticonvulsants, her angioma, together with an underlying plaque of gliosis, was removed by Dr. A. Gonski. She experienced one seizure in the recovery period, not preceded by any visual disturbance, but on three occasions a formed hallucination appeared in her left half fields. The apparition was a different person each time, her father-in-law, her neurosurgeon and the Queen. Details of dress were noted on each occasion. The Queen, with a bag over her arm, walked from the left to the centre of the ward, then vanished. After operation her left homonymous hemianopia included the macular area (fig. 2B).

Vascular Embolism or Thrombosis

Case 5. Left occipital infarction (embolism). A male business executive aged 48 years, a patient of Dr. J. Leicester, suffered from atrial fibrillation as the result of rheumatic heart disease. One evening he suddenly became nauseated, sweaty, dysarthric; his vision blurred and his left arm went through several involuntary pronation-supination movements. He then developed a severe throbbing headache over the vertex and vomited. The headache subsided over a few hours. The next morning he noticed hallucinations in his right visual field. These consisted of pyramids, sculptures, steps and Roman soldiers in sweaty uniforms complete with buckles, all viewed with a greater than natural clarity.

These persisted for three days, whether his eyes were open or closed, flowing into the right visual field, interfering with any attempt to concentrate, read or watch television. After three days, the visions altered to flashing lights, lines, zigzags and twinkling overlapping billiard balls of blue and white which persisted for one day. After this, the pattern changed again, exclusively to cats—cats' heads, kittens' heads, groups of cats looking at him—all in the right visual field. The cats were at first colourful but lost colour as the visions became less frequent, until there remained only one faithful grey and white kitten which he called Dexter because he always came in from the right. Hallucinations ceased one month after the onset although he remained conscious of blackness in his hemianopic right field and sometimes imagined a shadowy form at the edge of his vision on the right. He had never previously shown any particular interest in archaeology, history or cats.

The only physical sign of note was a right homonymous hemianopia which remained dense one month after the onset but was resolving two weeks later, and a bruit audible over the right carotid artery. Four-vessel angiography confirmed stenosis of the origin of the right internal carotid artery. The distal intracranial vessels were not displaced but brain scan showed a small wedge of increased uptake in the PA view to the left of the mid-line separate from the torcula. The appearances were consistent with a left calcarine infarct, presumably from embolization in view of the patient's fibrillation.

Case 6. Left occipital infarction. A woman aged 70 years, a patient of Dr. J. T. Holland, had undergone an operation for rectal prolapse. Two days after the operation she noted formed visual hallucinations of little men crawling over the foot of the bed or in front of her and a large hand arising from the right side and extending over her field of vision. This recurred continuously at first but over the next five days became intermittent and was then definitely restricted to the right visual field. The only abnormality found on examination was a right homonymous hemianopia with doubtful macular sparing. She continues to have a variety of hallucinations on the right side and recently wrote 'they are a menace and I have to keep telling myself the men, women and children are not there as they come to me with outstretched arms, especially at night, and I live alone. The animals and cars which do not exist are not making things very good.'

Case 7. Right occipital infarction (vertebrobasilar insufficiency). A man aged 53 years, a patient of Dr. J. Leicester, experienced an attack of frontal headache with tinnitus, vertigo and vomiting three months after a similar episode. On the second occasion he developed a right intention tremor and a dense left homonymous hemianopia splitting the macula. For the next two weeks he reported distortion of objects seen (fingers becoming thicker and thinner, shorter then fatter), and additional fingers and hands appeared to be present on his left side, thus complicating eating and other semi-skilled activities. A man who had just walked past his bed would be seen to make the journey again a moment afterwards (palinopsia). Two weeks after the onset, formed visual hallucinations appeared on the left side. He saw his beagle sitting on his bed and cats running along a picture rail to his left. A group of visitors standing in front of him multiplied until the ward to his left was filled with a hundred people or so. There were occasional unformed hallucinations such as pairs of lights on an aircraft descending on a dark landing strip. These visual phenomena all ceased one week later.

Isotope brain scan showed a wedge of intensely increased uptake in the medial occipital lobe on the right side. A vertebral angiogram showed some stenosis of the proximal part of the right posterior cerebral artery. The brain scan had returned to normal after three months but his left homonymous hemianopia remained.

Case 8. Right parietal infarction. A woman aged 60 years, a patient of Dr. J. Leicester, was recovering from a vagotomy and gastroenterostomy carried out for a prepyloric ulcer when she developed a left hemiplegia with anosognosia which recovered after some hours and a dense left homonymous hemianopia which resolved over one week. Brain scan was reported as showing diffusely increased uptake in the right parietal area.

At the time of her collapse she saw herself as a tiny figure, two feet long, wrapped in a green bundle on the floor. Subsequently her room appeared very small, like a tiny caravan with the walls close to

her. Black spots on the wall moved across her gaze and disappeared to the left. Later, formed hallucinations were noticed in the left visual field, of two or three people with big heads and discoloured brown skin with black spots. She was not sure who they were; they were possibly relatives but she found them very alarming and had doubts about her sanity. When her hallucinations disappeared after five days she said with relief, 'Thank God they've gone, that lot!'

Case 9. Right occipital infarction (vertebrobasilar insufficiency). A music teacher, a woman aged 62 years with a past history of hypertension, was greeting old friends at a musicale when the room seemed to rock backwards and forwards and she had to hang on to furniture to retain her balance. She became aware of a pain in the back of her head. When she attempted to walk, she veered to the left. It was not until she was admitted to hospital that she realized that she was unable to see to the left. When she returned home and sat down at her piano she commented that she could not see any note below middle C unless she turned her head to the left.

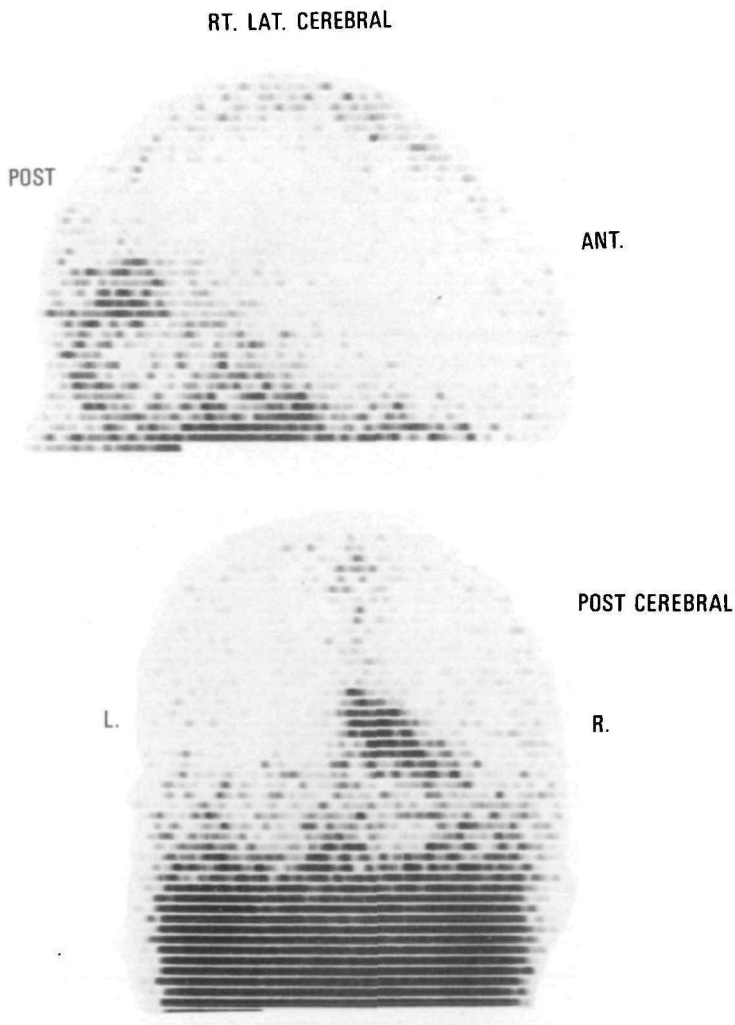


FIG. 4. Isotope scan showing increased uptake in right occipital region (Case 9).

She adjusted to her visual field defect and started to teach music again. Four months later, while taking her first pupil at 7 a.m. she noticed a rippling, whirling movement in her left half visual fields. This sensation recurred intermittently for two days but on the third day, the hallucinations assumed a definite form. She saw a life-sized stream of people coming towards her on the left side. Their faces were solemn but otherwise featureless and, as they passed by, some of them looked at her, some bowed their heads, some shook their heads and others turned their heads away. She said that she felt as though she were lying in Lenin's tomb in the Red Square of Moscow. Occasionally a dog would pass by with its tail wagging 'just like my dog at home.' The next day, the visions partly subsided but any sensory stimulus or excitement started the hallucinations again. The siren of an ambulance or fire engine was enough to start 'a crowd of people scurrying about on my left side.' On another occasion, she smelt actual food cooking and it then appeared as though smoke was pouring from the wall on the left side. This impression continued on and off for two hours as long as the smell of food persisted.

After one week, she saw no more people or smoke but the perception of any sudden movement in her field of vision would make it appear as though the roof were flapping up and down and the walls of the room were undulating on the left side. In addition palinopsia developed. When she was looking at a person, a second image of that person would detach itself from the real image and disappear into the background. On other occasions, she would see someone walk across a room and, a fraction of a second later, an identical image would repeat the action. She described a lady in a blue dress walking, seen 'with her right eye' and, a moment later, the same blue lady was seen in an identical performance 'with her left eye.' She had a similar experience with her own actions. She remembers placing some paper in a basket under her wash basin and then, when she turned the water on in the wash basin, she could see an image of herself placing the paper in the basket again. When she walked out of the bathroom she encountered five or six apparitions of herself, all doing things she had done a short time beforehand.

On examination she had a complete left homonymous hemianopia but no other abnormality although a transient left hemiparesis had been noted at the time of her original episode. A brain scan demonstrated increased uptake in the right occipital area (fig. 4) which resolved over a period of three months. The hallucinations lessened when she was given carbamazepine 600 mg daily and disappeared when the dose was increased to 1 200 mg daily.

Case 10. Right occipital infarction. A diabetic woman, aged 65 years, seen in consultation with Dr. K. Grainger, suddenly developed a transient left hemiparesis and a left homonymous hemianopia which persisted. There was no macular sparing. Brain scan showed an increased uptake in the distribution of the right posterior cerebral artery.

Four days after the onset of her hemianopia she first noticed formed coloured hallucinations in the left field of vision. She described a little girl, a puppy wagging its tail and a train which she recognized as the Indian Pacific (an Australian transcontinental train linking the Indian and Pacific Oceans). Each of these visions were very brief, lasting one to two seconds only. They recurred up to ten times an hour at first but progressively diminished in frequency until they disappeared after three months.

Case 11. Right occipito-parietal infarction. A hypertensive farmer, aged 72 years, awoke one morning to find that purple kidney-shaped blobs were floating across the lower quadrant of his left visual field to the mid-line, where they broke up into small square fragments which then disappeared. This continued throughout the day. The next morning the hallucinations were clearly formed into the shape of animals, seen in their natural colour about a quarter to half their normal size. The animals would appear from the left one at a time. At various times he saw dogs, goats, a lion and a horse as well as birds and butterflies. The animals would emerge from a door on the left side of the room and walk to the mid-line. If he looked to the left the animals retreated towards the door but would advance again as he looked to the front. The images disappeared if he closed his eyes. The patient was well aware that the objects were hallucinations and was afraid that people might think he was mad when he described them. The most complex hallucination was of horses harnessed to a buggy as in a trotting race. The

formed visions persisted during his waking hours for about one month when they regressed in form to the purple blobs he had noticed at first. The final hallucinatory experience was of a large bluish ink-spot with a gold rim around it which floated from the left to the mid-line when it shattered into many smaller particles, each blue with a gold rim, which scattered 'like a flock of seagulls disappearing into the sunset.' He had not had any hallucination since.

His visual fields showed a clearly defined defect in the left lower quadrant (fig. 5) which has persisted. All investigations, including electroencephalogram, brain scan and right carotid angiogram were normal.

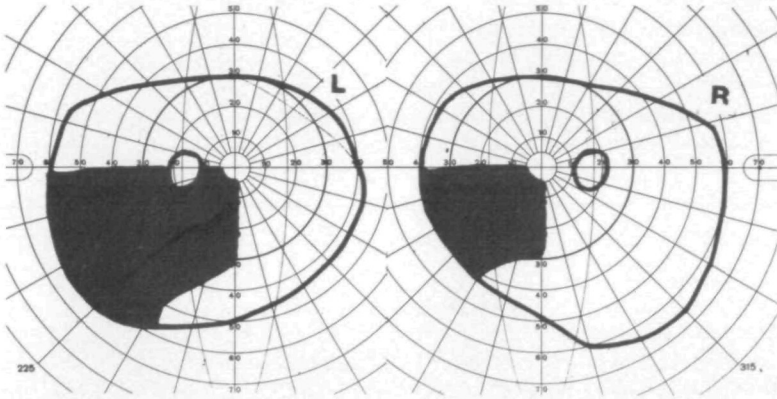


FIG. 5. Left lower quadrant field defect (Case 11).

Case 12. Right occipital infarction. A hypertensive woman, aged 73 years, a patient of Professor J. G. McLeod, suddenly developed a dense left homonymous hemianopia without any accompanying symptoms or signs. Brain scan showed increased uptake of isotope in the right occipital region. Since that time, she has seen lifelike figures in the left visual field, at first when she was wide awake but later when she was feeling drowsy. The vision was often that of a girl aged about 10 or 12 with curly hair. Once she was dressed in a sailor suit like an old photograph of her sister as a child. On some occasions the vision appeared to be close beside her and she could move her hand through it. She can remember other occasions when the image was that of a man, and another time when it was a Chinese lad. She spoke to him and he disappeared. Each apparition lasted for seconds only. The hallucinations gradually disappeared after some months.

Case 13. Left then right occipital infarction (vertebrobasilar insufficiency). I am indebted to Drs. D. S. Pryor and J. Enis for the case history of this patient. A woman aged 72 years experienced 'drop attacks' (atonic episodes in which she suddenly fell to the ground without loss of consciousness) between the ages of 30 and 35 which then ceased. Over the past twenty-five years she had been subject to classical fortification spectra in her right visual field at weekly or monthly intervals. These consisted of two zigzag crescents, one blue and one gold which spread from the periphery of the field on the right towards the mid-line, lasting about twenty minutes each time. They were never associated with headache or other symptoms. For the past four years she had suffered from severe intermittent claudication. Her present trouble started in August 1974, when she experienced sudden vertigo on standing up then lost consciousness for one hour. On awakening she was aware of some difficulty with recent memory and was found to have a right homonymous hemianopia.

Ten days later she began to have three to four episodes of formed hallucinations each day in her right visual field, lasting from a few seconds to a minute or so. They consisted of a pair of elderly human hands, a tricycle, a bicycle, pieces of honeycomb, a pineapple, water running down the side of a glass, numbers or letters. On a few occasions she saw the Union Jack and once only a group of pink pigs. Sometimes when she was watching television, a piece of timber or the branch of a tree emerged from the set and moved towards her, always stopping two to three feet away from her. The visions usually appeared separately but sometimes two or three were seen together. The visions subsided after three months as her field defect improved, and were replaced by white lights or circles, which in turn gradually disappeared. Since the onset of her right homonymous hemianopia, the fortification spectra she had experienced weekly or monthly for twenty-five years have recurred on a few occasions only at intervals of three to four months and have been less distinct.

After the episode in August 1974 she became subject to episodes of vertigo, lasting from a few seconds to five minutes, recurring three to four times a day. In June 1975 she awoke one morning to find that she had completely lost vision in her left half-fields.

Since this episode she has experienced transient visual hallucinations in the left half-fields two or three times each day and lasting about a minute. Some are formed, in the shape of numbers or letters, usually on top of one another, and others are unformed patches of vivid colours or a single colour, either blue or 'peacock green.'

CLINICAL ANALYSIS

The hallucinations were confined to the defective area of the visual field at all times in all patients except for Case 6, who stated that some images appeared to be in front of her for a few days before they became clearly restricted to one half-field. All patients recognized that the visual images were indeed hallucinations although several expressed fears for their sanity when they first appeared. One patient actually passed her hand through the apparitions. The hallucinations were repeated briefly and frequently in 6 patients (Cases 1, 2, 4, 10, 12 and 13), lasting from a few seconds to a minute and recurring from one to twenty times each day. The visions were fairly persistent at first in the remaining patients but became more episodic as time elapsed.

In some patients the hallucinations started at the time of the cerebral insult but in others there was a latent period from the development of the visual field defect of twelve hours (Case 5), two days (Case 6), four days (Case 10), seven days (Case 3), ten days (Case 13 on the first occasion), two weeks (Case 7) and four months (Case 9). The hallucinations continued for a period of three days to three months with the exception of the first 2 cases in whom the hallucinations appeared to be part of a focal epileptic discharge and persisted for some years.

The apparitions were all in colour and most of them were lifelike, full-sized and clear in detail. The visions were smaller than life-size in Cases 1 and 2, one-quarter life-size in Case 11 and tiny in Cases 3 and 6 (visions of giraffes and hippopotamuses sitting on the right side of a pillow, and little men crawling on the foot of the bed respectively). Case 6 later saw hands which were larger than life. The image of herself seen by Case 8 at the time of her cerebral infarction appeared only two feet long but she later had visions of people with unusually large heads. She also complained of micropsia in that her room looked unusually

small and cramped. The hallucinatory images were usually of one person or thing at one time or a small group, but were replicated to be a crowd of people in Cases 7 and 9. In some cases there appeared to be some connection between the visions seen and the past visual experience of the patient; for example, the boy saw spacemen, the farmer saw animals, an elderly lady saw a girl in a sailor suit like her sister wore in a photograph. Mostly the images seemed to be a random selection of people or objects. Indeed, one intelligent patient who saw ancient monuments and Roman soldiers in great detail denied any particular interest in these subjects. There was no question of patients placing their own interpretation on a shapeless mass. All were quite definite about which visions were formed and which were unformed and the transition from one to another when this occurred. Distinctive features about the visions were that they consisted of people and things rather than scenes or landscapes, that any action which took place was stereotyped (head-nodding, walking) and did not tell any story, and that there was no auditory accompaniment.

In 2 patients the apparent repetition of observed movements, similar to an 'instant re-play' on television, was noted, once before the onset of hallucinations (Case 7) and once after the hallucinations (Case 9). This phenomenon, known as palimpsest or palinopsia, is usually associated with a parieto-occipital lesion, most commonly right-sided with a defect in the left half-fields (Bender, Feldman and Sobin, 1968).

Pathophysiology of this Type of Visual Hallucination

The calcarine area of the occipital lobe can be excluded as the origin of formed hallucinations since it was infarcted in many of the cases reported and was replaced by a porencephalic cyst in Case 2. The surrounding visual association cortex is a more likely source since it lies in the watershed area at the junction of posterior cerebral and middle cerebral artery distributions which would be rendered ischaemic but not completely inactivated by occlusion of the posterior cerebral artery. Part of the temporal lobe also lies along this watershed area so that one must seek for clinical evidence to decide whether the parieto-occipital region, temporal lobe or both sites may contribute to this form of visual hallucination. Cases 2 and 4 are particularly helpful in this respect since the nature of the hallucinations changed following operation.

Case 4 had a wedge-shaped angioma at the right parieto-occipital junction with an incomplete homonymous hemianopia sparing the macular area. Pre-operatively her seizures started with a flash of light in the left visual field, indicating origin from the residual calcarine cortex. After excision of the angioma, the hemianopia became complete, splitting the macula, showing that the remainder of the calcarine area had become infarcted. She had no further unformed hallucinations but experienced three formed hallucinations in the left half-field, suggesting that site of spontaneous cortical activity had moved anteriorly to the visual association

cortex. In Case 2, formed hallucinations arose in the hemianopic left field as part of an epileptic seizure in which the patient had turned to the left. After the anterior wall of his occipital porencephalic cyst had been excised, the hallucinations lessened in complexity and appeared simply as white lines, circles or bars of colour. In other cases, formed and unformed hallucinations appeared together (Cases 7 and 8) or there was a transition from formed to unformed or vice versa (Cases 5, 9 and 11) which does not assist in localization. The sites of lesions demonstrated or deduced from clinical evidence in the present series is shown in fig. 6.

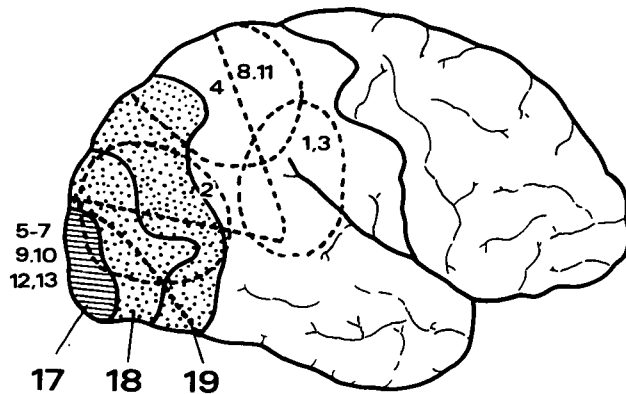


FIG. 6. Apparent site of lesion responsible for formed visual hallucinations. Numbers next to interrupted lines indicate case reference while those below refer to Brodmann's areas.

The nature of the field defect was a homonymous hemianopia in all except Cases 1 and 11 in whom the fixed defect was in the left lower quadrant, indicating a lesion in the superior part of the calcarine cortex or the optic radiation in the parietal lobe.

Those hallucinations projected into the area of the visual field defect appear to arise in the visual association areas adjacent to damaged calcarine cortex after a latent period which implies they are not simply release phenomena. The nature of the neural discharge responsible for the hallucinations was frankly epileptic in Case 2 and probably epileptic in Cases 1 and 4 in whom focal spike discharges were recorded in the EEG. In 3 other patients (Cases 10, 12 and 13) the phenomena recurred for brief periods several times each day in paroxysmal fashion suggestive of epilepsy although the EEG showed only focal slow waves. In the remainder, the hallucinations continued for longer periods or were more or less continuous, and the EEG again showed non-specific slow activity. The concept of spontaneous discharge of neuronal circuits in ischaemic cortex is attractive. Hallucinations were reduced or abolished by anticonvulsant therapy in Cases 1, 2, 3, 4 and 9 but resolved spontaneously in most other patients. Case 6 is still subject to

occasional episodes. Formed hallucinations have been carefully documented as an ictal phenomenon in post-traumatic epilepsy (Russell and Whitty, 1955).

The lesion was in the right hemisphere in 9 patients, in the left hemisphere in 3 patients and both hemispheres in one patient. The preponderance of lesions in the posterior right hemisphere may not be fortuitous because there is evidence from psychometric testing that the right parietal cortex plays a specific role in the intellectual processing of visual data (Basso, De Renzi, Faglioni, Scotti and Spinnler, 1973).

Constriction of the pupil on the side of the hallucination in Case 1 probably resulted from simultaneous stimulation of the pupillary occipital fibres. Cogan (1948) stated: 'The pathways for pupillo-constriction from the occipital area, at least for the cat in which it has been most thoroughly investigated, form a small fascicle in the lateral wall of the lateral ventricle. The pupillary fibres then course over the geniculate body and are scattered through the stratum zonale of the thalamus; thence they course to the pretectal area chiefly of the opposite side, where they undergo synapsis. Removal of the pupillo-constrictor zone in one occiput of the cat results in anisocoria with the larger pupil on the opposite side.'

It may be concluded that the appearance of simple formed hallucinations in the area of a visual field defect is an irritative phenomenon of the visual association cortex which may, in some instances, be frankly epileptic in origin. This type of hallucination has not been encountered by the author unaccompanied by a transient or permanent homonymous defect of the visual fields.

DISCUSSION

Visual hallucinations are not uncommon as manifestations of toxiconfusional states or psychosis. Most recent medical publications are devoted to the action of hallucinogenic drugs. Another cause of hallucinations is the absence of normal flow of information into the visual cortex, an afferent deprivation syndrome observed in patients who are blind from whatever cause (Walsh and Hoyt, 1969). The evidence for hallucinations arising from lesions in areas other than the cerebral cortex, such as the optic tract and mid-brain (*L'hallucinosé pédonculaire*) remains doubtful because of the extensive nature of the lesions reported in such cases (Weinberger and Grant, 1940; Smith, Gelles and Vanderhaeghen, 1971). Vascular lesions of the mid-brain are often associated with vertebrobasilar insufficiency and resulting impairment of blood flow in the posterior cerebral arteries. Hauge (1954) describes 6 patients who developed formed hallucinations one to twenty-four hours after vertebral angiography. The visions, including people, animals, flowers, bicycles and flags, were similar to those described here and by Symonds and Mackenzie (1957) after occipital infarction.

Penfield and Perot (1963) reported visual hallucinations as part of a seizure pattern in 41 of 1132 patients with focal epilepsy. Of these, 21 experienced

hallucinations of vision alone (15 with lesions of the non-dominant hemisphere and 6 with lesions of the dominant hemisphere). Another 11 patients described combined auditory and visual hallucinations, such as a man talking or people dancing to music, and the remaining 9 were dreamlike states with a visual component which was sufficiently vague to prevent classification. On electrical stimulation of the cortex at operation, a person, object or scene was evoked from 38 different points in 19 patients. There were 14 points in the borderland between the occipital lobe and posterior temporal lobes while the remainder were clustered in the superior part of the tip of the temporal lobe or buried deeply beneath the insula. Of the 38 responses, 28 were obtained from the non-dominant hemisphere in 12 patients and 10 from the dominant hemisphere in 7 patients. One patient was of particular interest, a boy aged 12 years in whom 'occipital cortex stimulation produced coloured flashes of light and, immediately anterior to this, stimulation produced the figures of robbers with guns.' Penfield and Perot conclude: 'The points associated with experiences that are largely visual tend to be located in the posterior temporal cortex near the visual sensory area of the occipital lobe, at least on the right side. It is evident, and most significant, that stimulation, within the large speech area of the temporal lobe on the dominant side, never produced visual experimental responses, although such responses are most numerous in that area on the non-dominant side.'

Penfield and Perot (1963) considered that hallucinations evoked at operation were 'a random reproduction of whatever composed the stream of consciousness during some interval of the patient's past working life.' They recognized that there were astonishing gaps in the types of experience recalled.

Among our patients with parieto-occipital lesions the visions were stereotyped with only a few resembling a fragment of memory. The emphasis on objects, people and animals suggests that these are the common building blocks of visual memory, a matrix for the channelling of visual memory rather than the memory itself. While the apparitions are one degree more complex than the flashes, zigzags and whorls of light or colour obtained from the primary receptive cortex in the calcarine area, they fall far short of an integrated visual memory. The visual association cortex may be orientated in such a way as to provide a primary classification and organization of those images most commonly seen. Stimulation of the visual association area, whether directly from parieto-occipital or temporo-occipital lesions, or propagated from other parts of one temporal lobe, may thus activate columns of cells devoted to the category of person, animal or thing.

A sensorimotor seizure most commonly starts in the face or hand because the area devoted to the face and hand is disproportionately large. By the same token, irritation of the visual association cortex may evoke an hallucination which is representative of groups or categories of the most familiar images. The occurrence of such hallucinations with a visual field defect implies that the visual association cortex is more likely to discharge spontaneously once its afferent connections with the primary visual cortex are severed.

SUMMARY

Thirteen patients with transient or permanent homonymous visual field defects experienced formed hallucinations localized to the affected part of the visual field. The lesion was occipital in 8 instances (infarction 7, porencephalic cyst 1), parieto-occipital in 3 (infarction 2, angioma 1) and probably parietal in 2 (epilepsy 1, encephalitis 1). The disorder involved the right hemisphere in 9 cases, the left hemisphere in 3 cases and both hemispheres sequentially in one patient. Hallucinations were accompanied by palinopsia in 2 cases, metamorphopsia in one case and constriction of one pupil in another case.

This particular type of hallucination is considered as an irritative phenomenon of the visual association cortex which can be symptomatic of a parieto-occipital lesion and does not necessarily implicate the temporal lobes. Distinctive features about the visions were that they consisted of people, animals or objects. There was no auditory accompaniment and any action that took place was stereotyped and did not tell a story. In most cases, the hallucinations were not clearly related to any visual memory. It is suggested that the visual association cortex may be responsible for the organization of visual percepts into broad categories of which people, animals and objects are representative.

The occurrence of such hallucinations with a visual field defect suggests that the cells of the association cortex are more likely to discharge spontaneously once they are deprived of their normal afferent inflow from the calcarine cortex.

ACKNOWLEDGEMENTS

I am most grateful to my colleagues for referring their patients or giving me access to their meticulous case histories and investigations where acknowledged in the text. Many of these patients were examined by the late Dr. Bryan Cooper and Dr. P. Beaumont in the Neuro-ophthalmology Clinic, The Prince Henry Hospital.

Fig. 6 was drawn by Mrs. F. Rubiu and all photographs were prepared by the Department of Medical Illustration, University of New South Wales.

REFERENCES

- BASSO, A., DE RENZI, E., FAGLIONI, P., SCOTTI, G., and SPINLER, H. (1973) Neuropsychological evidence for the existence of cerebral areas critical to the performance of intelligence tasks. *Brain*, **96**, 715-728.
- BENDER, M. B., and KANZER, M. G. (1941) Metamorphopsia and other psychovisual disturbances in a patient with tumor of the brain. *Archives of Neurology and Psychiatry, Chicago*, **45**, 481-485.
- FELDMAN, M., and SOBIN, A. J. (1968) Palinopsia. *Brain*, **91**, 321-338.
- COGAN, D. G. (1948) *Neurology of the Ocular Muscles*. 1st edition. Springfield: Thomas, p. 115.
- CRITCHLEY, M. (1951) Types of visual perseveration: 'paliopsia' and 'illusory visual spread.' *Brain*, **74**, 267-299.

- FOERSTER, O. (1931) The cerebral cortex in man. *Lancet*, **ii**, 309-312.
- HAUGE, T. (1954) Catheter vertebral angiography. *Acta Radiologica*, Supplement **109**, 1-219.
- HORRAX, G. (1923) Visual hallucinations as a cerebral localizing phenomenon with especial reference to their occurrence in tumors of the temporal lobes. *Archives of Neurology and Psychiatry, Chicago*, **10**, 532-547.
- LANCE, J. W., COOPER, B., and MISBACH, J. (1974) Visual hallucinations as a symptom of right parieto-occipital lesions. *Proceedings of the Australian Association of Neurologists*, **11**, 209-217.
- MOONEY, A. J., CAREY, P., RYAN, M., and BOFIN, P. (1965) Parasagittal parieto-occipital meningioma with visual hallucinations. *American Journal of Ophthalmology*, **59**, 197-205.
- PENFIELD, W., and PEROT, P. (1963) The brain's record of auditory and visual experience. *Brain*, **86**, 595-696.
- RUSSELL, W. R., and WHITTY, C. W. M. (1955) Studies in traumatic epilepsy. 3. Visual fits. *Journal of Neurology, Neurosurgery and Psychiatry*, **18**, 79-96.
- SMITH, R. A., GELLES, D. B., and VANDERHAEGHEN, J. J. (1971) Subcortical visual hallucinations. *Cortex*, **7**, 162-168.
- SYMONDS, C., and MACKENZIE, I. (1957) Bilateral loss of vision from cerebral infarction. *Brain*, **80**, 415-455.
- WALSH, F. B., and HOYT, W. F. (1969) *Clinical Neuro-ophthalmology*. 3rd edition. Baltimore: Williams and Wilkins, Vol. 1, pp. 116-119.
- WEINBERGER, L. M., and GRANT, F. C. (1940) Visual hallucinations and their neuro-optical correlates. *Archives of Ophthalmology, Chicago*, **23**, 166-199.

(Received April 20, 1976)