

Severe frontal syndrome associated with infarcts of the left anterior cingulate gyrus and the head of the right caudate nucleus

A clinico-pathological case

J.-D. Degos, N. da Fonseca, F. Gray and P. Cesaro

Département de Neurosciences, C.H.U. Henri Mondor, Créteil, France

SUMMARY

The clinicopathological findings in a patient who presented a severe frontal syndrome and who had ischaemic lesions in the left anterior cingulate gyrus and in the head of the right caudate nucleus are reported. The clinical features included complex disorders such as distractibility, docility, emotional unconcern, manual grasping, prehension and utilization behaviour, perseverations and anterograde amnesia. They are closely similar to those previously described in a patient with bilateral lesions involving the anterior cingulate gyri. These findings suggest that (i) in the presence of a lesion of the anterior cingulate gyrus on one side, a lesion of the head of the contralateral caudate nucleus may be equivalent to a lesion of the anterior cingulate gyrus, the anterior cingulate gyrus–caudate complex working as a single functional unit; (ii) the anterior cingulate gyri (and anterior cingulate gyrus–caudate complexes) play a crucial role in the expression of frontal lobe functions; (iii) they are necessary for sustained goal-oriented responses to (emotionally or not) discriminated stimuli.

INTRODUCTION

Severe deficits, such as decreased spontaneous speech and movements have been described in association with bilateral ischaemic lesions of the anterior cingulate gyrus (Barris and Schuman, 1953; Faris, 1969; Freemon, 1971; Buge *et al.*, 1975). However, the lesions extended beyond the anterior cingulate gyrus, making the signs difficult to interpret. Amnesia and personality changes (Okawa *et al.*, 1980; Alexander and Freedman, 1984), such as apathy or lack of concern, following rupture of anterior communicating artery aneurysms, appear related to lesions in areas including the anterior cingulate gyrus, but may also involve other possibly relevant structures. Laplane *et al.* (1981) reported a case of complex behavioural changes, including gross inattention, indifference, docility, prehension and utilization behaviour and a confabulatory amnesic syndrome, associated with a bilateral infarct of anterior cingulate gyrus and fornices. We report the clinicopathological findings in a patient with a clinically similar disorder who had limited ischaemic

Correspondence to: Dr J.-D. Degos, Service de Neurologie, C.H.U. Henri Mondor, 94010 Créteil, France.

lesions in the left anterior cingulate gyrus and anterior cingulate bundle, and in the head of the right caudate nucleus.

CASE REPORT

Mrs P., a 78-year-old right-handed woman, described by her family as an active housewife and an independent-minded, self-sufficient person, was admitted immediately after the abrupt onset of left hemiparesis with loss of consciousness. Hypertension was the only significant previous disorder. On admission, Mrs P. was alert but unable to obey commands or answer questions. The left hemiparesis had recovered and neurological examination was normal except for bilateral Babinski signs and grasp reflexes. Clinical and ECG signs of atrial fibrillation were noted.

During the following days, the patient could be persuaded to walk and talk only by vigorous encouragement. When left to herself, she remained silent and motionless for hours, with episodic motor agitation. When fed or nursed, she seemed remarkably indifferent to both the nurses and the situation. On examination, bilateral extensor plantar responses and grasp reflex persisted; an obvious prehension and utilization behaviour was observed: silent tactile and/or visual presentation of objects compelled the patient to grasp them (she could end up with many objects in her hands), and use them (e.g. having grasped a pen and a sheet, she started writing, but without order); this behaviour occurred even if the patient was told a few seconds before not to grasp. Her attention shifted constantly to any external stimulus. Formal neuropsychological assessment was impossible because of this distractibility by irrelevant stimuli and inability to sustain goal-oriented behaviour. Mrs P., of Portuguese parents, was born in France and was bilingual; however, whether a question was put in French or Portuguese, she regularly answered in French. Her speech was unaltered but her responses were usually limited to a single word. She was able to state her name, age, birth date and address, and, occasionally, she gave coherent responses about past events in her life. She could even repeat long sentences correctly, and her digit span was 6. She could state the year and the month, but not the precise day. She could not recognize the members of the medical staff and was unable to recall a single word 2 min after learning it. Neither confabulation nor false recognition was noted. Objects and pictures (photographs) were correctly named, but serial presentations resulted in perseverations. Alternate motor and graphic Luria's tasks were not carried out. Ideational (e.g. candle lighting) and ideomotor (pantomime, symbolic gesture, imitation of manual or finger postures) apraxia tests were correctly performed. Drawing tasks elicited gross perseverations and disclosed a constructive disability.

Two weeks after her admission, Mrs P. began to feed, wash and dress herself but only if she was specifically and repeatedly asked to do so. Unless someone regularly took the precaution of reminding her to visit the toilet, she urinated and defecated wherever she happened to be. Although the reduction in spontaneous speech persisted, provoked responses seemed more readily obtainable. Sometimes she merely answered with a nod or a gesture. She showed little initiative and was very docile. For example, she used to stay motionless at the nurses' office until someone accompanied her back to her room. Her mood seemed rather euphoric in that she used to smile and laugh in imitation of those around her. However, underneath this surface appearance, her lack of emotional concern was startling. Not even the most tragic event or situation seemed to trouble her. She hardly reacted when she was told that her husband to whom she was devoted had fallen ill. One week later, when she was informed of his death, an astonished expression fleetingly crossed her face, but almost immediately her attention was drawn to noise outside her room and it was easy to make her laugh. Questioned about the effect his death had on her, she replied with a smile: 'It's not really great fun.' The prehension and utilization behaviour gradually diminished during this period although the bilateral grasp reflex persisted. Mrs P. knew that she was in a hospital, but not the reason why. She was unable to recall a single word from three she had learned 3 min before, or to recognize more than one in a multiple choice test. Motor and graphic alternate serial tasks continued to be impossible to carry out, and perseverations still interfered with the quality of her writing and drawing.

Her condition remained stable for 1 month before she died suddenly 6 weeks after the onset of the neurological signs.

NEUROPATHOLOGICAL FINDINGS

Post-mortem examination was performed 18 h after death. It revealed a massive pulmonary embolus.

Gross examination of the brain (1280 g) on coronal sections of the hemispheres and sections of the brainstem and cerebellum perpendicular to their axis, showed several, often haemorrhagic, infarcts, all in the anterior cerebral artery territories (Fig. 1). The

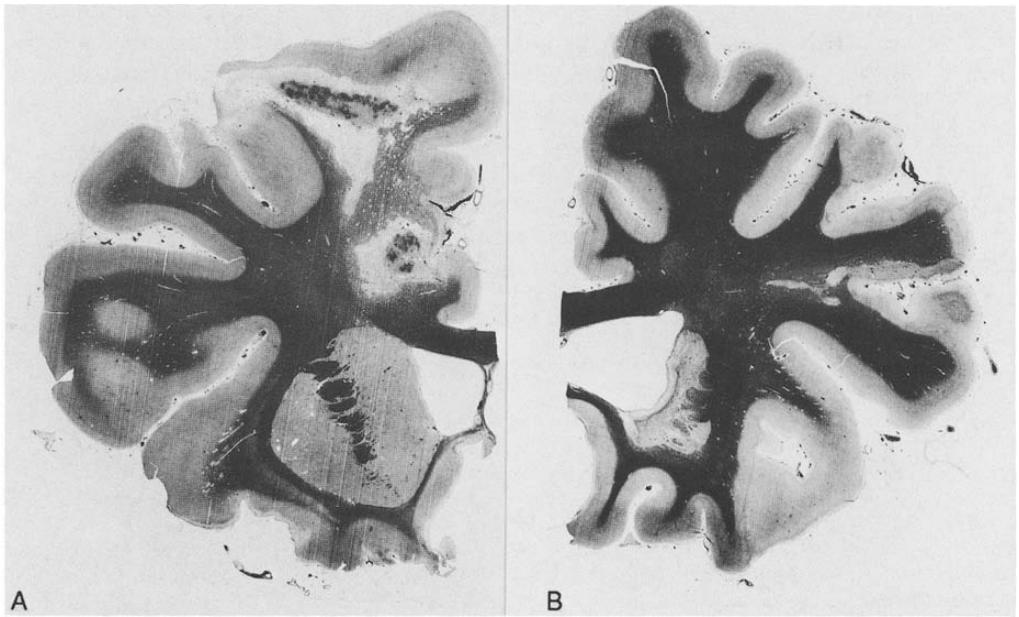


FIG. 1. A, coronal section of the left cerebral hemisphere at the level of the anterior part of the putamen and head of caudate nucleus, Loyez stain for myelin. A partly haemorrhagic infarct involving the cortical territory of the left anterior cerebral artery including the superior frontal gyrus and the cingulate gyrus can be seen. B, coronal section of the right cerebral hemisphere at the same level as A, Loyez stain for myelin. A pale infarct in the territory of the medial striate artery (recurrent artery of Heubner) involving the head of the caudate nucleus and adjacent part of the putamen can be seen. More recent subcortical ischaemic lesions are also present in the inferior frontal gyrus.

basilar part of the right anterior cerebral artery was occluded by an old embolus. The anterior communicating artery, the right pericallosal artery and the left anterior cerebral artery were neither stenosed nor occluded. The remaining intracerebral arteries and the cervical arteries of the carotid-vertebral system were devoid of atherosclerosis or occlusion.

All the hemispheric slices containing the lesions were embedded in celloidin, serially cut at 15 μ m, and stained with haematoxylin and eosin and Loyez's stain for myelin. Every 10 mm on the left and 3 mm on the right a section stained for myelin was drawn with a camera lucida to give a precise topography of the lesions.

Light microscopy confirmed several infarcts of various ages. Two of them (in the territories of left and right anterior cerebral arteries) were old ones, containing numerous lipid laden macrophages and occasional siderophages. More recent lesions with necrosis, slight inflammatory reaction and extravasation of blood cells were also present in the

right frontal cortex. Some embolic arteriolar occlusions were seen in the leptomeninges responsible for limited ischaemic changes.

The topography of all the cerebral lesions is represented in Fig. 2A, B. On the left side, the infarct was old, haemorrhagic and restricted to the superficial territory of the anterior cerebral artery. It destroyed the anterior part of the cingulate gyrus from its anterior pole to a vertical plane through the mamillary body. The cingulum was involved at its anterior part around the rostrum of the corpus callosum. The infarct also extended to the internal part of the superior frontal gyrus. The corpus callosum, medial frontal gyrus and precentral gyrus were spared. On the right side, a pale ischaemic lesion was present in the territory of the medial striate artery (recurrent artery of Heubner). It destroyed the anteromedial part of the head of the caudate nucleus and adjacent part of the putamen; the internal capsule, the pillars of fornices and the septal nuclei were unaffected. Limited and more recent cortico-subcortical haemorrhagic infarcts were observed on both sides of the inferior frontal gyrus. The superior frontal gyrus, cingulate gyrus, cingulum, corpus callosum and precentral gyrus were spared.

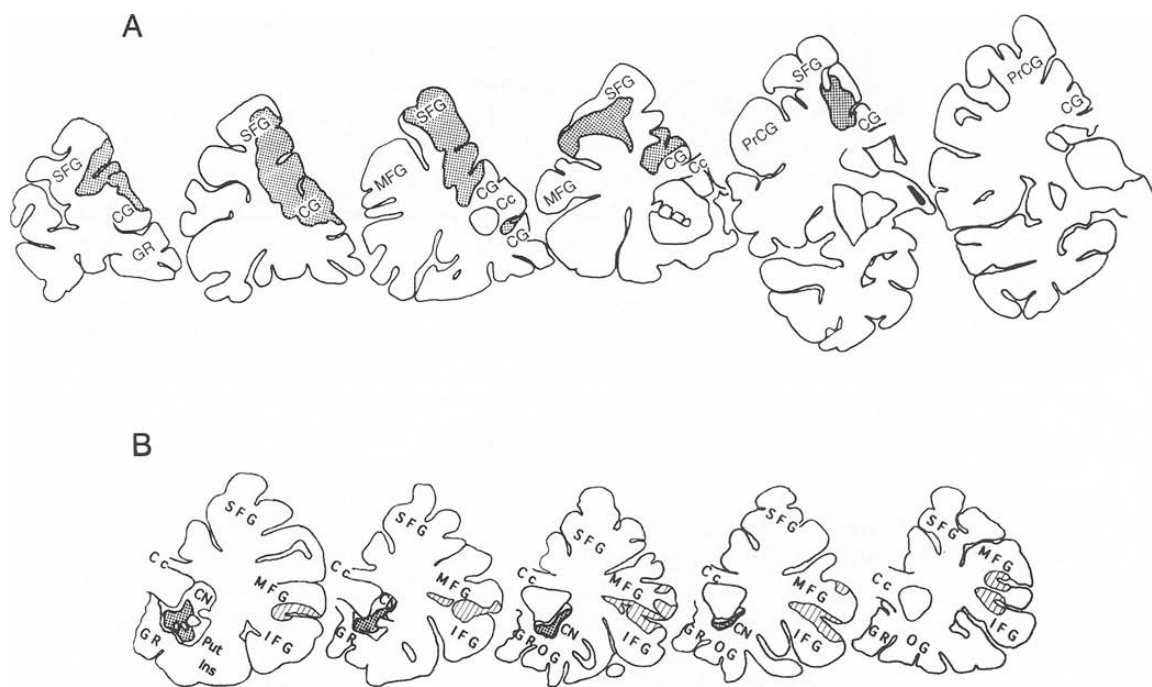


FIG. 2. A, schema representing the topography of ischaemic lesions on the left side. Every 10 mm a section stained for myelin was drawn with a camera lucida. B, schema representing the topography of ischaemic lesions on the right side. Every 3 mm a section stained for myelin was drawn with a camera lucida. The squared areas correspond with the lesions responsible for the symptomatology; the hatched ones correspond with more recent lesions. Cc = corpus callosum; CG = cingulate gyrus; CN = caudate nucleus; GR = gyrus rectus; IFG = inferior frontal gyrus; Ins = insula; MFG = middle frontal gyrus; OG = orbital gyrus; PrCG = precentral gyrus; Put = putamen; SFG = superior frontal gyrus.

DISCUSSION

The clinical features of this case included several complex disorders: distractibility, docility, emotional unconcern, manual grasping, prehension and utilization behaviour, perseverations and anterograde amnesia. They are closely similar to those described by Laplane *et al.* (1981) in a patient with bilateral lesions involving the anterior cingulate gyri, the rostral cingulum bundle and the pillars of the fornices. The clinical similarity was so striking, particularly regarding the dramatic emotional unconcern, that the diagnosis of a bilateral lesion of the anterior cingulate area was immediately suspected.

The anatomical examination of the brain showed bilateral embolic infarcts in the territory of the anterior cerebral arteries: on the left, the anterior parts of the cingulate gyrus and of the cingulum and the adjacent internal part of the superior frontal gyrus were destroyed; on the right the lesion was limited to the anteromedial part of the head of the caudate nucleus and the adjacent part of the putamen, sparing the cingulate gyrus. These infarcts are the same age, and probably responsible for the symptomatology. A few small infarcts were also found in the right frontal cortex; however, these lesions were more recent (less than days), and are likely to have occurred after the clinical onset. As they did not result in any modification of the symptomatology, they can be considered not responsible for it.

These findings suggest that, in the presence of a lesion of the anterior cingulate gyrus on one side, a lesion of the head of the contralateral caudate nucleus may be equivalent to a lesion of the anterior cingulate gyrus. Anatomically, frontal cortico-caudate projections originate from the supra- and infragranular layers of the cortex. This distinguishes them from other cortico-fugal pathways to subcortical structures which arise from infragranular layers only, and makes them similar to inter-cortical connections (Royce, 1982; Arikuni and Kubota, 1986). Thus the function of the caudate nuclei may be intimately related to the function of the corresponding cerebral cortex, and anterior cingulate gyrus—caudate complex can be seen as a single functional unit.

Of interest in our case is the small size of the lesions contrasting with their devastating neuro-behavioural effect. Most elements of the so-called frontal lobe syndrome were present, suggesting that the anterior cingulate gyrus—caudate complex constitutes a crucial pathway in the expression of frontal lobe functions. Small subcortical lesions are able to produce some components of the frontal lobe syndrome (Castaigne *et al.*, 1966; Richfield *et al.*, 1987; Mendez *et al.*, 1989; Caplan *et al.*, 1990; Pedrazzi *et al.*, 1990; Trillet *et al.*, 1990; Sandson *et al.*, 1991). However, in our patient, as in the patient of Laplane *et al.* (1981), the frontal lobe syndrome was strikingly complete and severe.

Prehension and utilization behaviour, which was present in these two cases, has been described by Lhermitte (1983) who ascribed it to lesions of the orbital surface of the frontal lobe, and possibly, of the head of the caudate nucleus. In fact, his pathological case had ischaemic lesions in the territory of Heubner's arteries involving the head of the caudate nucleus bilaterally. Furthermore, the coronal sections of the frontal lobes displayed bilateral demyelination of the white matter reflecting the disconnection of large areas of frontal cortex. The four other patients had large frontal lesions involving the medial aspect of one cerebral hemisphere on CT scan; similar features were found in the case described by Shallice *et al.* (1989). Therefore it seems likely that, in these cases, the prehension and utilization behaviour resulted from a lesion of the anterior cingulate gyrus—caudate complex.

It has been proposed that cingulate gyrus is a part of a network for the distribution of directed attention (Mesulam, 1990). This statement is clinically based on the location of the lesions responsible for neglect in both humans and monkeys, namely the dorsolateral posterior parietal cortex, the dorsolateral premotor-prefrontal cortex and the cingulate gyrus. However, as far as the anterior cingulate gyrus is concerned, it is not in accordance with the present and previous clinico-pathological data (Laplane *et al.*, 1981) where neglect was absent. We propose another functional diagram after having surveyed the few available data on anterior cingulate gyri.

Bilateral surgical lesions of the anterior cingulate gyrus and/or anterior cingulate bundles in mentally disabled patients do not result in gross persistent neurological impairment (Le Beau, 1954). However, detailed analysis of performance reveals specific deficits of attention (Janer and Pardo, 1991). On the other hand, the major deficits described after spontaneous bilateral cingulate injury are inconclusive because the lesions were not confined to anterior cingulate gyri (Barris and Schuman, 1953; Faris, 1969; Freemon, 1971; Buge *et al.*, 1975).

Some informative results related to the function of the anterior cingulate gyrus arose from its electrical stimulation in conscious man (Talairach *et al.*, 1973; Bancaud *et al.*, 1976; Halgren, 1982) which produced complex motor responses involving the face or the hands in association with attention and mood modifications. When these responses appeared, no spreading of the after-discharge to other structures was noticed. It seems therefore that elaborated motor activity, mood and arousal changes represent specific effects of anterior cingulate gyrus activation.

Recent PET studies have established a relationship between the anterior cingulate gyrus and the attention required for generating action as opposed to attention to relevant sensory stimuli (Posner *et al.*, 1988; Pardo *et al.*, 1991): selecting language (or other forms of information) for action, requiring the inhibition of the habitual response and the selection of the task-oriented response resulted in an increase of blood flow in areas of the medial frontal lobe (Posner *et al.*, 1988; Petersen *et al.*, 1989; Pardo *et al.*, 1990).

Anatomically, the anterior cingulate gyrus is interconnected with the frontal (prefrontal, orbital, premotor) cortex (Selemon and Goldman-Rakic, 1985), the supplementary motor area structure (Goldberg, 1985) and with the thalamus (mainly intralaminar and medio-dorsal nucleus), mesencephalic reticular formation and amygdala. Powerful reciprocal projections link the anterior cingulate gyrus to area 7 (Baleydier and Mauguière, 1980), which is known to be involved in the detection and spatial localization of behaviourally relevant visual stimuli, and to drive movements directed towards them (Lynch, 1980); it furnishes the only sensory input to the anterior cingulate gyrus. The efferent subcortical projections of the anterior cingulate gyrus run to the striatum where they are intimately mingled with other associative cortex projections (Percheron *et al.*, 1984).

From these different data, the anterior cingulate gyrus can be considered the efferent limb of a network of neocortical (frontal and parietal association areas), limbic and reticular interconnections, on which converge influences from cognitive, emotional and arousal systems. Thus it can reasonably be postulated that the specific function of the anterior cingulate gyrus may be triggering appropriate, sustained goal-oriented responses to discriminated stimuli. When the anterior cingulate gyri (or the anterior cingulate gyrus on one side and the head of the caudate nucleus on the other side as in our patient) are damaged, their efferent areas may be disconnected from the cortical and limbic influences necessary for producing selective responses which no longer occur.

REFERENCES

- ALEXANDER MP, FREEDMAN M (1984) Amnesia after anterior communicating artery aneurysm rupture. *Neurology, Cleveland*, **34**, 752–757.
- ARIKUNI T, KUBOTA K (1986) The organization of prefrontocaudate projections and their laminar origin in the macaque monkey: a retrograde study using HRP-gel. *Journal of Comparative Neurology*, **244**, 492–510.
- BALEYDIER C, MAUGUIÈRE F (1980) The duality of the cingulate gyrus in monkey: neuroanatomical study and functional hypothesis. *Brain*, **103**, 525–554.
- BANCAUD J, TALAIRACH J, GEIER S, BONIS A, TROTTIER S, MANRIQUE M (1976) Manifestations comportementales induites par la stimulation électrique du gyrus cingulaire antérieur chez l'homme. *Revue Neurologique*, **132**, 705–724.
- BARRIS RW, SCHUMAN HR (1953) Bilateral anterior cingulate gyrus lesions: syndrome of the anterior cingulate gyri. *Neurology, Minneapolis*, **3**, 44–52.
- BUGE A, ESCOUROLLE R, RANCUREL G, POISSON M (1975) 'Mutisme akinétique' et ramollissement bicingulaire. 3 observations anatomo-cliniques. *Revue Neurologique*, **131**, 121–137.
- CAPLAN LR, SCHMAHMANN JD, KASE CS, FELDMANN E, BAQUIS G, GREENBERG JP *et al.* (1990) Caudate infarcts. *Archives of Neurology, Chicago*, **47**, 133–143.
- CASTAIGNE P, BUGE A, CAMBIER J, ESCOUROLLE R, BRUNET P, DEGOS JD (1966) Démence thalamique d'origine vasculaire par ramollissement bilatéral, limité au territoire du pédicule rétro-mamillaire. *Revue Neurologique*, **114**, 89–107.
- FARIS AA (1969) Limbic system infarction. A report of two cases. *Neurology, Minneapolis*, **19**, 91–96.
- FREEMAN FR (1971) Akinetic mutism and bilateral anterior cerebral artery occlusion. *Journal of Neurology, Neurosurgery, and Psychiatry*, **34**, 693–698.
- GOLDBERG G (1985) Supplementary motor area structure and function: review and hypotheses. *Behavioral and Brain Sciences*, **8**, 567–615.
- HALGREN E (1982) Mental phenomena induced by stimulation in the limbic system. *Human Neurobiology*, **1**, 251–260.
- JANER KW, PARDO JV (1991) Deficits in selective attention following bilateral anterior cingulotomy. *Journal of Cognitive Neuroscience*, **3**, 231–241.
- LAPLANE D, DEGOS J-D, BAULAC M, GRAY F (1981) Bilateral infarction of the anterior cingulate gyri and of the fornices. Report of a case. *Journal of the Neurological Sciences*, **51**, 289–300.
- LE BEAU J (1954) Anterior cingulectomy in man. *Journal of Neurosurgery*, **11**, 268–276.
- LHERMITTE F (1983) 'Utilization behaviour' and its relation to lesions of the frontal lobes. *Brain*, **106**, 237–255.
- LYNCH JC (1980) The functional organization of posterior parietal association cortex. *Behavioral and Brain Sciences*, **3**, 485–534.
- MENDEZ MF, ADAMS NL, LEWANDOWSKI KS (1989) Neurobehavioral changes associated with caudate lesions. *Neurology, Cleveland*, **39**, 349–354.
- MESULAM MM (1990) Large-scale neurocognitive networks and distributed processing for attention, language, and memory. *Annals of Neurology*, **28**, 597–613.
- OKAWA M, MAEDA S, NUKUI H, KAWAFUCHI J (1980) Psychiatric symptoms in ruptured anterior communicating aneurysms: social prognosis. *Acta Psychiatrica Scandinavica*, **61**, 306–312.
- PARDO JV, PARDO PJ, JANER KW, RAICHEL ME (1990) The anterior cingulate cortex mediates processing selection in the Stroop attentional conflict paradigm. *Proceedings of the National Academy of Sciences of the USA*, **87**, 256–259.
- PARDO JV, FOX PT, RAICHEL ME (1991) Localization of a human system for sustained attention by positron emission tomography. *Nature, London*, **349**, 61–64.
- PEDRAZZI P, BOGOUSLAVSKY J, REGLI F (1990) Hématomes limités à la tête du noyau caudé. *Revue Neurologique*, **146**, 726–738.
- PERCHERON G, YELNIK J, FRANÇOIS C (1984) A Golgi analysis of the primate globus pallidus. III. Spatial organization of the striato-pallidal complex. *Journal of Comparative Neurology, Chicago*, **227**, 214–227.
- PETERSEN SE, FOX PT, POSNER MI, MINTUN M, RAICHEL ME (1989) Positron emission tomographic studies of the processing of single words. *Journal of Cognitive Neuroscience*, **1**, 153–170.
- POSNER MI, PETERSEN SE, FOX PT, RAICHEL ME (1988) Localization of cognitive operations in the human brain. *Science*, **240**, 1627–1631.

- RICHFIELD EK, TWYMAN R, BERENT S (1987) Neurological syndrome following bilateral damage to the head of the caudate nuclei. *Annals of Neurology*, **22**, 768–771.
- ROYCE GJ (1982) Laminar origin of cortical neurons which project upon the caudate nucleus: a horseradish peroxidase investigation in the cat. *The Journal of Comparative Neurology*, **205**, 8–29.
- SANDSON TA, DAFFNER KR, CARVALHO PA, MESULAM MM (1991) Frontal lobe dysfunction following infarction of the left-sided medial thalamus. *Archives of Neurology, Chicago*, **48**, 1300–1303.
- SELEMON LD, GOLDMAN-RAKIC PS (1985) Longitudinal topography and interdigitation of corticostriatal projections in the rhesus monkey. *Journal of Neuroscience*, **5**, 776–794.
- SHALLICE T, BURGESS PW, SCHON F, BAXTER DM (1989) The origins of utilization behaviour. *Brain*, **112**, 1587–1598.
- TALAIRACH J, BANCAUD J, GEIER S, BORDAS-FERRER M, BONIS A, SZIKLA *et al.* (1973) The cingulate gyrus and human behaviour. *Electroencephalography and Clinical Neurophysiology*, **34**, 45–52.
- TRILLET M, CROISILE B, TOURNIAIRE D, SCHOTT B (1990) Perturbations de l'activité motrice volontaire et lésions des noyaux caudés. *Revue Neurologique*, **146**, 338–344.

Received March 15, 1993. Revised June 4, 1993. Accepted July 2, 1993