

Posterior Ischemia During an Attack of Transient Global Amnesia

Ker-Neng Lin, MS; Ren-Shyan Liu, MD; Tzu-Pei Yeh, MD;
Shuu-Jiun Wang, MD; Hsiu-Chih Liu, MD

Background: The popular concept that cerebral ischemia causes transient global amnesia has been difficult to prove by cerebral blood flow studies during attacks because the transient global amnesia attacks are so short.

Case Description: We performed single-photon emission computed tomography (SPECT) of the brain and neuropsychological assessment in a 37-year-old woman during a 10-hour attack and twice thereafter. A neuropsychological evaluation 3 hours after the onset of transient global amnesia revealed severe impairment of recent memory and verbal fluency, both of which returned to normal 2 and 28 days later, respectively. A ^{99m}Tc -labeled hexamethylpropyleneamine oxime SPECT of the brain performed 6 hours after the onset showed multiple perfusion defects in both occipital lobes, the medial left temporal lobe, and the left thalamus. A second brain SPECT performed 3 days later showed perfusion defects in only the occipital regions. A third brain SPECT performed 28 days later was normal. The patient's brain computed tomographic scan, electroencephalogram, duplex ultrasound of the carotid artery, and echocardiogram were normal.

Conclusions: The perfusion defects revealed by the brain SPECT during the transient global amnesia attack indicated ischemia in the territory of the posterior cerebral arteries, which partially resolved in 3 days and completely resolved by 28 days. (*Stroke* 1993;24:1093-1095)

KEY WORDS • amnesia • neuropsychological tests • tomography, emission computed

Transient global amnesia (TGA) is a well-known clinical syndrome that consisting of transient impairment of recent memory and lasts less than 24 hours.¹ Because most cases of TGA last only 8 to 10 hours, by the time the patients are seen by their physicians they usually have recovered from the attack. This makes it impossible to conduct a thorough work-up during the episode. There have been only a few reports of neuropsychological evaluation during the attack.²⁻⁶ Although the etiology of TGA remains unknown, ischemia in the territory of posterior cerebral artery involving structures such as the thalamus and medial temporal lobe has been a popular theory.⁷⁻⁹ This hypothesis is based mostly on the fact that the nature of anterograde amnesia in TGA is similar to that of permanent amnesia seen in bilateral thalamic or medial temporal lobe lesions. There is no confirming evidence from neuroimaging studies because most computed tomography (CT) scans of patients with TGA are normal. Recently, brain single-photon emission computed tomography (SPECT) has been used to measure the regional cerebral blood flow during attacks of TGA in three patients.⁷⁻⁹ We performed brain SPECT and neuropsychological assessment in a patient during an attack of TGA

and twice thereafter; ours is the fourth report of SPECT findings during such an attack.

Case Report

A 37-year-old right-handed woman, living alone and previously healthy, awoke on the morning of July 8, 1992, in a state of confusion. She usually went to a colleague's house for a ride to work, but on this morning she called the colleague and told him that she did not know how to get to his house. When her colleague hurried to the patient's house, she did not remember making the phone call. She could not remember what had happened during the past 2 days. She was sent to our emergency room, where she appeared anxious and upset and repeatedly asked, "Why am I here?"

Neuropsychological assessments were performed on the patient at 3 hours, 2 days, and 28 days after the attack. During the first evaluation, the patient looked perplexed and complained of a headache. She repeatedly asked, "Why am I here?" and could not remember what had occurred that morning. She was cooperative and followed instructions. The neuropsychological assessment included the Mini-Mental State Examination,¹⁰ modified Boston Naming Test, Wechsler Adult Intelligence Scale-Revised Digit Span Subtest and Modified Comprehension Subtest, Porteus Maze-like Maze Test, Delayed Picture Recognition Span Test, paired word learning test, remote memory test, word and sentence reading test, number reading and writing test, simple calculation test, pattern-matching test, simple figure coping test, and Verbal Fluency test. The

Received February 5, 1993; accepted March 8, 1993.

From the Neurological Institute (K.-N.L., T.-P.Y., S.-J.W., H.-C.L.) and the Department of Nuclear Medicine (R.-S.L.), Veterans General Hospital-Taipei and National Yang-Ming Medical College, Taipei, Taiwan, Republic of China.

Correspondence to The Neurological Institute, Veterans General Hospital-Taipei, Taipei, Taiwan, ROC (Dr Liu).

Results of the Neuropsychological Assessment

Cognitive domain (maximal score)	3 Hours	2 Days	28 Days
Mini-Mental State Examination (30)	23	30	30
Time orientation (5)	3	5	5
Place orientation (5)	3	5	5
Digit span (14)	11	13	14
Word span (5)	5	5	5
Recent memory (16)	4	16	16
Remote memory (41)	41	41	41
Naming (12)	12	12	12
Language comprehension (10)	10	10	10
Calculation (10)	9	10	10
Pattern matching (5)	3	5	5
Figure copying (7)	7	7	7
Abstract thinking (10)	9	10	10
Verbal fluency (animal)	7	13	13

results of the three assessments are summarized in Table 1.

The first neuropsychological assessment revealed that the patient was disoriented as to month, date, and place and was severely impaired in recent memory and verbal fluency. Her remote memory and immediate recall were normal, and her neurological examination was otherwise normal. ^{99m}Tc -labeled hexamethylpropyleneamine oxime (HMPAO) SPECT¹¹ (Figure, panel A) performed 6 hours after the attack showed multiple perfusion defects in the bilateral occipital lobes, medial left temporal lobe, and left thalamus. The patient's recent memory gradually returned to

normal by 10 hours after the attack. Retesting of her neuropsychological abilities 2 and 28 days later showed complete recovery of recent memory and other cognitive functions. Repeat ^{99m}Tc -HMPAO SPECT performed 3 days after the attack (panel B) showed perfusion defects only in the occipital regions, and the third brain SPECT 28 days later (panel C) showed no perfusion defects. The patient's CT scan, electroencephalogram, 24-hour cardiac Holter electrocardiogram, and two-dimensional echocardiogram were normal. A duplex ultrasound study of the carotid artery revealed small plaques in both common carotid arteries.

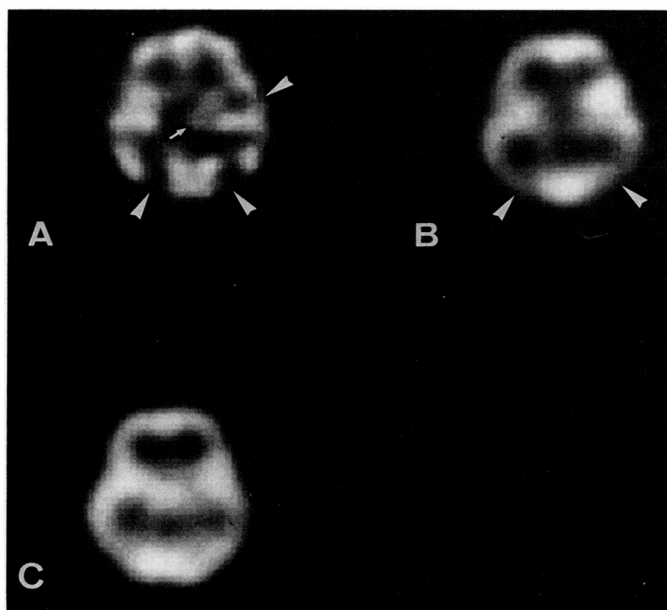
Discussion

Although the etiology of TGA remains uncertain, the most accepted concept is that it results from ischemia in the medial temporal lobe or thalamus. This hypothesis is supported by the neuropsychological dysfunctions²⁻⁶ as well as the results of SPECT studies⁷⁻⁹ during an attack of TGA. Our report further confirms this theory. The neuropsychological evaluation of our patient revealed anterograde amnesia and severe impairment of recent memory. SPECT revealed bilateral occipital hypoperfusion in addition to decreased perfusion in the left thalamus and medial left temporal lobe, which indicated ischemia in the territory of the posterior cerebral arteries. It was performed 6 hours after the onset of the attack, at a time when she was gradually recovering from the TGA attack. A second SPECT 3 days later indicated reduction of the area of perfusion defect. We suspect that if the first SPECT had been performed earlier in the attack, it might have shown more extensive perfusion defects, including those in the right thalamus and right temporal lobe. Stillhard et al⁷ report a case of TGA with evidence of bitemporal hypoperfusion on SPECT performed 7 hours after the ictus. Goldenberg et al⁹ describe a patient with perfusion defects in both thalami demonstrated by SPECT performed several hours after the onset. Tanabe et al⁸ describe a patient with hypoperfusion in the territory of the posterior cerebral artery with preserved blood flow in other areas, including the frontal cortex and thalamus; SPECT was performed 6 hours after the onset. In these three studies and in our case, patchy areas of decreased perfusion were revealed in the territory of posterior cerebral artery, a phenomenon that can be explained by the different timing of the SPECT.

Although all the studies indicate ischemia in the territory of the posterior cerebral artery, the etiology of posterior ischemia remains unknown. Our patient, young and previously healthy, did not have a history of migraine or any risk factors for cerebrovascular disease. Results of the echocardiogram and duplex ultrasound of the carotid arteries were normal. Vasospasm of the posterior cerebral artery is one possible mechanism; however, a cerebral angiogram obtained during an attack would be needed to resolve this issue.

Acknowledgment

The study was supported in part by a grant from the National Science Council (NSC 81-0420-B-075-557-Y).



A, ^{99m}Tc -labeled hexamethylpropyleneamine oxime single-photon emission computed tomography (HMPAO SPECT) of the patient performed 6 hours after onset of transient global amnesia showed multiple perfusion defects in bilateral occipital lobes, left medial temporal lobe, and left thalamus. Second brain SPECT (B) performed 3 days later showed perfusion defect only in bilateral occipital lobes. Third brain SPECT (C) performed 28 days later was normal.

References

1. Caplan LR. Transient global amnesia. In: Fredericks JAM, ed. *Handbook of Clinical Neurology, Volume 1*. Amsterdam, The Netherlands: Elsevier Science Publishing Co Inc, 1985;45:205-218.
2. Caffarra P, Moretti G, Mazzucchi A, Parma M. Neuropsychological testing during a transient global amnesia episode and its follow-up. *Acta Neurol Scand*. 1981;63:44-50.
3. Gallassi R, Lorusso S, Stracciari A. Neuropsychological findings during a transient global amnesia attack and its follow-up. *Ital J Neurol Sci*. 1986;7:45-49.
4. Regard M, Landis T. Transient global amnesia: neuropsychological dysfunction during attack and recovery of two 'pure' cases. *J Neurol Neurosurg Psychiatry*. 1984;47:668-672.
5. Wilson RS, Koller W, Kelly MP. The amnesia of transient global amnesia. *J Clin Neuropsychol*. 1980;2:259-266.
6. Hodges JR, Ward CD. Observations during transient global amnesia: a behavioural and neuropsychological study of five cases. *Brain*. 1989;112:595-620.
7. Stillhard G, Landis T, Schiess R, Regard M, Sialer G. Bitemporal hypoperfusion in transient global amnesia: 99m-Tc-HM-PAO SPECT and neuropsychological findings during and after an attack. *J Neurol Neurosurg Psychiatry*. 1990;53:339-342.
8. Tanabe H, Hashikawa K, Nakagawa Y, Ikeda M, Yamamoto H, Harada K, Tsumoto T, Nishimura T, Shiraishi J, Kimura K. Memory loss due to transient hypoperfusion in the medial temporal lobes including hippocampus. *Acta Neurol Scand*. 1991;84:22-27.
9. Goldenberg G, Podreka I, Pfaffelmeyer N, Wessely P, Deecke L. Thalamic ischemia in transient global amnesia: a SPECT study. *Neurology*. 1991;41:1748-1752.
10. Folstein MF, Folstein SE, McHugh PR. Mini-Mental State: a practical method for grading the cognitive state of patients for the clinician. *J Psychiatr Res*. 1975;12:189-198.
11. Ell PJ, Jarritt PH, Costa DC, Cullum ID, Lui D. Functional imaging of the brain. *Semin Nucl Med*. 1987;17:214-229.

Posterior ischemia during an attack of transient global amnesia.

K N Lin, R S Liu, T P Yeh, S J Wang and H C Liu

Stroke. 1993;24:1093-1095

doi: 10.1161/01.STR.24.7.1093

Stroke is published by the American Heart Association, 7272 Greenville Avenue, Dallas, TX 75231

Copyright © 1993 American Heart Association, Inc. All rights reserved.

Print ISSN: 0039-2499. Online ISSN: 1524-4628

The online version of this article, along with updated information and services, is located on the
World Wide Web at:

<http://stroke.ahajournals.org/content/24/7/1093>

Permissions: Requests for permissions to reproduce figures, tables, or portions of articles originally published in *Stroke* can be obtained via RightsLink, a service of the Copyright Clearance Center, not the Editorial Office. Once the online version of the published article for which permission is being requested is located, click Request Permissions in the middle column of the Web page under Services. Further information about this process is available in the [Permissions and Rights Question and Answer](#) document.

Reprints: Information about reprints can be found online at:
<http://www.lww.com/reprints>

Subscriptions: Information about subscribing to *Stroke* is online at:
<http://stroke.ahajournals.org/subscriptions/>