

A thrombosed saccular posterior cerebral artery aneurysm in an infant

H. CHEUNG AND F.C. LEE

Subang Jaya Medical Centre, Selangor, Malaysia

ABSTRACT

A case of recurrent hemiplegia due to saccular aneurysm of the left posterior cerebral artery in a female infant is described. The diagnosis was made at angiography, prompted by CT detection of a hyperdense, intra-aneurysmal thrombus, and was confirmed at subsequent surgery.

CASE HISTORY

A 12 month old Chinese baby girl was brought to the Pediatric Clinic at the Subang Jaya Medical Centre in May 1989 with a history of 3 episodes of right-sided hemiplegia in the preceding 4 months. Each episode lasted from 15 minutes to an hour, and was sudden in onset, with the child unable to move the right limbs. There was no history of fever, ear discharge, seizure or loss of consciousness. Her developmental milestones were normal.

On physical examination she was able to move all four limbs normally. There was no focal neurological defect, and plantar reflexes were normal. Reflexes were normal and equal, and there was no sensory deficit. The fundi were also normal. Apart from mild anaemia, with a haemoglobin of 10.2 g/dl (Normal = 13 – 18), the haematological and metabolic profiles were unremarkable.

The child was initially managed as a case of epilepsy. The EEG, however, did not show any epileptic focus. Cranial CT, without contrast, showed the presence of a small, solitary, focal hyperdensity in the region of the left

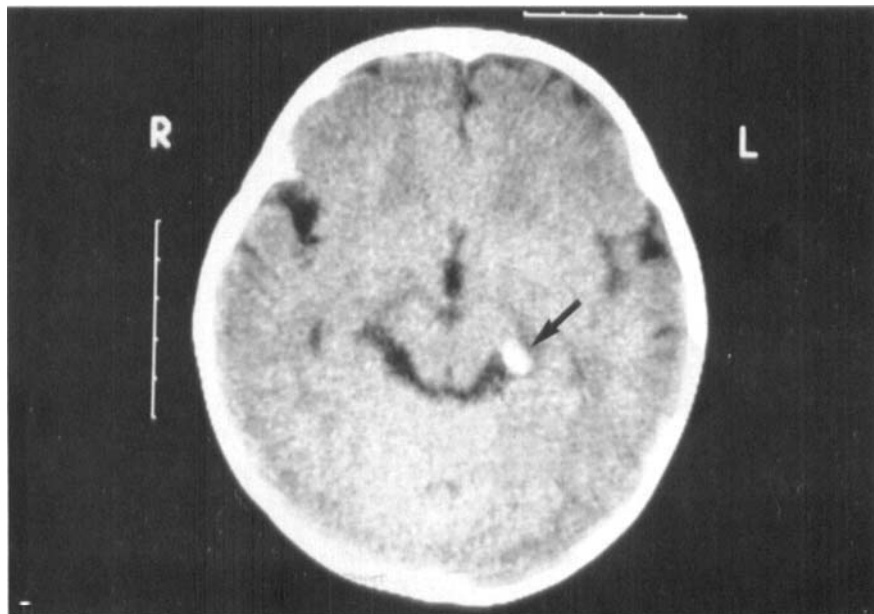


FIGURE 1 – Axial non-contrast CT showing a focal hyperdensity in the region of the Left Ambient Cistern with attenuation value of 50 HU (arrow), at the site of the aneurysm.

ambient cistern (Figure 1). This measured 10 by 8 mm and was interpreted as a focus of calcification, either within a granuloma or a vessel. A cerebral angiogram was performed in view of the CT finding and clinical suspicion of a vascular aetiology. Selective left carotid and vertebral studies were done under general anaesthesia, and the latter showed the presence of a solitary left posterior cerebral artery (PCA) aneurysm, arising distal to the origin of the posterior choroidal artery. There was also reduced filling of the left PCA compared to the right side, which may have been due to the spasm (Figures 2A and B).

The parents were advised regarding the inherent risk of aneurysmal rupture and agreed to surgery. At surgery, a left temporo-occipital craniotomy was performed and a cruciate dural incision made. Under magnification from a Carl Zeiss OPMI 6 operating microscope, the left temporal lobe was elevated to expose the left PCA. A small saccular aneurysm was found arising from a branch of the PCA projecting infero-medially into the ambient cistern. This was completely obliterated at its neck by a curved Yasargil

Phynox 6 mm aneurysm clip, and the sac excised.

On gross appearance the aneurysm was a 1.2 cms spheroidal, berry-like sac, with a smooth outer surface. Section showed an intra-aneurysmal thrombus with areas of early organisation. There was haemorrhage into its wall, which was composed mainly of fibrous tissue. Elastic tissue and smooth muscle could not be identified on light microscopy, and there was no evidence of malignancy.

Post-operatively the child made an uneventful recovery. Up to the time of writing, clinical follow-up revealed no recurrence of the right limb weakness. Repeat angiography, performed 2 years later in June 1991, confirmed total obliteration of the aneurysm neck and normal left PCA circulation (Figures 3A and B).

Address for correspondence:

H. Cheung
Department of Diagnostic Radiology & Organ
Imaging
Chinese University of Hong Kong
Prince of Wales Hospital
New Territories
Hong Kong
Telephone: 636 2268
Fax: 636 0012

Submitted for publication on: 26th November, 1991

Accepted for publication on: 4th June, 1992

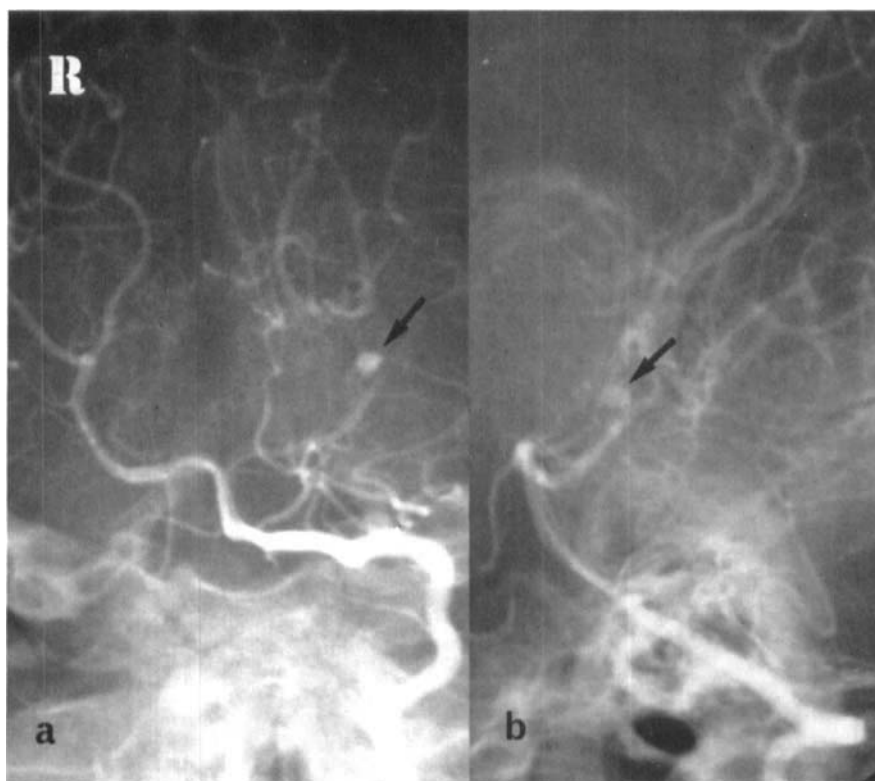


FIGURE 2 – Left vertebral angiogram showing the saccular aneurysm (arrows) in the frontal (a) and lateral (b) projection. There is reduced flow seen in the left PCA compared to the right side.

DISCUSSION

Approximately 2% of all intracranial aneurysms occur in childhood (1), and less than one hundred cases of arterial aneurysms have been reported in children, younger than 5 years (2, 3). In children, these saccular aneurysms appear distinct from those in adults, on the basis of sex predominance, size, location, aetiology and surgical outcome.

There is a male predominance of 70% (1, 4). Approximately 25 – 45% are giant aneurysms measuring more than 2.5 cms in size (1, 3, 5). A more peripheral site is common (2, 3, 6), which makes them relatively more accessible at surgery. There is a higher incidence in the anterior circulation (4, 6). PCA saccular aneurysms in children less than 5 years are extremely uncommon, being found in only 2 out of 32 patients in one review (2).

In children, the pathogenesis of intracranial aneurysms includes trauma and infection (6, 7). A congenital aetiology is suspected in those occurring in early childhood (2), or found in association with other cerebral and vascular congenital malformations (3). The unproven hypothesis is that they result from enlargement of retained 'nubbins' of foetal cerebral circulation (2).

The clinical presentation is most commonly related to subarachnoid bleeding, which is seen in 65 – 80% cases (4, 5). However a non-haemorrhagic presentation occurs in about

18%, compared to 2.5% in adults (3). This includes mass effect, and neural compression syndromes which are commonly seen with giant aneurysms in the posterior circulation (5). The mode of presentation in our patient was both peculiar and interesting. We could not find recurrent episodic hemiplegia described previously with childhood aneurysms. However, this history alerted us to the possibility of a vascular pathology. The recurrent motor deficit may be related to intermittent vascular insufficiency, perhaps due to spasm or microembolism.

Diagnoses have mostly been confirmed by angiography or surgery. CT detects bleeding in the presence of rupture, and may also show the aneurysm, especially if large (8). The presence of aneurysmal wall calcification and intra-aneurysmal thrombus will also facilitate CT detection (1, 5). In our patient the aneurysm was shown as a focal hyperdensity in the region of the left ambient cistern on non-contrast CT. This may have been due to either the thrombus in its lumen, or the haemorrhage within its wall, both of which were present on histological examination of the excised aneurysm sac.

Surgical results are generally better than in adults and this was the case in this patient. Good recovery is reported in 63 – 87% (1, 3, 4, 6, 9). An operative

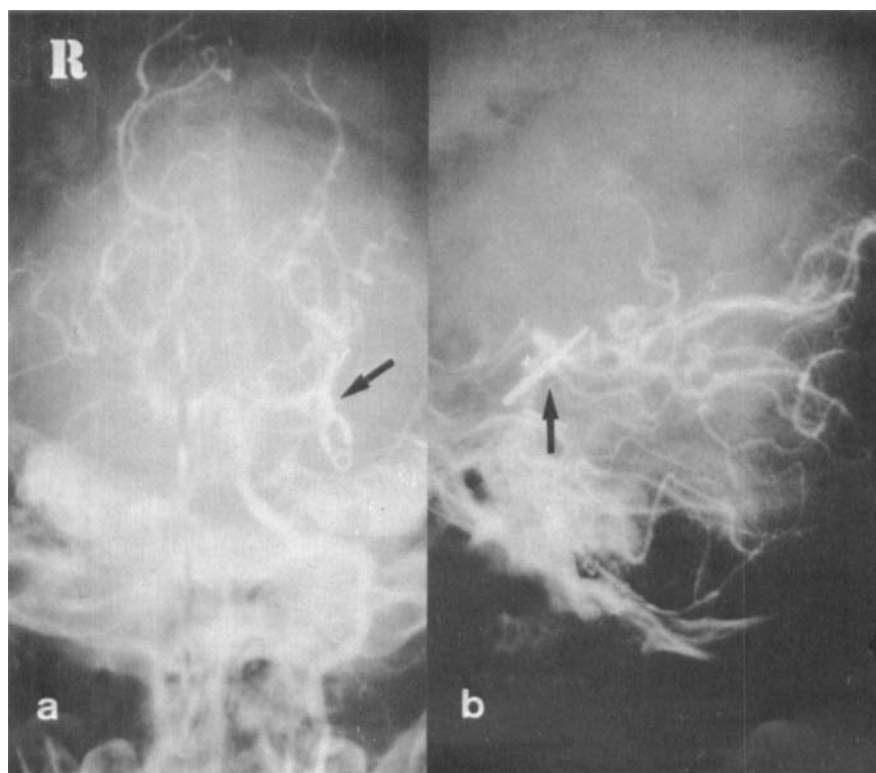


FIGURE 3 – A follow-up left vertebral angiogram performed 2 years after surgery showing normal Left PCA circulation in frontal (a) and lateral (b) projections. The aneurysm clip is arrowed.

mortality rate of 5% is attainable (5, 6). This is thought to be due to cerebral plasticity and a low incidence and greater tolerance of spasm (4), with perhaps better adaptation to ischaemia. Prognosis, however, is considerably worsened by the presence of massive intracerebral haematoma, when there is a high risk of mortality (9).

REFERENCES

1. Meyer FB, Sundt TM Jr, Fode NC, Morgan MK, Forbes GS, Mellinger JF. Cerebral aneurysms in childhood and adolescence. *Journal of Neurosurgery*, 1989; 70 (3): 420-425.
2. Becker DH, Silverberg GD, Nelson DH, Hanberg JW. Saccular aneurysm of infancy and early childhood. *Neurosurgery* 1978; 2 (1): 1-7.
3. Ferrante L, Fortuna A, Celli P, Santoro A, Fraioli B. Intracranial arterial aneurysms in early childhood. *Surgical Neurology* 1988; 29 (1): 39-56.
4. Roche JL, Choux M, Czorny A, Dhellemes P, Fast M, Frerebeau P *et al.* Intracranial arterial aneurysm in children. A cooperative study. Apropos of 43 cases. *Neurochirurgie*, 1988; 34 (4): 243-251.
5. Amacher AL, Drake CG, Ferguson CG. Posterior circulation aneurysms in young people. *Neurosurgery* 1981; 8: 315-320.
6. Pasqualin A, Mazza C, Cavazzani P, Scienza R, DaPian R. Intracranial aneurysms and subarachnoid haemorrhage in children and adolescents. *Childs Nervous System* 1986; 2 (4): 185-190.
7. Buckingham MJ, Crone KR, Ball WS, Tomsick TA, Berger TS, Tew JM Jr. Traumatic intracranial aneurysms in childhood. *Neurosurgery* 1988; 22 (2): 398-408.
8. TerBrugge K, Lee SH, Rao KCGV. Cerebral vascular anomalies. In *Cranial Computed Tomography*, eds Lee SH, Rao KCGV, 1983; 549-550. McGraw-Hill.