

Neurosurgery 1992-98

June 1993, Volume 32, Number 6

1028 Huge Multilobular Cavernous Angioma in an Infant: Case Report Case Report

AUTHOR(S): Kawagishi, Jun, M.D.;
Suzuki, Michiyasu, M.D.; Kayama, Takamasa, M.D.;
Yoshimoto, Takashi, M.D.

Division of Neurosurgery, Institute of Brain Diseases,
Tohoku University School of Medicine, Sendai,
Japan

Neurosurgery 32; 1028-1031, 1993

ABSTRACT: THE AUTHORS ENCOUNTERED a rare case of multilobular cavernous angioma arising from the paraventricular region in an infant. Total resection of the angioma, which was 8 cm in diameter, was performed. The patient showed no neurological deficit. Although 22 cases in infants have previously been reported, this is the largest cavernous angioma and it is especially rare because of its multilobular configuration.

KEY WORDS: Cavernous angioma; Infant;
Magnetic resonance imaging; Multilobular; X-ray computed tomography

Acavernous angioma in either an infant or an adult is a rare vascular anomaly. Takaku et al.⁽²¹⁾ reported 2 cases out of 103 brain tumors in infants and Jooma et al.⁽⁹⁾ found 1 in 100 cases. The authors encountered a rare case with a multilobular configuration and a diameter of 8 cm. The patient showed no neurological deficit, despite total resection of this huge angioma. Although 22 cases of cavernous angioma have previously been reported^(1-5,7-9,11-20,23,24), its pathophysiology is still unclear. The clinical pathology, neuroradiological features, and treatment of this case and 22 other known cases are discussed.

CASE REPORT

The patient was an infant boy, 11 months old, with an unremarkable family history. There were no abnormalities during pregnancy or delivery. At the time of delivery, his head showed a normal measurement of 33 cm. Several days before admission, he developed hemiparesis on the left side.

Examination

At the time of admission, his head measured 49 cm, which was still within the normal range. Neurologically, he was stuporous, and there was hemiparesis on the left side and conjugate deviation of the eyeballs to the right side. A plain radiograph of the head showed enlargement of the fontanel and diastasis of the sutures. X-ray computed tomography (X-CT) revealed a huge multilobular mass with a high-density rim in the right hemisphere. The mass was surrounded by a broad low-density area. An enhancement effect was observed in the rim and septum (Fig. 1). A T1-weighted magnetic resonance

image disclosed a mass with a maximum diameter of 8 cm extending to the pineal region, trigon, subcortical white matter, and contralateral hemisphere from the right paraventricular region. The septum exhibited relatively low-signal intensity, whereas the inner part of the lobuli showed hyper- to isosignal intensity (Fig. 2). In a T2-weighted magnetic resonance image, a multiple hyperintense mass surrounded by no signal band, which would indicate the presence of hemosiderin, was observed. A Niveau formation was also seen (Fig. 3). Cerebral angiography disclosed no abnormal vessels, arteriovenous shunting, or pooling of the contrast media but did reveal a mass sign (Fig. 4). The character of that mass lesion could not be determined from the neuroradiological examination; however, an operation was chosen because of his progressive symptoms.

Operation

An osteoplastic craniotomy was performed in the right parietal region. The mass lesion was dissected from the surrounding brain tissue under an operative microscope through a small corticotomy of the postsensory cortex, with careful preservation of deep veins. Because of the presence of a demarcated capsule, dissection of the mass was not difficult and total resection was done. In the paraventricular region, the mass adhered to the brain tissue. The multilobular configuration, which consisted of fresh to old hemorrhages in the cystic portion and a yellow-to-brownish hard capsule, was disclosed in a surgical specimen. The operative diagnosis was a cavernous angioma with recurrent hemorrhage.

Postoperative course

X-CT on the second postoperative day showed a drastic reduction of brain edema. The patient's hemiparesis and conjugate deviation of the eyeballs also disappeared postoperatively. During the following 8 months, a T1-weighted magnetic resonance image revealed only the small cavity once occupied by the angioma and a relatively large subdural space (Fig. 5). The patient showed no neurological deficit at the time.

Pathological examination

There were blood vessels of varying sizes sealed by single-layer endothelial cells. Although proliferating connective tissue intervened between those blood vessels, no neural tissue was observed. Bleeding and thrombi, which were fresh or organized, were also frequently observed (Fig. 6). On the basis of this histological evidence, a diagnosis of cavernous angioma was made.

DISCUSSION

Clinicopathology

Including the case presented here, there have been 23 reported cases of cavernous angioma in infants. There has been a predominance of female infants among the 22 cases in which the sex has been mentioned (male, 10; female, 12). The initial symptoms included enlargement of the head in 10

cases (44%), epilepsy in 6 (26%), bleeding in 4 (17%), and other symptoms in 3 (13%). Recently, an epileptic attack in a patient with cavernous angioma has been considered as a sign of bleeding. However, in adult cases, a higher incidence of bleeding (50 to 70%) has been reported as an initial symptom^(6,10,24). A difference in the location of the cavernous angiomas between infants and adults has also been noted. The paraventricular region, however, was the most common site in infants (43%), whereas the frontal and temporal lobes were predominant in adult cases. In our case, it was evident that the angioma had arisen from the paraventricular region. The maximum diameter was described in 11 of 23 patients. In two patients, the diameter was less than 2 cm; in four patients, it was 2 to 4 cm; in two patients, it was 4 to 6 cm; in two patients, it was 6 to 8 cm; and in our patient, it was over 8 cm. A histological examination of our patient revealed the presence of fresh to old hemorrhage, organized thrombi, and a marked proliferation of connective tissue. In addition, there has been a report of bleeding facilitating the growth of cavernous angioma⁽²²⁾. These pathological findings were also reported by Scott et al.⁽¹⁷⁾, who analyzed 19 cases in children. With this in mind, we thought that cavernous angiomas in infants might bleed frequently and grow rapidly because of hemorrhage and the proliferation of connective tissue.

Neuroradiology

X-CT examination was performed in 16 cases. Fifteen cases (96%) showed a high-density area on plain X-CT, and 9 cases (56%) showed an enhanced effect with contrast media. However, the obvious multilobular configuration in X-CT found in our case has never been described in any previous reports. Cyst formation was also a rare pathological finding, and there were only four cases with such formation. Twelve patients underwent cerebral angiography, which disclosed an avascular mass (seven patients or 58%) and abnormal staining (two patients or 17%). Magnetic resonance imaging was performed in only one other patient besides ours, and it revealed multicystic formation.

Treatment and outcome

Total resection of the angioma was performed in 17 patients. Thirteen patients (76%) were free of symptoms, and in two other patients, the symptoms improved. There are several possible reasons for the excellent outcome of total resection: 1) A cavernous angioma is easy to dissect without brain damage because of its clear demarcation and few feeders and drainers; 2) developing brains have more plasticity. In infants, the natural history of cavernous angioma is still unclear and operative indications have not been clearly determined. Nevertheless, it should be stressed that total resection is recommended, regardless of the size or preoperative neurological deficit, if the patient is currently symptomatic, either because of a mass effect, hemorrhage or seizure, or evidence of having bled in the past. The outcome of total resection is excellent, and there are risks of

subsequent bleeding and rapid growth under conservative therapy.

Received, April 23, 1992.

Accepted, January 6, 1993.

Reprint requests: Michiyasu Suzuki, M.D., Division of Neurosurgery, Institute of Brain Diseases, Tohoku University School of Medicine, Seiryomachi 1-1, Aoba-ku, Sendai, Japan 980.

REFERENCES:⁽¹⁻²⁴⁾

1. Arnstein LH, Boldrey E, Naffziger HC: A case report and survey of brain tumors during the neonatal period. **J Neurosurg** 8:315-319, 1951.
2. Canevini P, Farneti A, Flauto V: Report of a case of cavernous hemangioma of the dura mater in a 2-day old newborn. **Folia Hered Pathol** 12:163-166, 1963.
3. Chaddock WM, Binet EF, Farrell FW, Araoz CA, Reding DL: Intraventricular cavernous hemangioma. Report of three cases and review of the literature. **Neurosurgery** 16:189-197, 1985.
4. Fortuna A, Ferrante L, Mastronardi L, Acqui M, d'Addetta R: Cerebral cavernous angioma in children. **Childs Nerv Syst** 5:201-297, 1989.
5. Gangemi M, Longatti P, Maiuri F, Cinalli G, Carteri A: Cerebral cavernous angioma in the first year of life. **Neurosurgery** 25:465-469, 1989.
6. Giombini S, Morrelo G: Cavernous angioma of the brain. Account of fourteen personal cases and review of the literature. **Acta Neurochir** 40:61-82, 1987.
7. Hayashi T, Fukui M, Shyojima K, Utsunomiya H, Kawasaki K: Giant cerebellar hemangioma in an infant. **Childs Nerv Syst** 1:230-233, 1985.
8. Iwasa H, Indei I, Sato F: Intraventricular cavernous hemangioma. Case report. **J Neurosurg** 59:153-157, 1983.
9. Jooma R, Hayward RD, Grant DN: Intracranial neoplasms during the first year of life. Analysis of one hundred consecutive cases. **Neurosurgery** 14:31-41, 1984.
10. Mazza C, Scienza R, Beltramello A, Da Pian R: Cerebral cavernous malformations (cavernomas) in the pediatric age group. **Childs Nerv Syst** 7:139-146, 1991.
11. McGuire TH, Greenwood J, Newton BL: Bilateral angioma of choroid plexus. **J Neurosurg** 11:428-430, 1954.
12. Miyagi K, Mukawa J, Takara E, Kinjo N: Multiple intraventricular cavernous angiomas in early infancy (in Japanese) **Nerv Syst Child** 12:279-282, 1987.
13. Moritake K, Handa H, Nozaki K, Tomiwa K: Tentorial cavernous angioma with calcification in a neonate. **Neurosurgery** 16:207-211, 1985.
14. Nakasu S, Yoshida M, Nakajima M, Handa J:

- Cystic cavernous angioma in an infant. CT features. **J Comput Assist Tomogr** 15:163-165, 1991.
15. Okada Y, Shima T, Matsumura S, Nishida M, Yamada T, Hatayama T: Cystic cavernous hemangioma in the frontal lobe in an infant. Case report [English abstr] **Neurol Med Chir (Tokyo)** 29:40-43, 1989.
 16. Prenskey AL, Gado M: Angiographic resolution of a neonatal intracranial cavernous hemangioma coincident with steroid therapy. Case report. **J Neurosurg** 39:99-103, 1973.
 17. Scott RM, Barnes P, Kupsy W, Adelman RS: Cavernous angiomas of the central nervous system in children. **J Neurosurg** 76:38-46, 1992.
 18. Simard JM, Bengochea FG, Ballinger WE, Mickel JP, Quisling RG: Cavernous angioma. A review of 126 collected and 12 new clinical cases. **Neurosurgery** 18:162-172, 1986.
 19. Sonntag VKH, Waggner JD, Kaplan AM: Surgical removal of a hemangioma of the pineal region in a 4-week-old infant. **Neurosurgery** 8:586-588, 1981.
 20. Sugiyama Y, Kajima T, Kamimura Y, Tanabe Y, Sakai N, Yamada H, Ando T: Intracranial cavernous hemangioma in the first decade of life. Report of two cases with review of the literature (in Japanese) **Nerv Syst Child** 6:107-116, 1981.
 21. Takaku A, Kodama N, Ohara H, Horl S: Brain tumor in newborn babies. **Childs Brain** 4:365-375, 1987.
 22. Voigt K, Yasargil MG: Cerebral cavernous haemangiomas or cavernomas. Incidence, pathology, localization, diagnosis, clinical features and treatment. Review of the literature and report of an unusual case. **Neurochirurgia** 19:59-68, 1976.
 23. Yamasaki T, Handa H, Yamashita J, Paine JT, Tashiro Y, Uno A, Ishikawa M, Asato R: Intracranial and orbital cavernous angiomas. A review of 30 cases. **J Neurosurg** 64:197-208, 1986.
 24. Yasargil MG: *Microneurosurgery* IIIB. New York, Georg Thieme Verlag, 1988, pp 405-438.

COMMENTS

Kawagishi and colleagues have presented a remarkable case of a very large cavernous angioma in an 11-month-old child with a hemiparesis. They stated that their operation was performed through a "small corticotomy," but they do not mention its size or exactly how the mass was managed. I assume that the mass was removed piecemeal, that much of it represented clot and granulation tissue, and that bleeding was very easily handled--as is the case in most of the malformations that reach this size. The authors show us a single postoperative scan, which looks remarkably good, and they state that the patient

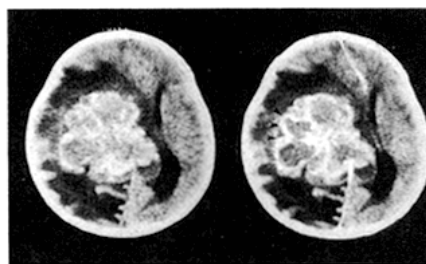


Figure 1. X-CT, axial plain. *Left*, plain. A huge multilobular tumor with a high-density rim surrounded by a broad low-density area was seen in the right hemisphere. *Right*, enhanced. An enhancement effect was also noted in the rim (*arrowheads*).

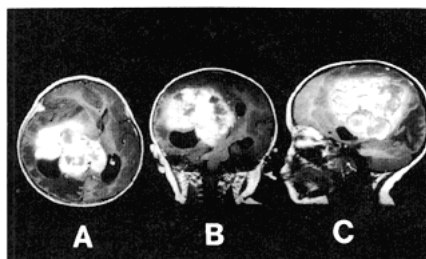


Figure 2. T1-weighted magnetic resonance image. *A*, gadolinium-enhanced axial view. *B*, gadolinium-enhanced coronal view. *C*, plain sagittal view. A multilobular tumor with mosaic intensity was observed, extending from the right paraventricular region to the trigon, pineal region, and subcortical white matter.

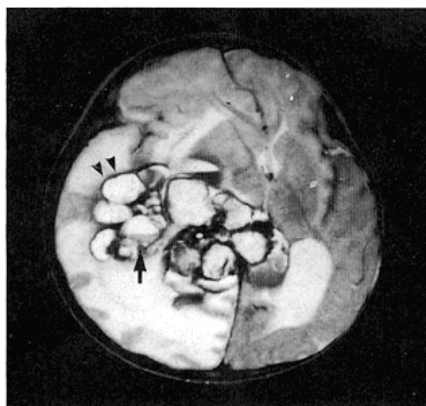


Figure 3. T2-weighted magnetic resonance image (axial view). No signal rim surrounded multiple hyperintense areas (*arrowheads*) in this T2-weighted image. Nodule was also noted inside (*arrow*).

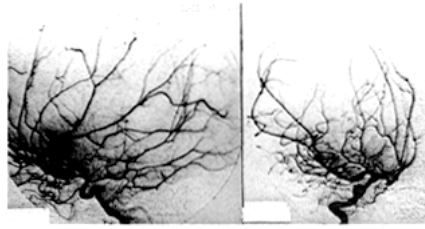


Figure 4. Right carotid angiogram. *Left*, lateral view; *Right*, anteroposterior view. An obvious mass sign was observed, but there were no abnormal vessels, pooling, or arteriovenous shunting.

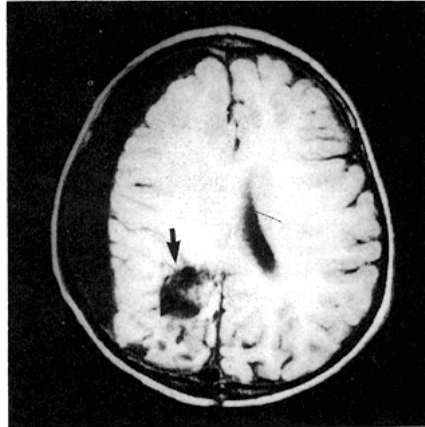


Figure 5. T1-weighted magnetic resonance image, 8 months after surgery. Only a small cavity (*arrow*) was seen.

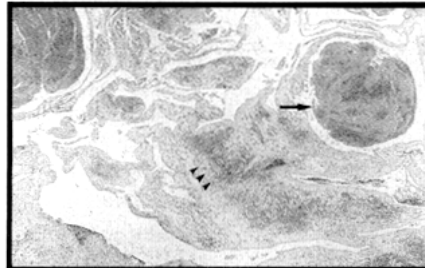


Figure 6. Photomicrograph of a surgical specimen (hematoxylin and eosin, $\times 20$). There were many dilated vessels with lumen of varying sizes. These were covered with a single-layered endothelium. Bleeding (*arrowheads*) and thrombosed vessels (*arrow*) were also noted. Proliferating connective tissue intervened between those vessels, but no neural tissue was observed.