

A.I. Canady
R.D. Fessler
M.D. Klein

Neurosurgery Children's Hospital,
Detroit, Mich., USA

Ultrasound Abnormalities in Term Infants on ECMO

Key Words

Ultrasound, head
Extracorporeal membrane
oxygenation
Extra-axial brain collections

Abstract

The charts and cranial ultrasounds of 29 infants treated with extracorporeal membrane oxygenation (ECMO) for respiratory insufficiency secondary to meconium aspiration syndrome, primary pulmonary hypertension, congenital diaphragmatic hernia and/or sepsis were examined to identify ultrasound abnormalities. Seventeen (58.6%) developed extra-axial fluid collections, only two of which were progressive. Ten (34.5%) developed evidence of intracranial hemorrhage (ICH); seven caudate, one each in the thalamus, parietal and occipital lobes. Eight (27.65%) of the neonates had seizures while on ECMO, 5 of whom had concurrent ICH.

Extracorporeal membrane oxygenation (ECMO) is increasingly used to improve oxygenation in neonates whose response to mechanical ventilation is unsatisfactory. It is most successful in those patients who have pulmonary hypertension as a major factor in their ventilatory failure. Initially, it was used in premature infants as well, but recently its use has been restricted to term or near-term infants. This study surveys the intracranial abnormalities demonstrated by ultrasonography that developed in this population.

Method

The charts and imaging studies for 29 neonates who were placed on ECMO at the Children's Hospital of Michigan from 1989 to 1991 were evaluated for the presence and nature of cranial ultrasound abnormalities. Twenty patients demonstrated abnormalities. The

infants were all full-term infants, average gestational age 39.5 weeks, with oxygenation difficulties secondary to meconium aspiration syndrome (10 patients), primary persistent pulmonary hypertension (7 patients), congenital diaphragmatic hernia (3 patients) and 1 patient with primary pulmonary hypertension and/or sepsis. The patients were on ECMO an average of 6.5 days. Ultrasounds were performed before the start of ECMO, daily during ECMO and as clinically indicated after ECMO decannulation. Infants with evidence of abnormality on pre-ECMO ultrasounds were excluded from the study. The cranial ultrasounds were performed using an Acuson (Mountain View, Calif.) with linear high frequency transducer 5 or 7 MHz.

Results

Twenty-nine charts and ultrasounds were reviewed. Nineteen (65%) developed an intracranial abnormality documented by cranial ultrasound during ECMO therapy. Seventeen (58.6%) developed extra-axial fluid collec-

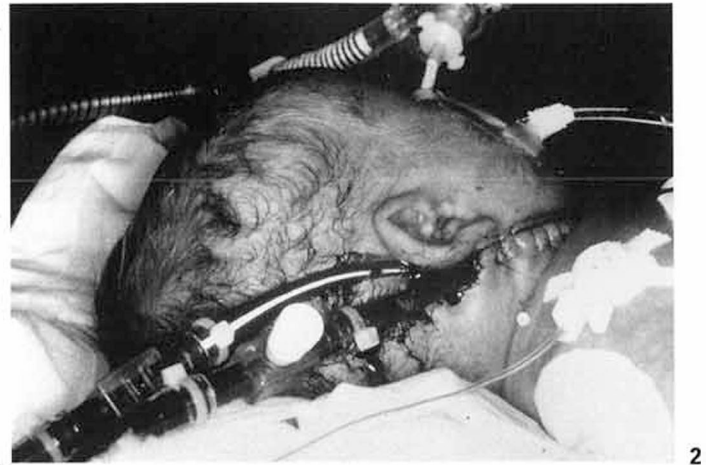
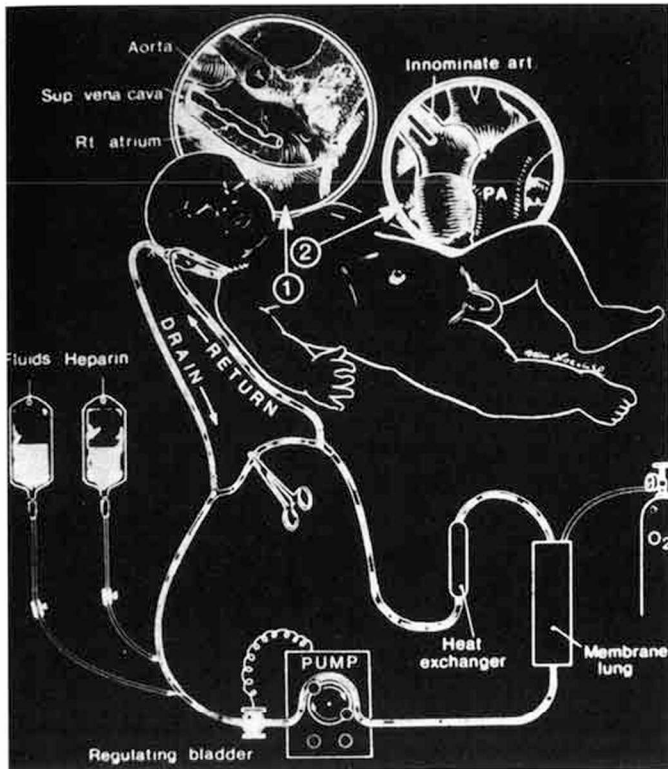


Fig. 1. Line drawing of ECMO circuit.

Fig. 2. Illustration of lines in place also showing significant scalp edema.

tions, two (6.9%) of which were progressive with enlarging head circumference and split sutures requiring surgical intervention. Fluid retention was a problem in ECMO patients with the intake exceeding the output in these patients by an average of 220 ml/day with the average central venous pressure being 16.7 mm Hg.

Ten (34.5%) of the infants, all of whom were full-term, developed evidence of intracranial hemorrhage (ICH): 7 caudate (24.1% of hemorrhages) and 1 (3.4% of hemorrhages) each in the thalamus, parietal and occipital lobes. All patients, as expected, since they failed mechanical ventilation, had documented hypoxia prior to being placed on ECMO. No patients required cardiopulmonary resuscitation prior to ECMO cannulation. Six patients with ultrasound abnormalities developed a pneumothorax in their course, 4 of whom also developed ICH on ultrasound. All studied patients had a period of hypotension in their course. Eight (27.6%) of the infants had seizures while on ECMO, 5 of whom had concurrent ICH. No intracranial hemorrhage required surgical intervention. ECMO was discontinued when hemorrhage was identified.

Discussion

ECMO has been demonstrated to be a useful technique for improved oxygenation in properly selected full-term infants. Neurosurgeons are being asked to consult on the infants with abnormal ultrasounds and need to understand the findings of a particular infant in the context of the ultrasound findings of children on ECMO in general. Part of this understanding must include the technical side of ECMO. Cannulation for ECMO involves the ligation of the right internal jugular vein and the right common carotid artery (fig. 1). Following cannulation, infants are heparinized and develop thrombocytopenia and coagulopathy requiring infusion of platelets, fresh frozen plasma and packed red blood cells. Outflow of the blood from the patient is by gravity only and frequently these patients are elevated to as much as four or five feet above the floor to facilitate drainage. Fluid intakes still exceed outputs with elevated central venous pressures, an average of 16.7 mm Hg in our patients. The infants are all grossly edematous (fig. 2) with third spacing of fluid.

In this context, the most common finding, extra-axial fluid collections (fig. 3, 4) sometimes misinterpreted as atrophy, seen in 17 patients, is not surprising. This per-

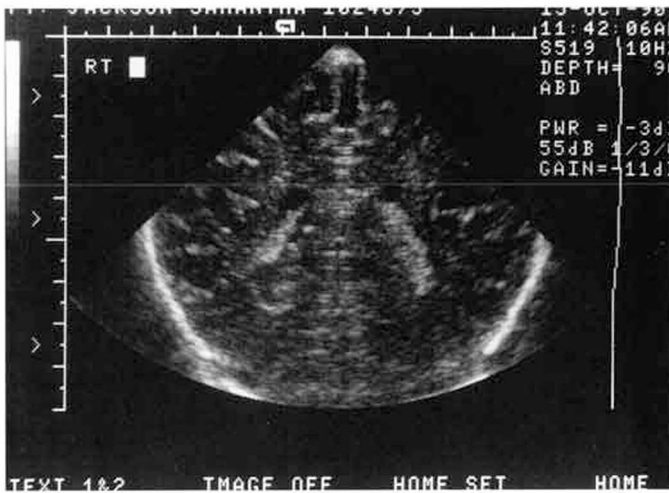

Fig. 3. Ultrasound showing increased fluid in interhemispheric fissure.

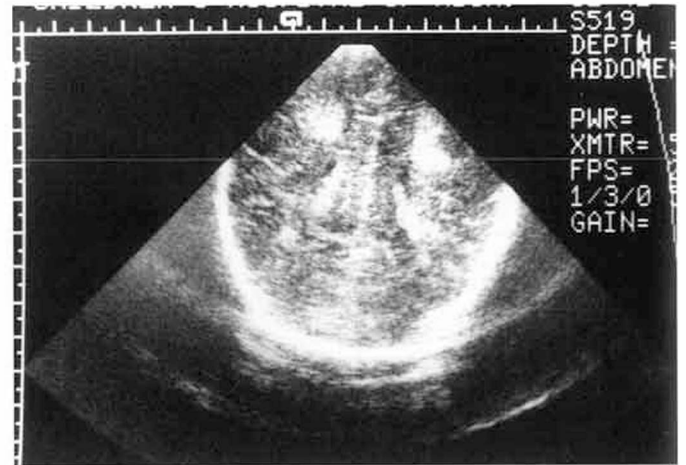


Fig. 5. Ultrasound of head showing ICH in a child on ECMO.

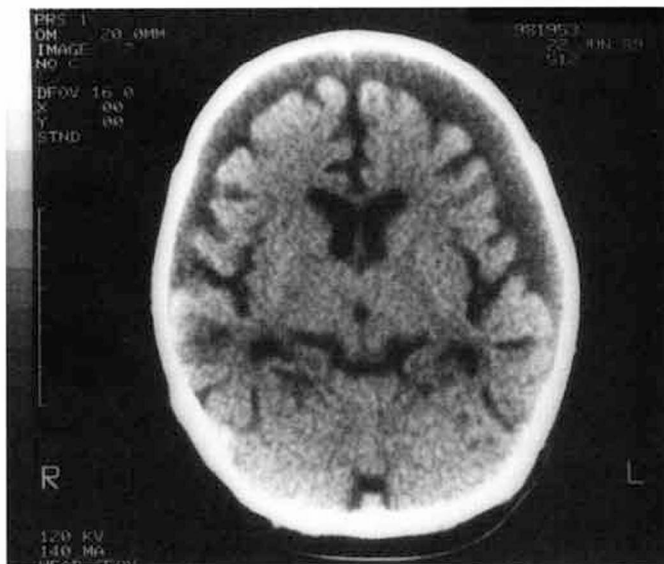

Fig. 4. Computerized tomography of patient who went on to require surgical intervention for extra-axial collections.

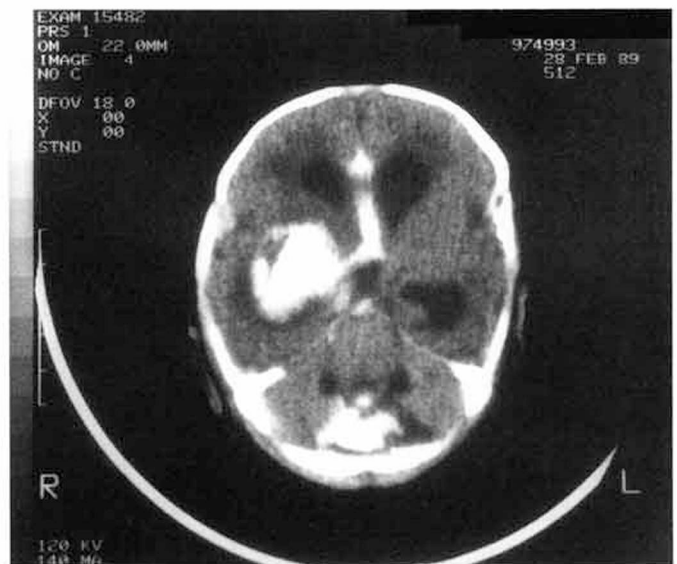

Fig. 6. ICH in posterior fossa, right temporal area, and 3rd ventricle.

centage of 59.6% is higher than in other series. Taylor et al. [1] reported 8 cases of atrophy and 8 of a widened interhemispheric fissure in a series of 146 patients. Both of these probably represent increased extra-axial collections for a total of 11%. An incidence of approximately 10% was also seen by Babcock et al. [2]. This series may have missed transient extra-axial collections as the protocol called for ultrasounds before ECMO, within 12 h of

ECMO and only on clinical grounds during ECMO. That explanation does not apply to the Taylor series where ultrasounds were also obtained daily during ECMO. The discrepancy cannot be explained at this time. The extra-axial collections are felt to be secondary to increased venous drainage pressures. All but two of these cases were only transient, making the ligation of the jugular vein which occurs at the time decannulation in all patients a

possible contributory but not the primary causative factor. Hydrocephalus has been seen in 2 patients, not in this series. In both those cases, the patients had superior vena cava obstruction as well.

The hemorrhages that are seen now in full-term infants who have had good control of their hypertension are much more discrete (fig. 5) than those seen in the past. Early experience showed that infants less than 35 weeks gestation had rates of ICH as high as 100% [3]. A correlation between hypertension and the occurrence of ICH was demonstrated at the Children's Hospital of Michigan. With a high hypertension index (hours systolic BP greater than 90 divided by hours receiving ECMO), there was an increased risk of ICH. If ICH is present, the hypertension index was 0.37 ± 0.28 and if no ICH, the hypertensive index was 0.2 ± 0.12 [4].

As these factors were recognized, the early massive ICH that came to neurosurgical attention largely disappeared (fig. 6). Instead, extra-axial fluid and discrete hemorrhages were the reason for neurosurgical consultation. The anticoagulation and thrombocytopenia undoubtedly play a role. In the current series, of the 6 patients with pneumothorax in their hospitalization, 4 had ICH, raising concern that barotrauma which predisposes premature infants to germinal matrix hemorrhages may play a role as well. Other factors postulated include rapid infusion of colloid [3]. In our institution, ECMO is discontinued if

the daily ultrasound demonstrates new hemorrhage. At the Children's Hospital of Cincinnati, Babcock et al. [2] did not feel that small subependymal hemorrhages extended on ECMO. The 34.5% incidence of hemorrhage in this series is comparable to Taylor's series where preterm infants were also excluded and the hemorrhagic rate by ultrasound and computerized tomography was 30% [1].

Eight (37.6%) of the neonates had seizures while on ECMO, 5 of whom had concurrent ICH. So the occurrence of seizure should raise increased suspicion of ICH. This incidence is comparable to the series of Matamoros et al. [5] with a 25% incidence of seizures on ECMO.

Conclusion

Although there is a high incidence of extra-axial fluid collections in infants on ECMO, the vast preponderance is self-limited and does not require neurosurgical intervention either by tapping or surgery, both of which would be contraindicated in these heparinized patients without discontinuing the ECMO therapy. In the small percentage that are progressive, intervention can be accomplished after ECMO is discontinued as determined by pulmonary indications. In the cases of limited ICH, surgical intervention was not required but ECMO therapy was discontinued because of concern regarding extension of the clot.

References

- 1 Taylor GA, Fitz CR, Glass P, Short BL: CT of cerebrovascular injury after neonatal extracorporeal membrane oxygenation: Implications for neurodevelopmental outcome. *Am J Radiol* 1989;153:121-126.
- 2 Babcock DS, Han BK, Weiss RG, Ryckman FC: Brain abnormalities in infants on extracorporeal membrane oxygenation: Sonographic and CT findings. *Am J Radiol* 1989;153:571-576.
- 3 Cilley RE, Zwischenberger JB, Andrews AF, Bowerman RA, Roloff DW, Bartlett RH: Intracranial hemorrhage during extracorporeal membrane oxygenation in neonates. *Pediatrics* 1986;78:699-704.
- 4 Sell LL, Cullen ML, Whittlesey GC, Yedlin ST, Philippart AI, Bedard MP, Klein MD: Hemorrhagic complications during extracorporeal membrane oxygenation: Prevention and treatment. *J Pediatr Surg* 1985;21:1087-1091.
- 5 Matamoros A, Anderson JC, McConnell J, Bolam DL: Neurosonographic findings in infants treated by extracorporeal membrane oxygenation (ECMO). *J Child Neurol* 1989;4:S52-S61.