

## SHORT REPORT

## Hemineglect and seizures in Binswanger's disease: clinical-pathological report

Stephan A Mayer, Thomas K Tatemichi, Laura S Hair, James E Goldman, Ann Camac, J P Mohr

### Abstract

**The range of clinical effects from ischaemic damage to white matter in Binswanger's disease has not been fully characterised. Although focal deficits and seizures occur frequently, superficial infarcts often coexist, making the cause of these symptoms unclear. The case of a 69 year old woman is described who presented with acute left sided weakness and hemispacial neglect, followed a year later by electrographically documented seizures originating from the right hemisphere. Interim examinations showed bilateral pyramidal signs and mild intellectual decline. Serial CT and MRI studies showed bilateral diffuse ischaemic lesions of the cerebral white matter and old left sided lacunar infarcts but no evidence of acute infarction. Post-mortem examination showed gliosis and demyelination of the deep white matter which spared the subcortical arcuate fibres; this is consistent with Binswanger's disease. The neocortex was normal. This case and previous reports indicate that focal symptoms typically referable to the grey matter, including hemineglect and seizures, may occur as a manifestation of subcortical ischaemic injury to white matter in Binswanger's disease.**

(*J Neurol Neurosurg Psychiatry* 1993;56:816-819)

Binswanger's disease is a progressive form of vascular dementia resulting from diffuse and multifocal ischaemic damage to subcortical white matter. Although the pathological features of the disease have been well defined,<sup>1-3</sup> their relation to focal symptoms or signs in the course of the disease remains uncertain. In a recent review by Babikian and Ropper focal neurological deficits occurred in 55% and seizures in 18% of 47 pathologically verified cases of Binswanger's disease.<sup>3</sup> The frequent coexistence of cortical and lacunar infarcts<sup>3</sup> and the retrospective nature of the diagnosis (with imperfect historical information) have limited previous attempts to correlate focal neurological signs and pathological changes in patients with the disease. We describe the case of a patient with acute non-dominant hemispheric deficits and seizures

whose postmortem examination showed only subcortical lesions in white matter consistent with Binswanger's disease.

### Case report

A 69 year old right handed woman was first admitted to the Neurological Institute with acute left sided weakness and hemispacial neglect. She had a long history of treated hypertension but no history of stroke, dementia, or seizures.

On admission her blood pressure was 230/120 mm Hg. She was alert but disoriented to place and time, with dysarthric, perseverative speech and rightward head turning. She bisected a line to the right and failed to draw numerals on the left side of a clock face. There was no visual field cut, aphasia, anosognosia, or asomatagnosia. Cranial nerves were normal except for a gaze preference to the right and flattening of the left nasolabial fold. She had a moderate left hemiparesis, 4/5 in the arm and leg, with deficits to light touch, pinprick, graphesthesia, and double simultaneous stimulation on the left side. Deep tendon reflexes were active but symmetrical and the toes withdrew bilaterally. Coordination testing was performed slowly on the left, without dysmetria or ataxia. Gait could not be tested.

CT on admission showed generalised cerebral atrophy, prominent bilateral patchy lucencies in the centrum semiovale and corona radiata (figure 1), and discrete lucencies of the left posterior internal capsule and upper pons consistent with old lacunar infarction. CTs obtained 2 and 14 days later showed the same results. An EEG on admission and two weeks later showed continuous polymorphic delta activity over the right hemisphere. Doppler ultrasound studies showed normal flow velocities in the internal carotid and vertebral arteries. Electrocardiography, echocardiography, Holter monitoring, and procoagulant studies gave normal results; erythrocyte sedimentation rate was normal and tests for venereal disease gave negative results.

She was treated with aspirin and nifedipine. By the time of discharge 20 days later her strength had fully recovered, but mild signs of left sided hemineglect and sensory loss persisted.

Department of  
Neurology  
S A Mayer  
T K Tatemichi  
A Camac  
J P Mohr

Department of  
Pathology  
L S Hair  
J E Goldman

Columbia University,  
College of Physicians  
and Surgeons, New  
York, New York,  
United States

Correspondence to:  
Dr T K Tatemichi, Stroke  
and Aging Research Project,  
Neurological Institute, 710  
West 168th Street, New  
York, NY 10032, USA.

Received 15 May 1992  
and in revised form  
31 July 1992.

Accepted 11 August 1992

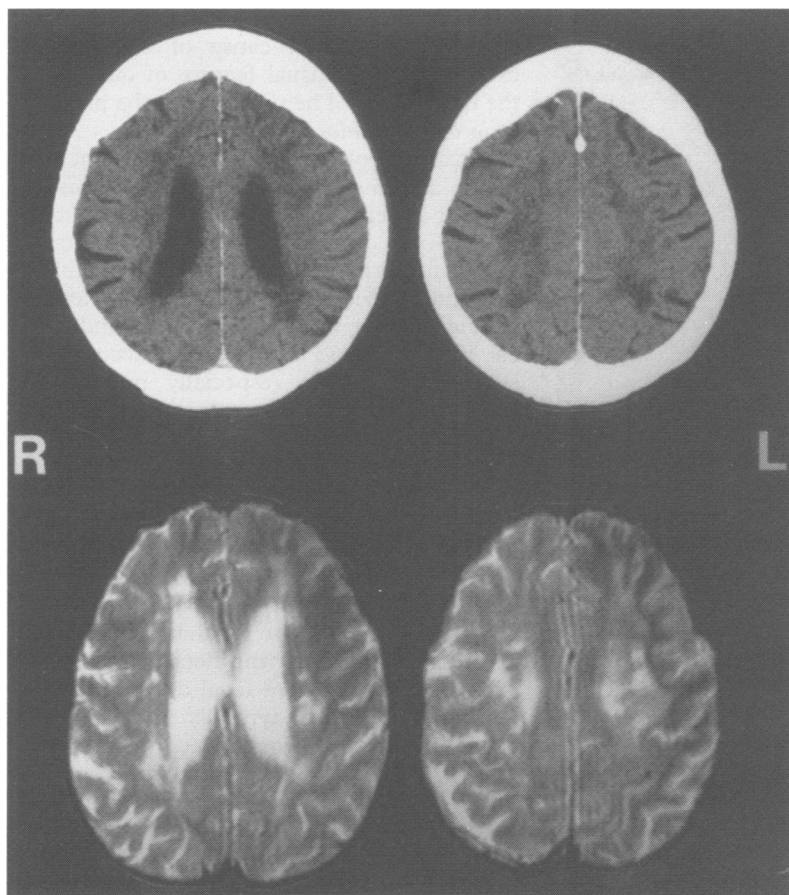


Figure 1 CT on presentation (top) showed moderate atrophy and diffuse patchy areas of low density in the centrum semiovale and corona radiata. T2 weighted magnetic resonance images obtained two months after patient's initial admission (bottom) showed multiple foci of increased signal in a similar distribution. All follow up studies gave same results.

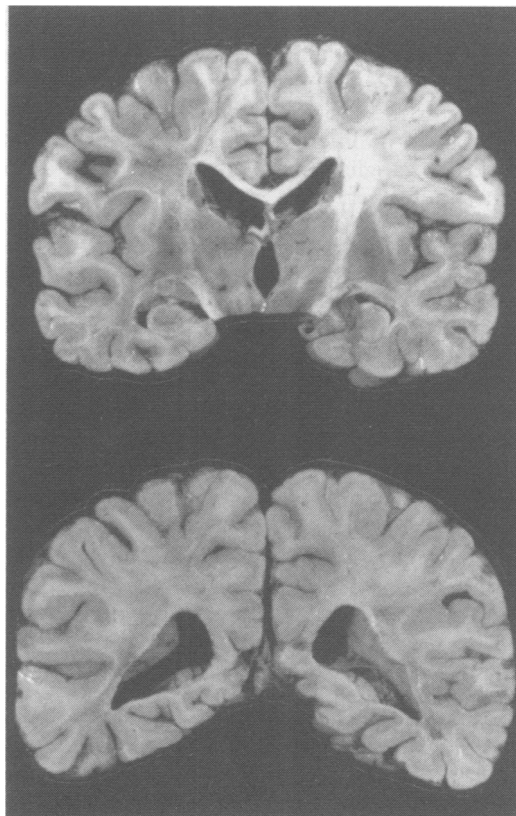


Figure 2 Coronal sections at level of anterior thalamus (top) and occipital horns (bottom) showing severe gliotic changes bilaterally in subcortical white matter (left side is to reader's left).

Three months after discharge, members of her family noted new difficulty with memory, affective lability, and paranoid ideation. On examination she was disoriented to year, with hypophonic, perseverative speech and impaired short term recall. She displayed constructional apraxia on clock drawing but showed no signs of neglect, sensory loss, or weakness. Rapid alternating movements were slow bilaterally, reflexes were symmetrical, and Babinski's sign was absent. She walked with a decreased armswing on the left and was unable to walk in tandem.

T2 weighted magnetic resonance imaging obtained two and eight months after the initial stroke showed generalised atrophy with multiple foci of increased signal in the bilateral fronto parietal white matter, left brachium pontis, and left upper pons (fig 1).

One year after her first admission, she presented with seizures characterised by leftward head and eye deviation, left beating nystagmus, and tonic contractions of the left arm and leg with occasional clonic movements. Her blood pressure was 200/100 mm Hg. After treatment with intravenous phenytoin she was oriented only to name, with diminished verbal output, left hemineglect, and moderate left hemiparesis. By the following day her left motor signs had improved, with only slowed rapid alternating movements evident, but signs of hemineglect persisted. A CT of the head showed the same as the previous studies.

On her second day in hospital further seizure activity was noted with eye blinking, inattention, and left arm posturing. Electroencephalopathy showed an electrographic seizure originating from the right fronto temporal region, unreactive continuous polymorphic delta and periodic lateralising epileptiform discharges over the right hemisphere, and diffuse slowing without a posterior dominant rhythm. Her seizures were subsequently controlled with the addition of phenobarbitone. On the fifth day in hospital she died of cardiac arrest.

#### PATHOLOGICAL FINDINGS

##### Macroscopic description

The fresh brain weighed 1130 g. There was generalised moderate sulcal and gyral atrophy with no external signs of discoloration or softening. The blood vessels at the base of the brain showed mild evidence of atherosclerosis. Although the cortical grey matter appeared grossly normal, the subjacent white matter was gliotic throughout both hemispheres. These changes were patchy, symmetrical, and most severe in the posterior parietal lobes (fig 2). A cystic area measuring 0.4 cm in diameter was noted in the right centrum semiovale, with a similar lesion on the left. Sequential sections of the brainstem and cerebellum were macroscopically normal.

##### Microscopic description

Arterioles throughout the subcortical white matter displayed markedly thickened and fibrotic walls (fig 3). Atherosclerotic plaques

Figure 3 Marked arteriolar thickening and severe myelin loss in deep hemispheric white matter (Luxol fast blue-periodic acid-Schiff stain, magnification  $\times 200$ ).

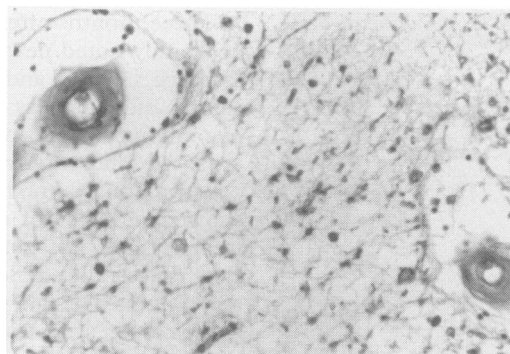
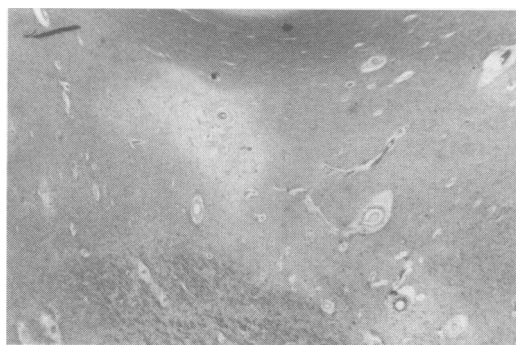

Figure 4 Subcortical demyelination with sparing of arcuate U fibres (Luxol fast blue-periodic acid-Schiff stain, magnification  $\times 40$ ).



were noted in the pial arteries and to a lesser extent in the medullary cortical vessels. There was extensive demyelination and gliosis throughout the white matter, most severe in the posterior parietal and occipital lobes. The demyelination spared the arcuate fibres and was most severe in the deep and periventricular regions (fig 4). Bielschowsky's silver stain showed a decrease in axonal fibres, although they were spared compared with the loss of myelin. Several microscopic areas of infarction were noted in the left basal ganglia and bilateral thalamus and pons; these were not apparent macroscopically.

Nine sections of bilateral frontal, parietal, and occipital neocortex were examined, including the posterior parietal lobes overlying the most severely affected white matter. In these regions the neuronal populations were normal with no evidence of ischaemic tissue damage. A moderate number of diffuse amyloid plaques and neurofibrillary tangles were scattered throughout the basal forebrain and the frontal and occipital cortices; they were no more than would be expected with normal ageing.

### Discussion

Our patient presented first with a stroke characterised by non-dominant hemispheric deficits and later with seizures, with evidence of intellectual deterioration in the interim. Postmortem findings showed pathological changes of the type typically seen in Binswanger's disease, with no evidence of large deep cavitory lesions or injury to the neocortex. Although large subcortical *infarction* affecting the non-dominant thalamus,

basal ganglia, or frontal-parietal white matter is a well described cause of neglect syndromes,<sup>4,5</sup> the unusual feature of our case is the occurrence of hemineglect in the presence of *incomplete white matter infarction*.<sup>6</sup>

Focal neurological deficits consistent with stroke or transient ischaemic attack occur in 60% of patients with Binswanger's disease at some point during the illness.<sup>2,3</sup> Among 47 cases of the disease with complete pathological reports reviewed by Babikian and Ropper, lacunar infarcts were found in 93% and cortical infarcts in 33% of cases.<sup>3</sup> Accordingly, lacunar syndromes (especially pure motor stroke) are the most common acute focal deficits in Binswanger's disease.<sup>2</sup> However, several instances of persistent focal cortical deficits (incorporating aphasia,<sup>7</sup> hemianopia,<sup>8,9</sup> and apraxia<sup>10</sup>) have been described in patients in whom the corresponding neocortex was normal on neuropathological examination. These cases and our case support the view proposed by Lassen that incomplete ischaemic damage to the deep white matter can result in persistent focal deficits indistinguishable from those typically associated with acute infarction.<sup>11</sup> Positron emission tomography studies showing both diffuse<sup>12,13</sup> and focal<sup>12</sup> reductions in cerebral blood flow in cortical regions overlying large confluent white matter lesions on MRI or CT suggest that such deficits may occur on the basis of cortical deafferentation.

Seizures are widely recognised as part of the clinical spectrum of Binswanger's disease<sup>2,3</sup> but have received limited attention, perhaps because of uncertainty about their origin. We have identified 10 previously reported cases of Binswanger's disease associated with seizures.<sup>1,9,14-19</sup> One patient experienced partial motor seizures after a hemiparesis, and in this case a cortical infarct was identified that may have been responsible.<sup>1</sup> In two cases metabolic derangements may have precipitated the seizures.<sup>9</sup> Otherwise, unprovoked recurrent generalised tonic-clonic seizures are the rule, typically appearing late in the course of the illness. In some instances seizures marked the onset of either a transient<sup>14,15</sup> or permanent<sup>16,17</sup> focal neurological deficit. The corresponding cortical areas in these patients were described as macroscopically normal, as was the case in our patient.

The EEG finding of periodic sharp wave complexes in Binswanger's disease has been previously noted in a patient who had no seizure activity.<sup>20</sup> However, electrographic seizures arising from pathologically normal areas of cortex have not been previously documented in the disease. Four days before her death our patient presented with recurrent left sided weakness and neglect in the setting of simple partial and complex partial status epilepticus. We cannot determine whether these symptoms were triggered by a new subcortical ischaemic event or represented seizures with Todd's paralysis. Nevertheless, the EEG and pathological findings indicate that the subcortical ischaemic demyelinating lesions were probably responsible. Although

seizures are typically thought to result from disease of the cortex, a well defined risk of epilepsy has been identified in other diseases of the white matter as well—for example, multiple sclerosis<sup>21</sup> and progressive multifocal leucoencephalopathy.<sup>22</sup>

The full range of focal symptomatology associated with white matter ischaemia in Binswanger's disease is poorly understood. Vague terms such as stroke-like events<sup>3</sup> and transient neurological phenomena<sup>2</sup> abound in published reports, illustrating the sometimes atypical fluctuating symptoms seen in the disease. Babikian and Ropper have argued that Binswanger's disease should be recognised as an entity distinct from multi-infarct dementia because of both the characteristic pathology and the "irregularity and inconsistency of [the] focal stroke syndromes". Our case shows that focal symptoms and signs typically referable to the grey matter (specifically, hemineglect and seizures) may occur as a manifestation of incomplete white matter ischaemia, in the absence of complete infarction with cystic cavitation. Confirmation of this finding, and the delineation of other unusual focal manifestations of Binswanger's disease, may broaden the clinical range of white matter ischaemic disorders in general, and Binswanger's disease in particular.

We thank Drs Cassilda Balmaceda and Elizabeth Webster for their help in translating the French cases. This work was supported in part by grants R01-NS26179 and P01-AG07232 from the National Institutes of Health.

- 1 Caplan LR, Schoene WC. Clinical features of subcortical arteriosclerotic encephalopathy (Binswanger's disease). *Neurology* 1978;28:1206-15.
- 2 Fisher CM. Binswanger's encephalopathy: a review. *J Neurol* 1989;236:65-79.

- 3 Babikian V, Ropper AH. Binswanger's disease: a review. *Stroke* 1987;18:2-12.
- 4 Heaton EB, Navarro C, Bressman S, Brust JCM. Subcortical neglect. *Neurology* 1982;32:776-8.
- 5 Stein S, Volpe BT. Classical "parietal" neglect syndrome after subcortical right frontal lobe infarction. *Neurology* 1983;33:797-9.
- 6 Englund E, Brun A, Alling C. White matter changes and dementia of Alzheimer's type. *Brain* 1988;111:1425-39.
- 7 Dubas F, Gray F, Rouillet E, Escourrolle R. Leukoencéphalopathies artériopathiques. *Rev Neurol* 1985;141:93-108.
- 8 Ali Cherif A, Labrecque R, Pellissier JF, Poncet M, Boudouresques J. Encéphalopathie sous-corticale de Binswanger. *Rev Neurol* 1979;135:665-78.
- 9 Garcia-Albea E, Cabello A, Franch O. Subcortical arteriosclerotic encephalopathy (Binswanger's disease): a report of five patients. *Acta Neurol Scand* 1987;75:295-303.
- 10 Dupuis M, Brucher JM, Gonsette RE. Observation anatomo-clinique d'une encéphalopathie sous-corticale artériosccléreuse avec hypodensité de la substance blanche au scanner cérébral. *Acta Neurol Belg* 1984;84:131-40.
- 11 Lassen NA. Incomplete cerebral infarction—focal incomplete ischemic tissue necrosis not leading to emolliation. *Stroke* 1982;13:522-3.
- 12 Herholz K, Heindel W, Rackl A, et al. Regional cerebral blood flow in patients with leuko-araiosis and atherosclerotic carotid artery disease. *Arch Neurol* 1990;47:392-6.
- 13 Yao H, Sadoshima S, Kuwabara Y, Yuichi Y, Fujishima M. Cerebral blood flow and oxygen metabolism in patients with vascular dementia of the Binswanger type. *Stroke* 1990;21:1694-9.
- 14 Neumann MA. Chronic progressive subcortical encephalopathy. Report of a case. *J Gerontol* 1947;2:57-64.
- 15 Rosenberg GA, Kornfeld M, Stovring J, Bicknell JM. Subcortical arteriosclerotic encephalopathy (Binswanger): computerized tomography. *Neurology* 1979;29:1102-6.
- 16 Yvonneau M, Vital C, Lafforgue J, Kinsala MS. L'encéphalopathie sous-corticale chronique de Binswanger. *Bordeaux Med* 1969;2:1135-41.
- 17 Ladame C. Encéphalite sous-corticale chronique. *Encéphale* 1912;7:13-39.
- 18 Aronson SM, Perl DP, eds. Clinical neuropathological conference. *Dis Nerv Syst* 1974;35:286-91.
- 19 Biemond A. On Binswanger's subcortical arteriosclerotic encephalopathy and the possibility of its clinical recognition. *Psychiatr Neurol Neurochir* 1970;73:413-7.
- 20 White JC. Periodic EEG activity in subcortical arteriosclerotic encephalopathy (Binswanger's type). *Arch Neurol* 1979;36:485-9.
- 21 Kinnunen E, Wikstrom J. Prevalence and prognosis of epilepsy in patients with multiple sclerosis. *Epilepsia* 1986;27:729-33.
- 22 Krupp LB, Lipton RB, Swerdlow ML, et al. Progressive multifocal leucoencephalopathy: clinical and radiographic features. *Ann Neurol* 1985;17:344-9.