



Axial Motor Disturbances After Hypoxic Lesions of the Globus Pallidus

A. P. Fève, G. Fénelon, *C. Wallays, P. Rémy, and A. Guillard

*Service de Neurologie, and *Service de Radiologie, Hôpital Tenon, Paris, France*

Summary: Four subjects aged between 29 and 60 years were examined because of axial motor impairment after hypoxic brain injury. Magnetic resonance imaging revealed circumscribed lesions of the globus pallidus in every case. The association of freezing of the gait, speech disorders, axial bradykinesia, and postural disturbances, with no rigidity or tremor and little or no distal akinesia, suggests a role of the globus pallidus in controlling axial motion. **Key Words:** Hypoxic-ischemic—Globus pallidus—Axial motility.

Hypoxic ischemic injury is known to cause necrosis of the striatopallidal region (1,2). Bilateral hypoxic lesions of the basal ganglia due to ischemia (3-5) or carbon monoxide poisoning (6) produce various neurological pictures, including abnormal, involuntary movements and extrapyramidal syndromes. However, the lesions are often extensive (7) and associated with diffuse neurological symptoms (8). We report the cases of four patients who developed predominantly axial motor disturbances following apparently pure bilateral lesions of the globus pallidus (GP) after a hypoxic-ischemic event.

CASE REPORTS

Case 1

A 35-year-old man was treated for depression in June 1990 with viloxazine and loxapac. In July 1990, he developed severe inhalation pneumopathy and was admitted to the intensive care unit. He abruptly developed respiratory arrest with profound and sustained hypotension requiring immediate mechanical ventilation. He gradually regained consciousness over a 1-week period. At examination in June 1991, he was alert but had very slow

movements. Although he never fell, he had a frozen gait with motor blocks and small steps when starting to walk, during half-turns, or going through doorways and narrow spaces. He presented a second type of gait blockade in the same situations, with inversion of his left foot and left rotation of the head (see videotape). This posture was fixed but not dystonic, and the muscle tone was normal. Dropping pieces of paper on the floor did not improve his walk. He moved his trunk in a slow and rigid manner. However, the gait was steady and tolerated a narrow base. Alternative rhythmic movements of the feet were almost possible. Despite this slowness, he sometimes experienced sudden periods of normal mobility, during which he walked easily. These paradoxical periods were triggered by pleasant experiences, such as meeting his family or eating meals. All upper-limb movements were slow with occasional motion arrests. For example, while drinking, he would stay in the same fixed position for a few seconds, with the glass close to his lips. However, he could dress, wash, and eat unaided. Puppets and finger tapping were correctly executed with both hands, but the movements were slow. His handwriting was micrographic. He was severely dysarthric and his facial immobility was striking. Dopa therapy resulted in a mild improvement in the distal slowness, but not in the axial or gait disturbances. Ear, nose, and throat (ENT) work-up and

Videotape segments accompany this article.

Address correspondence and reprint requests to Dr. A. P. Fève, Service de Neurologie, Hôpital Tenon, 4 rue de la Chine, 75020 Paris, France.

cranial nerve examination were normal. He was well-oriented, although neuropsychological assessment disclosed marked inertia and difficulties in shifting his attention. Computed tomography (CT) scan showed bilateral pallidal lucencies; these were confirmed by magnetic resonance imaging (MRI) (Fig. 1).

Case 2

A 29-year-old woman was referred to our neurological center in June 1991, following deterioration of her ability to speak and walk. She had been depressed for 5 years and had been treated with imipramine and amitryptiline hydrochloride. In May 1990, she ingested a massive dose of imipramine in a suicide attempt and had a cardiac arrest. She remained comatose for 48 h, but gradually returned to normal consciousness. Examination 1 year later revealed gait freezing only when crossing door steps or half-turning. Also, postural instability sometimes occurred (see videotape). She was in the habit of placing a bandage around her right foot to lift it when she froze. However, this procedure had no clear effect. The gait was otherwise normal and the patient was able to tap her feet alternately on the floor. Her handwriting was micrographic and undecipherable after the first line. This contrasted with the absence of any upper-limb movement disorder (UPDRS motor examination) (9). Strength, deep-tendon reflexes, and sensory tests were normal. Both plantar reflexes were flexor. She had whispering speech with palilalia. There was mild intellectual impairment and memory disturbances. CT and MRI scans (Fig. 2) showed bilateral lesions of the pallidal area. Standard laboratory tests (the cupremia and ceruleoplasmin) were normal. Slit-lamp ex-

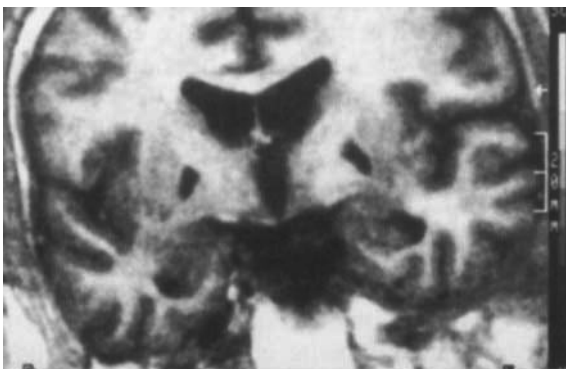


FIG. 1. Case 1. T1 scans in inversion recovery sequences in the frontal plane perpendicular to anterior-posterior/commissural line (AP/CL) plan showing bilateral lesions of the external GP.

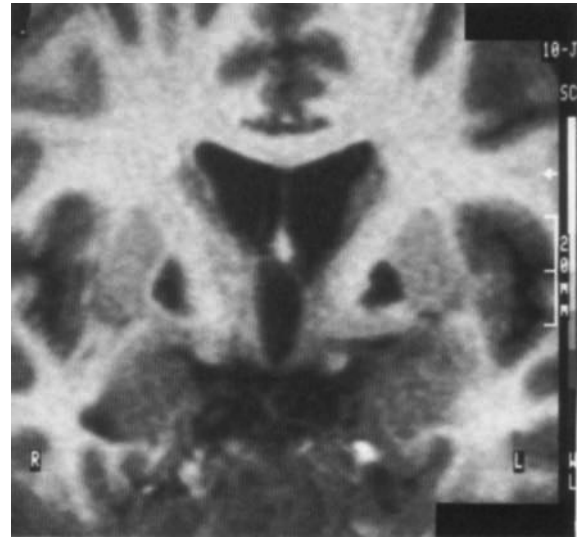


FIG. 2. Case 2. T1 scans in inversion recovery sequences in the frontal plane perpendicular to AP/CL plan demonstrated bilateral necrotic hypointense lesions of the external GP.

amination was also normal. The symptoms were not improved by apomorphine and levodopa.

Case 3

A 60-year-old retired woman with no notable medical history was examined in our hospital because of gait disturbances after hip-replacement surgery. She had developed cardiovascular collapse of septic origin immediately after the operation. She was obtunded, but gradually regained consciousness after 48 h. She had been unable to turn in bed or to change from the prone to the sitting position. Movements of the feet were normal. She had a tendency to retropulsion in the standing position, and waking her was impossible without aid. Movements of the upper limbs were otherwise normal; in particular, they were not slow. Neurological examination disclosed a discrete deficit of the right arm with no pyramidal signs. She had made a full recovery after 2 weeks. Neuropsychological evaluation revealed normal intelligence. Memory tests results were normal, but she had slow language fluency and inertia. The CT scan was normal, but the MRI scan (Fig. 3) showed symmetrical, bilateral lesions of the median pallidum.

Case 4

A 34-year-old man was treated in March 1982 for acute alcoholic pancreatitis; he subsequently developed severe cardiovascular collapse and cardiac arrest. Approximately 10 min elapsed before resusci-

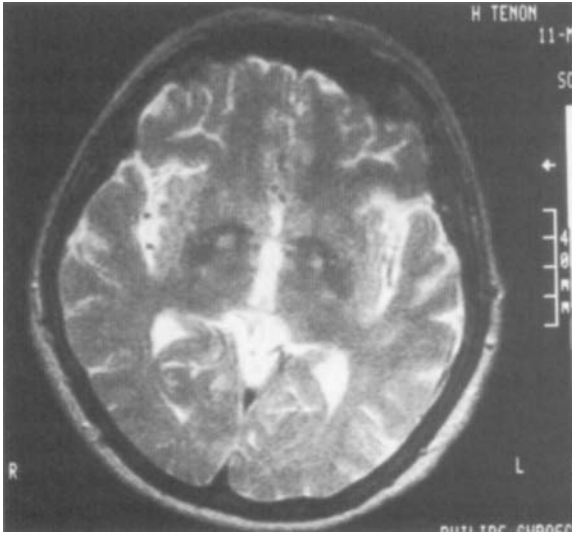


FIG. 3. Case 3. T2 scan parallel to and 3 cm below the AP/CL plane. This scan shows two high signals indicating circumscribed lesions of the medial part of the GP.

tation. During the first week after his attack, he was comatose and had a left hemiparesia, which completely resolved. He was fully alert, but remained mute and had gait disturbances. Neurological examination 1 month later showed an awkward and unsteady gait. He had a tendency to block his gait in a dystonic posture, with the right foot and hand behind the body. This freezing was triggered when passing through a doorway or starting to walk and occasionally caused him to fall. He walked easily, but would make half-turns with small steps. Gait disorders were not improved by visual stimuli such as stripes or obstacles on the floor. Alternative movements of the hands and feet (tapping on the floor) were correctly performed with no slowness. Precision tasks like pointing at a target or pointing to the nose with the index finger were also normal. There was a postural tremor of the upper limbs, with mild rigidity of the wrists. He was able to wash, dress, and eat unaided. Strength was normal, and the deep-tendon reflexes were normal and symmetrical; both plantar reflexes were flexor. Speech was severely impaired, with marked dysarthria, but tongue and larynx movements were not dystonic and ENT examination was normal. Neuropsychological assessment revealed a normal intellect and speaking ability, but with slowness and marked inertia. Visuospatial tests were disturbed. Nevertheless, he was not apathic and frequently took walks in the grounds, read, and phoned his family. His state remained stable between 1982 and 1990. A CT

scan performed in 1984 was normal, but an MRI scan in 1990 (Fig. 4) revealed bilateral lesions of the pallidal area. Cerebrospinal fluid (CSF), routine laboratory tests, cupremia and cupriuria, and slit-lamp ophthalmologic examinations were normal. Levodopa, carbidopa, and trihexyphenidyl were ineffective.

DISCUSSION

All these patients had bilateral lesions of the globus pallidus (GP), detected by an MRI scan in inversion recovery sequences. They had only mild segmental bradykinesia contrasting with marked disturbances of posture and slowed axial movements. They also had starting difficulties, especially for walking (gait blockade or freezing) and speech (pallilalia-mutism). By contrast, rigidity and resting tremor were absent, giving a particular clinical picture different from the classical "extrapyramidal" parkinsonian syndrome (Table 1).

All patients had postural impairment. They fell in ante- or retropulsion, without correction by postural reflexes, and generally made no attempt to avoid falling. In the standing position, they tolerated a narrow base and did not sway. Eye closure generally did not worsen their postural defect. They had otherwise slowed axial movements, moving en bloc when they rose from a chair or turning in bed with difficulty. When walking, they made half turns very slowly. Gait blocks (GB) were frequent; patients 1, 2 and 4 had a tendency to block, and to stop

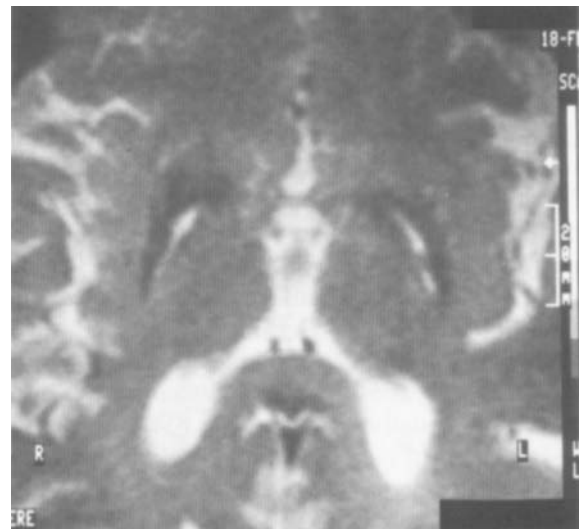


FIG. 4. Case 4. Spin-echo T2 MRI sequences in the AP/CL plane demonstrating lesions of the external globus pallidus.

TABLE 1. *Clinical characteristics of the patients*

Cases	1	2	3	4
Postural disturbance	++	++	++	++
Axial slowness	+++	++	++	++
Freezing of the gait	+++	+++	0	+++
Speech impairment	+++	+++	0	+++
Distal akinesia	+	0	+	0
Axial rigidity	0	0	0	0
Limb rigidity	0	0	0	0
Resting tremor	0	0	0	0
Postural tremor	+	++	+	++

0, absent; +, mild; ++, moderate; +++, severe.

when starting and during the walk, when half-turning, or changing direction. GB was often triggered by going through narrow spaces or doorways. Two types of GB were noted: the patients tended to stomp and to stop with rhythmic, repetitive movements or they stayed in a frozen, "magnetically fixed" posture. These two types of freezing have been described previously in extrapyramidal disorders by Marelagno Filho (9). Patient 1 frequently froze but otherwise had normal mobility. Postural impairment, slowness of axial movements, and GB were not associated with neck or trunk stiffness.

Patients 1 and 4 had also difficulties in starting to speak. Patient 1 had severe dysarthria, whereas patient 4 was quasimute. Speech disturbances were present in cases 1, 2, and 4. Patient 2 was hypophonic and pallilalic. Furthermore, all the patients were amimic or hypomimic.

By contrast, three patients had only a discrete slowness of distal movements, whereas one was more severely bradykinetic (patient 1). Micrographia was noted in patients 2 and 3, and there was only discrete limb bradykinesia at the UPDRS evaluation of segmental single movements (10).

It is well known that degenerative disorders of the basal ganglia may produce postural instability (11); Denny-Brown (12) reported severe alteration of posture after massive bilateral lesions of the GP. Carbon monoxide poisoning is one of the best-known causes of hypoxia producing parkinsonian signs (13), and old clinical reports of bilateral post-CO lesions of the basal ganglia described severe changes of posture, resembling decerebrate rigidity (12). However, these lesions induced by CO intoxication are usually extensive (7). The lesions are rarely limited to the GP (7), and parkinsonian signs are usually associated with other neurological symptoms like pyramidal signs (13) and disturbed intellectual function. Many types of abnormal movements including chorea (14,15), myoclonus

(16) and tics (17) have been described after bilateral lesions of the striatum or pallidum, and have been caused usually by poisoning (13), hypoxia (1), toxic inhalation, or ingestion of cyanides (18) or carbon disulfid (19). "Psychic akinesia" and behavioral changes have also been reported after basal ganglia lesions (20,21). Diffuse dystonia is described after hypoxemia and bilateral lesions of striatum or pallidum (3,5). Apart from these involuntary, abnormal movements, pure parkinsonian features have rarely been reported. Durand et al. (4) reported a post-CO extrapyramidal syndrome with limited lesions of the striatum and pallidum showing on the MRI scan. Klawans et al. (22) first described post-CO intoxication with pure bilateral lesions of the GP at autopsy examination. Detailed observation of this case revealed pure extrapyramidal signs, with a predominance of axial signs, but no rigidity. Axial signs are found in other types of GP lesions: postural disturbances and frozen gait have been described in pure pallidal degeneration (23) and Labadie et al. (24) reported patients with unilateral pallidal or putaminal vascular lesions who experienced falls and postural deficits.

The responsibility of the GP in these clinical signs must be considered in the light of extensive lesions after diffuse brain hypoxia. However, massive lesions of the white matter were ruled out by the absence of an hypersignal in T2 MRI sequences.

Relationships between GP and axial akinesia and experiments in animals, especially monkeys, have shown that bilateral lenticular injuries can produce marked postural deficits (25,26). Selective bilateral cooling of the GP (27) induces an impairment of manual loading tasks, possibly caused by a loss of postural adjustments in the proximal muscles.

Difficulties in turning on a horizontal plane (e.g., in bed) and gait impairment are characteristic of axial motor impairment (28). Postural disturbances, gait blocks, dysarthria, and hypomimicry are generally considered "axial" signs of Parkinson's disease (PD) (29,30), and were the main motor impairments in our patients. Lakke et al. (28) reported a discrepancy between axial and distal motricity in PD. However, axial motor impairment, with postural disorders, falls, and freezing generally appears at a late stage of PD (29), along with marked limb akinesia, and results in a gradual deterioration of parkinsonian motor ability despite systematic treatment with dopaminergic drugs and dopaminergic agonists (31). L-dopa failed to improve the axial symptoms in our patients, contrary to PD (31), but

the absence of axial and limb rigidity contrasts with the classical features of old parkinsonian syndrome. Gait blocks in PD have generally been considered as symptoms of akinesia (28). Here, the gait blocks were not explained by leg or trunk stiffness. Although a few investigators (32) have suggested that axial akinesia could be a consequence of rigidity, cases of pure akinesia with motor blocks and gait disturbances without rigidity have been described in extrapyramidal degenerative diseases (33) and in vascular parkinsonism (34).

Parkinsonian patients generally find it difficult to initiate and execute simultaneous or sequential programmed motor tasks (35,36). These difficulties have been related to disturbances in basal ganglia function (37). Gait and speech, two types of bilateral, synchronized complex motor tasks, were the main impairments in our patients. Brotchie et al. demonstrated the role of the GP in initiation and execution of sequential limb movements by intraneural recordings (38). Thus, impairment of gait and speech could be a consequence of a difficulty in executing sequential fractions of movement or alternative movements (39) after lesions of the GP. This possible impairment of sequential movements was also illustrated by the presence of micrographia, despite little distal limb akinesia.

The wide spectrum of clinical expression after lesions of the GP is probably a result of its partitioning into various sensorimotor or associative territories (40). Disruption of striatopallidal projections by a massive lesion could occur. The supplementary motor area (SMA) is one of these projections, via the thalamus (41). It has been suggested that disruption of the pallidothalamus-SMA connection could lead to the impairment of gait or speech initiation (42). Other targets of pallidal projections as the pedunculopontine nucleus could be involved in postural control (43,44). The role of associated axonal lesions within the GP, e.g., striatonigral or nigrostriatal lesions, remains to be determined.

In conclusion, limited bilateral hypoxic injuries of the GP form valuable pathophysiological models for understanding the axial motor impairment in extrapyramidal syndromes. Although associated lesions, especially in cortical structures, could not be ruled out, the description of patients with circumscribed and apparently exclusive lesions of the GP underlines the role of this structure in the control of bradykinesia, axial motion, posture, and initiation of gait and speech.

Acknowledgment: We wish to thank Prof. G. Rancurel and Dr. J. Mallecourt for referring the patients, Prof. B. Dubois for useful discussions of the cases, and Clara Bazzinotti for preparing the manuscript.

LEGENDS TO VIDEOTAPE

Segment 1: Patient 1 showed severe bradykinesia, predominant on lower limbs. Gait was markedly impaired by slowness and freezing phenomenon.

Segment 2: Patient 2 disclosed freezing phenomenon and postural instability during half turns. No akinesia of upper limbs could be seen. Speech was whispered and pallilalic. For instance, to the first question ("quel est votre métier?" i.e., what is your job?) the patient repeats three times the answer ("je suis préparatrice en pharmacie" i.e., I am a chemist's assistant).

REFERENCES

1. Bierley JB, Graham D. Hypoxia and vascular disorders of the central nervous system. In: Adams JH, Corsellis JAN, Duchon LW, eds. Greefield's neuropathology. 4th ed. New York: John Wiley and Sons, 1984:131-133.
2. Wallays C, Fève A, Boughdène F, Fénelon G, Guillard A, Bigot JM. Selective vulnerability of striatopallidal structures to hypoxic ischemic injuries; Neuroradiological assessment of 12 cases by MRI and CT scan. *J Neuroradiol* (in press).
3. Boylan KB, Chin JH, De Armond SJ. Progressive dystonia following resuscitation from cardiac arrest. *Neurology* 1990; 40:1458-1461.
4. Durand MCh, Vercken JB, Goulon M. Syndrome extra pyramidal après incompétence cardio circulatoire. *Rev Neurol* (Paris) 1989;145:398-400.
5. Hawkers K, Lang AE. Hypoxic-ischemic damage of the basal ganglia. Case reports and a review of the literature. *Movement Disorders* 1990;5:209-224.
6. Ginsberg MD, Myers RE, McDonagh BF. Experimental carbon monoxide encephalopathy in the primate II. Clinical aspects, neuropathology, and physiologic correlations. *Arch Neurol* 1974;30:209-216.
7. Lapresle J, Fardeau M. Anatomical study of brain lesions following intoxications with carbon monoxide (22 cases). In: Bour H, Ledingham MCA, eds. *The central nervous system and carbon monoxide poisoning. Progress in brain research*. Amsterdam: Elsevier Science Publishers, 1967;24:31-73.
8. Ginsberg MD, Whyte TH, Richardsson EP. Hypoxic-ischemic leukoencephalopathy in man. *Arch Neurol* 1976; 33:5-14.
9. Meralgno Filho R. Sur quelques aspects des troubles de la détermination volontaire. *Arqu Neuropsychiatr* 1948;61:334-351.
10. Fahn S, Elton RL, and members of the UPDRS Developmental Committee. Unified parkinson's disease rating scale. In: Fahn S, Marsden CD, Calne D, Goldstein M, eds. *Recent developments in parkinson's disease*. vol. 2. Florham Park, NJ: Macmillan Healthcare Information, 1987:153-163.
11. Steele JC. Progressive supranuclear palsy. *Brain* 1972;95: 693-704.
12. Denny-Brown D. *The basal ganglia and their relation to disorder of movement*. New York: Oxford University Press, 1962.
13. Jellinger K. Exogenous lesions of the pallidum. In: Vinken PJ, Bruyn JW, Klawans HL, eds. *Handbook of clinical neu-*

- rology. vol. 49. Amsterdam: Elsevier Science Publishers, 1986.
14. Schwartz A, Hennerici M, Wegener OH. Delayed choreoathetosis following acute carbon monoxide poisoning. *Neurology* 1985;35:98-99.
 15. Davous P, Rondot P, Mauvin MH, Gueguen B. Severe chorea after carbon monoxide poisoning. *J Neurol Neurosurg Psychiatr* 1986;49:206-208.
 16. Fahn S. Post-hypoxic action myoclonus: literature review update. In: Fahn S, Marsden CD, VanWoert MH, eds. *Advances in neurology*. vol. 43. New York: Raven Press, 1986;157-170.
 17. Pulst SM, Walshe TM, Romero JA. Carbon monoxide poisoning with features of Gilles de la Tourette's syndrome. *Arch Neurol* 1983;40:443-444.
 18. Uitti RY, Rajput AH, Rozdilsky B. Cyanide induced parkinsonism: a clinicopathological report. *Neurology* 1985;35:921-925.
 19. Peters HA, Cevine RL, Matthews CG, Chapman LJ. Extrapyramidal and other manifestations associated with carbon disulfide fumigant exposure. *Arch Neurol* 1988;45:537-540.
 20. Laplane D, Baulac M, Widlöcher D, Dubois B. Pure psychic akinesia with bilateral lesions of basal ganglia. *J Neurol Neurosurg Psychiatr* 1984;47:377-385.
 21. Laplane D, Levasseur M, Pillon B, et al. Obsessive compulsive and other behavioral changes with bilateral basal ganglia lesions: a neuropsychological, magnetic resonance imaging and positron tomography study. *Brain* 1989;112:699-725.
 22. Klawans HL, Stein RW, Tanner CM, Goetz CG. A pure parkinsonian syndrome following acute carbon monoxide intoxication. *Arch Neurol* 1982;39:302-304.
 23. Aizawa H, Kwak S, Shimizu T, et al. A case of adult onset pure pallidal degeneration I. Clinical manifestations and neuropathological observations. *J Neurol Sci* 1991;102:76-82.
 24. Labadie EL, Awerbuch GI, Hamilton RH, Rapcsak SZ. Falling and postural deficits due to acute unilateral basal ganglia lesions. *Arch Neurol* 1989;46:492-496.
 25. Maclean PD. Effects of lesions of globus pallidus on species-typical display behavior of squirrel monkeys. *Brain Res* 1978;194:175-196.
 26. Martin JMP. *The basal ganglia and posture*. London: Pitman Publishing, 1967.
 27. Beaubaton D, Trouche E, Amato G, Legallet E. Perturbations du déclenchement et de l'exécution d'un mouvement visuellement guidé chez le babouin, au cours du refroidissement ou après lésion du segment interne du globus pallidus. *J Physiol (Paris)* 1981;77:107-118.
 28. Lakke JPWF. Axial apraxia in Parkinson's disease. *J Neurol Sci* 1985;69:37-46.
 29. Guillard A. Le "déclin" des parkinsoniens traités par la L-Dopa. *Nouv Presse Méd (Paris)* 1975;4:2503-2506.
 30. Agid Y. Parkinson's disease: pathophysiology. *Lancet* 1991;337:1321-1324.
 31. Weinrich M, Koch K, Gaveia F, Angel RW. Axial versus distal motor impairment in Parkinson's disease. *Neurology* 1988;38:540-545.
 32. Narabayashi H. Clinical analysis of akinesia. *J Neurol* 1980;16(suppl):129-136.
 33. Imai H. Frozen gait in Parkinson's disease. *Neurol Med Chir (Tokyo)* 1976;4:309-318.
 34. Fitzgerald PM, Jankovic J. Lower body parkinsonism: evidence for vascular etiology. *Movement Disorders* 1989;4:249-260.
 35. Schwab RS, Chafetz ME. Control of two simultaneous voluntary motor acts in normals and in parkinsonism. *Arch Neurol Psychiatr* 1954;72:591-598.
 36. Hallett J, Khoshbin SA. A physiological mechanism of bradykinesia. *Brain* 1980;103:301-314.
 37. Marsden CD. The mysterious motor function of the basal ganglia: the Robert Wartenberg lecture. *Neurology* 1982;32:514-539.
 38. Brotchie P, Iannsek R, Horne MK. Motor function of the monkey globus pallidus: cognitive aspects of movement and phasic neuronal activity. *Brain* 1991;114:1685-1702.
 39. Benecke R, Rothwell JC, Dick JPR, Day BL, Marsden CD. Disturbance of sequential movements in patients with Parkinson's disease. *Brain* 1987;110:361-379.
 40. Percheron G, Yelnick J, Francois C. A Golgi analysis of the primate globus pallidus. III. Spatial organization of the striatopallidal complex. *J Comp Neurol* 1984;227:214.
 41. Schell GR, Strick PL. The origin of thalamus inputs to the arcuate premotor and supplementary motor areas. *J Neurosci* 1984;4:539-560.
 42. Goldberg G. Supplementary motor area structure and function: review and hypothesis. *Behavioral and Brain Sciences* 1985;8:567-616.
 43. Jellinger J. The pedunculopontin nucleus in Parkinson's disease, progressive supranuclear palsy and Alzheimer disease. *J Neurol Neurosurg Psychiatr* 1988;51:540-543.
 44. Zweig RM, Jankel WR, Hedreen JC. The pedunculopontine nucleus in Parkinson's disease. *Ann Neurol* 1989;26:41-46.