

Emergent Aneurysmal Surgery Without Preoperative Angiography: Usefulness of the Intraoperative Portable Digital Subtraction Angiography

Satoshi Ayuzawa, M.D.,¹ Akira Matsumura, M.D.,² and Tadao Nose, M.D.³

Department of Neurosurgery, Moriya-Daiichi General Hospital,^{1,2} and Department of Neurosurgery, Institute of Clinical Medicine, University of Tsukuba,³ Ibaraki, Japan

Ayuzawa S, Matsumura A, Nose T. Emergent aneurysmal surgery without preoperative angiography: usefulness of the intraoperative portable digital subtraction angiography. *Surg Neurol* 1993;40:251-4.

A 42-year-old male with subarachnoid and large intracerebral hemorrhage in coma was operated without preoperative angiography because of impending cerebral herniation. After emergent decompressive craniotomy, intraoperative digital subtraction angiography (DSA) was performed and a middle cerebral artery aneurysm was demonstrated clearly. Aneurysmal neck clipping was successfully performed, and the patient made a good recovery and returned to almost independent activity with minimal hemiparesis. The prognosis of patients with ruptured aneurysm with large intracerebral hematoma is affected by early hematoma evacuation. Since the time spent for preoperative angiography may cause irreversible damage to the brain stem, in such case, early decompressive procedure and subsequent aneurysm diagnosis by intraoperative DSA may be used as alternative method to achieve a good outcome.

KEY WORDS: Cerebral aneurysm; Cerebral herniation; intracerebral hematoma; Intraoperative angiography; Portable digital subtraction angiography; Subarachnoid hemorrhage

Case Report

This 42-year-old male was brought to our emergency room after experiencing a sudden loss of consciousness as he was driving a small bus. The Glasgow Coma Scale (GCS) [7] on arrival was 14; he had a deep skin laceration on his right face. His pupils were equal and reacted promptly to light and he had a slight left hemiparesis. Computed tomographic (CT) scans showed a right temporoparietal hematoma in the sylvian fissure and diffuse

subarachnoid hemorrhage (SAH) (Figure 1). Rupture of a cerebral aneurysm was suspected and cerebral angiography was planned immediately. During preparation of the angiography, however, the patient vomited and became unconscious. His pupils were dilated and fixed, and he showed bilateral decerebrate posture. He was intubated, hyperventilated, and given Mannitol intravenously, but he remained comatose. Emergent CT scans showed an increase in the volume of the hematoma (Figure 2). Rapid progression of the cerebral herniation with brain stem compression was suspected. Angiography was canceled; he was brought to the operating room immediately, where a large frontotemporal craniotomy and dural incision were performed for decompression of the brain stem. Then right carotid angiography was carried out using a portable digital subtraction angiography (DSA) system (DFA-S and DHF-123CV, manufactured by Hitachi-Medico, Tokyo, Japan) by direct carotid puncture method. DSA, which were taken from three different directions, showed a right middle cerebral artery (MCA) trifurcation aneurysm (Figure 3). The operative field could be kept clean during the examination and it took about 15 min for the whole procedure. The large hematoma was evacuated and the neck clipping of the aneurysm was successfully performed. DSA after the aneurysmal clipping showed the disappearance of the aneurysmal dome and the patency of normal branches (Figure 4). The wound was closed without replacement of the bone flap for decompression. Dilatation of pupils disappeared soon after the operation but the right pupil remained slightly larger than the left for 3 weeks. The patient was managed under barbiturate-induced coma for 14 days postoperatively. Conventional cerebral angiography, which was performed 2 months after operation (Figure 5), showed successful clippings of the aneurysm. A ventriculoperitoneal shunt was performed for communicating hydrocephalus. His state of consciousness gradually improved and he became alert 2 months after the first operation. The left hemiplegia improved to the point that he could walk with canes by the time he was referred to an outside rehabilitation center.

Address reprint request to: Satoshi Ayuzawa, Department of Neurosurgery, Institute of Clinical Medicine, University of Tsukuba, 1-1-1 Tennodai, Tsukuba Science City, Ibaraki, 305, Japan.

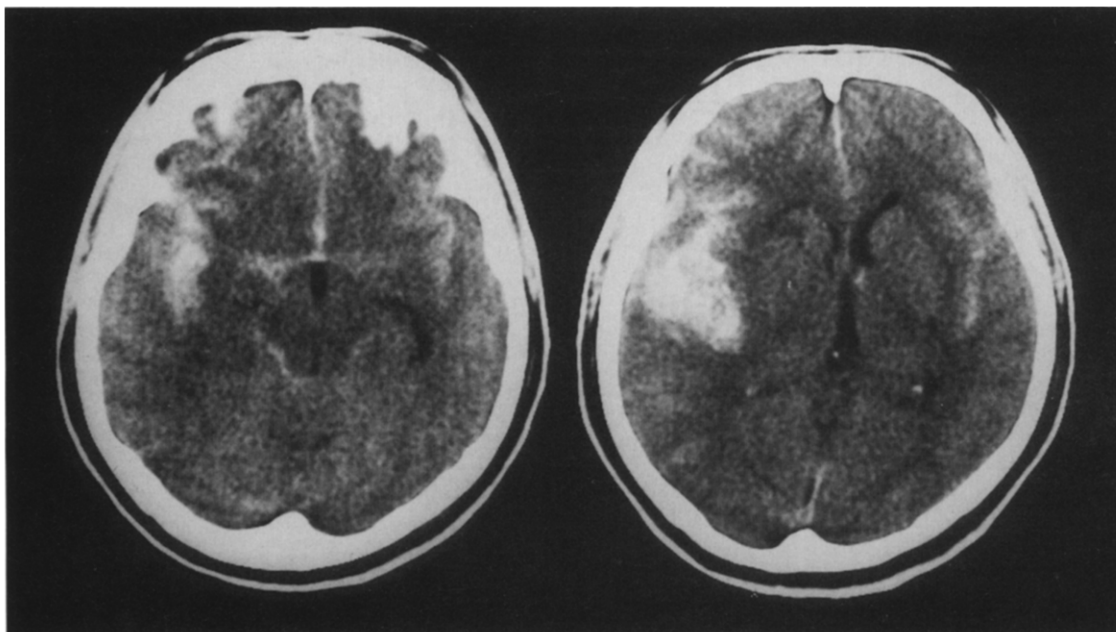
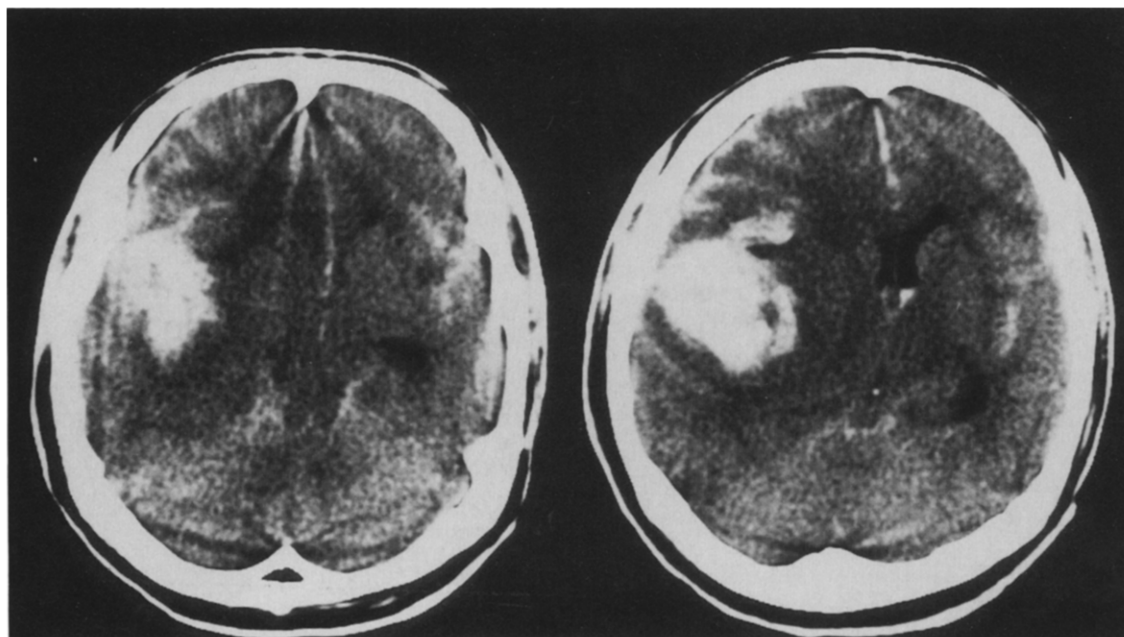


Figure 1. CT scan on arrival revealing a right temporal hematoma and diffuse SAH.

Figure 2. CT scan after rerupture demonstrating a massive hematoma and marked mass effect.

Discussion

The prognosis of patients of SAH associated with cerebral hematoma is affected by early hematoma evacuation for decompression, especially those patients with Hunt and Kosnik [6] grade 4 or 5 [4,8,12]. It is controversial whether preoperative angiography should be done when cerebral herniation due to large hematoma is in progress. Brandt et al. [2] reported four cases of ruptured MCA aneurysm with cerebral hematoma in younger patients.



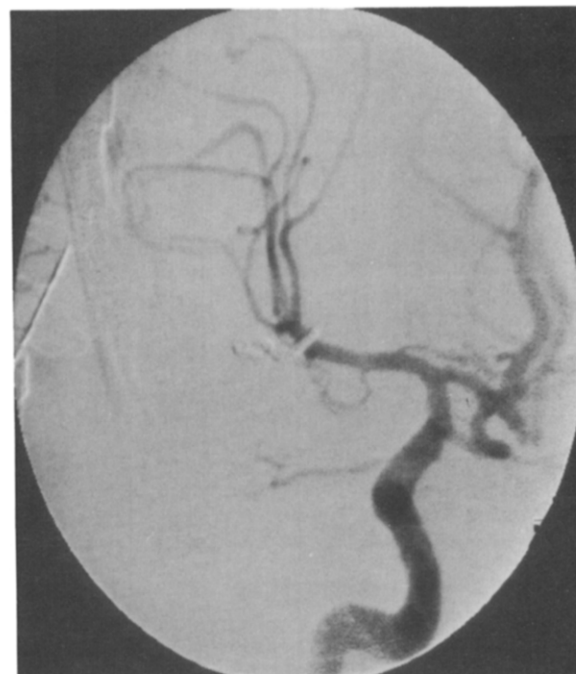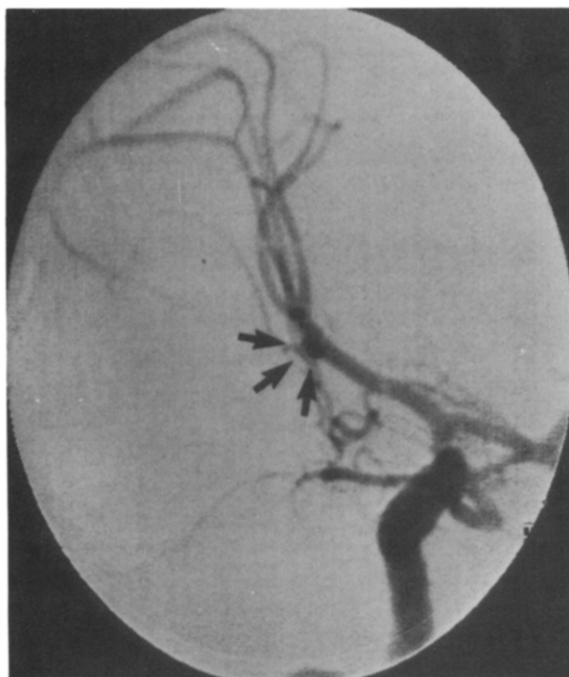


Figure 3. *Intraoperative portable DSA showing aneurysm at right MCA (arrows).*

Figure 4. *DSA after clipping showing disappearance of aneurysmal dome. The patency of normal vessels is seen.*

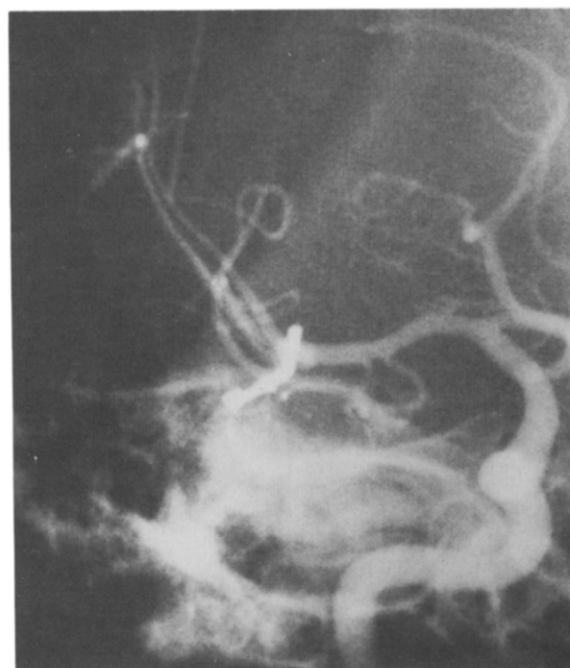Although they were treated without pre- and/or intraoperative angiography, they had better outcomes than expected. In addition, Batjer et al [1] reported four surgical cases of SAH with cerebral hematoma that were operated on without preoperative angiography. In both series, the purpose of omitting preoperative angiography was to save time for surgical decompression. In one case from Batjer et al [1], however, sylvian fissure was dissected first to find an aneurysm, but it turned out to be an internal carotid aneurysm. Although one can operate in such cases without preoperative angiography expecting a MCA aneurysm, in the majority of cases, operations without knowing the localization of aneurysm are difficult. It is clear that if angiography can be easily obtained after decompressive procedure, a more focused and safe surgery can be performed.

In recent years, some authors reported the efficiency of intraoperative portable DSA for diagnosis and treatment of intracranial vascular lesions [3,5,9,10,11].

We are using the intraoperative portable DSA via the femoral Seldinger approach for aneurysm surgery and other vascular malformations almost routinely in our institution. It can also be performed with direct puncture of the carotid artery of the involved site without disturbing the operating field within about 20 min. A portable DSA unit is installed in the operating room and using C-arm fluoroscopy we can take intraoperative angiography from various directions according to the operative position of the patient and the type of aneurysm.

In this reported case, we performed intraoperative DSA soon after external decompression and successfully operated with "angiographic guide". Intraoperative DSA also could be used in cases in which the intraoperative

Figure 5. *Postoperative conventional angiography showing successful clipping. Two months postoperative.*



aneurysmal findings are uncertain or negative after hematoma evacuation. It is still controversial whether our method could improve the outcome of such emergent aneurysmal surgery; thus further experience with a large number of cases of ruptured aneurysm with intracerebral hemorrhage is required to confirm the advantage of these methods.

References

1. Batjer HH, Samson DS. Emergent aneurysmal surgery without cerebral angiography for the comatose patient. *Neurosurgery* 1991;28:283-7.
2. Brandt L, Sonesson B, Ljunggren B, Säveland H. Ruptured middle cerebral artery aneurysm with intracerebral hemorrhage in younger patients appearing moribund: Emergency operation? *Neurosurgery* 1987;20:925-9.
3. Foley KT, Cahan LD, Hieshima GB. Intraoperative angiography using a portable digital subtraction unit. *J Neurosurg* 1986;64:816-8.
4. Heiskanen O, Poranen A, Kuurne T, Valtonen S, Kaste M. Acute surgery for intracerebral haematomas caused by rupture of an intracranial arterial aneurysm. *Acta Neurochir* 1988;90:81-3.
5. Hieshima GB, Reicher MA, Higashida RT, Halbach VV, Cahan LD, Martin NA, Frazee JG, Rand RW, Bentson JR. Intraoperative digital subtraction neuroangiography: A diagnostic and therapeutic tool. *AJNR* 1987;8:759-67.
6. Hunt WE, Kosnik EJ. Timing and perioperative care in intracranial aneurysm surgery. *Clin Neurosurg* 1977;21:79-89.
7. Jennett B, Teasdale G. Aspect of coma after severe head injury. *Lancet* 1977;1:878-81.
8. Kawamura S, Suzuki A, Sayama I, Yasui N. Clinical significance of intracerebral hematomas following aneurysmal rupture. *Neurol Med Chir (Tokyo)* 1987;27:1158-66.
9. Kirsch WM, Zhu YH. Intraoperative digital subtraction angiography for neurosurgery. *West J Med* 1990;153:547-8.
10. Martin NA, Bentson J, Vinuela F, Hieshima G, Reicher M, Black K, Dion J, Becker D. Intraoperative digital subtraction angiography and the surgical treatment of intracranial aneurysm and vascular malformations. *J Neurosurg* 1990;73:526-33.
11. Meguro K, Matsumura A, Tsurusima H, Matsumaru Y. Demonstration of a vascular lesion by intraoperative portable DSA in a case of intracerebral hematoma with impending herniation. *Neurol Surg* 1990;18:453-6.
12. Pasqualin A, Bazzan A, Cavazzani P, Scienza R, Licata C, Pian RD. Intracranial hematomas following aneurysmal rupture: Experience with 309 Cases. *Surg Neurol* 1986;25:6-17.