

THE FUZZY BOUNDARIES OF APPERCEPTIVE AGNOSIA

Ennio De Renzi¹ and Federica Lucchelli²

(¹Neurology Department, University of Modena; ²Neuropsychology Unit, Department of Neurology, Clinica del Lavoro Foundation, Medical Center of Veruno, Novara)

Until recently the variety of visual recognition disorders arising from hemisphere damage has been thought to be adequately classified by the dichotomy between apperceptive and associative agnosia, first proposed by Lissauer (1890) with reference to the stage at which the process of stimulus identification was disrupted. Apperceptive agnosia covers cases of impaired recognition due to the failure to achieve a fully specified percept from visual information, in spite of adequate, or at least not severely impaired elementary sensory abilities, whereas associative agnosia encompasses disorders of recognition in which the stimulus is correctly perceived and yet fails to arouse the attributes that assign it a meaning. This distinction is ostensibly neat, but, when applied to clinical facts, it runs into difficulty (Kertesz, 1979). A major matter of disagreement concerns the definition of the boundaries of apperceptive agnosia, with respect to both the early stages of sensory data processing and its delimitation from associative agnosia.

The traditional position has been to assign the diagnosis of apperceptive agnosia to patients who, despite normal, or at least adequate, visual acuity and visual fields, have difficulty in discriminating the shape of simple stimuli, as shown by their inability not only to recognize them but also to match and copy items, and to make “same”/“different” judgments. Warrington (1985) took exception with this view, claiming that disorders in achieving a two-dimensional description of visual forms indicate a deficit affecting the early stages of perceptual processing and lying outside the domain of true apperceptive agnosia, for which the label of “pseudoagnosia” would be more appropriate. In the computational approach to vision proposed by Marr (1982), this type of disorder would correspond to an impairment at the level of the primal sketch, which encodes the local organization of boundary elements in the visual field, or of the 2 1/2 sketch, which takes into account the depth and orientation of the visible surfaces.

On this account, the word “agnosia” is better reserved for a disruption occurring at a later stage of the visual process, where a volumetric representation of the stimulus, articulated in its component parts and independent of the viewer’s position, is constructed and compared with its analogue stored in long-term memory (the 3-D model in Marr’s terms). It would be the availability of 3-D

models in the catalogue of known object forms that allows the subject to recognize that stimuli seen through different perspectives or with different completeness of appearance belong to the same object. Patients with apperceptive agnosia were operatively defined (Warrington and James, 1988) as those passing the Efron (1969) shape discrimination test, where a square and an oblong having the same total flux must be distinguished, and the Warrington and Taylor's (1973) shape detection test, where a fragmented X or O superimposed upon a random pattern background must be perceived as present or absent. These tests are typically failed by pseudoagnosics and passed by apperceptive agnosics, whose impairment would emerge when performance requires perceptual classification, e.g., the recognition of objects viewed from unusual perspectives. The degradation of structural descriptions also accounts for their poor performance on tasks (Gollin's incomplete outline drawings, foreshortened silhouettes, rotated shadow images) presenting images that have been so manipulated as to impoverish or obscure their critical, distinctive features, thus making it more difficult to arouse the corresponding templates. Warrington and James (1988) illustrated this condition with three patients, whose impairment on perceptual classification tests contrasted, on the one hand, with their intact shape discrimination and detection, and, on the other hand, with their preserved semantic knowledge of objects, provided they were presented in canonical views.

Such a radical change in the conceptualization of apperceptive agnosia is not, however, without problems. First, it entails the exclusion from its domain of practically all cases so diagnosed in the literature, in spite of the discontinuity and qualitative differences they show with respect to patients with mere sensory deficits (McCarthy and Warrington, 1990a). This may be considered, though, a problem of terminology. More importantly, the cases reported by Warrington and James (1988) as examples of apperceptive agnosia were in fact not agnosic, if the term must keep its original meaning: the inability to recognize visual stimuli. None of them was hampered in everyday life and all of them scored in the normal range when objects were presented in their conventional view, i.e., the view traditionally used to document the presence of visual agnosia. There must be some additional factor that accounts for the difference between Warrington and James's (1988) patients and the patient reported by Ratcliff and Newcombe (1982; see also Newcombe and Ratcliff, 1975; Newcombe, Young and De Haan, 1989), who failed to recognize 28 out of 36 line drawings of objects, in spite of being "virtually perfect" in matching identical objects and "remarkably accurate" in copying drawings. Knowing that he performed near chance in deciding whether a pair of pictures displaying objects photographed from a conventional or an unconventional view was the same or different, though interesting in its own right, does not help clarify why his canonical view recognition was impaired, while that of Warrington and James's patients was not.

Finally, if the criterion for the diagnosis of apperceptive agnosia is the failure on perceptually demanding tasks, then we run into the problem of how to discriminate this deficit from that shown by several patients labelled in the literature as associative agnosics, who also are impaired on these tests. The integrity of the perceptual level was usually inferred from their flawless (but often very slow) performance on matching and copying tasks, i.e., the tasks that, in

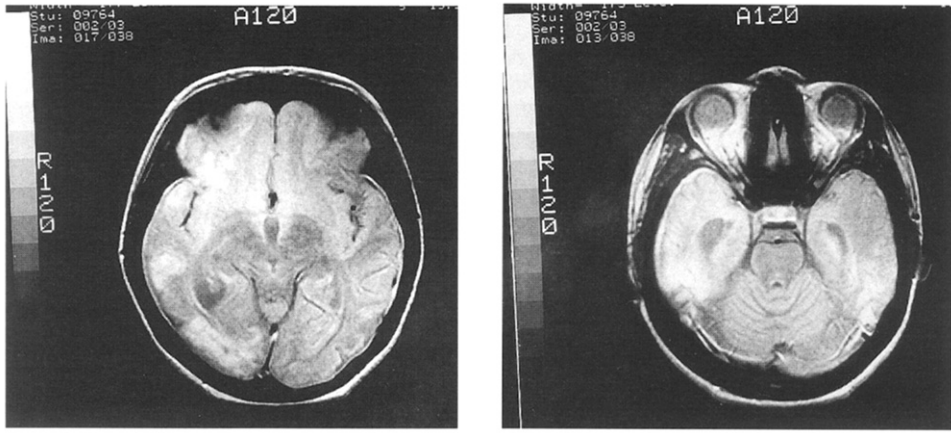


Fig. 1 – MRI slices.

Warrington's view, are only failed by pseudoagnosics. However, as Farah's (1990) review has convincingly pointed out, their performance was disrupted when higher levels of perception were tested.

In spite of these queries, Warrington's (1985) position in keeping the patients traditionally labelled apperceptive agnosics separate from other patients who are able to perceive bidimensional shapes, but fail at later stages of perceptual processing, appears justified in the light of a few recent case reports of agnosia (Ratcliff and Newcombe, 1982; Riddoch and Humphreys, 1987a; Graillet, Seron, Bruyer et al., 1990). They have shown that when patients are examined with tests designed in accordance with the principles that are presumed to underlie the architecture of visual recognition, the fuzziness of the border separating apperceptive agnosia from neighbouring syndromes is alleviated and the need for more fine-grained taxonomy emerges. A few steps in this direction have been taken (Humphreys and Riddoch, 1987), but the dearth of adequately investigated cases prevents one from arriving at firm conclusions. We report a patient with severe impairment in object recognition in the hope of contributing to the clarification of this controversial issue.

CASE HISTORY

Annalisa is a 21-year-old girl, who after 8 years of schooling attended for 2 years a professional school of cookery and then worked with her parents in the restaurant they own. On August 8, 1988, she suffered a severe head injury in a traffic accident. Two days later, CT scan was reported to show haemorrhagic lesions in the basal areas of the right frontal and temporal lobes. She remained unconscious for a week, then progressively recovered, but her parents noticed that for a few months she showed disorders of language with verbal paraphasias and neologisms. In May 1989, a CT scan showed an area of hypodensity in the right temporo-occipital region. When first seen by us in September, 1989, the neurological examination disclosed a mild spastic paresis of the left lower limb, without sensory disturbances. Visual fields were full to confrontation and she no longer manifested signs of aphasia in spontaneous speech. Her main complaint was the inability to read and to recognize familiar faces and objects. She had to be helped even in the simplest cooking duties, because she frequently mistook foods or kitchen utensils. Memory for new events and of

previous knowledge (e.g., recipes) was poor. In the subsequent months, the paresis recovered completely and there was some improvement of reading and object recognition, while prosopagnosia remained severe. In November 1989, an MRI scan showed a remarkable widening of subarachnoid cortical and basal spaces and dilatation of the ventricular system (Figure 1). A large area of hyperlucency was seen in the temporo-occipital region of the right hemisphere. At 15-16 mm from the orbitomeatal line the lesion impinged upon the following cortical areas: 38, 21, 22, 37, 19. There was also a minimal involvement of areas 47 and 24 and a more marked one of area 6 that extended to the upper sections. In the upper sections areas of hyperlucency were visible bilaterally in the parasagittal region of the frontal and parietal lobes. This was the only evidence of damage to the left hemisphere.

Elementary Visual Functions

Visual field testing was normal to confrontation and on Goldman perimetry. Fundus oculi examination was normal in the left eye and showed a subatrophic papilla in the right eye.

Visual acuity was tested by asking the patients to report the orientation in space of a letter E and with the interferometric method. It was found to be 7-8/10 with the former procedure and 8-9/10 with the latter.

Visual evoked potentials were tested using sinusoid gratings with spatial frequencies from 1 to 8 cycles per degree, 100% contrast, 40 candles/m² intensity, and 1/sec frequency of stimulation. VEPs were present at each of the spatial frequencies tested. The P100 latencies and amplitudes for each frequency are reported in Table I.

TABLE I
P100 Latency and Amplitude of VEPs in the two Eyes

Right Eye	
P100 Latency	Amplitude
1 c/d 127.2	1.7 μ V
2 c/d 156.0	1.5 μ V
4 c/d 157.2	0.5 μ V
8 c/d 170.4	0.5 μ V
Left Eye	
P100 Latency	Amplitude
1 c/d 104.4	1.9 μ V
2 c/d 104.4	1.2 μ V
4 c/d 117.6	1.4 μ V
8 c/d 142.8	1.0 μ V

NEUROPSYCHOLOGICAL EXAMINATION

The patient was oriented in time and space and was very cooperative throughout testing.

Intelligence

Due to her visual recognition disorders, only the verbal scale of the WAIS-R was given. She achieved a VIQ of 82 in September 1989 and of 93 in June 1991. The lowest score was that of the Information subtest and it probably reflects the severe impairment of memory.

Language

Spontaneous speech was fluent and flawless. She scored 29/36 on the Token Test (cut-off 29), had a PFL verbal fluency score of 11 (cut-off 14), and a sentence repetition score of 18.5 (cut-off 15.5). While reading 21 letters yielded four errors consisting in visually similar letters (O for D, U for V, N for H and O for Q), 120 two-, three-, and four-syllable words were read with only two errors, and with latencies never exceeding 10 sec. Letter-by-letter reading was never observed. She could read out and understand short stories. Writing to dictation and the spontaneous writing of a letter to a friend were free of error.

Praxis

She scored in the normal range both on a gesture imitation task (De Renzi et al., 1980) and on a test where she mimed the use of objects named by the examiner. The scores were 63/72 and 20/24, respectively.

Memory

A short story was poorly recalled: 8 elements out of 26 in the immediate recall and 1 element after a 10 minute delay. A 10-word list was not learned in 20 trials, but the mean word recall per trial (corrected for age and years of schooling) was 7.49, above the cut-off of 6.58 found in normals. Paired-associate learning in three trials yielded a corrected score of 7.53, below the cut-off point of 8.73 (De Renzi et al., 1977).

Spatial Abilities

There was no sign of neglect, misreaching and topographical disorientation. Her ability to copy drawings (see below) excluded gross visuo-spatial disorders. Immediate spatial memory (Corsi's cube tapping test) was 4. A supraspan (span +2) sequence of cubes was learnt to criterion in 19 trials, a rather poor performance, but still in the range of the normal distribution.

The main complaint of Annalisa was prosopagnosia, which was manifest and embarrassing in everyday life. The study of this symptom has been reported elsewhere (De Renzi, Faglioni, Grossi et al., 1991) and the interested reader is referred to that paper for further details.

EXPERIMENTAL INVESTIGATION

The patient was first tested in September, 1989 and was followed throughout 1990 and the first half of 1991. Tests that were correctly performed in September 1989 were no longer repeated; those that elicited impairment were given again. A group of 10 girls matched for age and educational level was used for comparison on those tests for which cut-off scores, derived from administration to large samples of normal subjects, were not available.

Object Recognition through Different Modalities

In this section we will report on Annalisa's ability to name objects in response to different types of information: visual, tactile, acoustic, pantomimes displaying their use, and verbal description. Object and picture visual recognition, object tactile recognition and object naming on verbal description were assessed with a set of 30 common, manipulable objects and their coloured photographs, for which De Renzi, Zambolin and Crisi (1987) have established the cut-off points discriminating a normal from a pathological performance in 70 non-brain-damaged subjects. A correct identification was scored 2 if given in 10 sec., 1 if given in 11-30 sec. Sound and pantomime recognition was tested with partially different sets of objects, chosen to be easily identifiable through their sound or the gesture with which they are used. If the patient was unable to retrieve the name of the item, she was encouraged to use circumlocutions or definitions of function that were suitable to demonstrate its recognition, but only exceptionally did this device improve her performance.

Table II shows Annalisa's scores on the four versions of the 30 item test, obtained in September 1989 and June 1991. Both scores graded for time of response and raw scores are given. In September 1989 her performance was below the cut-off points in all modalities, but the severity of the deficit varied from test to test, being highest in those involving vision and decreasing in the non-visual tests, particularly the verbal one. This was confirmed by χ^2 analysis. The χ^2 of the table was highly significant: 24.50, $p < .001$ with 3 d.f. Partitioning the 3 d.f., we contrasted 1) the visual tests against the non-visual tests: $\chi^2 = 15.04$, $p < .001$ with 1 d.f., 2) visual objects against photographs: $\chi^2 = 5.04$, $p < .05$ with 1 d.f., 3) tactile objects against verbal description: $\chi^2 = 4.42$, $p < .05$ with 1 d.f. In June 1991, there was an improvement in all modalities, but only on the verbal one was the performance practically normal. The overall χ^2 was 25.37 ($p < .001$). Visual test scores were poorer than non-visual test scores ($\chi^2 = 15.29$, $p < .001$), photographs than objects ($\chi^2 = 5.62$, $p < .02$) and tactile responses than verbal responses ($\chi^2 = 4.45$, $p < .05$).

It is worth mentioning that tactile errors cannot be attributed to defective processing of the somatosensory input, since when in September 1989 the same objects were handed out of vision for matching with one of four photographs, the patient scored 27/30. The discrepancy with respect to the score of 14/30 in the tactile naming task is striking and highly significant: $\chi^2 = 13.02$, $p < .001$, with 1 d.f.

Error types were categorized as semantic, visual, visual-semantic, unrelated and no response (Table III). For visually presented stimuli the most numerous class was by far that of no response, which corresponded either to no verbalization, or to an attempt to give an approximate and coarse description of the material, the color, or the shape of the stimulus (e.g., *candle*: a white stripe... it seem to be plastic; *match*: it seems to be wood... with a red stripe). With visual stimuli no semantic error occurred, whereas there were some visual errors and very few visual-semantic errors.

Object sound recognition was assessed with a 24-item test which has been

TABLE II
Recognition across Modalities

	Annalisa		Cut-off score
	Sept. 1989	June 1991	
Visual objects	17/60 (9/30)	32/60 (17/30)	55/60
Visual pictures	8/60 (4/30)	16/60 (8/30)	46/60
Tactile objects	28/60 (14/30)	32/60 (19/30)	53/60
Verbal naming	42/60 (22/30)	53/60 (27/30)	54/60
Sounds	18/24	—	16/24
Pantomimes	7/24	13/24	21/24
Verbo-visual matching			
a) semantic distractors	28/30		30/30
b) perceptual distractors	22/30		30/30

Numbers in brackets of the naming tests are raw scores, without time credit.

TABLE III
Types of Naming Errors (September 1989)

	Semantic	Visual	Visual semantic	Unrelated	No response
Objects	0	3	2	2	14
Photographs	0	3	1	4	17
Tactile	2	5	3	3	3

standardized on 100 control subjects (Palmieri, 1986) in a version where a sound has to be matched with the picture of its source, presented with three distractors. This procedure was not appropriate for Annalisa, owing to her visual impairment. We therefore asked her to name the source of the sound. Since this change in procedure is unlikely to make the test easier, the cut-off point of 16 established in normals with the original version of the test was retained. The patient performed in the normal range: 18/24 (Table II).

Pantomime recognition was assessed with a 24-item test (Tundo, 1986), in which the examiner mimed the use of an object that the patient was required to name. Also this test has been standardized on 100 normals with a pantomime-picture matching procedure, presenting the picture of the object with three distractors. The cut-off score is 21/24 and Annalisa was severely impaired: 7/24 (Table II). The deficit could not be attributed to the inability to evoke the gesture associated with an object, since, when the same objects were named by the examiner and she was requested to pantomime their use, her performance was correct (20/24). She could also imitate gesture made by the examiner.

The patient was also given a *verbo-visual matching task* where the object named by the examiner had to be indicated from among an array of pictures. Some, but not all, of the target-stimuli were drawn from the set used in the naming tests. There were two versions of the test: in one, the target was presented with three perceptually similar, but semantically dissimilar alternatives; in the other, with three semantically similar, but perceptually dissimilar alternatives. On both versions her performance was remarkably better than on visual

naming, but it was sensitive to the quality of distractors (Table II). She scored 22/30 with visual distractors and 28/30 with semantic distractors ($\chi^2 = 6.66$, $p < .01$ with 1 d.f.). Normals were flawless on both tasks.

A final test was *coin discrimination*. Fifty five coins, half Italian and half foreign, were scattered on the table and she was requested to sort them quickly into two heaps, without attempting to read the words engraved on them. She made 17 errors.

Comment

This first set of tests provides evidence that Annalisa is severely impaired in recognizing stimuli of different kinds (objects, pictures and pantomimes) presented in the visual modality, both when the recognition requires naming and when it requires verbal-visual matching. Error analysis of naming responses was scarcely informative about the stage at which disruption occurred, because they were mostly of the "don't know" type, but comparison of the two verbo-visual matching tasks suggests that the locus of functional damage was perceptual and not semantic.

When the information for recognition was conveyed through other sensory channels, she performed in the normal range with sounds, and was mildly defective on verbal description in the first examination but subsequently recovered; she showed an impairment of intermediate severity on the tactile recognition test. This deficit will be discussed later. For the time being, the finding that the number of errors was contingent on the input modality argues against a primary naming deficit and constitutes evidence in support of the diagnosis of agnosia, predominantly affecting visual information.

In the following sections we will try to identify the level at which the agnosic disruption occurs, by probing the patient's performance at different stages of visual information processing, from shape discrimination to access to the semantic store.

Unidimensional Discrimination Tests

We first tested the patient's ability to discern shape differences, determined by the variation of one dimension. Two tests were used (Figure 2). One was the Efron test, which was given following the procedure of Warrington and James (1988). Ten black squares, 50 mm \times 50 mm, and 10 black oblongs, 46 mm \times 55 mm, were mounted on white cards and presented in pseudo-random order, requesting the patient to decide whether the stimulus was a square, or an oblong. The second test was an arch test, derived from Talland (1958). It consisted of 9 vertically oriented oblongs, which ended at their upper side with an arch of graded sharpness. All possible combinations of two different figures, for a total of 36 pairs, were given to the patient who was requested to point to the sharpest member of the pair (Figure 2).

As shown by Table IV, Annalisa's performance was normal on both tests, indicating that her ability to make subtle discrimination of unidimensional perceptual differences was not impaired.

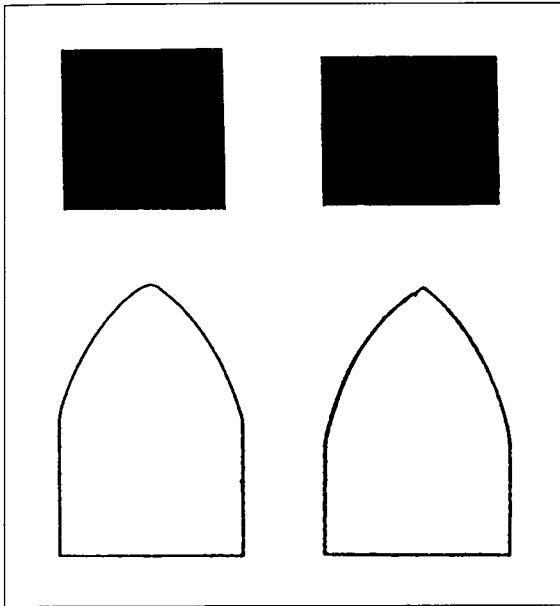


Fig. 2 – Efron test (top) and an item of Talland test (bottom).

TABLE IV
Performance on the Efron's Test and Talland's Test

	Efron (Mx: 20)	Talland (Mx: 36)
Annalisa	19	32
Controls (range)	15-20	32-36

Figure Matching and Same-Different Comparisons

The following set of tasks involved more complex visual material, which varied along multiple dimensions and was intended to assess shape perception at a level demanding careful inspection of the external configuration and the internal structure of the stimulus.

Object-Object Matching

The patient was asked to match an object with its identical pair, presented with three distractors, one or two of which had a similar shape (e.g., the alternatives for a clothes brush were a shaving brush, a whitewash brush and a comb). Twenty five items were given and the patient scored 25/25, giving quick responses.

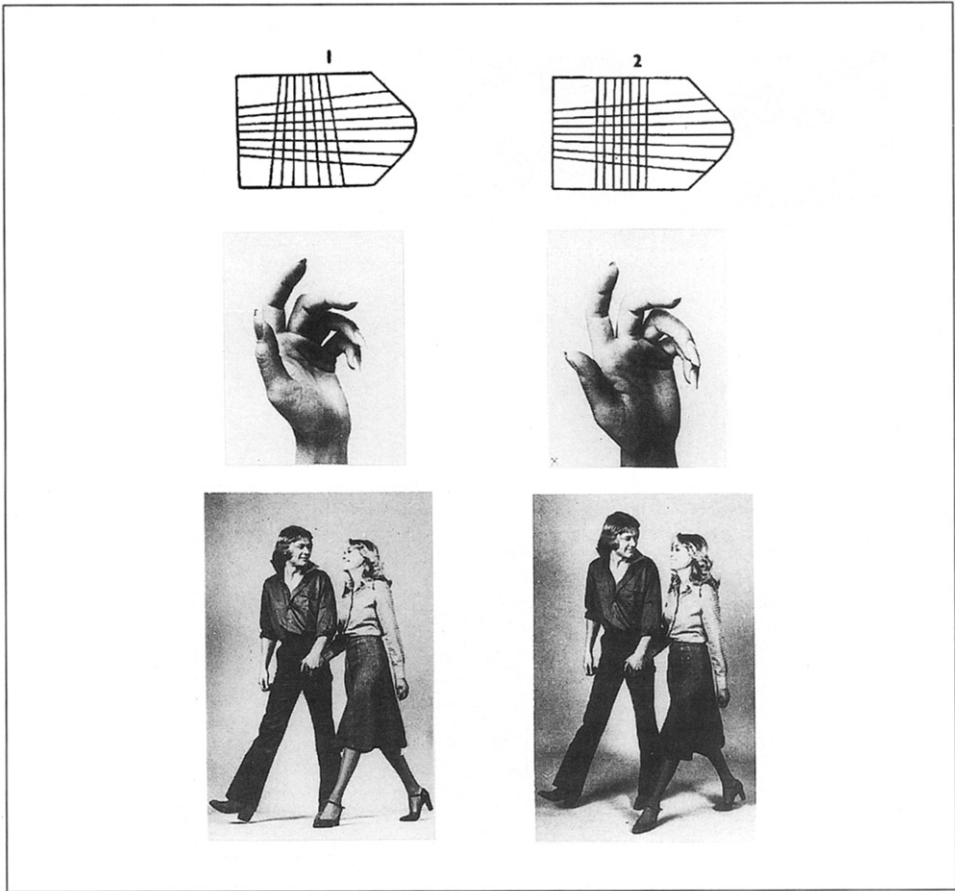


Fig. 3 – Examples of pairs with abstract figures, hands and couples.

Object-Figure Matching

The format was the same as that of the previous test, but the match had to be made between an object and its colored photograph presented with three distractors. Annalisa made 4 errors out of 25, gave 3 correct responses between 15 and 25 sec. and a correct response after 40 sec. The task was easy and flawless for control subjects.

Same-Different Discrimination

Three tests were given, in which the patient had to state whether pairs of figures were same or different. The stimuli were a) abstract designs from Raven Progressive Matrices (60 items), b) hand photographs variously oriented in space (44 items) and c) photographs of a young man and a girl walking side by side (42 items). The figures of the last two tests were taken from Fairburn Figures

(1987). Half of the pairs were same and half different, but remarkably similar in their general configuration (Figure 3).

Annalisa scored 56/60 on the Raven figures (controls from 55 to 60), 40/44 on hand figures (controls 41-43) and 38/42 on couple figures (controls 39-42). On the Raven and hand tests all correct responses were given in less than 10 sec.; on the couple test the delay was somewhat longer for the first 15 responses and then shortened to less than 10 sec.

Comment

Visuo-visual matching tasks are traditionally thought to assess the integrity of perception. They were successfully performed by the patient, who quickly arrived to a correct decision, without needing meticulous and length inspection of the stimuli. The only test where she showed a mild impairment was the object-figure matching test, which cannot be solved by identity matching, since it requires the transformation of the structured percept of a tridimensional stimulus into that of a bidimensional stimulus.

Copying

Another task that has been classically used to assess the pre-semantic processing of visual information is copying, since it does not imply the recognition of the model and just requires a correct perception of its global configuration and the spatial arrangement of its parts. Several authors (Ratcliff and Newcombe, 1982; Farah, 1990) have stressed that the qualitative analysis of performance is not less important than the evaluation of its end-product, since it may reveal that the patient proceeds by a slavish, line-by-line approach — betrayed by the exceedingly long time employed to execute the drawings and the reproduction of irrelevant details, suggesting a reproduction that is not guided by a structured percept of the model.


The patient was first requested to copy 10 geometrical drawings and the two Rey figures. Her performance was substantially correct and we did not notice signs of hesitation. She was also requested to reproduce 10 geometrical drawings that were shown for 5 sec. and then removed. A square, a triangle, a square with two diagonals, a cross and a Greek fret were reproduced without error; more complex designs were not.

She was then presented with 10 pictures from the Boston Naming Test, only one of which was recognized. Her drawings were somewhat crude and did not always respect the spatial relation between parts, but most of them were recognizable and were completed in a reasonable amount of time (Figure 4). The patient never lost her place in drawing.

Comment

The copying performance of Annalisa attests that she was able to achieve an adequate perceptual representation of the stimulus and to draw under its guidance, without relying on a time-consuming line-by-line approach.

Fig. 4 – Copy of one of the Rey figures and of drawings from the Boston Naming test.



Degraded Gestalt Perception

Patients with apperceptive disorders have been reported to be sensitive to conditions in which the identification of shape is made harder by the presence of extraneous lines or cross-hatching marks, or by degrading the contrast between the figure and its background and reducing the information contained in the stimulus. This appeared to be the case for Annalisa, even when she was not required to recognize the stimulus, but simply to detect its presence. Two types of test were used for this purpose. One was *Warrington and Taylor's (1973) shape detection test*, in which a fragmented letter (an X or an O) is superimposed upon a fragmented background, and the relative ratio of blackness to white in the figure and the background is varied. The test was given in two versions. In the former (A) the patient had to classify 33 cards as an X, an O or no figure. In the latter (B) she had to state whether a fragmented letter (X, or O) was superimposed on the background (22 items) or not (22 items). We do not have normative data for this version, but Warrington reports almost perfect scores (mean 19.92 out of a maximum of 20) in 60 control subjects (1991). Compared to normals, Annalisa was impaired on both versions of the test (see Table V).

The second test was modelled on *Ghent's (1956) overlapping figure test* and was presented in two versions, one made up of meaningful and the other of

meaningless figures. The meaningful test consisted of 10 displays, each presenting on the top a figure consisting of 3 to 5 overlapping drawings of objects belonging to the same category, and below 10 figures drawn in two columns and representing the same objects in isolation along with other exemplars of the category (Figure 5). The patient was requested to choose the figures present in the target from among the alternatives (maximum score: 40). The meaningless test was similarly constructed and presented 9 displays for a maximum score of 35. Annalisa's scores fell far below the range of the normal performance (Table V).

Comment

While disorders of perception were not brought out by performances involving same-different discrimination, matching and copying, they emerge when

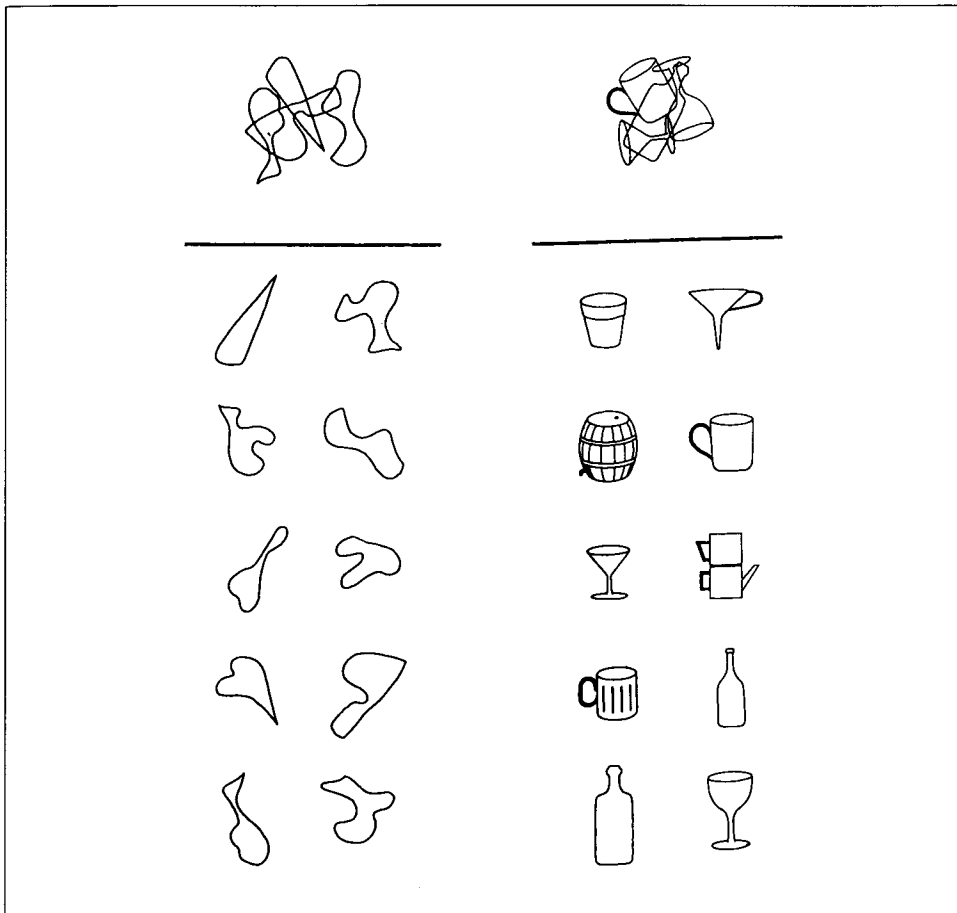


Fig. 5 – Examples from the meaningless (left) and meaningful (right) overlapping figure test.

TABLE V
Tests of Degraded Gestalt Perception

	Shape detection A (Mx: 33)	Shape detection B (Mx: 44)	Meaningful overlapping figures (Mx: 44)	Meaningless overlapping figures (Mx: 35)
Annalisa	20	36	21	15
Controls (range)	31-33	—	38-40	32-35

a gestalt must be disentangled from a confused background. It is worth noting that the meaningless overlapping figure test does not imply the ability to compare the figures with their stored structured representations, but simply to trace a good form without being deceived by intersecting lines. Impairment occurs, therefore, before accessing the visual store.

Possible-Impossible Figure Decision Test

Another task taxing the ability to extract from visual information the global, three-dimensional structural relations that define an object is the possible-impossible figure decision test (Schacter, Cooper and Delaney, 1990). It consists in the presentation of geometrical figures, half of which depict solids that could exist in three-dimensional space and half solids containing subtle surface and edge violations that would make their existence in space impossible (Figure 6). After a few items given for demonstration, 40 drawings, taken from Schacter et al. (1990), were presented individually, and the patient was asked to decide whether they could actually exist in the world.

Annalisa scored 19/40, at chance level, while controls' scores ranged from 34 to 40. Although the proportion of possible stimuli (40%) correctly recog-

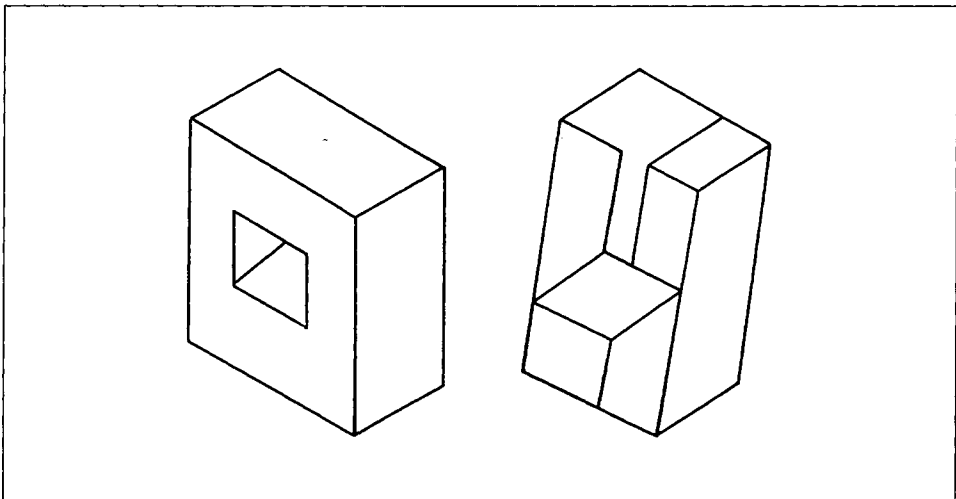


Fig. 6 – Examples from the possible-impossible figure decision test.

nized was lower than that of impossible stimuli (55%), the difference was not significant.

Testing the Pre-Semantic Representation Store with Visual Input

The next step was to verify whether stored abstract representations of objects were available to Annalisa for comparison with the structured percepts she derived from visual information processing. Since the pictorial data store is assumed to be pre-semantic, tasks designed to tap it must not demand the identification of meaning, but the mere knowledge of whether the stimulus form is familiar and exists in the world (object decision task) or a judgment of perceptual categorization, whereby prototypical and atypical representations are recognized as belonging to the same stimulus.

Object decision was tested with tasks involving two types of reality judgment: a) whether a shape was an object or a non-object, and b) whether it was a real object, or a "new" object, created by recombining the parts of two real objects (Humphreys and Riddoch, 1987).

The *object-non-object decision task* (Figure 7) was made up of 50 prototypical figures of objects or animals from Snodgrass and Vanderwart (1980) and 50 figures of non-objects that represented a high approximation to objects, drawn from a set constructed by Kroll and Potter (1984). Each figure was presented individually and the patient had to decide whether it existed or not. The controls' score was practically perfect (range 98-100). The patient made 25 errors

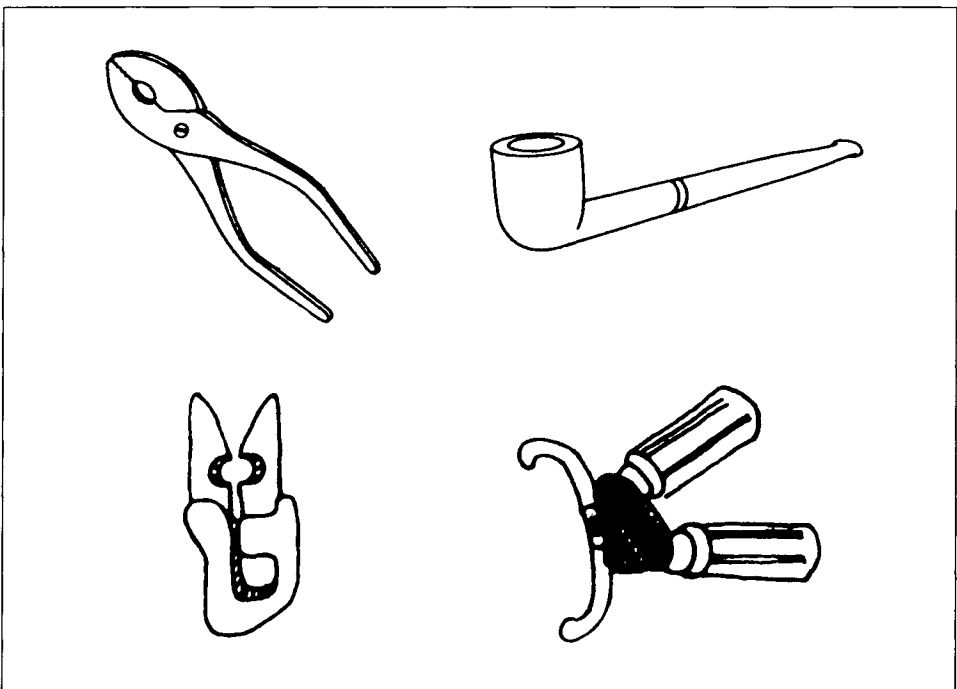


Fig. 7 – Examples from the object decision test.

out of 100 stimuli, which were unevenly distributed between the two categories: the correct response rate to non-objects was 92% as against 58% to objects ($\chi^2 = 15.41$, $p < .001$ with 1 d.f.). At the end of the test, she was again presented the 50 object items and requested to name or describe them. Only 14 of the 29 items judged real and none of the 21 items judged non-real were correctly identified.

The "new" object decision test consisted of two kinds of stimuli, 41 objects and 44 animals. In each case half figures were true objects or animals and half "new" objects or animals resulting from the substitution of a part of an object (or animal) with a part of another object (or animal). The two sets of stimuli were administered with different procedures. Object drawings were presented individually and a yes-no response was requested. Animal drawings were presented in pairs with a real animal coupled with a recombined animal and the patient had to point to the real one. The patient scored at chance on both subtests: the hit rate was 44% (18) for objects and 55% (24) for animals.

Perceptual Constancy

Conventional and unconventional views of the same object or of different objects were presented for a same-different decision. Thirty pairs were given, 15 same and 15 different. The patient scored 18/30 and was able to recognize just one object (it was the same in the conventional as well as in the unconventional presentation).

Comment

Annalisa has limited access to the catalogue of structured forms derived from previous experience with the perceptual world, which affords the basis for deciding whether a shape instantiates a familiar or an unfamiliar percept. Apparently, she retains fairly good criteria for rejecting figures that have no counterpart in reality, but has lost the knowledge of the visual appearance of objects that do exist.

Verbal Access to the Visual Store

In a patient who is impaired at deriving structured descriptions from visual input probing the pictorial store with figures leaves unanswered the question of whether the failure is only perceptual or also involves a mnemonic factor. To tap directly the store through a presumably intact route, we asked the patient to call up a visual representation of objects in response to their names, with three tests that required different kinds of response.

The first was *drawing from memory*. Names of geometrical figures (9) and of fruits and objects (20) were given, with the request to draw them. Admittedly, the results are difficult to evaluate, due to subjects' variation in drawing ability and to the difficulty in discriminating a representational from an executive deficit. Annalisa drew fairly accurately a square, a triangle, an oblong and a circle; she drew two lines across for a cross and made errors in drawing

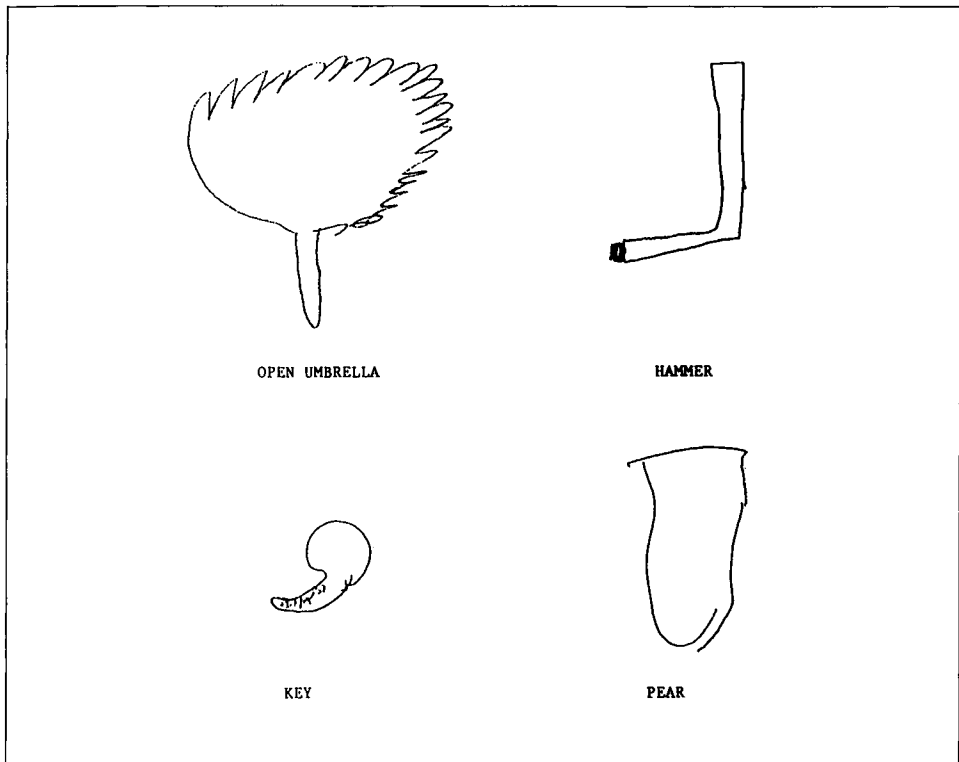


Fig. 8 – Drawing objects from memory.

a rhombus, a trapezium, an oval and a cube. Out of 20 objects and fruits, 9 drawings were recognizable by two independent observers, 11 were not (Figure 8).

The second test required a *verbal description of the perceptual differences* between pairs of objects, animals or fruits of similar shape, whose names were provided. Prior to testing, the following instructions were given: “You are going to hear the names of two objects that look pretty alike, but can be visually distinguished by some critical feature. Suppose that I know nothing about them and try to explain me how they can be identified. Don’t tell me how they differ in use, but just focus on their appearance and physical dissimilarities.” Answers were judged correct if at least one crucial feature distinguishing the two stimuli was mentioned. There were 25 items (see Appendix) and the patient scored 15. The normal control mean was 21.40 (range 18.5 to 23).

The third test required the patient to *recall the color* of objects, fruits, animals, etc., having a typical color. She scored 56/100. The control mean was 90 (range 83 to 100). Many errors were blatant, e.g., goose-yellow; cock’s comb-white; ribbon for announcing a male birth-black; the ace of diamonds-yellow; yolk of egg-white.

Comment

The many errors made in drawing from memory and in answering questions concerning the perceptual features of named stimuli point out that the ability to retrieve visual images from memory was impaired. The impairment in visualization also extended to colors. Whether this was due to store disruption or to an impairment of the generation process will be discussed later.

Verbal Description of the Curvature of Alphabet Letters

The patient was requested to imagine the capital letters of the alphabet, as they were named by the examiner and to decide whether they were entirely made up of straight lines or contained curves. Twenty letters were given twice in random order. Responses were quick and always correct (40/40). The same was true when, subsequently, the decision was made on the visually presented letters.

Semantic Knowledge

The attempt to assess semantic knowledge via visual input was hindered by the patient's inability to recognize the single stimuli. This was apparent in a *semantic association test*, where she had to match the colored photograph of an object with that of a member of the same semantic category, which was presented along with 3 distractors (e.g., a belt had to be paired with one of the following objects: a broom, suspenders, ruler, espresso pot). She made 6 correct matches out of 24 with a time limit of 30 sec. If the time limit was increased to 60 sec., 5 further correct pairings were added. In no case was there evidence that the stimuli had been recognized. The names she provided were totally unrelated, even when the match was correct.

The study of semantic knowledge was, therefore, pursued by verbally probing knowledge with questions concerning the function, the context, and other non-visual attributes of objects, foods, and animals. The types of questions are listed in Table VI along with the scores of Annalisa and of 10 control subjects (limited to the tests where there was a suspicion of deficit). Note that the first two tests are concerned with the knowledge of the physical features of the stimuli, but do not demand a detailed visual representation.

On most tests (see Table VI) Annalisa's performance was correct and only in a few of them was marginally below that of controls.

DISCUSSION

The object recognition impairment exhibited by Annalisa, though present in more than one modality, was definitely more marked for visually presented stimuli, and could not be attributed to the effect of elementary sensory deficits, aphasia and/or generalised mental deterioration. The spectrum of performance on which she failed was wide and involved different types of mental operations.

TABLE VI
Tests Tapping Semantic Knowledge

	Annalisa	Controls
Which object is heavier	19/20	—
Of what material is an object made	23/25	—
Foods cooked on the fire	23/25	—
Foods used for minestrone	23/25	—
Objects: used to sew or to cook	12/12	—
Objects: used in bath or in workshop	14/14	—
Animals: living in Italy	15/20	18-20
Animals: jumping, flying, swimming or crawling	25/30	29-30
Animals: tame or wild	20/24	23-24
Means of transportation: which is faster	8/10	8-10

Her deficit resulted in the inability to recognize objects, either verbally or by other means, but it also extended to visual tasks that do not require the attribution of meaning (e.g., meaningless overlapping figures) and to verbal tasks that imply knowledge of the visual features of objects, though not their perceptual processing (e.g., describing the difference between two named stimuli). On the other hand, she manifested a preserved body of information about the functional, contextual and semantic attributes of the stimuli, when they were probed verbally.

The Perceptual Deficit

The classification of Annalisa's recognition deficit as apperceptive or associative depends on the operational criteria adopted to categorize agnosias. Those proposed by Lissauer (1890), and until recently accepted to define apperceptive agnosia, mainly hinged on performance on three tests assumed to assess form perception independently of meaning, namely, visual matching, detecting small differences between similar shapes and copying drawings. If patients with apperceptive agnosia are those who fail them and patients with associative agnosia those who pass them, then Annalisa would be given the label of associative agnosia. Her reproduction of drawings was clearly recognizable and carried out without hesitation and the line-by-line approach that are thought to characterize the performance of patients who are unable to achieve a good percept of the model (Ratcliff and Newcombe, 1982). Visuo-visual and tactile-visual matching tasks were performed either flawlessly or with few errors. Form discrimination was correct and quick, not only for shapes varying along one dimension (Efron's and Talland's tests), but also for complex figures that are remarkably similar and only distinguishable by minor differences of their external configuration or internal structure (same-different judgments on Raven, hand and couple tests). In this respect, Annalisa is strikingly different from the patients labelled apperceptive agnostic in the literature, who all manifest severe difficulty to perceive gross differences between simple shapes and to copy elementary forms and often to trace them. To give an example, patient H.C., originally reported by Adler (1944, 1950), still failed to match Raven's designs and to copy ele-

mentary geometrical figures, when re-examined approximately 40 years later, in spite of substantial recovery in the identification of common objects (Sparr et al., 1991).

The claim that Annalisa's perceptual processing is unimpaired does not hold out, however, against a more thorough investigation with tests that, though still not involving meaning, are perceptually more exacting, because they require the subject either to disentangle a form from a confusing background or to achieve a highly structured description of the stimulus. It is worth noting, in this connection, the dissociation between performance on the two tests requiring the discrimination of a square from an oblong and of a fragmented X from a fragmented O, both considered by Warrington (1985) as a cornerstone for the diagnosis of agnosia. Annalisa passed flawlessly the former and failed the latter. This is not surprising, because the fragmented figure detection test appears to have more features in common with other tests of figure-ground discrimination, such as the overlapping figure test, than with Efron's test, where the performance is based on an elementary variable, i.e., the changing ratio between the height and the width of the stimulus. The need to keep separate performance on the two tests finds support in a study of the severe agnosic patient, recently reported by Kartsounis and Warrington (1991), who was able to discriminate a square from an oblong, a circle from an ellipse, circles of different sizes, lines of different lengths and to identify small size letters, but failed on tasks of figure-ground discrimination and when the stimuli presented with discontinuities.

Further evidence indicating the deterioration of perceptual processing can be gathered from performance on two tasks that are easy for normal controls and on which the patient failed: the possible-impossible object decision test and the verbo-visual matching task. The former requires the subject to analyze the relation between the edges and surfaces of a three-dimensional form and to decide whether it respects the rules governing the spatial structure of objects. Since neither possible nor impossible figures have been previously encountered, they do not have any preexisting representation as a unit in memory and their discrimination must be entirely based on a viewer-centered structured description that permits violations of spatial relations to pop out. The chance score of the patient bears witness to the profound impairment of her ability to transform a bidimensional figure into a structured three-dimensional percept.

In addition, pointing to objects named by the examiner was an easy task for our patient, thanks to the restricted number of alternatives. In fact, her performance was fairly good in the semantic condition, when the physical characteristics of the distractors were easy to differentiate. Yet it deteriorated, when the choice had to be made among visually similar figures, suggesting a perceptual discrimination problem.

The Visual Store Deficit

When perceptual processing is impaired, it is problematic to assess the functioning of the visual store when it is accessed via sensory information, as in object decision tasks, since errors can arise from the degradation of structured

descriptions, or of stored form representations or of both. Some hints that recognition deficits are, at least in part, due to the impairment of the visual store may be found in the dissociable performance on the two object decision tasks used in this study. With drawings of non-objects and objects, the performance was almost flawless for non-objects and fell just above chance for objects. On the other hand, when animal and objects drawings had to be distinguished from drawings that recombined parts of objects or animals, she scored at chance on both kinds of stimuli. This pattern of performance is hard to account for in terms of defective perception, since the non-objects of both tests were of similar perceptual complexity. It is more likely that the deficit arose when Annalisa was searching through the catalogue of stored representations. Assuming that the disorder had caused some loss of their distinctive features (Farah, 1990), the patient conceivably found it difficult not only to accept as real true objects, but also to reject the distorted stimuli of the "new" object decision test, because they maintained several of the essential characteristics of their referents. Only true non-objects yielded correct responses, since they contained no element of reality and could not trigger any ambiguity in the catalogue.

More direct evidence of an impairment of the visual store is provided by the poor performance on imaging tests, such as drawing from memory, describing the perceptual differences between similar objects and recalling the color of objects. Since in all of these tasks visual descriptions were accessed through the verbal route, the confounding effect of a noisy perceptual channel was avoided. Nor could the deficit be attributed to a block in the pathway transmitting verbal information, since it only emerged with questions concerning the description of the physical properties of stimuli and not with those concerning their contextual, associative and functional attributes.

The common basis of the failed tests is that they require image generation from long-term visual memory. There has been increasing agreement in recent years that when subjects are engaged in the visualization of an object, they generate from long-term memory and transfer for inspection to a short-term buffer a representation of the object's visual appearance that permits its recognition. Farah (1984) has outlined the cognitive architecture underpinning imagery processes and has used it to localize the functional lesion of cases with loss of mental imagery reported in the literature, based on the patient's performance on tasks tapping the different components of the system. For instance, patients who fail on imagery tests but pass recognition tests are assumed to have damage confined to the image generation process, while those (like Annalisa) who are impaired on both kinds of tasks are thought to suffer from a disruption of the long-term visual store. It can be objected that the hypothesis of a common origin for recognition and imagery difficulty holds for cases of associative agnosia, but not when recognition problems are perceptual, i.e., when they arise at a stage not requiring the utilization of the information stored in visual memory. On this hypothesis, Annalisa's imagery deficits might have no direct bearing on her recognition disability and simply reflect the concomitant functional lesion of the image generation process. A generation deficit would, however, be expected to affect all types of visual images, independently of the category to which they belong, while Annalisa's performance was flawless when

she had to decide whether a letter named by the examiner had curves or not, a dissociation remindful of that reported by Mehta, Newcombe and DeHaan (1992) in patient M.S. A differential performance depending on the nature of the stimulus is easier to accommodate by assuming a category specific organization of the visual store rather than a fractionation of the generation process into discrete mechanisms specialized for specific classes of imagery. Moreover, the stimuli that are well recognized — letters — were also well imagined, and *viceversa* in the case of objects, fruits, and animals. This finding that efficiency on imagery tasks paralleled that on recognition tasks is claimed to support the idea that both processes avail themselves of the same visual representation (Farah, 1984).

We are inclined, therefore, to believe that Annalisa is impaired both at the perceptual level and at the level of the stored structured representations. Are the two deficits independent and resulting from lesions of adjacent structures or are they causally related, in that the disruption of fine-grained perceptual processing is due to the unavailability of the top-down assistance that stored visual memories provide to differentiating complex stimuli? Aware of this problem, Lissauer (1890) warned: "We cannot expect to see an impairment of associative processes without some additional apperceptive problems, i.e. there cannot be a selective associative visual agnosia, but at most a predominantly associative visual agnosia", a claim that has received some support from the observation (Farah, 1990) that practically all cases of associative agnosia show some abnormality in perception, although too few cases have been thoroughly investigated.

The aid that a top down 'parser', driven by mental representation, can provide to the analysis of familiar stimuli cannot be underestimated, but the reduction of perceptual impairment to a mere consequence of the deficit of the visual form store is unconvincing in the present case: the patient also failed in front of certain types of meaningless stimuli, which, having never been encountered before, could not be represented in visual memory. This was the case for the meaningless overlapping figure test and for the possible-impossible object decision test. Also the poor performance on Warrington and Taylor's (1973) figure detection test cannot be ascribed to defective memories of letter configuration, since the patient could read letters flawlessly. Therefore, albeit in violation of the principle of parsimony, the position that Annalisa suffered from damage to two distinct modules of the functional architecture of visual cognition would appear to account better for the spectrum of her defective performance.

Further, the dissociation shown by the patient in answering questions on the physical characteristics of stimuli and on their contextual, associative and functional attributes suggests a fractionation within a semantic system with separate stores for the different types of information. Two models have been proposed. In one account (Warrington and Shallice, 1984; Shallice, 1988) at least two discrete compartments, specified by the input modality, can be identified in semantic memory: the verbal and the visual store. Probably the most compelling evidence for this duplication is represented by patient TOB (McCarthy and Warrington, 1988, 1990b) who showed a selective impairment in comprehend-

ing the spoken names of living things. In this view, the visual store contains knowledge of the form, color, visual context and gesture associated with the stimulus, along with any other kind of information that can be acquired visually and can contribute to the enrichment of its meaning. An alternative view (Ratcliff and Newcombe, 1982; Humphreys, Riddoch and Quinlan, 1988) is that a single, all-purpose semantic store, common to all modalities, is hierarchically superimposed on a presemantic visual form store, where the 3D structural description of an object is matched with the corresponding mental representation, but is not recognized. In this account, a visually presented stimulus would first activate the visual template in the pre-semantic store and then gain access to semantic memory. When questions regarding its shape are addressed, the verbal message travels in another direction, from language areas to semantic memory, where it is decoded, and then to the presemantic store, where images are generated. Patient JB (Riddoch and Humphreys, 1987b), who passed flawlessly object decision tasks, but failed to associate semantically related pictures, would represent an example of a disconnection between the two stores and bear witness to their independence. In the present case, the evidence drawn from the verbal approach to the store shows that the impairment in retrieval was confined to the physical features (shape, color) that specify the visual appearance of the stimulus and did not extend to characteristics — the gesture associated with an object, the context in which the stimulus is encountered — that are less strictly dependent on visual information. While this dissociation points to a discrete treatment of certain visual data, it cannot determine whether this selective processing occurred in a presemantic or semantic visual store.

In conclusion, this case shows that the distinction between apperceptive and associative agnosia does not do justice of the complexity of clinical facts and may be difficult to apply in the single case. Annalisa shared features of both syndromes: she performed poorly on certain complex perceptual tests and thus demonstrated features of apperceptive agnosia, though not in a “classical” sense. But she also failed on tasks concerned with accessing the visual store and this performance raises the question of whether an impairment at this stage of processing points to an associative deficit. Perhaps it is more fruitful to abandon rigid taxonomy and rather specify degrees and levels of functional impairment, in each case.

Tactile Recognition

The impairment shown by Annalisa in tactile recognition deserves comment, since a prerequisite for the diagnosis of visual agnosia has traditionally assumed the integrity of recognition and naming when the information is conveyed through other sensory modalities. However, scrutiny of the literature suggests that this is far from being the rule, at least with respect to the tactile modality; in several cases, we must be content with demonstrating a more marked visual than tactual deficit rather than an intact tactile performance. Morin, Rivrain, Eustache et al. (1984) reviewed the literature from 1970 and found that out of 17 cases of visual agnosia, 6 had marked and 6 moderate deficits of tactile recognition. Among the most recent case reports, impairment of tactile recog-

dition from mild to extremely severe has been reported by Davidoff and Wilson (1985), McCarthy and Warrington (1986), Riddoch and Humphreys (1987b) and Grailet et al. (1990). Moreover, in a consecutive series of 16 patients selected for the presence of a left posterior cerebral artery infarct (De Renzi, Zambolin and Crisi, 1987), in whom the same 30 objects were presented in the visual and tactile modality and performance was assessed relative to the cut-off scores obtained from 70 normal controls, there were 11 patients impaired on the visual test and 10 on the tactile test. Since the territory of distribution of the posterior cerebral artery does not involve pathways or cerebral areas specialized in the transmission, processing and storage of somatosensory information, the failure to identify adequately objects presented tactually cannot be attributed to defective perceptual processing and implies that their recognition is at least partially mediated by the retrieval of an image from the visual form store. Two additional clinical findings are consistent with this view and they help in rejecting both the hypothesis of a concomitant deficit and that of a semantic, supramodal disorder: the extreme rarity of cases of pure tactile agnosia (Morin et al., 1984); and the fact that visual agnosia is practically never accompanied by auditory agnosia (this was also the case for Annalisa). The association of an object with its sound is likely to be much more straightforward and to be carried out without relying on the reconstruction of shape.

A pragmatic consequence of these observations is that the diagnosis of visual agnosia is not challenged by the presence of tactile recognition disorders, even if severe, because the misidentification of palpated objects may be secondary to the unavailability of visual representations. However, if sound recognition is also impaired, the locus of the lesion is perhaps more likely to implicate a more fundamental semantic level.

Pantomime Recognition

The visual recognition impairment of Annalisa extended to pantomimes. Miming has received attention in studies of agnosia as an alternative method of demonstrating the recognition of an object that the patient is unable to name. Preserved ability would suggest that object meaning has been decoded by the semantic system: i.e., an instance of optic aphasia, not of associative visual agnosia. This claim has, however, been disputed on the assumption that the output of perceptual processing can directly activate the appropriate action, bypassing the semantic system (Riddoch, Humphreys, Coltheart et al., 1988). Evidence supporting this notion can be found in patient WLP, reported by Schwartz, Marin and Saffran (1979) and patient JB (Riddoch and Humphreys, 1987b). Interestingly, Gonzales Rothi, Mack and Heilman (1986) have pointed out the opposite dissociation, i.e., pantomime agnosia in the absence of object agnosia.

In the present case, the deficit affected Annalisa's ability to identify by name a pantomime executed by the examiner in contrast to the preservation of her gestural imitation and the production of pantomime on verbal command. It is unlikely that the impaired recognition of gesture was due to faulty discrimination of its visual features, because the patient was able to imitate normally gestures produced by the examiner. Imitation, however, is scarcely informative

about the ability to identify the meaning of the proposed action; an adequate structured description of the gesture configuration could directly activate the motor programming system located in the left parietal cortex (Heilman, 1979; De Renzi, 1989), without demanding the recognition of the referent. Yet, the fact that the patient was able to produce on verbal command most of the pantomimes she could not recognize is evidence of the integrity of their stored mental representations, contrary to what occurred for object recognition, where the verbal activation of stored representations was also defective (see drawing from memory). Thus the problem with Annalisa's impaired recognition of gesture would appear to reside in the failure of the adequately processed visual information to access the visual store rather than in a degradation of the store itself. This conclusion must be tempered with a word of caution, because it does not take into account the important role that proprioceptive memory might play in the imitation and production of gestures. The availability of proprioceptive engrams could assist gestural imitation and, at least in part, account for the observed dissociation.

Anatomical Considerations

Anatomo-clinical correlations must be pursued with caution in cases of traumatic etiology, since microscopic lesions may be more extensive than revealed by current imaging techniques. With this reservation in mind, it is worth emphasizing that the main lesion in this case was located in the right temporo-parietal-occipital region. Those areas of hyperlucency visible bilaterally in the parasagittal frontal cortex encroached upon cortical or subcortical structures that have never been implicated in the perceptual processing of visual data and are, therefore, unlikely to be relevant to the understanding of agnosia. Thus it is reasonable to suggest that it was the damage to the temporo-occipital areas of the right hemisphere that were mainly responsible for the visual disorders presented by the patient. The absence of persisting alexia further implied that the corresponding areas of the left hemisphere were not involved.

There is evidence from monkey studies (Ungerleider and Mishkin, 1982) that the processing of visual information, initiated in the calcarine cortex, concerned with shape recognition, proceeds along a pathway connecting the pres-triate with the posterior temporal cortex and ending in area TE of the antero-inferior temporal cortex. Whereas a lesion in the posterior visual areas is thought to impair the processing of the physical features of the stimulus, when they are analyzed in a viewer-centered coordinate framework, a lesion of TE would disrupt its recognition in memory tasks and hence the ability to extract and store an object-centered prototype (Weiskrantz and Saunders, 1984; Mishkin et al., 1983).

A critical difference between human and animal cerebral organization is the emergence in man of hemispheric specialization that assigns to each side of the brain distinct functions in the processing of information. With reference to visual recognition, the picture exhibited by our patient must be viewed in the context of data, derived from group studies (De Renzi et al., 1969; Warrington and Taylor, 1973) that have pointed to the prevalent, or even dominant role of the

right brain in achieving a structured description of the visual stimulus, which would then be transferred to the left hemisphere where it achieves meaning. This hypothesis is suggested by differences found in the performance of right and left brain-damaged samples on perceptual and semantic tests: it has not so far been supported by single case studies which show that apperceptive agnosia can occur with a lesion confined to the right hemisphere. Patient FZ (Levine, 1978) suffered from a severe deficit in object discrimination following a right occipital lobectomy, but she was left-handed. Patient 2 of Karpov, Meerson and Tonkonogii (1979) was reported to have suffered from a right occipital softening (although no radiological evidence was provided) that was associated with "slight object agnosia". However, more precise specification was lacking and handedness was not reported. There are, of course, several patients with damage confined to the right hemisphere who suffered from prosopagnosia, but their deficits in object identification, when present, were mild, limited to pictures, and not apparent in everyday life. These clinical features were also present in three right brain-damaged patients reported by Warrington and James (1989) as instances of pure apperceptive agnosia. Thus our case would appear to be unique in terms of the severity of the deficit. We would submit that what made the lesion of our patient particularly disruptive to higher stages of perceptual processing was its extension in the whole area involved in visual recognition, from the prestriate cortex to the anterior temporal lobe.

ABSTRACT

Following a trauma that mainly involved the right hemisphere, a 21-year-old girl showed a profound impairment in visual object recognition, without language and intellectual deficit. Her elementary sensory functions were preserved and she performed in the normal range on visual matching tasks, on tasks requiring to detect small differences between similar complex shapes and in copying drawings, without any evidence of a line by line approach. Her deficit emerged with tests that, though not implying identification of meaning, demanded to disentangle a form from a confused background and to achieve a highly structured description of the stimulus. In addition to this high-level perceptual processing disorder, there was a deficit in recovering from the visual store the shape of an object, also when the performance did not involve perceptual discrimination, e.g., in drawing from memory or telling the physical difference between two named stimuli. Knowledge of the semantic and contextual attributes of objects was intact. The case is taken as evidence that the borders of apperceptive agnosia may be ampler than usually thought and its distinction from associative agnosia less rigid, with some patients laying in-between the two syndromes.

Acknowledgments. We are grateful to Dr. F. Newcombe for her helpful suggestions on an earlier version of the paper. This research was supported by grants from CNR and MURST 40% to Dr. E. De Renzi.

REFERENCES

- ADLER, A. Disintegration and restoration of optic recognition in visual agnosia: Analysis of a case. *Archives of Neurology and Psychiatry*, 51: 243-259, 1944.
- ADLER, A. Course and outcome of visual agnosia. *Journal of Nervous and Mental Diseases*, 111: 41-51, 1950.
- DAVIDOFF, J., and WILSON, B. A case of visual agnosia showing a disorder of presemantic classification. *Cortex*, 21: 121-134, 1985.

- DE RENZI, E. Apraxia. In F. Boller and J. Grafman (Eds.), *Handbook of Neuropsychology*. Amsterdam: Elsevier, 1989, vol. 2, pp. 245-263.
- DE RENZI, E., FAGLIONI, P., GROSSI, D., and NICHELLI, P. Apperceptive and associative forms of prosopagnosia. *Cortex*, 27: 213-221, 1991.
- DE RENZI, E., FAGLIONI, P., and RUGGERINI, C. Prove di memoria verbale di impiego clinico per la diagnosi di amnesia. *Archivio di Neurologia e Psichiatria*, 38: 303-318, 1977.
- DE RENZI, E., MOTTI, F., and NICHELLI, P. Imitating gestures: A quantitative approach to ideomotor apraxia. *Archives of Neurology*, 37: 6-10, 1980.
- DE RENZI, E., SCOTTI, G., and SPINNLER, H. Perceptual and associative disorders of visual recognition. Relationship to the side of cerebral lesion. *Neurology*, 19: 634-642, 1969.
- DE RENZI, E., ZAMBOLIN, A., and CRISI, G. The pattern of neuropsychological impairment associated with left posterior cerebral artery infarcts. *Brain*, 110: 1099-1116, 1987.
- EFRON, R. What is perception? In R.S. Cohen and M. Wartofsky (Eds.), *Boston Studies in Philosophy of Science*. New York: Humanities Press, 1968, vol. 4.
- FARAH, M. The neurological basis of mental imagery. A componential analysis. *Cognition*, 18: 245-272, 1984.
- FARAH, M. *Visual Agnosia*. Cambridge: The MIT Press, 1990.
- Fairburn Figures*, Graphic Books International 1987.
- GHENT, L. Perception of overlapping and embedded figures by children of different ages. *American Journal of Psychology*, 69: 575-587, 1956.
- GONZALES ROTH, L., MACK, L., and HEILMAN, K.M. Pantomime agnosia. *Journal of Neurology, Neurosurgery and Psychiatry*, 49: 451-454, 1986.
- GRAILET, J.M., SERON, X., BRUYER, R., COYETTE, F., and FREDERIX, M. Case report of a visual integrative agnosia. *Cognitive Neuropsychology*, 7: 275-309, 1990.
- HEILMAN, K.M. Apraxia. In K.M. Heilman and E. Valenstein (Eds.), *Clinical Neuropsychology*. New York: Oxford University Press, 1979, pp. 159-185.
- HUMPHREYS, G.W., and RIDDOCH, M.J. The fractionation of visual agnosia. In G.W. Humphreys and M.J. Riddoch (Eds.), *Visual Object Processing: A Cognitive Neuropsychological Approach*. London: Lawrence Erlbaum Associates, 1987.
- HUMPHREYS, G.W., RIDDOCH, M.J., and QUINLAN, P.T. Cascade processes in picture identification. *Cognitive Neuropsychology*, 5: 67-103, 1988.
- KARPOV, B.A., MEERSON, Y.A., and TONKONOGII, I.M. On some peculiarities of the visuomotor system in visual agnosia. *Neuropsychologia*, 17: 281-294, 1979.
- KARTSOUNIS, L.D., and WARRINGTON, E.K. Failure of object recognition due to a breakdown of figure-ground discrimination in a patient with normal acuity. *Neuropsychologia*, 29: 969-980, 1991.
- KERTESZ, A. Visual agnosia: the dual deficit of perception and recognition. *Cortex*, 15: 403-419, 1979.
- KROLL, J.F., and POTTER, M.C. Recognizing words, pictures and concepts: a comparison of lexical, object and reality decisions. *Journal of Verbal Learning and Verbal Behavior*, 23: 39-66, 1984.
- LEVINE, D. Prosopagnosia and visual object agnosia: A behavioural study. *Brain and Language*, 5: 351-365, 1978.
- LISSAUER, E. Ein Fall von Seelenblindheit nebst einem Beitrage zur Theorie derselben. *Archiv fur Psychiatrie und Nervenkrankheiten*, 21: 222-270, 1890.
- MARR, D. *Vision*. San Francisco: W.H. Freeman, 1982.
- MCCARTHY, R.A., and WARRINGTON, E.K. Visual associative agnosia: A clinico-anatomical study of a single case. *Journal of Neurology, Neurosurgery and Psychiatry*, 49: 1233-1240, 1986.
- MCCARTHY, R.A., and WARRINGTON, E.K. Evidence for modality-specific meaning systems in the brain. *Nature*, 334: 428-430, 1988.
- MCCARTHY, R.A., and WARRINGTON, E.K. *Cognitive Neuropsychology. A Clinical Introduction*. San Diego: Academic Press, 1990a.
- MCCARTHY, R.A., and WARRINGTON, E.K. The dissolution of semantics. *Nature*, 343: 599, 1990b.
- MEHTA, Z., NEWCOMBE, F., and DEHAAN, E. Selective loss of imagery in a case of visual agnosia. *Neuropsychologia*, 30: 645-655, 1992.
- MISHKIN, M., UNGERLEIDER, L.G., and MACKO, K.A. Object vision and spatial vision: two cortical pathways. *Trends in Neuroscience*, 6: 414-417, 1983.
- MORIN, P., RIVRAIN, Y., EUSTACHE, F., LAMBERT, J., and COURTHEOUX, P. Agnosie visuelle et agnosie tactile. *Revue Neurologique*, 140: 271-277, 1984.
- NEWCOMBE, F., YOUNG, A.W., and DEHAAN, E. Prosopagnosia and object agnosia without covert recognition. *Neuropsychologia*, 27: 379-391, 1989.
- NEWCOMBE, F., and RATCLIFF, G. Agnosia: A disorder of object recognition. In F. Michel and B. Schott (Eds.), *Les Syndromes des Disconnection Calleuse chez l'Homme*. Colloque International de Lyon. Lyon, 1975.
- PALMIERI, D. Preparazione e taratura di un test per l'agnosia acustica. M.D. Thesis, University of Modena, 1986.
- RATCLIFF, G., and Newcombe, F. Object recognition: Some deductions from the clinical evidence. In

- A.W. ELLIS (Ed.), *Normality and Pathology in Cognitive Function*. London: Academic Press, 1982.
- RIDDOCH, M.J., and HUMPHREYS, G.W. A case of integrative agnosia. *Brain*, 110: 1431-1462, 1987a.
- RIDDOCH, M.J., and HUMPHREYS, G.W. Visual object processing in optic aphasia: A case of semantic access agnosia. *Cognitive Neuropsychology*, 4: 131-185, 1987b.
- RIDDOCH, M.J., HUMPHREYS, G.W., COLTHEART, M., and FUNNELL, E. Semantic system or systems? Neuropsychological evidence reexamined. *Cognitive Neuropsychology*, 5: 3-25, 1988.
- SARTORI, G., and JOB, R. The oyster with four legs: A neuropsychological study on the interaction of visual and semantic information. *Cognitive Neuropsychology*, 5: 105-132, 1988.
- SCHACTER, D.L., COOPER, L.A., and DELANEY, S.M. Implicit memory for unfamiliar objects depends on access to structural description. *Journal of Experimental Psychology: General*, 119: 5-24, 1990.
- SCHWARTZ, M.F., MARIN, O.S.M., and SAFFRAN, E.M. Dissociations of language function in dementia: A case study. *Brain and Language*, 7: 277-306, 1979.
- SNODGRASS, J.G., and VANDERWART, M. A standardized set of 260 pictures: Norms for name agreement, image agreement, familiarity, and visual complexity. *Journal of Experimental Psychology: Human Learning and Memory*, 6: 174-215, 1980.
- SPARR, S.A., JAY, M., DRISLAND, F.W., and VENNA, H. A historical case of visual agnosia revisited after 40 years. *Brain*, 114: 789-800, 1991.
- TALLAND, G.A. Psychological studies of Korsakoff's psychosis: II Perceptual factors. *Journal of Nervous and Mental Diseases*, 127: 197-219, 1958.
- TUNDO, P. Taratura di due test associativi per la diagnosi di agnosia visiva. M.D. Thesis, University of Modena, 1986.
- UNGERLEIDER, L.G., and MISHKIN, M. Two cortical visual systems. In D.J. Dingle, M.A. Goodale and R.J.W. Mansfield (Eds.), *Analysis of Visual Behavior*. Cambridge, MA: The MIT Press, 1982, pp. 549-586.
- WARRINGTON, E.K. Agnosia: The impairment of object recognition. In J.A.M. FREDERIKS (Ed.), *Handbook of Clinical Neurology: Clinical Neuropsychology*. Amsterdam: Elsevier, 1985.
- WARRINGTON, E.K., and JAMES, M. Visual apperceptive agnosia. A clinico-anatomical study of three cases. *Cortex*, 24: 13-32, 1988.
- WARRINGTON, E.K., and TAYLOR, A.M. Contribution of the right parietal lobe to object recognition. *Cortex*, 9: 152-164, 1973.
- WEISKRANTZ, L., and SAUNDERS, R.C. Impairments of visual object transforms in monkeys. *Brain*, 107: 1033-1072, 1984.

APPENDIX

Pairs of Stimuli Used to Test Perceptual Discrimination from Memory

1. Knife blade – saw blade
2. Nail – screw
3. Horse back – camel back
4. Artichoke – fennel
5. Pig tail – horse tail
6. Button – 100 L. coin
7. Chestnut – nut
8. Wooden match – toothpick
9. Pot – frying pan
10. Brush – toothbrush
11. Fly – bee
12. Telephone counter – 200 L. coin
13. Pot – colander
14. Needle – pin
15. Bicycle wheel – car wheel
16. Necktie – scarf
17. Almond – hazelnut
18. Spaghetti – noodles
19. Cigar – cigarette
20. Pine branches – oak branches
21. Slippers – bedroom slippers
22. Pear – apple
23. Spoon – ladle
24. Bean – pea
25. Horse ears – sheep ears