

Moyamoya disease in pregnancy: A case report

Soheil Amin-Hanjani, MD, Mark Kuhn, MD, Neil Sloane, MD, and Ashwin Chatwani, MD
Philadelphia, Pennsylvania

Moyamoya disease is a rare condition characterized by narrowing and occlusion of the internal carotid arteries. The disease usually presents as alteration of consciousness caused by intracranial hemorrhage. We describe a case of moyamoya disease presenting as seizures in a pregnant patient. The characteristic angiographic appearances and plan of management are described. (*Am J Obstet Gynecol* 1993;169:395-6.)

Key words: Moyamoya, pregnancy, intracranial hemorrhage, seizure

Moyamoya disease is a rare condition characterized by angiographic evidence of bilateral narrowing and occlusion of the internal carotid arteries, along with the presence of an abnormal capillary network of vessels at the base of the brain. The disease presents in children with motor paresis, sensory disturbance, headache, convulsive seizures and involuntary movements. In contrast, in adults it usually presents with intracranial hemorrhage.¹

We describe a case of moyamoya disease in pregnancy that presented with seizures. Also described are angiographic appearances, clinical features, and management options.

Case report

A 25-year-old black woman, gravida 1, para 0, with no prenatal care and an unknown date of last menstrual period was admitted after having experienced a grand mal seizure. She had no history of seizure, trauma, or accidents.

Physical examination revealed blood pressure of 156/100 mm Hg with normal deep tendon reflexes. Abdominal examination revealed a term size uterine fundus. The fetal heart rate was 160 beats/min. Urinalysis showed no proteinuria. A tentative diagnosis of eclampsia was made, and a loading dose of 5 gm of intravenous magnesium sulfate was begun. During the administration, the patient had another tonic-clonic seizure, and the fetal heart rate dropped to 60 beats/min. A cesarean section was performed immediately with the patient under general anesthesia, and a live male infant weighing 6 pounds 8 ounces was delivered with Apgar scores of 8 and 8 at 1 and 5 minutes.

*From the Departments of Obstetrics, Gynecology, and Reproductive Sciences, Temple University School of Medicine.
Received for publication January 29, 1993; accepted February 28, 1993.*

Reprint requests: Ashwin Chatwani, MD, Temple University School of Medicine, Department of Obstetrics and Gynecology, 3401 N. Broad St., Philadelphia, PA 19140.

*Copyright © 1993 by Mosby-Year Book, Inc.
0002-9378/93 \$1.00 + .20 6/1/46904*

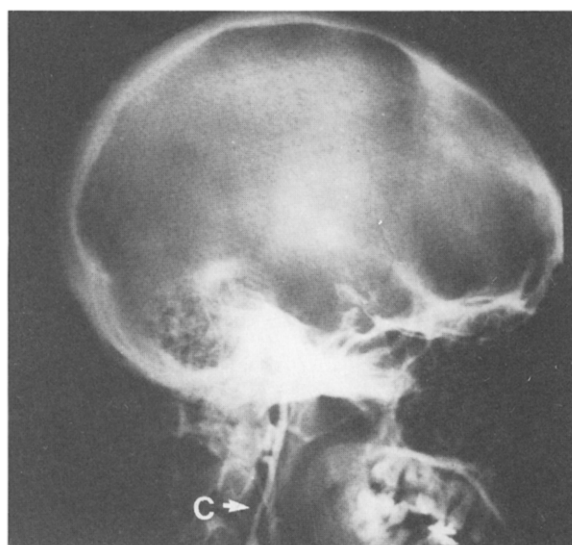


Fig. 1. Left carotid angiogram showing small caliber internal carotid artery with complete occlusion at siphon. C, Internal carotid artery.

All the results of blood tests obtained before surgery were reported to be normal.

Because the patient, apart from high blood pressure, did not show any clinical or laboratory evidence of eclampsia, a neurologic consultation was obtained. Further neurologic examination revealed left lower-extremity weakness. A lumbar puncture revealed xanthochromic spinal fluid. Computerized tomography of the head showed a right temporal lobe low-density lesion and right convexity effacement with abnormal pattern consistent with subarachnoid hemorrhage. Bilateral carotid angiograms revealed both internal carotid arteries to be very small in caliber from their origin to just above the origin of the ophthalmic arteries where they tapered to a complete occlusion (left side demonstrated in Fig. 1). Very small collaterals were identified distal to the occlusion. A small amount of contrast to the anterior and middle cerebral arteries was thought to be from the occipital collaterals into the vertebral basilar system. Left vertebral angiogram re-

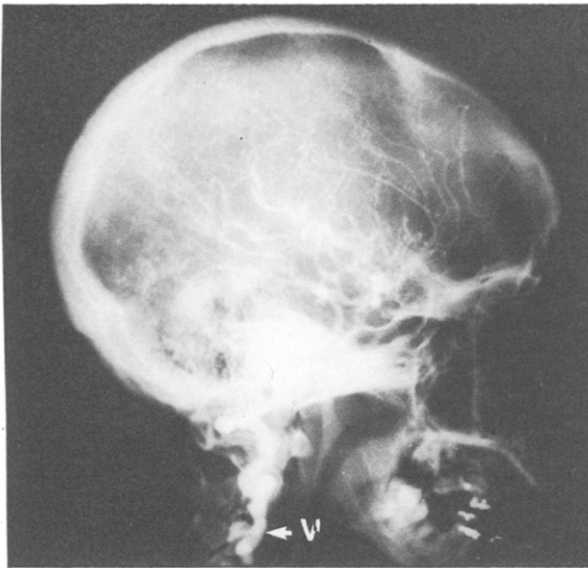


Fig. 2. Left vertebral artery supplying entire intracranial circulation. V, Vertebral artery.

vealed it to be large and supplying the entire intracranial circulation (Fig. 2). The overall radiographic picture was consistent with moyamoya disease, stage 6¹. The electroencephalogram revealed right-sided slowing and one episode suggestive of seizure activity.

The patient was started on a regimen of phenytoin and discharged home on the thirteenth postoperative day without any symptoms except for minimal difficulty in walking.

Comment

Because the majority of cases of moyamoya disease were initially found in Japan, it was thought to be restricted to that ethnic group until additional cases were described in the Western hemisphere in the late 1960s. Angiographically, moyamoya disease is characterized by narrowing and occlusion of both internal carotid arteries, although the disease may initially start with unilateral narrowing. A typical collateral network of vessels is present at the base of the brain. The occlusive process begins in the region of the carotid siphon and spreads distally, approaching the anterior and middle cerebral arteries, usually without collateral filling through the circle of Willis. Eventually cerebral perfusion may become dependent on collateral circulation from the vertebral arteries, as seen in our patient

(stage 6 of the disease was described by Suzuki and Kodama¹).

Moyamoya in the Japanese language is an adjective denoting a hazy network resembling a puff of smoke. The term is not descriptive of the specific manifestations of the disease but rather of its initial angiographic appearance.

The cause of the disease is obscure. However, there are two main hypotheses: a true congenital vascular malformation or an acquired arteritic condition. Autopsy examination of patients with this condition has shown severe reduction in the caliber of the vessel fibrotic intimal thickening, and degeneration of the internal elastic lamina.

The disease usually presents in children with paroxysmal hemiplegia, hemiparesis, involuntary movement, headache, and seizures. In adults of reproductive age the disease usually occurs as alterations of consciousness caused by cerebral ischemia or intracranial hemorrhage.

There are only a few case reports of the disease in pregnancy.² Those that have been reported have largely presented as intracranial hemorrhage, which is associated with the bearing down of parturition.² Our patient's primary symptom was seizures, which may have been a result of hemorrhage. The high incidence of intracranial hemorrhage mandates careful control of any maneuver that increases intraabdominal pressure, such as bearing down. Even though an extremely rare condition, moyamoya disease should be a part of the differential diagnosis in pregnant patients with seizures or coma. Blood pressure must be strictly controlled during pregnancy, delivery, and the puerperium. Although our patient was delivered by cesarean section for obstetric indications, one must consider elective cesarean section for patients with moyamoya disease to avoid the hypertension and possible cerebral ischemia with active labor in this subgroup of obstetrics patients.

REFERENCES

1. Suzuki J, Kodama N. Moyamoya disease—a review. *Stroke* 1983;14:104-9.
2. Miyakawa I, Huei CL, Haruyama Y, Mori N, Mikura T, Kinoshita K. Occlusive disease of the internal carotid arteries with vascular collaterals (moyamoya disease) in pregnancy. *Arch Gynecol* 1986;237:175-80.