

Case Report

Moyamoya disease associated with bilateral renal artery stenosis

TAKASHI NAKANO,¹ EIICHI AZUMA,¹ MASARU IDO,¹ MASAHIRO ITOH,¹
MINORU SAKURAI,¹ SHIGERU SUGA² AND HIROSHI KAWAGUCHI²

¹*Department of Pediatrics, Mie University School of Medicine and* ²*Department of Pediatrics, Ueno Municipal Hospital, Mie-ken, Japan*

Abstract

Recent research has suggested that an association exists between moyamoya disease and fibromuscular dysplasia which involves systemic vessels, including renal arteries. We report a 3 year old girl with moyamoya disease associated with bilateral renal artery stenosis. This case may support the common etiology of these two clinical conditions. To our knowledge this is the youngest case of moyamoya disease associated with bilateral renal artery stenosis.

Key words

child, hypertension, Japan, moyamoya disease, renal artery stenosis.

The Japanese term 'moyamoya' means 'puff of smoke'. Moyamoya disease is a clinical entity which was named with reference to the cerebral angiographic findings. It is characterized by occlusion or stenosis of the internal carotid arteries and vessels in the circle of Willis. The collateral vessels are considered to form the network which looks like a 'puff of smoke' in compensation for the cerebral ischemic condition. We report a 3 year old girl with moyamoya disease associated with bilateral renal artery stenosis.

Case report

The patient was born healthy at the gestational age of 40 weeks and there had been no problems during the pregnancy. Growth and psychomotor development during infancy were within normal limits except for breath-holding spells, after which she showed tonic convulsive motion.

At the age of 3 years and 9 months, she suddenly developed left hemiplegia but recovered after several hours without sequelae. She was examined in a private hospital and a brain computed tomography (CT) scan revealed no abnormalities. After this, she often complained of strange sensations, associated with eye ball fixation, tonic convul-

sive motion and incontinence. Two months later monoplegia of the left upper limb appeared and lasted for over a week. A repeated brain CT scan was within normal limits again. She was referred to the Mie University Hospital.

On admission, hypertension (right arm: 164/104 mmHg, left arm: 162/100 mmHg, legs: 150–155/90–95 mmHg) was noticed. The patient was alert and well-oriented with normal speech. Monoplegia of the left upper limb was evident. No other neurological defects were found. Fundoscopic examination showed no abnormality. No bruits were audible over the carotid and abdominal areas.

Laboratory data were as follows. The urinalysis was normal and the erythrocyte sedimentation rate was 4 mm/h. Blood count, liver function, electrolytes, immunoglobulin levels and coagulation study were normal except for prolonged bleeding time (12 min by Duke method). The renal function test showed normal values, with a mean creatinine clearance of 75.8 mL/min and a normal phenol-sulfonphthalein excretion test result (15 min: 52.7%, 120 min: 94.9%). Serum complement levels (C3, C4) were normal. Anti-nuclear antibody, anti-DNA antibody, anti-extractable nuclear antigen antibody and lupus erythematosus cell tests were negative. The endocrine function test showed normal thyroid function and a normal serum cortisol level. Urinary 11-hydroxycorticosteroid, 17-ketosteroid and catecholamine levels were normal. Plasma renin activity was elevated to 10 ng/mL per h with an angiotensin-I level of 550 pg/mL (normal range < 250 pg/mL), an angiotensin-II level of 19 pg/mL (normal range

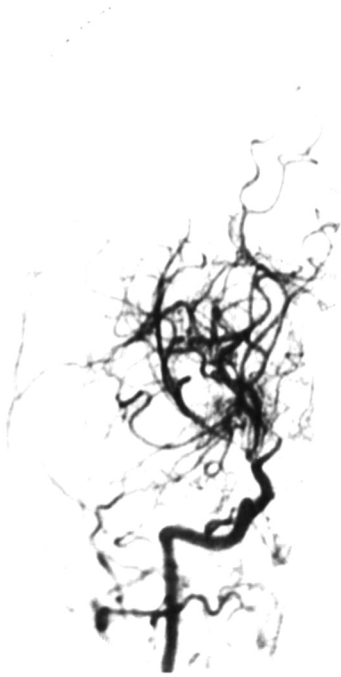


Fig. 1 Right carotid arteriography (frontal view). Intracranial stenosis and 'moyamoya' networks.

< 25 pg/mL) and an aldosterone level of 280 pg/mL (normal range is 35.7–240.0 pg/mL). Examination of the cerebrospinal fluid showed normal glucose and protein levels without pleocytosis, and no oligoclonal bands were detected.

The electroencephalogram showed background slowing (1–3 Hz high voltage δ activity was dominant at the occipital region) and asymmetry (right hemisphere voltage was higher than left side). Hyperventilation provocation was performed to no effect. Contrast-enhanced CT scan of the brain revealed no abnormalities. Magnetic resonance imaging showed disappearance of the circle of Willis, which was compatible with moyamoya disease. Brain vessels circulation scintigraphy showed decreased perfusion which was dominant for the right cerebral hemisphere.

Head aortography (Figs 1, 2) showed severe stenosis at the terminals of both internal carotid arteries. Bilateral anterior and middle cerebral arteries were nearly obstructed. The unusual vascular networks typical of moyamoya disease were observed, and distal portions of arteries were stained later through these collateral 'moyamoya' networks. There were also severe stenosis and 'moyamoya' networks around the area of the posterior communicating artery and posterior cerebral artery. Abdominal aortography (Fig. 3) demonstrated proximal segmental stenosis of both renal arteries. There was no evidence of aortitis or arteriosclerosis. Selective blood sampling from veins was

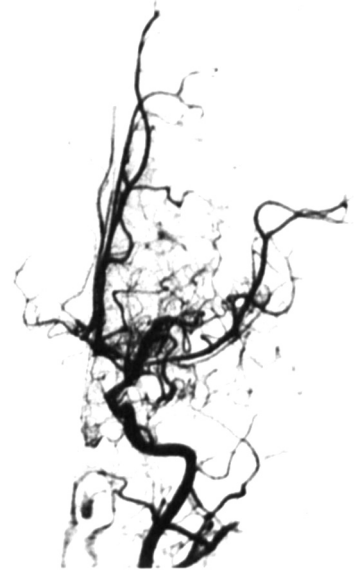

Fig. 2 Left carotid arteriography (frontal view). Intracranial stenosis and 'moyamoya' networks.

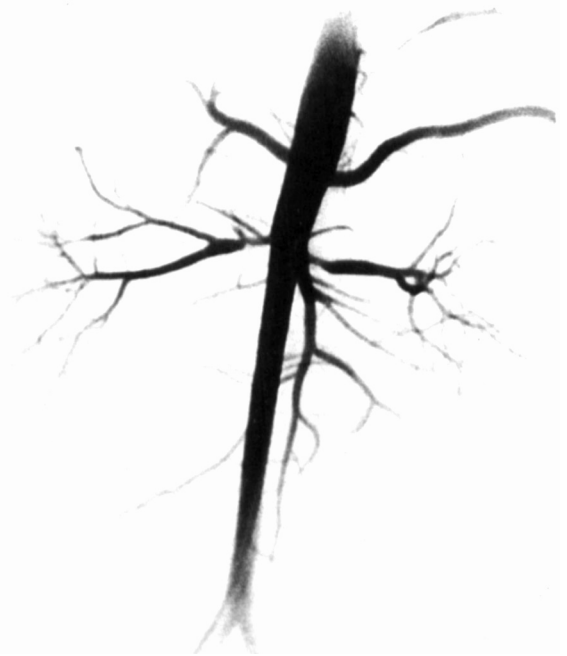

Fig. 3 Abdominal aortography (frontal view). Proximal segmental stenosis of bilateral renal arteries.

performed and plasma renin activity measured: right renal vein, 6.1 ng/mL/h; left renal vein, 2.6 ng/mL/h; upper inferior vena cava, 3.1 ng/mL/h; lower inferior vena cava, 2.8 ng/mL/h.

The paralysis of this patient was caused by ischemic attack in the brain, and hypertension was caused by renal

artery stenosis. A final diagnosis of moyamoya disease associated with bilateral renal artery stenosis was made. Hypertension in this patient was refractory. Nifedipine (≤ 18 mg/day) and captopril (≤ 18.75 mg/day) were given, but hypertension (140–180/90–120 mmHg) persisted. The patient underwent auto-graft bypass surgery (double superficial temporal artery to middle cerebral artery anastomoses and encephalo-myosynangiosis) of the right hemisphere of the brain, as its circulating condition was the most critical. Unfortunately, multiple cerebral infarction occurred during the operative procedure.

Discussion

The incidence of moyamoya disease in Japan is higher than in other countries. A nationwide survey in Japan showed a higher incidence in women (1.6 : 1) and a mean age of onset of 18.4 years. About a quarter of the patients showed their first symptom at < 5 years of age.¹ In Japan, 70% of the first symptoms of patients under 15 years are ischemic episodes, but more than half of the first symptoms of patients over 15 years are hemorrhagic episodes. The complication rate of renal artery stenosis with moyamoya disease in Japan is around 2%.

We reviewed moyamoya disease with renal artery stenosis in the literature (Table 1)^{2–10} and found half of the cases reported were from Japan. The onset age of neurological symptoms is generally older in the USA and Europe than in Japan. In Table 1, the neurological symptoms of the

older patients (cases 8, 9 and 10) are also ischemic episodes. Among the patients with moyamoya disease associated with renal artery stenosis, we cannot find any where the neurological symptoms were hemorrhagic episodes, even in older cases. Selective blood sampling of veins does not always show the typical results of localized renal artery stenosis (Table 1) as well as in the present case. Further investigation of the relationship between hypertension and renal artery stenosis is needed.

In our case, angiography was performed at the age of 4 years and 3 days and bilateral renal artery stenosis was confirmed. This is the youngest case of moyamoya disease associated with bilateral renal artery stenosis reported. It suggests that systemic vascular abnormality in such cases can develop at a very early age. In our case, onset of neurological symptoms was at 3 years of age, but breath-holding spells might be the first neurological symptom induced by cerebral ischemia on hyperventilation.

There have been no cases reported where the progression of systemic artery stenosis has been shown by serial repeated angiography. For case 1 in Table 1, left renal artery angiography was not performed on the occasion of the first angiography at 4 years of age. For older cases (cases 8 and 9), however, systemic artery involvement was observed. This may suggest that artery stenosis spread to systemic vessels with ageing in moyamoya patients. This may be the reason that younger children with fibromuscular dysplasia have rarely been reported. Long-term follow-up for the observation of the progression of systemic artery involvement should be continued.

Table 1 Literature review of Moyamoya disease cases with renal artery stenosis

No.	Sex	Country	Age of onset of neurological symptoms (years)*	Age when renovascular stenosis discovered (years) [†]	Plasma renin activity of select sampling (mg/mL per h) [‡]	Ref. no.
1	M	Holland	0.6	4, R; 6, L	n.d.	2
2	F	Japan	2	5, R & L	n.d.	3
3	M	Japan	2	7, R	r: 6.5; l: 4.4; up & low: 4.3	4
4	M	Japan	2	11, R & L	r: 17, l: 13, up & low: 15	5
5	M	Japan	3	4, R	up: 1.1, low: 1.2	6
6	F	Japan	3	4, R & L	r: 6.1, l: 2.6, up: 3.1, low: 2.8	!
7	?	USA	10	12, R & L	r: 41, inf. vena cava: 24	7
8 [†]	F	USA	29	29, L	n.d.	8
9**	F	France	30	30, R & L	n.d.	9
10	F	USA	34	34, R	r: 1.8; l: 1.3; up & low: 1.4	10

*All ischemic.

[†]R: Right; L: left.

[‡]r: Right renal vein; l: left renal vein; up: inferior vena cava, higher portion than renal vein; low: inferior vena cava, lower portion than renal vein.

[†]Coronary, splenic, internal iliac and femoral arteries were also involved.

**Internal and external iliac and mesenteric arteries were also involved.

!: Corresponding case.

References

- 1 Ministry of Health and Welfare, Japan. *Annual Report (1989) The Research Committee on Spontaneous Occlusion of the Circle of Willis (Moyamoya disease)*. The Ministry of Health and Welfare, Japan. 1989.
- 2 Jansen JN, Donker AJM, Luth WJ, Smit LME. Moyamoya disease associated with renovascular hypertension. *Neuropediatrics* 1990; 21: 44-7.
- 3 Yamashita M, Tanaka K, Kishikawa T, Yokota K. Moyamoya disease associated with renovascular hypertension. *Hum. Pathol.* 1984; 15: 191-3.
- 4 Takahashi H, Takayasu Y, Miura Y *et al.* A case report of Moyamoya disease associated with renovascular hypertension. *Jap. J. Pediatr. Med.* 1982; 14: 1220-2.
- 5 Fuchimukai T, Terai Y, Takahashi H *et al.* Two renovascular hypertension cases with Moyamoya network of brain. *J. Pediatr. Prac.* 1986; 49: 2153-8.
- 6 Terasawa K, Yamaguchi Y, Ishihara O, Matsuishi T, Tsunosue M, Morimatsu M. Moya-moya disease associated with fibromuscular dysplasia of renal artery. *No to Hattatsu.* 1983; 15: 350-5.
- 7 Ellison PH, Largent JA, Popp AJ. Moya-Moya disease associated with renal artery stenosis. *Arch Neurol* 1981; 38: 467.
- 8 Hartman JD, Yound I, Bank AA, Rosenblatt SA. Fibromuscular hyperplasia of internal carotid arteries. *Arch Neurol.* 1971; 25: 295-301.
- 9 Godin M, Helias A, Tadie M, Fillastre JP, Creissard P. Moya-Moya syndrome and renal artery stenosis. *Kidney Int.* 1978; 15: 450.
- 10 Halley SE, White WB, Ramsby GR, Voytovich AE. Renovascular hypertension in Moyamoya syndrome: Therapeutic response to percutaneous transluminal angioplasty. *Am. J Hypertens.* 1988; 1: 348-52.