

acute pulmonary oedema during or following use of beta-mimetics cardiac enzyme measurements were not reported.

Betamimetics can induce electrocardiographic changes suggestive of myocardial ischaemia. A study by Hendricks (Hendricks *et al.* 1986) of 112 consecutive patients treated with ritodrine found that 96% developed sinus tachycardia, 70% developed ST-depression, and 55% developed T-wave flattening or inversion. Hendricks explained these changes as being due to relative hypoperfusion of the sub-endocardium with functional ischaemia and concluded that the majority of women undergoing ritodrine therapy develop electrocardiographic changes of myocardial ischaemia but without symptoms.

A later study (Shlomo *et al.* 1986) was undertaken to investigate further the incidence of myocardial ischaemia in patients receiving ritodrine. Fifteen women were studied. On each woman three ECGs were recorded: before ritodrine was commenced, when uterine contractions had ceased, and immediately on discontinuing the ritodrine infusion. Significant ST-segment depression occurred in 73% in anteroseptal leads which resolved soon after ritodrine was stopped. Echocardiography was performed in four women during the maximum dose period. Hypokinesia of the interventricular septum was noted in three of these four. Creatinine phosphokinase MB isoenzyme measurements were normal in all patients. The authors concluded that the ECG changes were highly suggestive of myocardial ischaemia, supported by the echocardiographic demonstration of septal hypokinesia as an independent marker of myocardial ischaemia. Whether or not the hyperoestrogenic state of pregnancy up-regulates coronary alpha or beta receptors, thereby altering vasomotor tone and predisposing to coronary vasospasm and infarction, is unknown.

Acknowledgments

The authors would like to thank Ms E. Scanlan for preparing the manuscript.

References

- Blikstein I. *et al.* (1988) Ritodrine induced pulmonary oedema unmasking underlying peripartum cardiomyopathy. *Am J Obstet Gynecol* **159**, 332–333.
- Glancy D. L., Melvin L. M. & Epstein S. E. (1971) Myocardial infarction in young women with normal coronary arteriograms. *Circulation* **44**, 495–502.
- Hankins G. D., Wendel G. D. & Levenok J. (1985) Myocardial infarction during pregnancy: a review. *Obstet Gynecol* **65**, 139–146.
- Hendricks S. K., Keroes J. & Katz M. (1986) Electrocardiographic changes associated with ritodrine induced maternal tachycardia and hypokalemia. *Am J Obstet Gynecol* **154**, 921–923.
- Jacobs M. M., Knight A. B. & Arias F. (1980) Maternal pulmonary oedema resulting from beta-mimetics and glucocorticoid therapy. *Obstet Gynecol* **56**, 56–59.
- Katz M., Robertson P. & Creasy R. (1981) Cardiovascular complications associated with terbutaline treatment for preterm labour. *Am J Obstet Gynecol* **139**, 605–608.
- McGing P. G. & UaConaill D. (1988) Transient increase in CK-BB after a road traffic accident. *Clin Chem* **34**, 2603.
- Shlomo F. *et al.* (1986) Myocardial ischaemia during intravenous ritodrine treatment: is it so rare? *Lancet* **ii**, 917–918.
- Tinga P. J. & Aarnoudse J. G. (1979) Post partum pulmonary oedema associated with preventive therapy for premature labour. *Lancet* **ii**, 1026.

Received 2 May 1991

Resubmitted 7 July 1992

Accepted 20 August 1992

British Journal of Obstetrics and Gynaecology
August 1993, Vol. 100, pp. 782–784

Chronic subdural haematoma following epidural anaesthesia, presenting as puerperal psychosis

DOUGLAS A. CAMPBELL *Registrar*, THELEKAT R. K. VARMA *Consultant*

Department of Surgical Neurology, Royal Infirmary, Dundee, Scotland

Case report

A previously healthy 21 year old primigravida was delivered by emergency caesarean section for cephalopelvic disproportion. The operation was carried out under epidural anaesthesia at her request. The first attempt at epidural catheterisation was unsuccessful, but at a second

attempt a 16 gauge catheter was inserted into the epidural space between the second and third lumbar vertebrae. Anaesthesia to T5 level was obtained with 15 ml 0.5% bupivacaine hydrochloride (Marcain).

The operation was uneventful and a healthy male infant weighing 3654 g was born, with an estimated blood loss of 370 ml. The epidural catheter was removed 4 h post-operatively. The following day, the woman complained of severe headache and over the next 10 days significant

Correspondence: Mr T. R. K. Varma, Department of Surgical Neurology, Dundee Royal Infirmary, Dundee, UK.

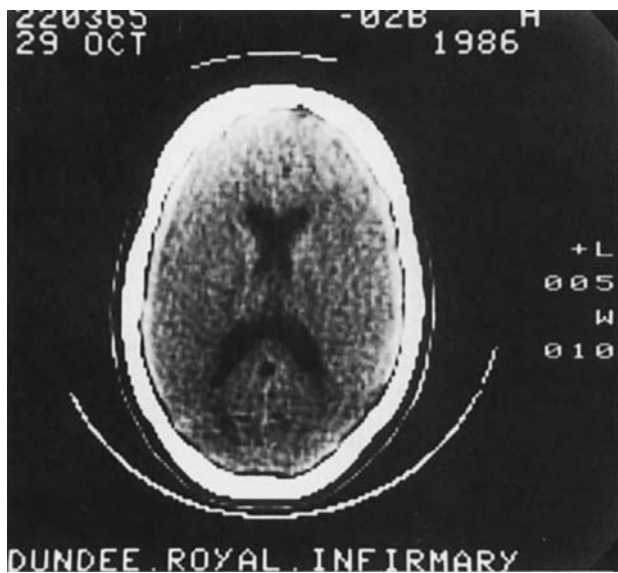


Fig. 1. CT scan of the head showing bilateral subdural haematomata.

mood swings were noted in addition to erratic, disorganised behaviour towards the infant. This was thought to be due to postnatal depression, but she persistently attributed her behaviour to the severe, unremitting headache.

On the eleventh postpartum day, she was transferred to the Psychiatric Assessment Unit for observation; she was discharged home after two weeks, with community support and no medication. She was readmitted to the Psychiatric Unit 10 days later following her self-confessed assault on her son. She had also made a serious suicide attempt, and a provisional diagnosis of puerperal psychosis was made. She began to vomit intermittently and continued to complain of intolerable headaches as the cause of her irrational behaviour. She also complained of blurred vision. Examination by an optician almost six weeks after delivery revealed bilateral papilloedema.

She gave a coherent history and showed no overt signs of psychological disturbance. There was no history, nor any external evidence, of head injury, and there were no focal neurological signs. A computerised tomographic (CT) scan of the brain revealed bilateral high density subdural haematomata (Fig. 1). A vascular abnormality was excluded by carotid angiography. Bilateral burr holes were performed and liquid subdural haematomata under pressure were drained. The consistency of the clot was in keeping with a subdural haematoma of five to six weeks duration.

Following an uneventful post-operative recovery, she was discharged home, free of symptoms. Her post-operative behaviour was unremarkable and psychiatric assessment revealed no evidence of psychosis. A further CT scan four weeks after surgery confirmed the complete resolution of the haematoma. A year later she remains well with no neurological symptoms.

Discussion

Minor postpartum psychiatric disorders are common,

occurring in 50 to 75% of mothers (Kumar 1989); they are seen so frequently that they may be regarded as a variant of normal (Harding 1989). Severe postnatal psychiatric disorders requiring admission to hospital occur in 0.2% of mothers and are most common after the first child. Of these severe cases, 66% will have symptoms in the first 15 days following childbirth (Kendell *et al.* 1987). Our patient's symptoms were therefore, understandably, attributed to psychiatric pathology, though her own explanation of intractable headaches as the cause of her irrational behaviour was ignored.

Subdural haematomata are not common in women of childbearing age (McKissock *et al.* 1960; Jack 1979). In the absence of coagulation defects (Scott 1949), they are usually caused by trauma. They are a rare but recognised complication of spinal anaesthesia and lumbar myelography (Dohrmann *et al.* 1983; Rudehill *et al.* 1983; Blake *et al.* 1987) and they may progress to a fatal outcome (Newrick & Read 1982). The accepted theory of aetiology of subdural haematoma complicating dural puncture is that leakage of cerebrospinal fluid (CSF) causes a reduction in CSF pressure and traction on thin walled dural blood vessels. These vessels can be torn, resulting in haematoma formation (Jonsson *et al.* 1983). Our patient had no recorded dural breach, but she did have more than one attempt at epidural catheterisation. It is most likely that the dura was breached at the first attempt. Pre-eclampsia is a recognised cause of subdural haematoma (Jack 1979) but this woman did not have pre-eclampsia.

Following dural puncture, persistent headache is the single most consistent symptom (Newrick & Read 1982; Van de Kelft *et al.* 1991). Medical supervision should continue until this symptom subsides (Jack 1979) and continuing headache should raise suspicion of an intracranial haematoma (Edelman & Wingard 1980). However, headache due to dural puncture does not always begin immediately. It may be up to 10 days after the procedure before symptoms develop (Dripps & Vandam 1951).

Subdural haematoma is a rare but accepted complication of procedures where the dura is punctured. This case report emphasises the importance of recognising an unusual but treatable cause of apparent puerperal psychosis.

References

- Blake D. W., Donnan G. & Jensen D. (1987) Intracranial subdural haematoma after spinal anaesthesia. *Anaesth Intens Care* **15**, 341-342.
- Dohrmann G. J., Elrick W. L. & Siu K. H. (1983) Intracranial subdural haematoma after lumbar myelography. *Neurosurgery* **12**, 694-696.
- Dripps R. D. & Vandam L. D. (1951) Hazards of lumbar puncture. *JAMA* **147**, 1118.
- Edelman J. D. & Wingard D. W. (1980) Subdural haematomas after lumbar dural puncture. *Anaesthesiology* **52**, 166-167.
- Harding J. J. (1989) Postpartum psychiatric disorders: a review. *Compr Psychiatr* **30** (1), 109-112.
- Jack T. M. (1979) Postpartum intracranial subdural haematoma. *Anaesthesia* **34**, 176-180.
- Jonsson L. O., Einarsson P. & Olsson G. L. (1983) Subdural haematoma and spinal anaesthesia. *Anaesthesia* **38**, 144-146.
- Kendell R. E., Chalmers J. C. & Platz C. (1987) Epidemiology of puerperal psychoses. *Br J Psych* **150** (5), 662-673.

- Kumar R. (1989) Postpartum psychosis. *Baillieres Clin Obstet Gynaecol* **3** (4) (Dec), 823–838.
- McKissock W., Richardson A. & Bloom W. H. (1960) Subdural haematoma: a review of 389 cases. *Lancet* **i**, 1365–1369.
- Newrick P. & Read D. (1982) Subdural haematoma as a complication of spinal anaesthetic. *Br Med J* **285**, 341–342.
- Rudehill A., Gordon E. & Rahn T. (1983) Subdural haematoma: a rare but life-threatening complication after spinal anaesthesia. *Acta Anaesthesiol Scand* **27**, 376–377.

- Scott M. (1949) Spontaneous nontraumatic subdural haematoma. *JAMA* **141** (9), 596–601.
- Van de Kelft E. *et al.* (1991) Intracerebral haemorrhage after lumbar myelography with Iohexol: report of a case and review of the literature. *Neurosurgery* **28** (4), 570–574.

Received 11 March 1992

Revised version received 8 September 1992

Accepted 6 October 1992

British Journal of Obstetrics and Gynaecology
August 1993, Vol. 100, pp. 784–785

An unusual case of traumatic primary amenorrhoea

DEIRDRE MURPHY *SHO*, JOHN BONNAR *Professor*

Trinity College Department of Gynaecology, St James's Hospital and Coombe Hospital, Dublin

Case report

A 22 year old single student midwife with a history of primary amenorrhoea was referred in September 1977 for a second opinion. She gave a history of normal breast development at 14 years of age similar to that of her mother and sisters. She had no cyclical, menstrual or ovulation symptoms and no abdominal pain. Previously she had been treated with clomiphene and oestrogens but no withdrawal bleeding had occurred. On examination she had normal secondary sexual characteristics. The vulva and vagina were normal, the cervix was palpable and the uterus felt small.

An X-ray of the pituitary fossa was normal, and the bone age was appropriate. Chromosomal analysis of a buccal smear showed a 46XX karyotype with no structural or numerical abnormalities. Serum FSH and LH were elevated at 33 mU/ml and 48 mU/ml, respectively. Prolactin was normal and oestradiol was 180 pg/ml. The possibility of primary ovarian failure was considered but the results were inconclusive as significant oestradiol production was present.

At laparoscopy there were extensive adhesions with no evidence of a corpus uteri, fallopian tubes or ovaries in the pelvis. The presumptive diagnosis was congenital absence of the corpus uteri, ovaries and fallopian tubes, presuming that some ovarian tissue must be present under the adhesions to account for the normal breast development.

Subsequently a more detailed history was obtained. At the age of two the patient sustained severe injuries in a road traffic accident when a truck drove over her lower abdomen and pelvis. She suffered a fractured pelvis and ruptured bladder. She underwent a bladder repair with a suprapubic cystostomy. There was no note of the ovaries or uterus being involved.

At subsequent laparotomy a cervical stump 3 cm long

with the bladder overlying its superior margin and extensive pelvic adhesions were found. The adhesions were divided and the corpus uteri, fallopian tubes and ovaries were found buried behind the sigmoid colon, completely separate from the cervix. A small haematometra of approximately 1 ml was present. The upper cervix was dissected and fibrous tissue was excised down to the cervical canal. The uterus was anastomosed to the cervix over a polyvinyl tube. A good anatomical result was achieved with a pelvis of virtually normal appearance.

Post-operatively she made a good recovery and regular menstruation began after two months. In January 1979 she married, and a hysterosalpingogram was performed in June 1979 which showed normal continuity between the cervical canal and the body of the uterus. In March 1983, she presented with a five week history of amenorrhoea and on ultrasound was found to have a normal intra-uterine pregnancy. She was delivered of a 2.8 kg male infant in October 1983 by elective caesarean section. She has had two further successful pregnancies both by caesarean section.

Discussion

This woman presents an unusual case of primary amenorrhoea due to traumatic avulsion of the corpus uteri from the cervix. An unusual feature was the absence of a marked haematometra despite presentation at 22 years of age with normal secondary sexual development from 14 years. This may be explained by an Asherman's type syndrome as in many such cases there has been no correlation between diminution of menstrual bleeding and the surface area of endometrium involved by adhesions. The absence of correlation is more apparent when the cervico-isthmic area is involved. It has been suggested that a visceral reflex originating in the area of the isthmus may inhibit endometrial proliferation and lead to hypomenorrhoea or amenorrhoea (Toaff & Ballas 1978). A similar phenomenon has been observed with endometrial abla-

Correspondence: Dr D. Murphy, Level 6, Maternity Department, John Radcliffe Hospital, Headington, Oxford OX3 9DU, UK.