

PSORIASIS CONTRALATERAL TO HEMIPARESIS FOLLOWING CEREBROVASCULAR ACCIDENT

JOHN K. SOWELL, M.D.,

MARK A. PIPPENGER, M.D., AND MICHAEL J. CROWE, M.D.

A 62-year-old white man presented for evaluation of a chronic unilateral eruption. His medical history was remarkable for a right hemispheric cerebrovascular accident (CVA) at age 38, which resulted in persistent left hemiparesis, as well as transient left-sided paresthesias. Within 6 months of the CVA, he developed cutaneous lesions only on the right side of his body (Figs. 1 and 2). These unilateral lesions persisted, with periodic exacerbations and partial remissions, but never involved the left side of his body. The patient used numerous over-the-counter creams and ointments without significant improvement. There was no family history of similar eruptions.

On physical examination, the patient exhibited erythematous, silvery-scaled plaques on the right elbow, knee, and lateral lower leg, consistent with psoriasis vulgaris. There were no lesions on the left side of his body. In addition, the patient wore an orthotic brace on the left (paralyzed, nonpsoriatic) leg for correction of foot drop.

On neurologic examination, the patient was alert and oriented, and his speech was fluent. His gait was slightly awkward, with the left leg held in extension. Cranial nerve examination was normal except for very mild facial weakness on the left side, without ptosis. There was significant weakness of the left arm extensors and left leg flexors. Sensation to pain and temperature was intact bilaterally, while graphesthesia and two-point discrimination were mildly impaired on the left. Deep tendon reflexes were hyperactive throughout the left side, and plantar response was extensor on the left. All these findings are consistent with right hemisphere cerebral infarction in the territory of the middle cerebral artery.

Head CT scan revealed evidence of an old infarction in the right fronto-parietal region, with cavitation and a mild shift of midline toward the lesion. EEG showed focal slowing in the right fronto-parietal region consistent with past infarction in this region. These findings were compatible with clinical findings of right hemispheric cerebral infarction.

Punch biopsy of the silver-scaled plaque on the right leg confirmed the clinical diagnosis of psoriasis vulgaris. The cutaneous lesions responded readily to anthralin cream 0.1% and amcinonide ointment 0.1%.

From the Departments of Dermatology and Neurology, University of Arkansas for Medical Sciences, Little Rock, Arkansas.

Address for correspondence: John K. Sowell, M.D., UAMS Department of Dermatology, 4301 W. Markham St., Slot 576, Little Rock, AR 72205.

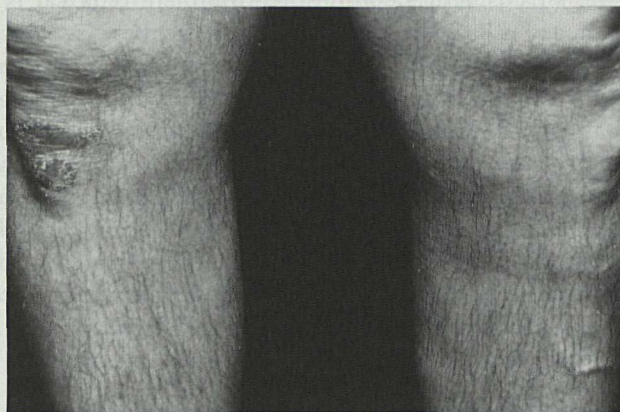


Figure 1. Psoriatic plaque limited to the right knee.

DISCUSSION

Two aspects of this case are of interest. The first is onset of psoriasis shortly following CVA. The second is the unilateral involvement of the disease.

The onset of psoriasis may occur at any age. It has been reported as early as birth and as late as age 108.¹ Given that both psoriasis and stroke are common ailments, one might reasonably expect that psoriasis might follow CVA in a small number of patients merely by coincidence. We were unable to find any reports of this temporal pattern in the English-language literature, although a possible association between psoriasis and occlusive vascular disease has been reported.² Since Braverman's description of microscopic changes in cutaneous blood vessels in psoriasis,³ it has been suggested that these changes could also be presented in other organ systems, possibly making them more susceptible to occlusive vascular disease.² There have been several reports in Russian literature linking central nervous system disease and psoriasis. Fedorova⁴ has reported the onset of psoriasis following cerebral injury. Of 190 patients with both psoriasis and organic diseases of the central nervous system, the onset of the CNS disease reportedly preceded the psoriasis in 22%. It was also reported that these patients tended to have psoriasis more recalcitrant to topical therapy. Fedorova hypothesized that some unknown cortical factor may be involved in the onset of the cutaneous lesions of psoriasis after CNS injury. To date, the nature of this

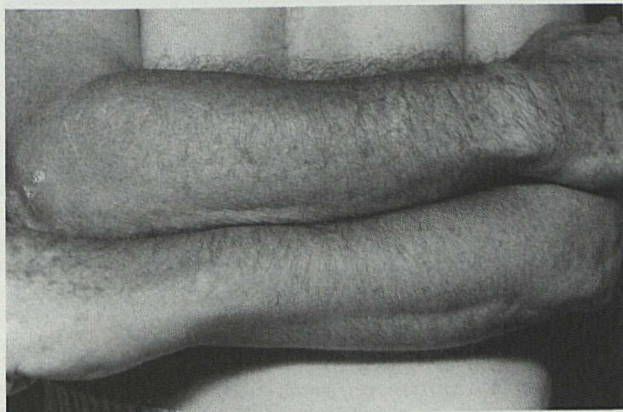


Figure 2. Psoriatic plaque limited to the right elbow.

suspected cortical factor has not been elucidated. Ena et al. have reported a slightly higher prevalence of occlusive vascular disease in 100 hospitalized psoriatics, as compared to age and sex matched hospitalized controls.⁵ They noted elevated plasma renin activity and an increased prevalence of hypertension in the psoriatics, and postulated that psoriatic microangiopathy as described by Braverman may be responsible for activating the renin-angiotensin system, thus producing hypertension and in turn increasing the likelihood of occlusive vascular disease.

Next, a few explanations could be offered for the unilateral distribution of the psoriatic lesions in our patient. A possible explanation is the Koebner phenomenon. One might expect a greater frequency of minor trauma on the limbs that are unaffected by the hemiparesis, as these are the most frequently used;⁶ however, our patient wears an orthotic brace, a source of much trauma, on his left (uninvolved) leg. If minor trauma were the explanation for his psoriasis distribution, one might reasonably expect some lesions in proximity to his brace. He also relates a history of frequently "bumping into things" with his paralyzed left arm

and leg, without precipitating lesions of psoriasis. A second possible explanation for the onset of unilateral psoriasis might be that some cortical factor, as postulated by Fedorova, is involved in the pathogenesis. Another possible link between a cortical factor and skin disease is unilateral neurogenic pruritus, which has been reported to occur in patients following stroke, ipsilateral to the hemiparesis.⁷

Thus, we agree with Fedorova that after CVA it is possible that some as yet unknown factor may be altered or released, affecting the CNS in a unilateral manner. Through neurocutaneous interaction, this may precipitate cutaneous lesions of psoriasis in a similar unilateral manner.

To the best of our knowledge, this is the first English language report of unilateral psoriasis with onset after CVA.

REFERENCES

1. Buntin DM et al. Onset of psoriasis at age 108. *J Am Acad Dermatol* 1983; 9:276-277.
2. McDonald CJ, Calabresi P. Psoriasis and occlusive vascular disease. *Br J Dermatol* 1978; 99:469-475.
3. Braverman IM. Electron microscopic studies of the microcirculation in psoriasis. *J Invest Dermatol* 1972; 59:91-98.
4. Fedorova ML, Fedorov SM. State of the nervous system in psoriasis patients. *Zh Nevropatol Psikhiatr* 1976; 76:1627-1631.
5. Ena P, Madeddu P, Glorioso N, et al. High prevalence of cardiovascular diseases and enhanced activity of the renin-angiotensin system in psoriatic patients. *Acta Cardiol (Brux)* 1985; 40:199-205.
6. Farber EM, Nall ML. The natural history of psoriasis in 5,600 patients. *Dermatologica* 1974; 148:1-18.
7. Shapiro PE, Braun CW. Unilateral pruritus after a stroke. *Arch Dermatol* 1987; 123:1527-1530.

Abstract-Sexually Transmitted Diseases in Chile

During 1987 and 1988 sexually transmitted diseases affected 87.2 per 100,000 inhabitants of the Vina del Mar-Quillota area. At all ages rates were 3.8 times higher in men compared with women, gonorrhea, syphilis, and nongonococcal urethritis accounted for most cases. In men, 82% of cases were due to gonorrhea, in women 50% were due to gonorrhea and 50% to syphilis. Rural and urban figures were not significantly different, except for HIV infection, which was predominantly urban. Rates of different infections peaked at different ages: HIV between 30 and 39, gonorrhea from 15 to 29, syphilis from 40 to 49 and after 60, and nongonococcal urethritis from 15 to 59. In a survey of affected subjects 85% were stated to be heterosexual, 10% omitted a response. *From Fernandez SML, Lopez B, Ilse M. Epidemiology of sexually transmitted diseases in the Vina Del Mar-Quillota area, Chile. Rev Med Chile* 1991; 119: 1213-1218 (Spanish). (Submitted by Yehudi M. Felman, M.D., Brooklyn, New York.)

This document is a scanned copy of a printed document. No warranty is given about the accuracy of the copy. Users should refer to the original published version of the material.