

# Alternating Hemiplegia Syndrome: Electroencephalogram, Brain Mapping, and Brain Perfusion SPECT Scan Study in a Chinese Girl

Virginia Wong, MBBS, MRCP(UK), DCH(London), DCH(Glasgow); Gerrit C.L. Ho, MBBS, MSc; Henry W.D. Yeung, MBBS, FRCR(UK), ABIM; K.M. Ma, MBBS, MRCP

## Abstract

A 3-year-old Chinese girl with alternating hemiplegia syndrome failed to respond to anticonvulsants, antimigrainous drugs, and calcium channel blockers. She made a complete remission with a 4-week course of steroid, and relapsed after steroid withdrawal. Electroencephalogram and brain mapping during the hemiplegic attack showed unilateral high-voltage sharp slow-wave discharges in the temporo-occipital region contralateral to the hemiplegic side and diffuse high-voltage slowing during attacks of quadriplegia or other clinical manifestation such as dullness, lethargy, or yawning. Brain perfusion single photon emission computed tomographic (SPECT) scan study during the attack showed decreased uptake in the temporoparietal region contralateral to the hemiplegic side and in the ipsilateral basal ganglia, whereas the perfusion was normal between attacks. Electroencephalogram background activity was improved while the child was in clinical remission with steroid treatment. Computed tomographic and magnetic resonance imaging scans of the brain were normal. Carotid angiogram failed to show any structural or dynamic changes of the carotid arteries. The possible mechanism underlying alternating hemiplegia syndrome might be transient and reversible cerebral ischemia with high-voltage slow-wave discharges shown in the electroencephalogram and decreased perfusion in SPECT scan. (*J Child Neurol* 1993;8:221–226).

Alternating hemiplegia syndrome consists of recurrent attacks of hemiplegia occurring on alternating sides associated with oculomotor abnormalities and other paroxysmal phenomena such as dystonia, choreoathetosis, or autonomic disturbances. These children usually have associated men-

tal or neurologic abnormalities.<sup>1</sup> The exact mechanism causing the hemiplegic attacks is not known. Possible relationship to migrainous or epileptic phenomena has been postulated.<sup>1–6</sup> The overall prognosis is guarded, because trials with anticonvulsants and antimigrainous drugs have failed to abort the attacks.<sup>1,2,5</sup>

We report changes in the electroencephalogram (EEG), brain mapping and brain perfusion single photon emission computed tomographic (SPECT) scan in a 3-year-old Chinese girl with intractable episodes of alternating hemiplegia or quadriplegia. She failed to respond to anticonvulsants, antimigrainous drugs, and calcium channel blockers but

Received Feb 25, 1992. Received revised May 20, 1992. Accepted for publication June 11, 1992.

From the Department of Paediatrics (Dr Wong), University of Hong Kong, Queen Mary Hospital and the Department of Nuclear Medicine (Drs Ho, Yeung, and Ma), Queen Mary Hospital, Hong Kong.

Address correspondence to Dr Virginia Wong, Department of Paediatrics, University of Hong Kong, Queen Mary Hospital, Pokfulam Road, Hong Kong.

made a complete remission with a short course of steroid treatment and then relapsed on its withdrawal.

### Case Report

L.W.M. was a 3-year-old Chinese girl born by cesarean section for breech presentation with a birth weight of 3.1 kg. Antenatally, the mother noted decreased fetal movement all through her pregnancy. There was no perinatal asphyxia. She was noted to be hypotonic from birth.

At the age of 2 months, she was noted to have deviation of eyes and head to her left, with loss of consciousness for about 30 minutes. There was no clonic twitching of the limbs. She remained drowsy after the attack. At 5 months of age, she had staring followed by deviation of eyes and head to her left, with clonic twitching of all four limbs and associated loss of consciousness for 5 minutes. She was admitted into Queen Mary Hospital, the University of Hong Kong teaching hospital. Thereafter, she was noted to have repeated attacks of up-rolling of eyes and deviation of eyes or head turning to her left or right side. EEG did not show any focal abnormalities. She was started on carbamazepine.

At the age of 7½ months, she was noted to have deviation of eyes to the left with sudden loss of movement of her left upper and lower limbs and a blank expression lasting for 36 hours. With the return of movement on her left side, she was noted to have decreased movement of her right upper and lower limbs lasting for 24 to 36 hours. She was fully conscious during the attack.

Thereafter, she had recurrent attacks of alternating hemiparesis/hemiplegia and quadriplegia/quadruplegia. The frequency varied from one attack per week to 30 attacks per day. Each attack lasted from 10 minutes to 48 hours. Preceding the attack, she was usually dull and tired looking. Her face sometimes turned pale, and circumoral cyanosis sometimes appeared. Sometimes, dilated veins were seen on one side of the forehead unrelated to the hemiparetic side. She was very miserable and irritable during the attack and cried a lot. The hemiparesis alternated on both sides repeatedly or remained on the same side during the attack. She was fully conscious during the attack, and she could still shake her head to indicate that she could not move her limbs. Her speech was slurred with a low pitch quality. Occasionally, she was aphasic, and tears sometimes ran out continuously from one eye, usually on the same side as the hemiparesis. Her muscle tone was extremely hypotonic during the attacks, but fluctuation to slight rigidity occasionally occurred. Her big toes were sometimes dorsiflexed with a clustering together of the other toes. There was sometimes associated coarse tremor of the hemiparetic or normal hand. Her pupils were sometimes relatively dilated. Tachycardia and, sometimes, decreased respiratory movement occurred during the attack. After the attack, she was usually tired and slept for a long time. She usually woke up feeling refreshed, with disappearance of the hemiparesis. Her attacks may have been precipitated by stress but were unrelated to sleeping pattern.

Her developmental milestones were delayed. She achieved head control at 4 months of age, sat with support

at age 10 months, and walked with support at 2½ years of age. She started to say single words at age 2 years. Her mental age was in the mild mental retardation range.

The mother had a history of recurrent frontal headache since her youth, but she had no symptoms suggestive of migraine. There was no family history of periodic paralysis. Physical examination of the child showed generalized hypotonia with no muscle weakness between attacks. During attacks, she had generalized hypotonia and weakness (unilateral or generalized) and brisk deep tendon reflexes, but negative Babinski reflexes.

The following investigations were found to be normal: complete blood count; erythrocyte sedimentation rate; renal, liver, and thyroid function tests; and serum levels of potassium, magnesium, glucose, ammonia, creatine kinase, lactate, and pyruvate. Tests for antinuclear factor, rheumatoid factor, and anti-DNA antibodies were negative, as were anticardiolipin antibody, lupus anticoagulant, and antineutrophil cytoplasmic antibody examinations. Urine analysis for amino acids, organic acids, and metabolic screening was negative. Nerve conduction study and electromyogram results were normal. Muscle biopsy showed no evidence of mitochondrial myopathy. Computed tomographic and magnetic resonance imaging scans of the brain and brain-stem auditory evoked potential were normal. Carotid angiogram failed to show any stenosis of the carotid arteries. Echocardiogram and Holter monitoring were normal.

Prolonged video-EEG monitoring and brain mapping with a 16-channel Concerto machine (Dantec) showed that the clinical attacks were not associated with any spike wave discharges. Diffuse high-voltage slow delta activities occurred during attacks of dullness, lethargy, loss of speech, yawning, and tearing without clinical evidence of hemiplegia (Figure 1). Bursts of generalized high-voltage slow delta waves occurred for a prolonged period of time during the sleeping stage after an attack. During a hemiplegic attack, slowing of the background activity with high-voltage slow delta or theta waves occurred in both temporo-occipital regions or sometimes contralateral to the hemiplegic side (Figure 2). Photic stimulation induced asymmetrical photic recruitment response, with absent response ipsilateral or contralateral to the hemiplegic side during the attack.

Three sets of <sup>99m</sup>Tc-hexamethylpropylenamine oxide (HMPAO) SPECT scans were performed between attacks, in the left hemiplegic state, and in the right hemiplegic state. Commercially supplied HMPAO (Amersham Co) brain agent was freshly labeled with 25 to 30 mCi <sup>99m</sup>Tc in 5 mL eluate. In the baseline state between attacks (upper row, Figure 3), the uptake of <sup>99m</sup>Tc-HMPAO was normal and symmetrical in the cerebral hemispheres, basal ganglia, and cerebellum. However, during the hemiplegic attack, there was decreased uptake detected in the cerebral hemisphere contralateral to the side of hemiplegia. In the case of left hemiplegic attack (middle row, Figure 3), hypoperfusion was detected in the right frontal, parietal, and occipital regions and the left basal ganglia. During an attack of right hemiparesis, the child had dystonic posturing of the right upper limb with mild tremor and the paralysis was only mild (lower row, Figure 3). Hypoperfusion during this attack was more subtle because it was detected only in a small segment of the left anterior parietal lobe and in the right basal ganglia. The uptake in the cerebel-

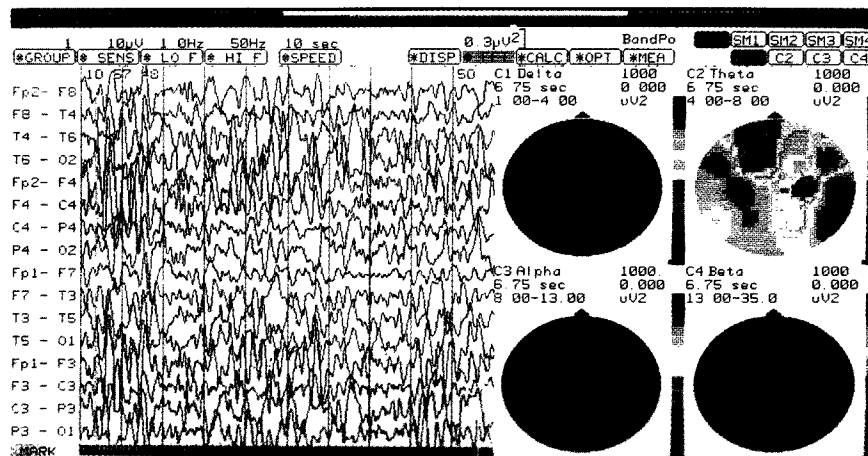


FIGURE 1 EEG and brain mapping during an attack of dullness, irritability, prolonged crying, and slurring of speech, with no hemiplegia. The red to blue areas are indicative of regions of high to low spectral energy, respectively, in different frequency bands (delta, theta, alpha, and beta). Diffuse high-voltage slow delta waves (upper left) and bilateral temporo-occipital theta waves (upper right) are seen in the brain mapping study (vertex view).

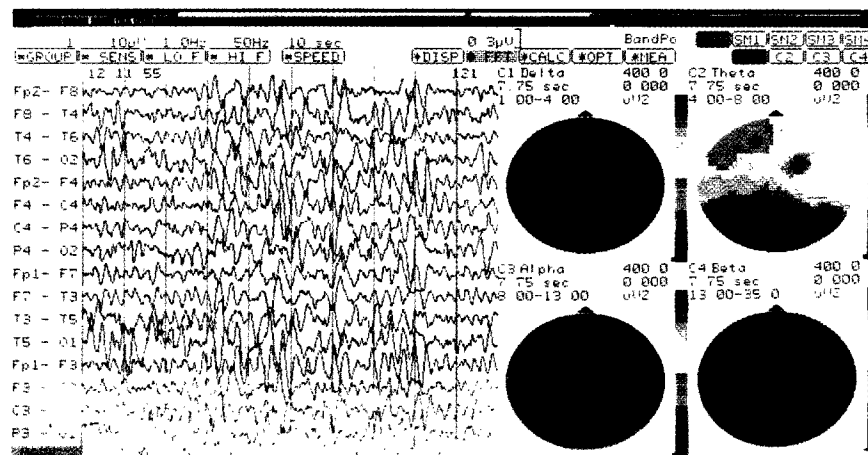


FIGURE 2 EEG and brain mapping during an attack of left hemiplegia showing diffuse high-voltage slow delta wave discharges (upper left) and increased theta activities over right temporocentral and left temporoparietal regions.

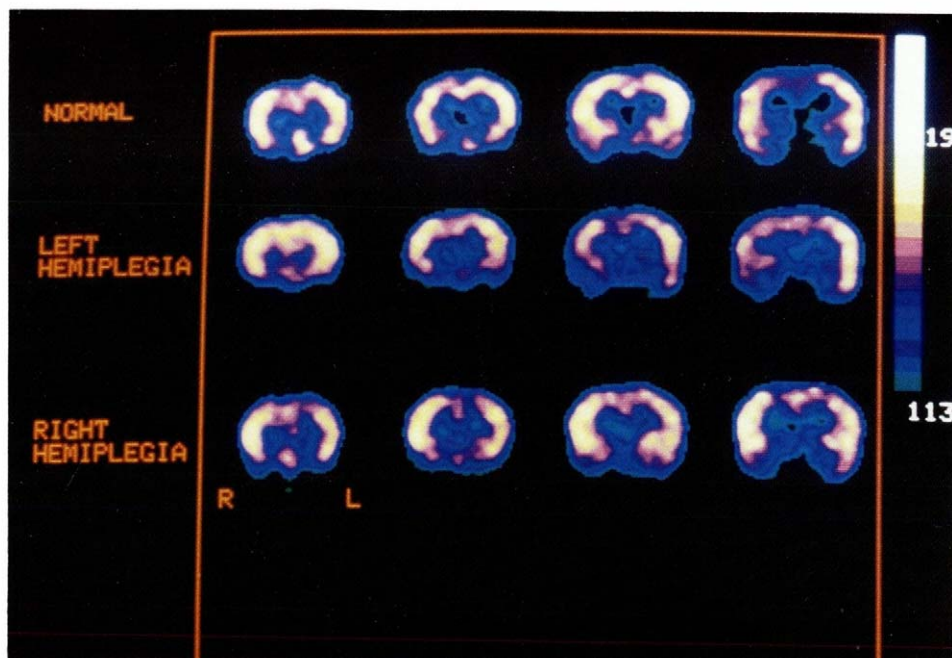


FIGURE 3  
 $^{99m}\text{Tc}$ -HMPAO SPECT scan showing four coronal cuts of the three sets of imaging; (1) between attacks (top row), (2) left hemiplegia (middle row), and (3) right hemiplegia (bottom row). The yellow to blue areas are indicative of high to low  $^{99m}\text{Tc}$ -HMPAO uptake, respectively.

lum was symmetrical during the three clinical states and was therefore used as the maximal reference intensity for qualitative interpretation.

Our patient was administered sodium valproate, carbamazepine, phenytoin, and propranolol, with no improvement. A short trial of flunarizine for 2 months failed to abort the attacks. Because of the possibility that arteritis was causing vasospasm, betamethasone, 4 mg twice daily (the equivalent of 2 mg/kg prednisone per day), was tried. The attacks were completely aborted 2 days after administration, associated with marked improvement in EEG background activity. She could walk around steadily, and her mood was improved. Due to the appearance of marked cushingoid features, betamethasone was stopped at the request of the parents after a 4-week course. This was associated with immediate relapse of the attacks. Because the parents refused to retry steroid due to the occurrence of marked cushingoid features, we could not substantiate its continued therapeutic usefulness.

## Discussion

Our case, with typical features of alternating hemiplegia syndrome, showed poor response to anticonvulsants, antimigrainous drugs, and calcium channel blockers but made a complete remission with a 4-week course of steroid and relapsed after its withdrawal.

Alternating hemiplegia syndrome was first described in eight children with intermittent alternating

hemiplegia associated with vasomotor prodrome.<sup>2</sup> Periodic cerebral vascular ischemia related to migraine was postulated as the basis of the symptoms. Symptoms of migraine occurred in some of these children on follow-up. Subsequent reports<sup>1-6</sup> of alternating hemiplegia syndrome showed controversy in differentiating the underlying mechanism for the attacks, whether related to seizure or migraine. "Ictal" EEG in some cases showed slow-wave abnormalities or seizure discharges. The response to anticonvulsants was notably poor.

In 1984, Caesar and Azou<sup>7</sup> reported dramatic improvement in alternating hemiplegia syndrome with flunarizine, a calcium channel blocker. A subsequent international trial with 12 children<sup>8</sup> showed the usefulness of flunarizine in aborting the hemiplegic attacks. The mechanism of action might be related to the antihypoxic, antivasoconstrictive, and anticonvulsive activity of flunarizine.<sup>9</sup> Other studies also substantiated the usefulness of flunarizine in aborting the attacks.<sup>10,11</sup> The response of alternating hemiplegia syndrome to flunarizine was more rapid than the usual gradual improvement of migrainous symptoms in children and adults.<sup>9-11</sup> However, our patient failed to respond to a trial of 2 months' treatment with 5 mg flunarizine daily.

EEG findings of high-voltage slow-wave discharges in the contralateral and/or bilateral temporo-occipital regions during the prodrome or hemiplegic attacks in our case suggest decreased blood flow as the possible mechanism of hemiplegia and the associated autonomic manifestation. We failed to demonstrate any anatomic or dynamic occlusion of the carotid arteries with the angiogram. A short, 4-week course of betamethasone was tried for possible arteritis in causing recurrent cerebrovascular ischemia. The dramatic response with total absence of hemiplegic attacks and improvement of behavior, together with immediate deterioration with relapse of hemiplegia, quadriplegia, and tremor at a lower dose of betamethasone proved the clinical efficacy of the steroid. Serial EEG recordings documented the return to normal background activity, with loss of high-voltage slow-wave activity. Four days after stopping steroid treatment, the clinical attacks recurred and the EEG became abnormal again.

The usefulness of steroid in alternating hemiplegia syndrome has not been previously reported. The clinical and EEG remission induced by steroid therapy, with relapse during the withdrawal period in our case is interesting. Unfortunately, we were unable to document the continued usefulness of steroid in this disease, due to parental refusal of drug continuation. Alternating hemiplegia syndrome is a rare disease and further case-control study with steroid treatment is worthwhile. It is still too premature to document the usefulness of steroid in this rare condition because the therapeutic trial was short.

Recent reports<sup>12-15</sup> on cerebral perfusion during and between attacks with the use of brain perfusion SPECT scan showed conflicting results. Zupanc et al<sup>14</sup> showed hypoperfusion in the left cerebral hemisphere during an episode of right hemiplegia in a 17-month-old girl, which resolved with clinical improvement. The authors postulated vasospasm the probable cause of the transient reversible hypoperfusion of the contralateral hemisphere. EEG also showed focal slowing over the hypoperfused hemisphere during the attack. This case was similar to our child with focal hypoperfusion in SPECT scan and focal slowing in EEG except that our case also showed hypoperfusion in the ipsilateral basal ganglia as well.

However, Kanazawa et al<sup>15</sup> showed ictal hyperperfusion in the hemisphere contralateral to the hemiplegic side and symmetric uptake during the normal period. Thus, the authors postulated alternating hemiplegia syndrome as an atypical manifestation of epilepsy. Their case was a 12-month-old

boy with possible cerebral palsy and mental retardation, and focal spike discharges were shown in the interictal EEG. Thus, the SPECT scan study during the attack with hyperfusion might be actually detecting an underlying seizure phenomenon. Whether the hyperfusion was related to a genuine epileptic attack instead of a vasospasm-induced hemiplegia is unknown because children with alternating hemiplegia syndrome usually had epilepsy as well.

The tracers used were different in the two studies. <sup>123</sup>I-Iodoamphetamine (IMP) was used in the study by Zupanc et al<sup>14</sup> with hypoperfusion, whereas <sup>99m</sup>Tc-HMPAO was used in the study by Kanazawa et al with hyperperfusion.<sup>15</sup> Because both the Kanazawa group and our study used the same perfusion agent but yielded contradictory results, it is unlikely that the radiopharmaceutical biochemistry or kinetics resulted in the differences. This can be further supported by the fact that despite the different uptake kinetics and intracerebral binding stability of <sup>99m</sup>Tc-HMPAO and <sup>123</sup>I-IMP, we have obtained similar hypoperfusion results to those of Zupanc's group. Furthermore, the Kanazawa group reported only slight, relative hyperfusion without EEG paroxysmal discharges during an attack, which is again different from our findings.

The results of our SPECT scan study using <sup>99m</sup>Tc-HMPAO are more in line with the finding by Zupanc et al of decreased cerebral perfusion during an attack. Strangely enough, in our case, the clinical attack of left hemiplegia was associated with a markedly decreased perfusion in the right temporoparietal region, whereas the mild right hemiparesis with dystonia of right upper limb and tremor of right hand was associated with only slightly decreased perfusion in the left anterior parietal area. There seemed to be a good correlation between the degree of clinical attack and the degree and extent of hypoperfusion in our case. It is interesting to note that there was mildly decreased uptake shown in the basal ganglia ipsilateral to the hemiplegic side during the attacks. Whether this might be due to the results of the remote interruptive effects of trans-hemispheric diaschisis<sup>16</sup> is still to be investigated. This is similar to positron emission tomographic scan finding in alternating hemiplegia syndrome as reported by Tada et al<sup>17</sup> in an 11-year-old boy who showed a slight decrease in cerebral blood flow at the insula, putamen, and claustrum of the left side during an attack of right hemiplegia.

Thus, we postulate that transient vasospasm is the underlying mechanism for the recurrent hemiplegic attacks due to EEG, brain mapping, and brain

perfusion SPECT scan changes seen during and between the attacks. Alternating hemiplegia syndrome might be an intermittent paroxysmal movement disorder rather than being epileptic in nature. The mechanism underlying the dramatic response to steroid and relapse after its withdrawal is unknown. The decreased blood supply to the middle cerebral artery with resultant decreased blood flow to the frontal, parietal, and temporal lobes could account for the hemiplegia, quadriplegia, and aphasia. Decreased blood supply to the posterior cerebral artery with resultant ischemia to the basal ganglia could account for the extrapyramidal manifestation of dystonia, rigidity, choreoathetosis, and tremor of the limbs. Further study of this disease is warranted, especially using brain perfusion SPECT scan studies in relation to steroid treatment, in order to elucidate the basic mechanism underlying this rare disorder.

#### Acknowledgment

The authors would like to thank Mrs T. Wong for her secretarial assistance and Mr J. Ng for technical support.

#### References

1. Krageloh I, Aicardi J: Alternating hemiplegia in infants: Report of five cases. *Dev Med Child Neurol* 1980;21:784-791.
2. Clarke JM: On recurrent motor paralysis in migraine (with report of a family in which recurrent hemiplegia accompanied the attacks). *Br Med J* 1910;1534-1538.
3. Dynes JB: Alternating hemiparetic migraine syndrome. *Br Med J* 1939;2:446-447.
4. Golden GS, French JH: Basilar artery migraine in young children. *Pediatrics* 1975;56:722-726.
5. Hosking GP, Cavanagh NPC, Wilson J: Alternating hemiplegia: Complicated migraine of infancy. *Arch Dis Child* 1978;53:656-659.
6. Shirasaka Y, Ito M, Okuno T, et al: Epileptic seizures difficult to differentiate from alternating hemiplegia in infants: A case report. *Brain Dev* 1990;12:521-524.
7. Caesar P, Azou M: Flunarizine in alternating hemiplegia in childhood. *Lancet* 1984;2:579.
8. Casaer P, Aicardi J, Curatolo P, et al: Flunarizine in alternating hemiplegia in childhood. An international study in 12 children. *Neuropediatrics* 1987;18:191-195.
9. Curatolo P, Cusmai R: Letter to the editor. *Lancet* 1984;2:980.
10. Caers LI, De Beukelaar FD, Amery WK: Flunarizine, a calcium-entry blocker, in childhood migraine, epilepsy and alternating hemiplegia. *Clin Neuropharmacol* 1987;10:162-168.
11. Campistol PJ, Sans Fito A, Pineda Marfa M, et al: Alternating hemiplegia in infancy; Clinical features, clinical course and treatment based on three cases. *An Esp Pediatr* 1990;32:336-338.
12. Siemes H, Caesar P: Alternating hemiplegia in childhood. Clinical report and single photon emission computed tomography study. *Monatsschr Kinderheilkd* 1988;136:467-470.
13. Hattori H, Hashizuka S, Matsuoka O, et al: Alternating hemiplegia in infants: A case report with abnormal findings in ABR (auditory brainstem responses) and SPECT (single photon emission CT). *Jpn J Pediatr* 1989;42:77-82.
14. Zupanc M, Dobkin JA, Perlman SB: <sup>123</sup>I-Iodoamphetamine SPECT brain imaging in alternating hemiplegia. *Pediatr Neurol* 1991;7:35-38.
15. Kanazawa O, Yoshiyuki S, Hattori H, et al: Ictal <sup>99m</sup>Tc-HMPAO SPECT in alternating hemiplegia. *Pediatr Neurol* 1991;7:121-124.
16. Andrew RJ: Transhemispheric diaschisis, a review and comment. *Stroke* 1991;22:943-949.
17. Tada H, Miyake S, Yamada M, et al: A patient with alternating hemiplegia in childhood. *No To Hattatsu* 1989;21:283-288.