

# Stroke and Mixed Connective Tissue Disease

William D. Graf, MD; Jerrold M. Milstein, MD; and David D. Sherry, MD

## Abstract

We describe the clinical presentation and course of two girls with cerebrovascular disease and mixed connective tissue disease. One developed rapid onset hemiparesis and aphasia secondary to left internal carotid artery occlusion. She experienced a complete recovery after treatment with prednisone and cyclophosphamide. The other patient was diagnosed as having mixed connective tissue disease but had acute neurologic deterioration. She died due to an intracerebral hemorrhage. Autopsy demonstrated small-vessel fibrinoid necrosis. Although cerebrovascular disease secondary to central nervous system vasculitis is a manifestation of systemic lupus erythematosus, this is the first description of cerebrovascular disease as a primary sign in mixed connective tissue disease. These cases demonstrate the range of cerebrovascular disease observed in children with mixed connective tissue disease. (*J Child Neurol* 1993;8:256-259).

Mixed connective tissue disease is currently thought to be a distinct syndrome characterized clinically as an overlap of systemic lupus erythematosus, scleroderma, arthritis, and polymyositis.<sup>1</sup> The spectrum of various clinical and serologic features of mixed connective tissue disease as they compare to similar rheumatic conditions is shown in Table 1. Serologically, the diagnosis of mixed connective tissue disease is made by the demonstration of high titer antinuclear antibodies, in a speckled pattern, due to antibodies to ribonuclear protein, and the absence of anti-Smith or anti-DNA antibodies.<sup>2,3</sup> A variety of neurologic complications may be seen in patients with mixed connective tissue disease as well as related collagen-vascular diseases. Although intracranial vasculitis and stroke are common in patients with systemic lupus erythematosus, cerebral vasculopathy has not been described in mixed connective tissue disease.<sup>2,4-9</sup>

Cerebrovascular disease is uncommon in children; however, when present, it is often due to rare

but identifiable and treatable disorders.<sup>10</sup> The following case reports describe a complete left internal carotid occlusion in a previously healthy 9-year-old girl, who was subsequently identified as having mixed connective tissue disease, and a fatal intracerebral hemorrhage in a 13-year-old girl who was previously diagnosed with mixed connective tissue disease. Both cases illustrate the need to consider the diagnosis of mixed connective tissue disease in children with cerebrovascular disease.

In addition, we discuss the diagnosis and pathophysiology of mixed connective tissue disease as it pertains to the nervous system.

## Case Reports

### Patient 1

A 9-year-old girl was in good health until 2 days prior to admission, when she took a warm bath, fell asleep in the bath tub (which was unusual for her), and upon awakening, discovered that she had both weakness and numbness in her right arm and leg. She was noted to have a right hemiparesis, a shuffling gait, and an episode of urinary incontinence. Serum electrolytes and complete blood count were normal; erythrocyte sedimentation rate was 32 mm/hour. Cranial computed tomographic scan was normal. The next day she awoke with aphasia, had an episode of incontinence, and was transferred to our institution. Her past history was unremarkable.

Physical examination revealed an alert, cooperative, healthy-looking girl. She was afebrile; vital signs, including blood pressure, were normal. There was no facial rash;

Received June 23, 1992. Received revised Sept 23, 1992. Accepted for publication Oct 1, 1992.

From the Department of Pediatrics, Divisions of Neurology (Drs Graf and Milstein) and Rheumatology (Dr Sherry), Children's Hospital and Medical Center, University of Washington, Seattle WA.

Address correspondence to Dr William D. Graf, Department of Pediatrics, Division of Congenital Defects, Children's Hospital and Medical Center, 4800 Sand Point Way NE, Mail Stop CH-47, Seattle, WA 98105.

TABLE 1  
Clinical and Serologic Features of Mixed Connective Tissue Disease Compared to Systemic Lupus Erythematosus and Scleroderma

| Features                           | MCTD | SLE | Scleroderma |
|------------------------------------|------|-----|-------------|
| Raynaud's phenomenon               | +++  | +   | +++         |
| Serositis                          | ++   | +++ | +           |
| Inflammatory myositis              | ++   | +   | +           |
| Truncal scleroderma                | -    | -   | +++         |
| Proliferative glomerulonephritis   | +    | +++ | -           |
| Pulmonary fibrosis                 | +    | +   | +++         |
| Pulmonary hypertension             | +++  | +   | ++          |
| Seizures or psychosis              | +    | ++  | -           |
| Erosive polyarthritis              | ++   | -   | +           |
| Antinuclear antibodies             | +++  | +++ | +++         |
| Anti-DNA antibodies                | -    | +++ | -           |
| Antiribonuclear protein antibodies | +++  | ++  | +           |
| Anti-Smith antibodies              | -    | ++  | -           |
| Hypocomplementemia                 | +    | +++ | -           |

MCTD = mixed connective tissue disease; SLE = systemic lupus erythematosus.

however, a mild diffuse truncal rash was noted. Examination of the hands showed proximal thickening of the fingers and pinpoint necrotic lesions on the fingertips; there was limited flexion of the middle carpal phalanges joints. Cardiac examination was normal. She had moderate difficulties in word finding, reading, calculation, memory, and expressive language. The cranial nerve examination, including visual fields and funduscopy were normal. She had severe right flaccid hemiparesis, right hemihypesthesia, right hyperreflexia, and a right extensor plantar reflex.

An electroencephalogram showed left rhythmic high-voltage slowing. Repeat cranial computed tomographic scan 4 days after the onset of symptoms demonstrated a focal low density with mass effect in the left internal capsule, caudate nucleus, and centrum semiovale. A cerebral angiogram demonstrated occlusion of the left internal carotid artery in the suprasellar segment, with some delayed and incomplete filling of several middle cerebral artery branches (Figure 1A, arrow). Left anterior cerebral and middle cerebral arteries filled well by collaterals from the right anterior communicating arteries and the posterior circulation (Figure 1B, arrow). Normal laboratory studies included electrocardiogram and echocardiogram, coagulation studies, urine nitroprusside reaction, serum cholesterol and triglyceride levels, cerebrospinal fluid chemistries, and cell count. Repeat erythrocyte sedimentation rate was 25 mm/hour. Antinuclear antibodies were present (1:10,240) in a speckled pattern. A diagnosis of mixed connective tissue disease was made on the basis of sclerodactyly, arthritis, high-titered speckled antinuclear antibodies, a positive extractable nuclear antibody, antiribonuclear protein antibodies in high titer (1:256), and absence of anti-double stranded DNA and anti-Smith antibodies. Other pertinent positive studies included positive antineuronal antibodies, an abnormal upper-gastrointestinal barium study showing moderately severe gastroesophageal reflux, and abnormal pulmonary function studies (moderate re-

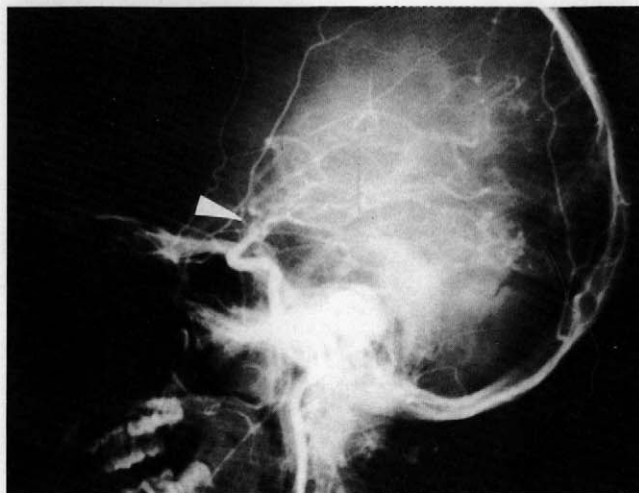


FIGURE 1A

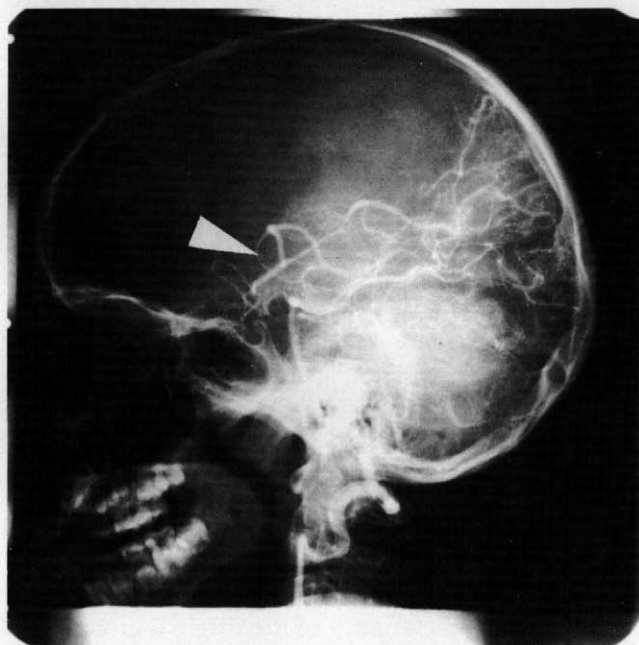


FIGURE 1B

FIGURE 1

(A) Lateral view of cerebral angiogram in patient 1 demonstrating occlusion of the left internal carotid in the suprasellar segment (arrowhead). (B) Left vertebral artery angiogram showing filling of the left middle cerebral artery via collaterals from the posterior circulation (arrowhead).

strictive and mild obstructive lung disease). Other pertinent negative or normal tests included normal cerebrospinal fluid index (ratio of cerebrospinal fluid immunoglobulin G to albumin divided by the ratio of serum immunoglobulin G to albumin), Lyme titers,  $C_3$ ,  $C_4$ ,  $CH_{50}$  assay for total complement prothrombin time, partial thromboplas-

tin time, and anticardiolipin antibodies in serum and cerebrospinal fluid.

Treatment included prednisone, 60 mg/day; D-penicillamine, 125 mg/day; and cyclophosphamide, 700 mg/m<sup>2</sup> once monthly for seven doses and then every 3 months for 3 years; and aspirin, 162 mg/day. She slowly regained full neurologic function but has slightly increased right tendon reflexes. She is in remission 3 years after presentation and is off all medication except D-penicillamine.

### Patient 2

A 13-year-old girl with recurrent parotitis was diagnosed with mixed connective tissue disease; she had a high titer of speckled pattern antinuclear antibodies, antibodies to ribonuclear protein, positive anti-Ro and negative anti-Smith antibodies, and normal complement studies. She subsequently developed nephritis, hepatitis, and interstitial pneumonia. Slowing on electroencephalogram was incidentally noted. She developed severe headache, fever, and cerebrospinal pleocytosis; she was treated with broad spectrum antibiotics despite negative cerebrospinal fluid cultures. One week later, she had a generalized tonic-clonic seizure, required ventilator support, and was treated with high-dose intravenous methylprednisolone (1 g/12 hours) and one dose of cyclophosphamide (10 mg/kg). Renal and pulmonary function worsened, and severe pancytopenia developed. Two days later, she became comatose, with deteriorating liver function. Plasmapheresis was performed, but she developed an intracerebral hemorrhage requiring surgical evacuation, and she never regained consciousness. Autopsy demonstrated severe cerebral edema, a large intracerebral hematoma cavity in the left parietal-occipital region, and herniation of the necrotic brain through the surgical craniotomy defect. Intracerebral capillary endothelial cells showed severe cytoplasmic vacuolation and reactive atypical nuclei. No perivascular inflammatory cell infiltrates were present. Fibrinoid necrosis of small numbers of intracerebral capillaries was present. The leptomeningeal vessels were normal. Renal glomeruli also showed focal fibrinoid necrosis.

### Discussion

The clinical characteristics of the original group of 25 patients with mixed connective tissue disease included a combination of features similar to those of systemic lupus erythematosus, progressive systemic sclerosis, and polymyositis.<sup>11</sup> Although major neurologic manifestations were not initially reported in these patients, subsequent follow-up of this cohort found three of the 14 patients to have central nervous system disease.<sup>12</sup>

Presently, the frequency of central nervous system disease in patients with mixed connective tissue disease ranges from 10% to 55%, depending on whether frequent headaches and neuropsychiatric symptoms are included as neurologic manifestations.<sup>13,14</sup> Trigeminal neuropathy is the predominant neurologic finding reported. It is described both as

an isolated sensory neuropathy and as a presenting symptom with subsequent evolution of aseptic meningitis and seizures.<sup>1,15</sup> Bennett describes an aseptic meningitislike illness as the most common neuropsychiatric disturbance in his series of 20 patients with mixed connective tissue disease.<sup>13</sup> Delayed onset of meningeal signs following fever, conjunctivitis, malaise, and cerebrospinal fluid pleocytosis has been reported in at least three patients with mixed connective tissue disease who also received ibuprofen or sulindac.<sup>16-18</sup> Singesen et al in their report of 10 children with mixed connective tissue disease, cite one child with headaches and elevated cerebrospinal fluid protein and two other children with seizures and encephalopathy.<sup>14</sup> Migraine-type, vascular headache and febrile headache also occur.<sup>1,19,20</sup> Transverse myelitis is a rare finding in mixed connective tissue disease, reported in two patients; prednisone and azathioprine were given in both cases, and one completely recovered.<sup>21,22</sup> Single case studies also include choreoathetosis, cerebellar ataxia, and ruptured intracranial aneurysms in patients with mixed connective tissue disease.<sup>1,23,24</sup>

Rheumatologic syndromes associated with central nervous system disease due to vasculitis or other mechanisms are seen most often in systemic lupus erythematosus.<sup>9</sup> In patients with systemic lupus erythematosus, both hemorrhagic and occlusive cerebrovascular disease have been reported as the presenting symptom.<sup>9</sup> In a review of cerebrovascular disease in systemic lupus erythematosus, Tsokos et al<sup>4</sup> found primary occlusive disease to be the most common form, often developing in the setting of prolonged quiescent disease. Other mechanisms of neurologic dysfunction include tissue ischemia, half of which consists of multiple small cortical infarcts, usually observed in the cortex, and endothelial proliferation, hyalinization, and autoantibodies.<sup>4,25</sup> Lupus anticoagulants are acquired immunoglobulin G or M, which inhibit coagulation by interfering with the phospholipid portion of the prothrombin activator complex and have been associated with both systemic lupus erythematosus and stroke-like syndromes in young adults.<sup>26-28</sup> Although found in association with other collagen vascular diseases, lupus anticoagulants have not been reported in mixed connective tissue disease. No single etiologic mechanism of pathogenesis in central nervous system connective tissue disease is evident; both the presence of serum antibodies directed against brain tissue and an alteration in the normal blood-brain barrier may be necessary to cause either vascular or parenchymal changes.<sup>8</sup> Although other clinical central nervous

system manifestations of systemic lupus erythematosus are diverse, more recent reports suggest that the majority of observed neurologic events are explainable by common metabolic, pharmacologic, and vascular abnormalities.<sup>6</sup>

Patient 1 had complete left internal carotid artery occlusion as the presenting complication of mixed connective tissue disease. This demonstrates that children or young adults may be at risk for developing symptoms associated with cerebral ischemia or vasculitis. This is in contrast to reports that suggest that cerebral vessels are unaffected in mixed connective tissue disease. The intracerebral hemorrhage was severe enough to cause the death of patient 2. The pathogenesis of this hemorrhage was probably due to cerebral capillary injury, as evidenced by fibrinoid necrosis, and thrombocytopenia. Systemic vasculitis in mixed connective tissue disease often involves large vessels, spares capillaries, and rarely shows such fibrinoid changes.

In conclusion, mixed connective tissue disease frequently presents with unusual combinations of signs and symptoms that evolve and change over time and may include the central nervous system, including cerebrovascular disease. The diagnosis of mixed connective tissue disease should be considered in children and young adults with cerebral vasculopathy of unclear etiology.

### References

- Bennet RM: Mixed connective tissue disease: A distinct syndrome? *J Musculoskel Med* 1987;4:69-79.
- Oetgen WJ, Boice JA, Lawless OJ: Mixed connective tissue disease in children and adolescents. *Pediatrics* 1981;67:333-337.
- Fraga A, Gudiño J, Ramos-Niembro F, Alarcón Segovia D: Mixed connective tissue disease in childhood; relationship with Sjogren's syndrome. *Am J Dis Child* 1978;132:263-265.
- Tsokos GC, Tsokos M, le Riche NGH, Klippel JH: A clinical and pathologic study of cerebrovascular disease in patients with systemic lupus erythematosus. *Semin Arthritis Rheum* 1986;16:70-78.
- Hart RG, Miller VT, Coull BM, Brill V: Cerebral infarction associated with lupus anticoagulants—preliminary report. *Stroke* 1984;15:114-118.
- Kaell AT, Shetty M, Lee BCP, Lockshin MD: The diversity of neurologic events in systemic lupus erythematosus. *Arch Neurol* 1986;43:273-276.
- Sigal LH: The neurologic presentation of vasculitic and rheumatologic syndromes. *Medicine (Baltimore)* 1987;66:157-180.
- Zvaifler NJ, Bluestein HG: The pathogenesis of central nervous system manifestations of systemic lupus erythematosus. *Arthritis Rheum* 1982;25:862-866.
- Silverstein A: Cerebrovascular accidents as the initial major manifestation of lupus erythematosus. *N Y State J Med* 1963;63:2942-2948.
- Schoenberg BS, Mellinger JF, Schoenberg DG: Cerebrovascular disease in infants and children: A study of incidence, clinical features, and survival. *Neurology* 1978;28:763-768.
- Sharp GC, Irvin WS, Tan EM, Gould RG, Holman HR: Mixed connective tissue disease—an apparently distinct rheumatic disease syndrome associated with a specific antibody to an extractable nuclear antigen (ENA). *Am J Med* 1972;52:148-158.
- Nimelstein SH, Brody S, McShane D, Holman HR: Mixed connective tissue disease: A subsequent evaluation of the original 25 patients. *Medicine (Baltimore)* 1980;59:239-248.
- Bennet RM, Spargo BH: Neuropsychiatric problems in mixed connective tissue disease. *Am J Med* 1978;65:955-962.
- Singsen BH, Kornreich HK, Koster-King K, et al: Mixed connective tissue disease in children. *Arthritis Rheum* 1977;20:355-360.
- Searles RP, Mladinich EK, Messner RP: Isolated trigeminal sensory neuropathy: Early manifestation of mixed connective tissue disease. *Neurology* 1978;28:1286-1289.
- Hoffman M, Gray RG: Ibuprofen-induced meningitis in mixed connective tissue disease. *Clin Rheumatol* 1982;2:128-130.
- Bernstein RF: Ibuprofen-related meningitis in mixed connective tissue disease. *Ann Intern Med* 1980;92:206-207.
- Lorino GD, Hardin JG: Sulindac-induced meningitis in mixed connective tissue disease. *South Med J* 1983;76:1185-1186.
- Johansson EA, Niemi KM, Lassus A, Gripeberg M: Mixed connective tissue disease: A follow-up study of 12 patients with special reference to cold sensitivity and skin manifestations. *Acta Derm Venereol (Stockh)* 1981;61:225-231.
- Bronshag MM, Prystowsky SD, Traviesa DC: Vascular headache in mixed connective tissue disease. *Headache* 1978;18:154.
- Weiss TD, Nelson JS, Woolsey RM, Zuckner J, Baldassare AR: Transverse myelitis in mixed connective tissue disease. *Arthritis Rheum* 1987;21:982-986.
- Pedersen C, Bonen H, Boesen F: Transverse myelitis in mixed connective tissue disease. *Clin Rheumatol* 1987;2:290-292.
- McKenna F, Eccles J, Neumann VC: Neuropsychiatric disorders in mixed connective tissue disease. *Br J Rheumatol* 1986;25:225-226 (letter).
- Masuzawa T, Nakahara N, Kobayashi S: Intracranial multiple berry aneurysms associated with fibromuscular dysplasia and mixed connective tissue disease. *Neurol Med Chir (Tokyo)* 1987;27:42-50.
- Moore PM, Cupps TR: Neurologic complications of vasculitis. *Ann Neurol* 1983;14:155-167.
- Halla JT, Volanakis JE, Schrohenloher RE: Circulating immune complexes in mixed connective tissue disease. *Arthritis Rheum* 1979;22:484-489.
- Levine SR, Welch KMA: The spectrum of neurologic disease associated with antiphospholipid antibodies, lupus anticoagulants and anticardiolipin antibodies. *Arch Neurol* 1987;44:876-883.
- Dungan DD, Jay MS: Stroke in an early adolescent with systemic lupus erythematosus and coexistent antiphospholipid antibodies. *Pediatrics* 1992;90:96-99.