

diabetes mellitus (4–8), but this association has only occasionally been reported. We report and illustrate a patient with nonketotic hyperglycemia and generalized chorea.

Case History

An 81-year-old woman developed generalized, abnormal, involuntary movements. She had been taking amiloride (100 mg daily) because of hypertension. She had never received neuroleptic drugs. One week before admission she noted intense thirst, polyuria, and involuntary movements of all four limbs and face. The clinical picture worsened gradually. Physical examination revealed an alert woman with mild signs of dehydration and generalized choreic movements. The rest of the examination showed normal results. The serum glucose level was 630 mg/dl. Glucosuria was found and ketones were absent. The rest of the routine biochemical blood test including acanthocytes, thyroid function, calcium and phosphorus, pH and bicarbonate, muscle and liver enzymes, and antinuclear antibodies were all normal. A computed tomography (CT) scan was also normal but magnetic resonance imaging showed small infarcts in subcortical white matter, which was considered "normal for an elderly person." She was treated with intravenous fluids, insulin, and tetrabenazine (100 mg daily) because she was exhausted. In a few days, serum glucose was normalized and the dyskinesias disappeared. We tried to withdraw tetrabenazine, but the chorea reappeared and the patient was discharged with a regimen of tetrabenazine 100 mg daily. One month later, the blood sugar level remained normal and she was free of chorea. We tried to slowly reduce the dosage of tetrabenazine again, and the chorea reappeared. Three months later, the blood glucose level continued to be normal. The tetrabenazine then was slowly reduced and stopped. Five months after admission, she was free of dyskinesias with a normal serum glucose level.

Discussion

Nonketotic hyperglycemia has been associated with paroxysmal choreoathetosis (4–6), hemichorea (7), hemiballismus (8), and tonic spasms (9). The case we have reported has generalized chorea associated with nonketotic hyperglycemia. However, there was no immediate improvement of the dyskinesia after the control of blood sugar. There are many other possible causes of chorea (1–3). Most of them were excluded in our patient with the exception of senile chorea and chorea of vascular origin. It is well known that in the elderly population chorea appears increasingly even in those never exposed to neuroleptic agents (1). However, chorea in aging is largely limited to the facial area, sparing the trunk and extremities, and is more likely a pathologic manifestation of an as yet undefined vulnerability in this elderly population. Generalized chorea due to small lacunar infarctions in the basal ganglia has only rarely been described (8–13), and it has been suggested that the particular vascular requirement for producing generalized chorea is ischemia rather than infarction (12).

We suggest that in our patient these two factors (old age and vascular lesions) have played a predisposing and a "chorea perpetuating" role. In fact, in the case reported by Sethi et al. (7), chorea also resolved slowly and the CT scan showed bilateral hemorrhagic infarctions in caudates and putamina.

Legends to Videotape

- Segment 1. Generalized chorea. Admission day.
Segment 2. Five months later, without chorea.

G. Linazasoro
M. Urtasun
J. J. Poza
J. A. Suárez
J. F. Martí Massó
*Servicio de Neurología
Hospital de Arantzazu
San Sebastián, Spain*

References

1. Shoulson I. On chorea. *Clin Neuropharmacol* 1986;9 (suppl 2):S85–S99.
2. Padberg G, Bruyn GW. Chorea: differential diagnosis. In: Vinken PS, Bruyn GW, Klawans HL, eds. *Handbook of clinical neurology*, vol 49. Amsterdam: Elsevier, 1986:549–564.
3. Fahn S. The other choreas. Aspen, Colorado, 1991:281–306.
4. Rector WG, Herlong HF, Moses H. Nonketotic hyperglycemia appearing as choreoathetosis or ballism. *Arch Intern Med* 1982;142:154–155.
5. Totoritis M, Cornish D, Thompson F. Nonketotic hyperglycemia. *Arch Intern Med* 1982;142:1405.
6. Haan J, Kremer HPH, Padberg G. Paroxysmal choreoathetosis as presenting symptom of diabetes mellitus. *J Neurol Neurosurg Psychiatry* 1989;52:133.
7. Sethi KD, Allen M, Sethi RK, McCord JW. Chorea in hypoglycemia and hyperglycemia [Abstract]. *Neurology* 1990;40 (suppl 1):337.
8. Stone LA, Armstrong RM. An unusual presentation of diabetes: hyperglycemia inducing hemiballismus [Abstract]. *Ann Neurol* 1989;26:164.
9. Maccario M, Brooklyn MD. Neurological dysfunction associated with nonketotic hyperglycemia. *Arch Neurol* 1968;19:525–534.
10. Folstein S, Abbot M, Moses R, Parlad I, Clark A, Folstein M. A phenocopy of Huntington's disease: lacunar infarcts of the corpus striatum. *Johns Hopkins Med J* 1981;148:104–113.
11. Tababton M, Mancondi G, Loeb C. Generalized chorea due to bilateral small deep cerebral infarcts. *Neurology* 1985;35:588–589.
12. Sethi KD, Nichols FT, Yaghmai F. Generalized chorea due to basal ganglia lacunar infarcts. *Mov Disord* 1987;2:61–66.
13. Margolin DI, Marsden CD. Episodic dyskinesias and transient cerebral ischemia. *Neurology* 1982;32:1379–1380.

Bifrontal Glioma Presenting as a Gross Movement Disorder



To the Editor:

We report the case of an 89-year-old woman who presented with gross abnormal movements, identical with

those seen in tardive dyskinesia, which were secondary to a large bifrontal glioma. Videotapes displaying her clinical findings pre- and post-treatment are included in two segments. We are unaware of any previous reports in which an intracranial tumour has caused such gross movement abnormalities.

This 89-year-old woman was admitted to St. Charles Hospital in April 1991. Three weeks prior to admission she had developed, over a few days, involuntary orofacial movements that had progressed rapidly to include bilateral involuntary arm and leg movements, which caused her to fall on a number of occasions. She had difficulty in swallowing, was sometimes incontinent of urine, and was unable to speak. Prior to this, she had been a healthy, independent woman with no medical complaints.

Her past medical history was unremarkable. She was taking Navidrex K 1 in the morning for mild heart failure. Apart from an occasional paracetamol, she had never taken any other medication; in particular, she had never taken neuroleptics.

On examination, she showed a wide range of involuntary movements including blepharospasm, orofacial dyskinesia, choreiform movements of both arms, hemiballism of the left arm, dystonic posturing of the left arm, body dystonia, and stereotypy of the legs, more so on the left (Segment 1 of video). She had a mild pyramidal weakness of the right side and an upgoing left plantar response. There were no cranial nerve abnormalities and her fundi could not be visualised because of cataracts. Physical examination was otherwise normal.

Investigations, including a complete blood count, ESR, biochemical screen, liver function, thyroid function, serum copper, glucose, and a chest X-ray, were all unremarkable.

The involuntary movements decreased somewhat on tetrabenazine 25 mg twice a day. After 1 week, sulpiride 100 mg twice a day was added. Within 3 days, she showed considerable improvement, although she continued to have some orofacial dyskinesia, left arm choreiform movements, and stereotypy of the left leg (Segment 2 of video). Despite this, she was now walking more easily and her swallowing was less troublesome.

An MR scan showed a large bifrontal glioma involving the corpus callosum and basal ganglia (Fig. 1). Tetraben-

zine and sulpiride were discontinued and dexamethasone commenced, starting at 4 mg t.d.s., reducing gradually to 4 mg mane after 2 weeks. The result was very interesting in that the steroids alone now maintained her improvement with regard to dystonia and hyperkinesia and also led to an improvement in her speech output.

One month after admission, she was discharged home. She was well at this time, showing fewer abnormal movements and making steady progress. Unfortunately, she developed a chest infection and passed away peacefully 3 weeks later. Permission for a postmortem examination was refused. One week prior to death, her dexamethasone had been stopped by her daughter because of her deteriorating health. According to her, the patient's abnormal movements returned to the same extent as on her admission.

Focal brain lesions occasionally produce typical focal or hemidystonia (1-3). Marsden's comprehensive paper on hemidystonia (4) showed that responsible lesions may include tumours, arteriovenous malformations, infarcts (post-traumatic, thrombotic, or embolic), or haemorrhages. The lesions involved a variety of cerebral regions including the thalamus, caudate nucleus, lentiform nucleus, internal capsule and cortex. Focal or hemidystonia was the only neurological abnormality in most of his patients.

Our patient had a bilateral movement disorder comprising orofacial dyskinesia, chorea, and dystonia, strongly reminiscent of tardive dyskinesia. However, there was no history of neuroleptic use at any time in the past. There are few reports of tumours causing such an unusual complication. Pall reported a case of bilateral Parkinsonism with long tract signs that were thought to be due to a large left hemisphere intrinsic tumour with contralateral hydrocephalus (5). There are other short reports similar to this but more typically describing hemidystonia or hemiparkinsonism (6,7). It is reasonable to assume that the gross abnormal movements in our patient were due to the mechanical pressure caused by the tumour and its related oedema, which certainly involved basal ganglia structures and connections. This is suggested by the response she had to dexamethasone and the subsequent return of her abnormal movements when it was stopped by her family during the final days of her illness.

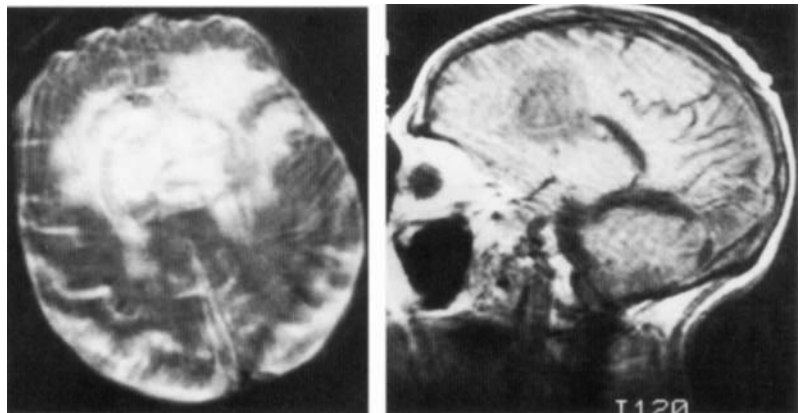


FIG. 1. There is a large bifrontal glioma centered on the anterior part of the corpus callosum, including trunk and genu, and extending widely into both cerebral hemispheres. There is also a posterior cerebral artery territory infarct.

Acknowledgments: We wish to thank Miss Jan Kleina for typing the manuscript and Dr. Rob Hicks for his help in editing the videotapes.

Legends to Videotape

Segment 1. Patient at presentation showing Orofacial dyskinesia; blepharospasm; choreoathetoid movements of the arms and legs L > R; stereotypy of the left leg; dystonic body posturing; and hemiballism of the left arm.

Segment 2. Ten days after treatment showing a dramatic improvement. She still has some orofacial movements, left arm chorea, and left leg stereotypy.

S. Roche
S. Godward
A. Middleton
*Department of Medicine
for the Elderly
St. Charles Hospital
London, England*
R. J. M. Lane
*Regional Neurosciences Centre
Charing Cross Hospital
London, England*

References

1. Brett EM, Hoare RD, Sheehy MP, Marsden CD. Progressive hemidystonia due to focal basal ganglia lesion after mild head trauma. *J Neurol Neurosurg Psychiatry* 1981;44:460.
2. Norbona J, Obeso JA, Tunon T, Martinez-Lage JM, Marsden CD. Hemidystonia secondary to localised basal ganglia tumour. *J Neurol Neurosurg Psychiatry* 1984;47:704-709.
3. Obeso JA, Martinez-Vila E, Dalgado G, Vaamonde J, Maravi E, Martinez-Lage JM. Delayed onset of dystonia following hemiplegic migraine. *Headache* 1984;24:266-268.
4. Marsden CD, Obeso JA, Zarranz JJ, Lang AE. The anatomical basis of symptomatic hemidystonia. *Brain* 1985;108:463-483.
5. Pall HS. 74 year old lady who developed bilateral Parkinsonism secondary to an intrinsic cerebral tumour. *J Neurol Neurosurg Psychiatry* 1987;50:1386-1387.
6. Navarro JA, Ezquerro JJR, Alburquerque TL, Gutierrez JC. Parkinsonism due to corpus callosum astrocytoma. *J Neurol Neurosurg Psychiatry* 1986;49:1457-1458.
7. Kulali A, Tugtedin M, Utkur Y, Erkurt S. Ipsilateral hemiparkinsonism secondary to an astrocytoma. *J Neurol Neurosurg Psychiatry* 1991;54:655.

Alcohol Sensitive Dystonia



To the Editor:

Alcohol intake improves a large proportion of patients with essential tremor (1), hereditary essential myoclonus (2,3), and inherited myoclonic dystonia (4). Patients with idiopathic torsion dystonia (ITD) do not show such striking sensitivity to alcohol, although alcohol-induced relaxation may provide some benefit (1). We recently described a patient with myoclonus and abnormal gait of sporadic presentation (5) who showed dramatic improvement with alcohol, suggesting that the spectrum of alco-

hol-sensitive movement disorders may be wider than previously recognized. We now report a patient with a pure dystonic syndrome sensitive to alcohol.

The patient was a 40-year-old man from Mallorca (Balearic Islands), with a 20 year history of gait disturbance. There was no family history of neurological disease or consanguinity. Symptoms began in 1970 when he started noticing that his right foot rotated externally while walking. Subsequently, the right arm adopted awkward postures when writing. By 1980, when he was 28, writing was not possible at all. Around 1986-87, the left leg also began to deviate on walking and rhythmic flexion-extension movements of the foot were present. These movements interfered with stance and gait. Treatment with trihexyphenidyl (12 mg/day) and with carbamazepine (600 mg/day) provided no relief.

We first saw the patient in 1990 at the age of 38. At that time he had great difficulty in walking and in keeping still. Dystonic postures were observed in all four limbs on action, and occasionally in the neck muscles, which showed a tendency to laterocollis. Rhythmic slow movements of the left foot were present at rest while lying in bed and were aggravated by action. These movements were the main source of problems in walking. A similar slow rhythmic flexion-extension movement of the right hand was also noticed. A dramatic improvement of these myorhythmic movements and the dystonic postures was consistently observed after drinking ~60 g of alcohol. Spontaneous myoclonus was not observed during action or in response to any form of sensory stimulation. The rest of the physical examination was normal. Both CT and MRI scans of the brain showed atrophy with predominance in the brainstem and cerebellum. All diagnostic blood tests were normal.

Surface EMG recording of tibialis anterior and gastrocnemius muscle in the left leg revealed rhythmic activity at a frequency of 2-3 Hz. Each burst had a duration of 100-150 ms and there was alternating activation of both muscles. This type of recording is characteristic of myorhythmia (1,7).

This patient showed a combination of generalized dystonia and myorhythmic movements, but no actual myoclonic activity was detected. Alcohol-induced improvement of this combination movement disorder was evident. Family history was negative. Slow, undulatory and repetitive movements of one body part have been well recognized in patients with ITD. Indeed, it was Hertz (7) who in his classic description of hereditary torsion dystonia referred to these movements as myorhythmia. Thus, all the clinical findings of our patient fell within the spectrum of motor manifestations of ITD (1,8). This is the first patient in whom alcohol produced a marked improvement of a purely dystonic syndrome. Recently, two families with progressive myoclonic epilepsy who responded dramatically to alcohol have been described (9,10). The effect of alcohol may therefore not be limited to patients with essential tremor and myoclonic dystonia.

Legend to Videotape

Segment 1 shows dystonic movements and postures in the four limbs and repetitive myorhythmic movements in