

## Conventional radiation therapy of intracranial arteriovenous malformations: long-term results

GARY J. REDEKOP, M.D., KOST V. ELISEVICH, M.D., PH.D., F.R.C.S.(C),  
LAURIE E. GASPARD, M.D., F.R.C.P.(C), KAREN P. WIESE, R.T.T., AND  
CHARLES G. DRAKE, M.D., F.R.C.S.(C)

*Department of Clinical Neurological Sciences, Division of Neurosurgery, and Department of Radiation Oncology, London Regional Cancer Centre, University of Western Ontario, London, Ontario, Canada*

✓ Conventional radiation therapy has been used in the treatment of arteriovenous malformations (AVM's) for many years, but there are limited data pertaining to specific treatment parameters, long-term results, and complications. Between 1955 and 1985, 15 patients with AVM's deemed inoperable or incompletely obliterated using surgical or endovascular techniques were treated at the University of Western Ontario. There were nine males and six females, aged 15 to 48 years (mean 29 years). Presenting symptoms included hemorrhage in nine patients, seizures in four, and focal neurological deficits in two. There were three infratentorial and 12 supratentorial AVM's, ranging in size from 1.5 to 6.5 cm. Therapy prior to irradiation consisted of incomplete surgical removal in four cases and subtotal embolization in four. One patient received 2000 cGy of irradiation, while 4000 to 5000 cGy were delivered in the remaining patients to fields ranging in size from  $4 \times 4$  to  $14 \times 14$  cm in 15 to 28 fractions. The 15 patients have been followed for  $1\frac{1}{2}$  to 21 years since undergoing radiotherapy (mean 8.1 years). Angiography in 12 patients at 1 to 21 years following irradiation demonstrated no significant change in seven patients, a slight reduction in AVM size in two, near-complete obliteration in one, and complete obliteration in two. One patient with an AVM measuring 6.5 cm refused angiography but underwent magnetic resonance imaging at 5 years which showed no evidence of residual AVM. There were four hemorrhages in 122 patient-years of follow-up study, indicating a hemorrhage rate of 3.3% per year. The authors conclude that conventional irradiation is successful in obliterating AVM's in only about 20% of cases.

**KEY WORDS** • arteriovenous malformation • radiation therapy • stereotaxy • radiosurgery

**I**NTRACRANIAL arteriovenous malformations (AVM's) constitute a formidable therapeutic challenge, and their appropriate management remains controversial. The impetus for the development of radiotherapeutic strategies to obliterate these lesions came initially as a result of inadequate surgical techniques in the early part of this century,<sup>7,12,29,42</sup> and has been maintained by an ever-increasing awareness of the natural history, including a significant risk of death or disability in the long term.<sup>4,14,17,36,55</sup> It is estimated that a patient who is found to have an unruptured cerebral AVM has a 2% to 3% risk of suffering a hemorrhage in the 1st year and as high as a 30% risk of hemorrhage over 10 years. After the initial bleeding episode, the likelihood of sustaining a significant neurological deficit is approximately 50%, and as many as 10% of the patients suffering a hemorrhage will die.<sup>55</sup> Recent information<sup>36</sup> suggests that the mode of presentation, whether hemorrhage, seizure, or incidental finding, does not influence the risk of future bleeding. The long-term rate of hemorrhage may be as high as 4% per year,

with a combined morbidity and mortality rate of nearly 3% annually.

While surgical treatment remains the procedure of choice for many, if not most, AVM's, radiation therapy and endovascular techniques have assumed a more prominent role in recent years.<sup>8</sup> Radiotherapy in the treatment of AVM's has been the subject of several recent reviews<sup>16,33,44</sup> and there have been a series of reports documenting the results of focused irradiation using the gamma knife,<sup>27,48,49</sup> linear accelerator,<sup>2,5,26,45</sup> proton beam,<sup>23,47</sup> and helium ion beam.<sup>20</sup>

Conventional radiation therapy has been used in the treatment of AVM's for many years,<sup>3,7,13,18,21,29,34,38,40-42,51,52</sup> but there are limited data pertaining to specific treatment parameters, long-term results, and complications. In many publications, the details of prior therapy, dosimetry, field size, and delivery have been incomplete. Irradiation doses were frequently low and given over a prolonged period. Follow-up evaluation was unsystematic and did not routinely include angiography. Since all forms of stereotactic radiosurgery

have been designed to improve on the results achieved with conventional techniques, a long-term systematic evaluation of a series of patients treated with conventional radiotherapy is necessary for comparison.

### Clinical Material and Methods

#### Patient Population

Between 1955 and 1985, prior to the development and implementation of a stereotactic radiosurgery facility at the University of Western Ontario, 15 patients with intracranial AVM's were treated with conventional radiotherapy. In all cases, the AVM was deemed inoperable or was only partially obliterated using surgical or endovascular techniques. There were nine males and six females, aged 15 to 48 years (mean 29 years). Presenting symptoms included hemorrhage in nine patients, seizures in four, and focal neurological deficits in two. There were three infratentorial and 12 supratentorial AVM's, ranging from 1.5 to 6.5 cm in greatest dimension at the time of irradiation. The lesion volume, calculated according to the method of Pasqualin, *et al.*,<sup>37</sup> ranged from 1 to 85 cu cm; five AVM's were less than 5 cu cm, three were 5 to 25 cu cm, three were 25 to 50 cu cm, and four were greater than 50 cu cm. Prior to irradiation, therapy included partial surgical removal in three cases, subtotal embolization in three, and both incomplete embolization and surgical removal in one case. Eight patients had no direct treatment for their AVM before radiotherapy, although one required insertion of a ventriculoperitoneal shunt. Clinical details of all cases are presented in Table 1.

#### Radiation Treatment

Radiation therapy was performed using either a 1.25-MeV <sup>60</sup>Co teletherapy unit or a 6-MV linear accelerator. The total treatment dose was 2000 cGy in the first patient and 4000 to 5000 cGy in all subsequent cases.

Irradiation was delivered via homolateral wedge fields, parallel opposed fields, or 360° rotation treatments. Field sizes ranged from 4 × 4 to 14 × 14 cm. Specific details of the radiation therapy parameters for each case are given in Table 2.

#### Clinical Follow-Up Study

The 15 patients have been followed for 1½ to 21 years since undergoing radiotherapy (mean 8.1 years). Follow-up data were obtained from review of hospital and clinic records and from telephone contact with the patients' primary-care physicians. Radiological investigations following treatment included angiography, computerized tomography (CT), and magnetic resonance (MR) imaging. In most cases these investigations were carried out at the University of Western Ontario; in cases where long distances were involved, however, the studies were performed at the patient's local hospital and subsequently made available for review.

### Results

#### Radiological Follow-Up Study

Follow-up cerebral angiography was performed in 12 patients at 1 to 21 years after irradiation and demonstrated no significant change in seven patients, modest reduction in AVM size in two, near-complete obliteration in one, and complete obliteration in two (Table 3). One patient (Case 11) with an AVM measuring 6.5 cm refused angiography but underwent MR imaging at 5 years after irradiation, which demonstrated no evidence of residual AVM. In one patient (Case 13) CT demonstrated no significant change in the appearance of the AVM at 3 and 5 years after irradiation and therefore angiography was not performed. One patient (Case 12) refused any imaging investigation but remained well 3 years after radiotherapy.

TABLE 1  
Summary of clinical data in 15 patients with intracranial AVM's treated with conventional irradiation\*

Case No.	Age (yrs), Sex	Presenting Symptom	AVM Location	Therapy Prior to Irradiation	Preradiation AVM Size (cm)	AVM Volume† (cu cm)
1	29, M	hemorrhage	lt thalamus	none	5.0 × 5.0 × 5.0	63
2	24, M	hemorrhage	lt rolandic	partial embolization, partial surgical removal	5.0 × 4.0 × 4.0	40
3	36, M	seizure	lt frontal	partial embolization	4.5 × 3.2 × 3.0	22
4	32, F	ataxia	midbrain	ventriculoperitoneal shunt	4.5 × 3.5 × 3.0	24
5	24, F	hemorrhage	lt cerebellum	partial surgical removal	2.0 × 2.0 × 2.0	4
6	20, F	seizure	lt rolandic	partial embolization	6.5 × 5.2 × 5.0	85
7	40, F	hemorrhage	rt basal ganglia	none	1.5 × 1.5 × 1.0	1.1
8	25, F	hemorrhage	rt temporo-occipital	partial embolization	5.5 × 4.5 × 4.5	56
9	48, M	vertigo, tremor	lt cerebellopontine angle, brain stem	partial surgical removal	1.5 × 1.5 × 1.0	1.1
10	15, M	hemorrhage	rt thalamus	partial surgical removal	1.5 × 1.5 × 1.5	1.7
11	44, F	seizure	rt rolandic	none	6.5 × 4.0 × 4.0	52
12	16, M	seizure	lt sylvian	none	1.4 × 1.2 × 1.0	0.8
13	47, M	hemorrhage	lt thalamus	none	6.0 × 5.0 × 2.0	30
14	22, M	hemorrhage	lt temporal	none	3.5 × 3.1 × 2.5	14
15	15, M	hemorrhage	rt occipital	none	4.0 × 4.0 × 3.5	28

\* AVM = arteriovenous malformation.

† Volume calculated according to the method of Pasqualin, *et al.*,<sup>37</sup> as length × width × height × 0.5.

## Conventional radiation therapy of AVM's

TABLE 2  
*Details of conventional radiation therapy used in the treatment of AVM's\**

Case No.	Irradiation Dose (cGy)	No. of Fractions	Field Size (cm)	Treatment Technique	Therapy After Irradiation
1	2000	10	6 × 6	360° rotation	none
2	4000	15	9 × 5	360° rotation	none
3	4000	15	7 × 7	wedge pair	none
4	5000	25	14 × 14†	wedge pair	none
5	4500	15	5 × 4	360° rotation	surgical removal 5 yrs after RT
6	5000	28	10 × 10	parallel opposed	none
7	4500	15	5 × 5	360° rotation	none
8	4000	15	8 × 7	wedge pair	none
9	5000	25	8 × 6	parallel opposed	none
10	4500	25	4 × 4	four wedged fields	none
11	4500	15	5 × 5	wedge pair	none
12	5000	25	6 × 6	wedge pair	none
13	5000	25	7 × 7	parallel opposed	none
14	4500	15	5 × 5	wedge pair	surgical removal 5 yrs after RT
15	4500	15	6 × 4	wedge pair	none

\* AVM = arteriovenous malformation; RT = radiation therapy.

† Fifteen fractions (3000 cGy) were delivered to a field measuring 14 × 14 cm and, subsequently, 10 fractions (2000 cGy) were delivered to a field measuring 9.5 × 10 cm.

### Recurrent Hemorrhage

There were no hemorrhages during the first 2 years after radiotherapy, during which time radiation-induced vascular changes are thought to occur.<sup>33</sup> Two patients each suffered two recurrent hemorrhages at 5 to 21 years after irradiation (Table 3). The first patient

(Case 1) survived for 19 years after radiation treatment before rebleeding, with a resultant minor deficit. He recovered but suffered a fatal hemorrhage 2 years later. The second patient (Case 5) had two recurrent hemorrhages, 2 months apart at 5 years after irradiation. Both hemorrhages were minor and did not add to the pre-

TABLE 3  
*Results of conventional radiation in the treatment of intracranial AVM's\**

Case No.	Follow-Up Investigation†	Result of RT	Complications	Follow-Up Study Period (yrs)	Condition at Last Review
1	angiography (19)	no change	rebled twice at 19 & 21 yrs	21	dead
	angiography (21)	no change			
2	angiography (1)	slight reduction	none	9	good
	angiography (4)	slight reduction			
3	angiography (2)	no change	none	11.5	good
	angiography (4)	no change			
	angiography (6)	no change			
4	angiography (1)	complete obliteration	none	1.5	good
5	angiography (5)	no change	rebled twice during 5th year	5	stable deficits
6	angiography (2)	no change	none	10	good
	angiography (3)	no change			
	MR imaging (10)	no change			
7	angiography (1)	significant reduction	none	10.5	good
	angiography (3)	complete obliteration			
8	angiography (2)	no change	none	10.5	good
	CT (10)	no change			
9	angiography (2)	partial reduction	hearing loss	9.5	good
	CT (4)	residual AVM			
10	angiography (1.5)	95% reduction	none	7.5	good
11	MR imaging (5)	probable obliteration	none	8	good
12	none	unknown	none	3	good
13	CT (3)	no change	none	6	good
	CT (5)	no change			
14	angiography (5)	no change	none	5	good
15	angiography (1)	partial reduction	none	4	good
	angiography (2)	no further change			
	angiography (4)	increased size			

\* AVM = arteriovenous malformation; RT = radiation therapy.

† Numbers in parentheses denote time (years) since RT. MR = magnetic resonance; CT = computerized tomography.

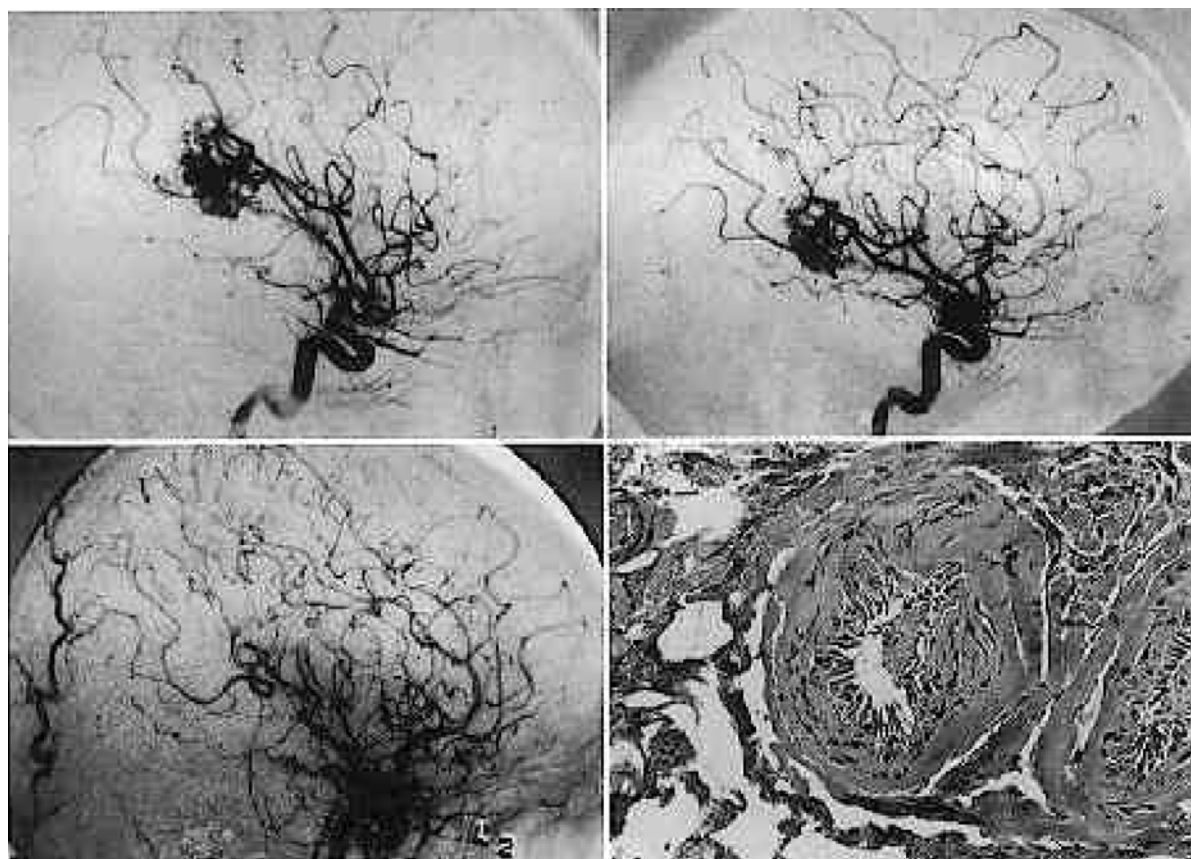


FIG. 1. Case 14. Angiograms of a left temporal arteriovenous malformation (AVM) before (*upper left*) and 5 years after (*upper right*) 4500 cGy radiotherapy, demonstrating no significant change in AVM size. Postoperative angiogram (*lower left*) reveals complete excision. A photomicrograph of the surgical specimen (*lower right*) shows patent vessels with some intimal thickening and coagulation artifact, but no evidence of thrombosis, fibrosis, or necrosis attributable to irradiation. H & E.  $\times 100$ .

existing neurological deficits. Thus, there were four hemorrhages in 122 patient-years of follow-up monitoring, indicating a hemorrhage rate of 3.3% per year.

#### *Pathological Examination*

Three irradiated AVM's were available for pathological examination. An autopsy was performed in Case 1 following a fatal recurrent hemorrhage 21 years after irradiation. Two patients (Cases 5 and 14) underwent surgical removal of the AVM 5 years after irradiation, when angiography showed no significant change in the size of the lesion. In each case, microscopic examination failed to demonstrate significant thrombosis, fibrosis, or necrosis that could be attributed to the previous radiation therapy (Fig. 1). Modest hyalinization of the pathological vessels was common, as is typical of many vascular malformations.<sup>30</sup>

#### *Complications of Radiation Therapy*

There were no significant complications as a result of radiation therapy (Table 3). One patient (Case 9) with a cerebellopontine angle AVM experienced permanent decreased hearing ipsilaterally, attributed to

inner-ear injury. There was no effect on ipsilateral facial nerve function.

#### **Illustrative Cases**

##### *Case 1: Fatal Recurrent Hemorrhage*

This 29-year-old man was admitted to our hospital in 1955 after suffering an intracerebral hemorrhage from a large, deep, left hemisphere AVM. He had previously had a coma-producing hemorrhage in 1951 at the age of 25 years, and was left with a mild expressive dysphasia and right hemiparesis. Radiation therapy was administered, consisting of 2000 cGy over 10 fractions to a field measuring  $6 \times 6$  cm, and he improved gradually from his neurological deficits. However, in 1974, at the age of 48 years, he again suffered an intracerebral hemorrhage and developed severe aphasia and right hemiparesis. Angiography was repeated and showed no significant change from the initial angiogram. He was treated with bed rest and experienced considerable improvement. Two years later, at the age of 50 years, he had another hemorrhage and developed complete aphasia and right hemiplegia. Cerebral angiography demonstrated no change in the appearance of

## Conventional radiation therapy of AVM's

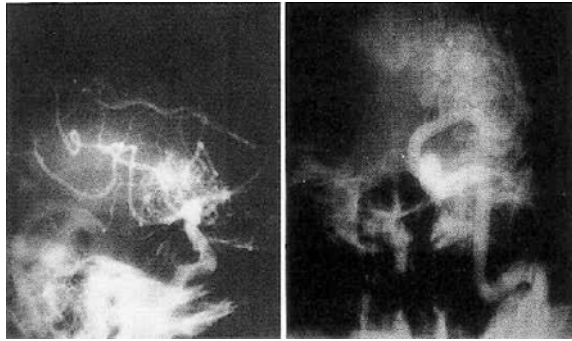


FIG. 2. Case 1. Lateral (*left*) and anteroposterior (*right*) angiograms obtained 21 years after treatment with 2000 cGy of irradiation demonstrating a deep, left hemisphere arteriovenous malformation. There was no change from the initial angiographic appearance.

the AVM (Fig. 2). The patient developed signs of transtentorial herniation and died shortly thereafter.

Autopsy examination revealed a large area of hemorrhage within the left thalamus, basal ganglia, and sylvian fissure. The AVM contained several areas of recent intraluminal thrombosis and an inflammatory infiltrate. There was a small amount of older thrombus within the lesion, and the surrounding brain was necrotic and hemorrhagic (Fig. 3).

### Case 4: Complete Obliteration

This 32-year-old woman experienced the gradual onset of severe ataxia, diplopia, slurring of speech, and headache. Cerebral angiography demonstrated a large AVM in the dorsal midbrain supplied primarily by the right posterior cerebral and superior cerebellar arteries (Fig. 4 *left*). A large varix drained into the vein of Galen, and there was also inferior drainage to the right sigmoid sinus. Computerized tomography showed moderate hydrocephalus. A ventriculoperitoneal shunt was

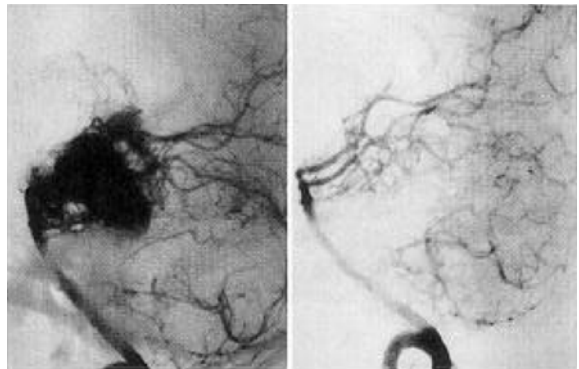


FIG. 4. Case 4. *Left*: Lateral angiogram demonstrating a large arteriovenous malformation (AVM) in the dorsal midbrain supplied primarily by the right posterior cerebral and superior cerebellar arteries. *Right*: Follow-up angiography at 1 year after treatment with 5000 cGy of irradiation showing that the AVM has been completely obliterated.

inserted, resulting in partial resolution of symptoms. The patient was treated with 5000 cGy of irradiation in 25 fractions to a field measuring  $14 \times 14$  cm. During the next few months, the ataxia and diplopia improved remarkably. Follow-up angiography performed 1 year after irradiation revealed complete obliteration of the AVM (Fig. 4 *right*).

### Case 11: Disappearance of AVM on Magnetic Resonance Imaging

This 44-year-old woman suffered a generalized seizure and was investigated with CT, which suggested an AVM in the right frontoparietal area. Angiography confirmed the presence of a large AVM supplied by branches of the right middle cerebral and anterior cerebral arteries (Fig. 5 *left*). She was treated with 4500 cGy of irradiation in 15 fractions to a field measuring  $5 \times 5$  cm. The patient suffered no further seizures and remained well. Follow-up angiography was refused but

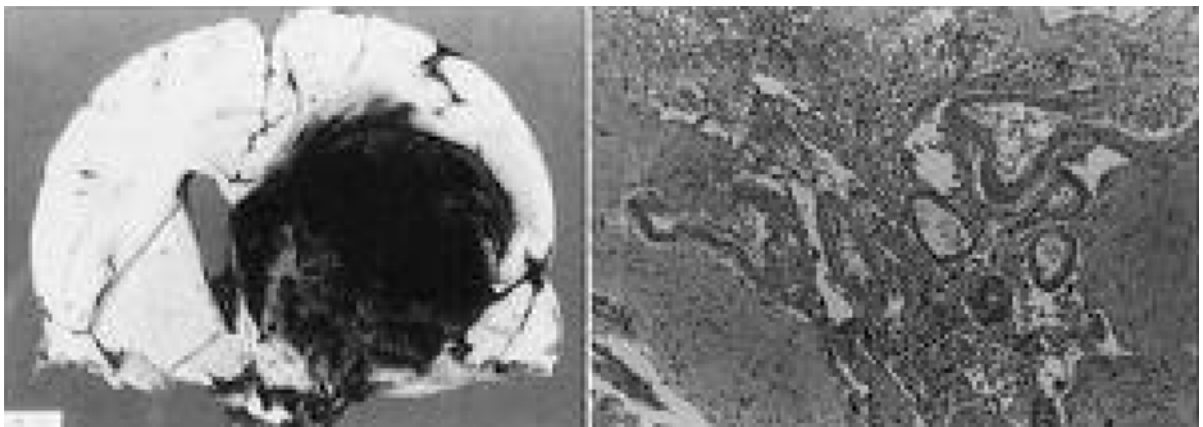


FIG. 3. Case 1. *Left*: Autopsy specimen showing residual arteriovenous malformation (AVM) and a large area of hemorrhage with subfalcine and transtentorial herniation. *Right*: Photomicrograph of the AVM specimen demonstrating patent vessels surrounded by an inflammatory infiltrate and necrotic brain tissue. H & E,  $\times 100$ .

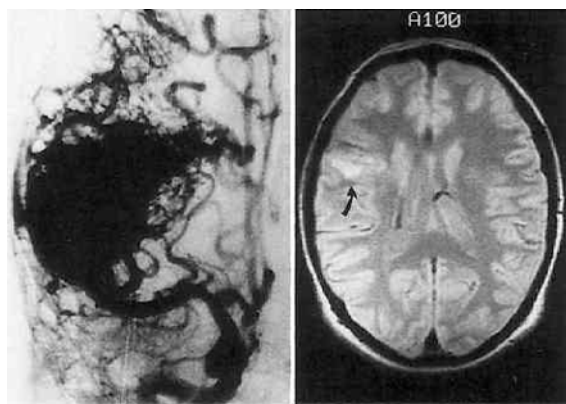


FIG. 5. Case 11. *Left:* Cerebral angiogram demonstrating a large arteriovenous malformation (AVM) supplied by the right middle cerebral and anterior cerebral arteries. *Right:* Axial T<sub>2</sub>-weighted magnetic resonance image obtained 5 years after treatment with 4500 cGy of irradiation showing increased signal (*arrow*) at the site of the previously identified AVM.

she underwent MR imaging 5 years later, which demonstrated no evidence of abnormal vasculature; however, focal areas of increased signal were present in the irradiated area (Fig. 5 *right*). At the time of the last follow-up examination, 8 years after irradiation, she was asymptomatic.

#### *Case 15: Partial Reduction With Subsequent Enlargement*

This 15-year-old boy suffered an intraventricular hemorrhage from a large AVM in the right occipital

area fed by the right posterior cerebral artery (Fig. 6 *left*). He was initially obtunded but made an excellent recovery, with no visual field abnormality. Since surgical removal would have resulted in a visual deficit, it was elected to proceed with irradiation, and the patient received 4500 cGy in 15 fractions to a field measuring 6 × 4 cm. He remained well and was able to continue his education. Follow-up angiography 1 year later demonstrated partial reduction in the size of the lesion (Fig. 6 *center*), which was unchanged on repeat examination 1 year later. However, when angiography was again performed 4 years after irradiation, the lesion had increased to its pretreatment size (Fig. 6 *right*).

### Discussion

#### *Literature Review*

Before surgical excision was established as the treatment of choice for most intracranial malformations,<sup>34</sup> a variety of indirect procedures, including simple decompression,<sup>7,42</sup> carotid ligation,<sup>21,42</sup> ligation of feeding vessels,<sup>38</sup> and conventional radiation treatment, had been employed.<sup>7,29,34,42</sup> The results of such treatments were generally poor, but occasional successes were documented.

Vilhelm Magnus, a neurosurgical pioneer in Norway, performed in 1913 an exploratory craniectomy over the left motor cortex in a woman with focal seizures and papilledema.<sup>12,29</sup> He discovered a large vascular malformation and carried out a decompressive craniectomy but did not attempt to remove the lesion. Considering the risk of causing a motor deficit too great, he elected to treat the patient with radium therapy on four occasions in 1914. She had several seizures in the next 2

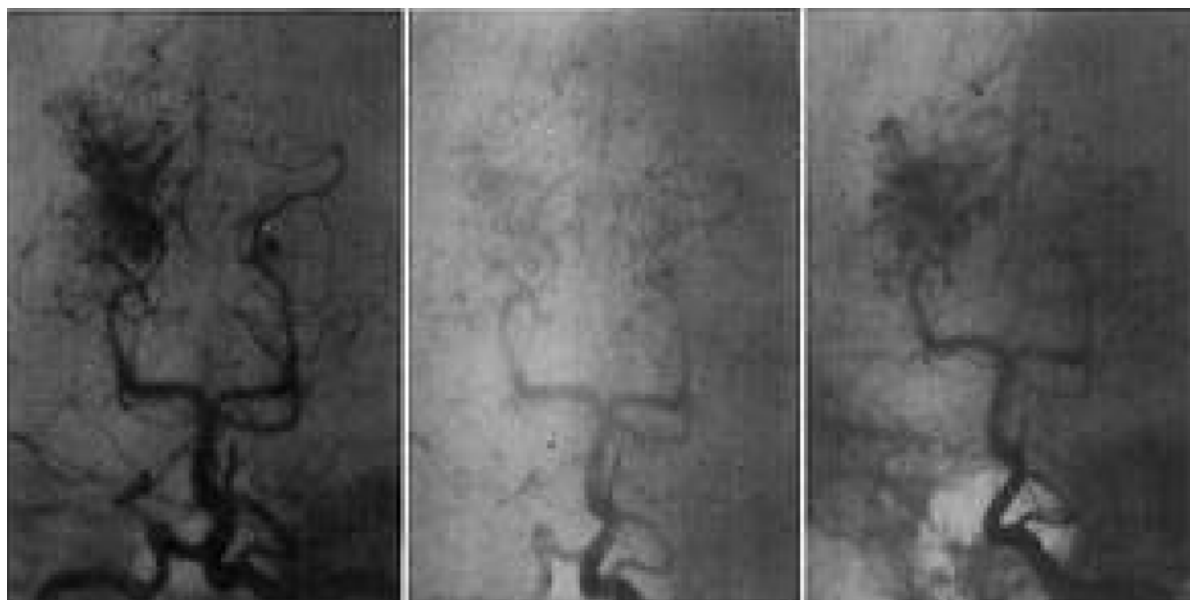


FIG. 6. Angiograms, anteroposterior view, in Case 15. *Left:* Initial angiogram, demonstrating a right occipital arteriovenous malformation (AVM) supplied by the right posterior cerebral artery. *Center:* Angiogram obtained 1 year after treatment with 4500 cGy of irradiation showing a partial reduction in the size of the AVM. *Right:* Angiogram obtained 4 years after treatment demonstrating an increase of the AVM to its original size.

## Conventional radiation therapy of AVM's

years but was seizure-free between 1916 and 1920. Magnus<sup>29</sup> concluded, "In this case radiotherapy was more lenient than the knife."

Cushing and Bailey<sup>7</sup> reviewed their experience with 14 "angiomatic malformations," including eight patients who had received radiation therapy. One of the irradiated cases had a most impressive result. When the malformation was exposed initially in 1924, it appeared as a pulsating tangle of vessels, and a desperate procedure ensued in order to obtain hemostasis. A series of radiotherapeutic treatments was administered 3 years later, and the lesion was re-explored and found to be a firm avascular mass that could be excised with surprising ease without bleeding. Microscopic examination revealed a tangle of blood vessels in which the intima was often greatly proliferated, occluding the lumen. On the basis of their experience, Cushing and Bailey concluded that "radiotherapy (whether given alone, or in conjunction with a decompression or carotid ligation) if persisted in, offers considerable promise of amelioration or possibly of cure."

In 1941, Ray<sup>42</sup> reported his experience in the treatment of six cases of cerebral arteriovenous aneurysm. Three of the patients were treated with irradiation, receiving 3050 cGy, 10,200 cGy, and 13,200 cGy, respectively. He felt that there was "nothing to indicate that it produced the desired effects." Later, in 1948, Olivecrona and Riives<sup>34</sup> described a single patient treated with roentgen therapy in their series of 43 AVM cases; angiography after a 10-year interval demonstrated enlargement of the malformations.

Krayenbühl<sup>21</sup> reported a series of patients treated with carotid artery ligation and described the reduction in size of a single AVM that had also been treated with irradiation. Potter<sup>40</sup> presented the results in 10 cases of irradiated AVM's in the 1955 Hunterian Lecture delivered at the Royal College of Surgeons in England. There was only one death in the treated group and four patients were alive at least 20 years after irradiation. However, no patient had follow-up angiography so there was no proof that the lesions had been obliterated. Nevertheless, he made a plea for the reconsideration of radiation therapy, particularly for those cases unsuitable for excision.

In a series of 110 intracranial AVM's reported by Paterson and McKissock,<sup>38</sup> 11 patients were treated with irradiation. Six patients had no other treatment, two had exploratory craniotomy, two had carotid artery ligation, and one had ligation of cortical feeding vessels. There was no evidence of permanent benefit resulting from irradiation in any case. Four died from recurrent hemorrhage, three deteriorated neurologically, and four were stable 4 to 14 years after treatment.

SVien and Peserico<sup>51</sup> described the regression occurring over several years of a left frontotemporal AVM treated with 3700 cGy of irradiation. A marked reduction in size was demonstrated angiographically 4 years later, at the time of recurrent hemorrhage. The authors considered that intracranial bleeding likely contributed to thrombosis within the lesion in this case.

A series of 10 patients with AVM's treated with irradiation was reported by Bouchard<sup>3</sup> in 1966. Nine

had been followed clinically for 12 to 24 years; in this group, there were no episodes of recurrent hemorrhage. However, an autopsy examination in one patient who died from unrelated illness revealed persistent angiomatous vessels. One patient had been followed for only 2 years, and follow-up angiography showed no evidence of obliteration. After treating seven AVM patients with irradiation, French and Chou<sup>13</sup> concluded that radiation therapy had no effect whatsoever. Of six patients who had been followed clinically, two died from recurrent hemorrhage within 3 years. Radiation therapy in the seventh patient, with an AVM in the corpus callosum, had no apparent effect on follow-up angiography performed 2 years later.

The largest series of patients with AVM's managed with conventional radiation therapy was reported in 1975 by Johnson.<sup>18</sup> He treated 100 cases over a 20-year interval, with the irradiation dose ranging from 4000 to 5000 cGy, and described the preliminary results in 20 patients who underwent cerebral angiography after intervals of 2 to 20 years. The malformation was totally obliterated in nine cases, improved in five, unchanged in five, and enlarged in one. He considered that his figures were not valid, as follow-up evaluation for the series was incomplete. On the basis of his preliminary results, he concluded that irradiation was effective for small to medium-sized, medially placed angiomas. Unfortunately, there have been no subsequent follow-up reports on this large series.

A recent case report by Tognetti, *et al.*,<sup>52</sup> documents significant regression of a right parietal AVM at 2 years after treatment with 4500 cGy of irradiation. Poulsen<sup>41</sup> described six patients treated with irradiation doses of 4500 to 7500 cGy. Follow-up angiography was performed in three patients and demonstrated complete obliteration in one and minimal effect in two. The other three patients underwent CT which showed a persistent AVM.

### Results of Present Series

In the present series, 12 of the 15 patients have had follow-up angiography at 1 to 21 years after irradiation. Complete obliteration was seen in two cases and a 95% reduction in a third. One patient had documented regression in AVM size after 1 year, only to have the AVM enlarge again to its preradiation therapy size. Computerized tomography in one case demonstrated persistence of the AVM; therefore, angiography was not performed. Magnetic resonance imaging carried out at 5 years after irradiation in another case suggested complete obliteration. Lunsford, *et al.*,<sup>27</sup> reported that, in their series of patients treated with gamma knife radiosurgery, MR imaging correctly demonstrated complete angiographic obliteration in 91% of cases. Thus, in the 14 patients in our series with radiographic follow-up evaluation, at best only three lesions (21%) were obliterated.

Large AVM's remain the greatest challenge both for surgical excision<sup>8,37</sup> and radiation therapy. The preferred AVM size for stereotactically guided isocentric radiation therapy (radiosurgery) is approximately 3 cm. In the present series, only five AVM's had a maximum

diameter of less than 3 cm, and two (20%) of the 10 larger AVM's had definite or probable complete obliteration. In a series of radiosurgically treated AVM's reported by Steiner,<sup>48</sup> 26 lesions were not entirely encompassed by the treatment plan and were studied angiographically after 2 years. Fourteen showed no change and only one (3.8%) was completely obliterated. Of the AVM's that were entirely encompassed, an 86.5% obliteration rate was accomplished.

The rebleeding rate of 3.3% per year in our series of conventionally irradiated AVM's shows no apparent difference from the natural history of untreated lesions.<sup>4,14,17,36,55</sup> There was no protection from recurrent hemorrhage as a result of irradiation in the absence of complete obliteration. It has been known for many years that only surgical methods that result in complete removal of the nidus are successful in preventing recurrent bleeding.<sup>8</sup> Recent experimental work by Lo, *et al.*,<sup>24</sup> supports this concept for lesions treated with radiation therapy. Partial elimination of the AVM results in alteration of the pressure gradients in remaining shunt vessels and may cause redistribution of regional cerebral blood flow so that increased flow occurs in the residual nidus, which may increase the probability of hemorrhage.

#### *Pathology of Irradiated AVM's*

The effects of irradiation on cells are primarily destructive but there may be increased activity of some cells secondary to the preceding injury. The results differ quantitatively but not qualitatively when produced by differing forms of ionizing irradiation.<sup>48</sup> Endothelial tissue of small blood vessels appears to be more sensitive to radiation therapy than that of larger vessels. Early changes include swelling, degeneration, and necrosis of endothelial cells with subsequent thrombus formation, fissuring of walls, and the development of punctate hemorrhages. The small vessels undergo progressive degeneration and fibrosis, and there is a perivascular infiltrate of lymphocytes and plasma cells.<sup>43,48</sup> The inflammatory process may be so great as to stimulate infection.<sup>30</sup> Larger vessels also show degenerative changes in the early period but they are not as severely affected as the smaller vessels.

Delayed radiation effects are usually seen months or years after initial radiation therapy. The injured endothelium proliferates and may ultimately result in obliteration of the lumen. There may also be proliferation of medial elements and perivascular fibrosis.<sup>43</sup> Although the precise mechanism of damage to the larger vessels is unclear, pathological evidence suggests that progressive sclerosis and subsequent occlusion of the vasa vasorum after irradiation interferes with nutrition of the vessel wall elements, leading to an endarteritis obliterans.<sup>48</sup> Eventually the vascular lesions contain such extensive and frequently confluent fibrous, acellular, hyaline thickening of the vessel walls that virtually complete occlusion results.

In addition to endothelial proliferation, thrombosis also plays an important role in the occlusion of pathological vessels. This may occur as a result of radiation

therapy<sup>43,48</sup> but it can also be seen in untreated AVM's.<sup>30,31,43,46,48</sup> Factors promoting thrombosis include intimal injury, turbulent blood flow, and increased platelet reactivity. Arteriovenous malformations are dynamic lesions with a high incidence of ongoing platelet aggregation.<sup>50</sup> Spontaneous regression or disappearance of angiographically confirmed AVM's is an uncommon but well-recognized aspect of their natural history.<sup>6,9,11,15,22,28,32,35,39,53</sup> Furthermore, many cases of angiographically occult vascular malformations are pathologically recognized as thrombosed AVM's.<sup>1,10,19,25,54</sup> Thrombosed vascular malformations may present with focal deficits or seizure disorders<sup>54</sup> but they may be of substantial size<sup>19</sup> and may result in hemorrhage despite the fact that they do not opacify on angiography.<sup>10,25</sup> It is most likely that the thrombosis occurring in irradiated AVM's is a result of treatment and not merely a spontaneous occurrence since, in stereotactically irradiated lesions, the obstructed segments of the feeding arteries and the obliterated tangles of vessels coincide precisely with the target area and the process occurs at a predictable and reproducible time after treatment.<sup>48</sup>

#### **Conclusions**

Direct surgical excision is the treatment of choice for the majority of intracranial AVM's. For AVM's that are unsuitable for such an approach, conventional radiation therapy has proven disappointing. Stereotactic radiosurgical techniques have been effective in the treatment of small lesions but only after a latent period of months to years. The treatment of large AVM's located in deep or inaccessible areas of the brain remains unsatisfactory. Multidisciplinary strategies incorporating surgical, endovascular, and radiotherapeutic methods are presently being evaluated in the treatment of these complex and challenging problems.

#### **References**

1. Bell BA, Kendall BE, Symon L: Angiographically occult arteriovenous malformations of the brain. *J Neurol Neurosurg Psychiatry* 41:1057-1064, 1978
2. Betti OO, Munari C, Rosler R: Stereotactic radiosurgery with the linear accelerator: treatment of arteriovenous malformations. *Neurosurgery* 24:311-321, 1989
3. Bouchard JLL: *Radiation Therapy of Tumors and Diseases of the Nervous System*. Philadelphia: Lea and Febiger, 1966, pp 145-147
4. Brown RD Jr, Wiebers DO, Forbes G, et al: The natural history of unruptured intracranial arteriovenous malformations. *J Neurosurg* 68:352-357, 1988
5. Colombo F, Benedetti A, Pozza F, et al: Linear accelerator radiosurgery of cerebral arteriovenous malformations. *Neurosurgery* 24:833-840, 1989
6. Conforti P: Spontaneous disappearance of cerebral arteriovenous angioma. Case report. *J Neurosurg* 34:432-434, 1971
7. Cushing H, Bailey P: *Tumors Arising From the Blood-Vessels of the Brain. Angiomatous Malformations and Hemangioblastomas*. Springfield, Ill: Charles C Thomas, 1928, pp 1-95
8. Drake CG: Cerebral arteriovenous malformations: con-



## Conventional radiation therapy of AVM's

- siderations for and experience with surgical treatment in 166 cases. *Clin Neurosurg* 26:145-208, 1979
9. Dyck P: Spontaneous thrombosis of an arteriovenous malformation. *Neurosurgery* 1:287-290, 1977
10. Ebeling JD, Tranmer BI, Davis KA, et al: Thrombosed arteriovenous malformations: a type of occult vascular malformation. Magnetic resonance imaging and histopathological correlations. *Neurosurgery* 23:605-610, 1988
11. Eisenman JI, Alekoubides A, Pribram H: Spontaneous thrombosis of vascular malformations of the brain. *Acta Radiol* 13:77-85, 1972
12. Fodstad H, Ljunggren B: Radiation therapy for arteriovenous malformations. *Neurosurgery* 27:1027, 1990 (Letter)
13. French LA, Chou SN: Conventional methods of treating intracranial arteriovenous malformations. *Prog Neurol Surg* 3:274-319, 1969
14. Fults D, Kelly DL Jr: Natural history of arteriovenous malformations of the brain: a clinical study. *Neurosurgery* 15:658-662, 1984
15. Hanigan WC, Brady T, Medlock M, et al: Spontaneous regression of giant arteriovenous fistulae during the perinatal period. Case report. *J Neurosurg* 73:954-957, 1990
16. Heros RC, Korosue K: Radiation treatment of cerebral arteriovenous malformations. *N Engl J Med* 323:127-129, 1990 (Editorial)
17. Itoyama Y, Uemura S, Ushio Y, et al: Natural course of unoperated intracranial arteriovenous malformations: study of 50 cases. *J Neurosurg* 71:805-809, 1989
18. Johnson RT: Radiotherapy of cerebral angiomas. With a note on some problems in diagnosis, in Pia HW, Gleave JRW, Grote E, et al (eds): *Cerebral Angiomas. Advances in Diagnosis and Therapy*. New York: Springer-Verlag, 1975, pp 256-266
19. Kamrin RB, Buchsbaum HW: Large vascular malformations of the brain not visualized by serial angiography. *Arch Neurol* 13:413-420, 1965
20. Kjellberg RN, Hanamura T, Davis KR, et al: Bragg-peak proton-beam therapy for arteriovenous malformations of the brain. *N Engl J Med* 309:269-274, 1983
21. Krayenbühl H: Carotid ligation for intracranial arteriovenous malformations. *Proceedings of the Fifth International Neurological Congress (Lisbon, 1953)*. 1954, Vol 3, pp 173-178
22. Kushner J, Alexander E Jr: Partial spontaneous regressive arteriovenous malformation. *J Neurosurg* 32:360-366, 1970
23. Levy RP, Fabrikant JI, Frankel KA, et al: Stereotactic heavy-charged-particle Bragg peak radiosurgery for the treatment of intracranial arteriovenous malformations in childhood and adolescence. *Neurosurgery* 24:841-852, 1989
24. Lo EH, Fabrikant JI, Levy RP, et al: An experimental compartmental flow model for assessing the hemodynamic response of intracranial arteriovenous malformations to stereotactic radiosurgery. *Neurosurgery* 28:251-259, 1991
25. Lobato RD, Perez C, Rivas JJ, et al: Clinical, radiological, and pathological spectrum of angiographically occult intracranial vascular malformations. Analysis of 21 cases and review of the literature. *J Neurosurg* 68:518-531, 1988
26. Loeffler JS, Alexander E III, Siddon RL, et al: Stereotactic radiosurgery for intracranial arteriovenous malformations using a standard linear accelerator. *Int J Radiat Oncol Biol Phys* 17:673-677, 1989
27. Lunsford LD, Kondziolka D, Flickinger JC, et al: Stereotactic radiosurgery for arteriovenous malformations of the brain. *J Neurosurg* 75:512-524, 1991
28. Mabe H, Furuse M: Spontaneous disappearance of a cerebral arteriovenous malformation in infancy. Case report. *J Neurosurg* 46:811-815, 1977
29. Magnus V: Bidrag til hjernechirurgiens klinik og resultater. *Norsk Mag Laegevidensk (Suppl Merkur Bok & Akcidenstrykkeri)* 82:1-138, 1921
30. McCormick WF: The pathology of angiomas, in Fein JM, Flamm ES (eds): *Cerebrovascular Surgery*, Vol 4. New York: Springer-Verlag, 1985, pp 1073-1095
31. McCormick WF, Hardman JM, Boulter TR: Vascular malformations ("angiomas") of the brain, with special reference to those occurring in the posterior fossa. *J Neurosurg* 28:241-251, 1968
32. Nehls DG, Pittman HW: Spontaneous regression of arteriovenous malformations. *Neurosurgery* 11:776-780, 1982
33. Ogilvy CS: Radiation therapy for arteriovenous malformations: a review. *Neurosurgery* 26:725-735, 1990
34. Olivecrona H, Riives J: Arteriovenous aneurysms of the brain: their diagnosis and treatment. *Arch Neurol Psychiatry* 59:567-602, 1948
35. Omojola MF, Fox AJ, Viñuela FV, et al: Spontaneous regression of intracranial arteriovenous malformations. Report of three cases. *J Neurosurg* 57:818-822, 1982
36. Ondra SL, Troupp H, George ED, et al: The natural history of symptomatic arteriovenous malformations of the brain: a 24-year follow-up assessment. *J Neurosurg* 73:387-391, 1990
37. Pasqualin A, Barone G, Cioffi F, et al: The relevance of anatomic and hemodynamic factors to a classification of cerebral arteriovenous malformations. *Neurosurgery* 28:370-379, 1991
38. Paterson JH, McKissock W: A clinical survey of intracranial angiomas with special reference to their mode of progression and surgical treatment: a report of 110 cases. *Brain* 79:233-266, 1956
39. Patil AA: Angiographic disappearance and reappearance of an arteriovenous malformation of the cerebellum and brain stem, and its surgical excision. A case report. *Acta Neurochir* 62:247-252, 1982
40. Potter JM: Angiomatous malformations of the brain: their nature and prognosis. Hunterian Lecture. *Ann R Coll Surg Engl* 16:227-243, 1955
41. Poulsen MG: Arteriovenous malformations — a summary of 6 cases treated with radiation therapy. *Int J Radiat Oncol Biol Phys* 13:1553-1557, 1987
42. Ray BS: Cerebral arteriovenous aneurysms. *Surg Gynecol Obstet* 73:615-648, 1941
43. Rubinstein LJ: *Tumors of the Central Nervous System. Atlas of Tumor Pathology, Series 2, Fascicle 6*. Washington, DC: Armed Forces Institute of Pathology, 1972, pp 349-360
44. Schwartz M, O'Brien P, Davey P, et al: Current status of radiosurgery for arteriovenous malformations. *Can J Neurol Sci* 18:499-502, 1991
45. Souhami L, Olivier A, Podgorsak EB, et al: Radiosurgery of cerebral arteriovenous malformations with the dynamic stereotactic irradiation. *Int J Radiat Oncol Biol Phys* 19:775-782, 1990
46. Stehbens WE: *Pathology of the Cerebral Blood Vessels*. St Louis: CV Mosby, 1972, pp 471-558
47. Steinberg GK, Fabrikant JI, Marks MP, et al: Stereotactic heavy-charged-particle Bragg-peak radiation for intracranial arteriovenous malformations. *N Engl J Med* 323:96-101, 1990

48. Steiner L: Radiosurgery in cerebral arteriovenous malformations, in Fein JM, Flamm ES (eds): **Cerebrovascular Surgery, Vol 4**. New York: Springer-Verlag, 1985, pp 1161-1215
49. Steiner L, Leksell L, Forster DM, et al: Stereotactic radiosurgery in intracranial arterio-venous malformations. **Acta Neurochir Suppl 21**:195-209, 1974
50. Sutherland GR, King ME, Drake CG, et al: Platelet aggregation within cerebral arteriovenous malformations. **J Neurosurg 68**:198-204, 1988
51. Svien HJ, Peserico L: Regression in size of arteriovenous anomaly. **J Neurosurg 17**:493-496, 1960
52. Tognetti F, Andreoli A, Cuscini A, et al: Successful management of an intracranial arteriovenous malformation by conventional irradiation. **J Neurosurg 63**:193-195, 1985
53. Wakai S: Thrombosed arteriovenous malformations. **J Neurosurg 58**:457, 1983 (Letter)
54. Wharen RE Jr, Scheithauer BW, Laws ER Jr: Thrombosed arteriovenous malformations of the brain. An important entity in the differential diagnosis of intractable focal seizure disorders. **J Neurosurg 57**:520-526, 1982
55. Wilkins RH: Natural history of intracranial vascular malformations: a review. **Neurosurgery 16**:421-430, 1985

---

Manuscript received March 18, 1992.

Accepted in final form July 28, 1992.

*Address reprint requests to:* Kost V. Elisevich, M.D.,  
Department of Neurological Surgery, Henry Ford Hospital,  
2799 West Grand Boulevard, Detroit, Michigan 48202.