

## Infantile panthalamic infarct with a striking sonographic finding: the “bright thalamus”

H. S. Wang<sup>1</sup> and S. C. Huang<sup>2</sup>

Departments of Paediatrics, <sup>1</sup> Chang Gung Memorial Hospital at Taipei, and Chang Gung Medical College, Taiwan, <sup>2</sup> Chang Gung Memorial Hospital at Kaohsiung, Republic of China

Received: 12 February 1991

**Summary.** A “bright thalamus” is not uncommonly observed in cranial sonograms of asphyxiated neonates, but not those of older infants. Three infants, aged 9–14 months, developed acute onset of seizures and disturbance of consciousness after a minor prodromal illness. Bilateral thalamic infarcts were demonstrated by ultrasonography and CT. One patient expired from causes not directly related to the infarcts; the other two survived with severe neurological sequelae.

**Key words:** Bright thalamus – Thalamic infarct – Infantile panthalamic infarct – Ultrasonography – Computed tomography – Paediatric neuroradiology

Involvement of the thalamus in asphyxiated term or pre-term neonates is not uncommon [1–9], and is manifest on sonograms as a “bright thalamus” due to markedly increased echogenicity [10–14]. The pathological changes include infarction, haemorrhage, calcification and status marmoratus [15]. However, in older infants, thalamic infarcts severe enough to be seen sonographically as a symmetrical, diffusely “bright thalamus” are rarely reported in the English literature, to the best of our knowledge. Three previously normal infants presenting with acute encephalopathy due to infarction of the whole thalamus are described.

### Case reports

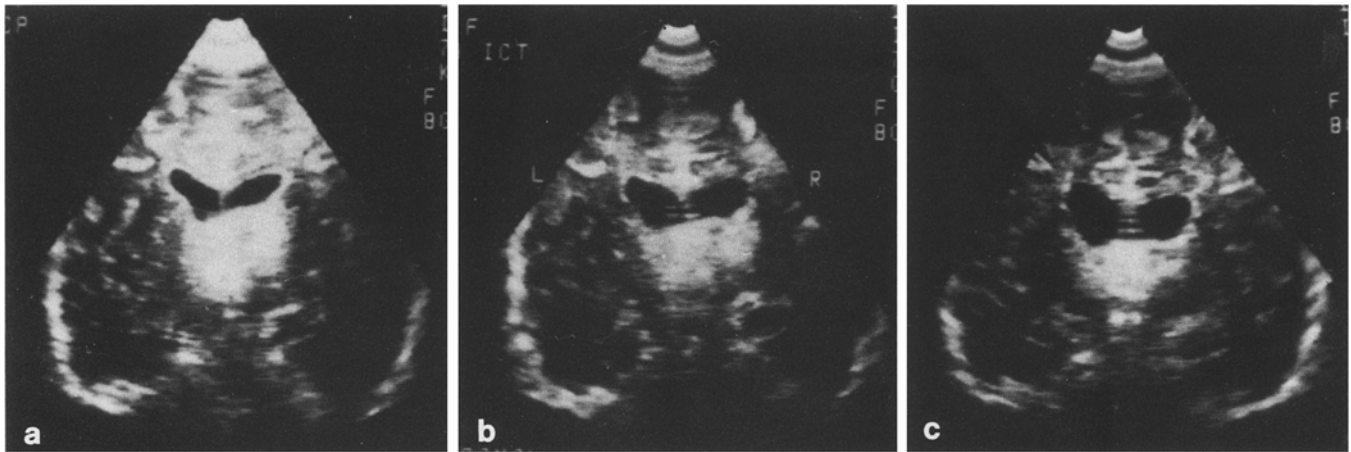
#### Case 1

A 9-month-old girl was well until 4 days prior to admission when she developed a cough, vomiting, and irritability. Two days later, she had sudden, repeated generalized seizures, and soon became stuporous. Examination 2 days later showed a rectal temperature of 38.1°C, pulse rate 144/min, respiratory rate 58/min, blood pressure 107/68 mm Hg, and body weight 7.8 kg. The anterior fontanelle was tense and bulging. The mucosae were mildly

dry, but the skin did not appear dehydrated. Heart sounds were regular without murmur. She was semicomatose. Deep tendon reflexes were diffusely increased. No focal weakness could be found. The blood pressure was normal throughout admission. Blood analysis, including gases, was normal, as was the cerebrospinal fluid. Ultrasonography showed mild dilatation of both lateral ventricles and markedly increased echogenicity of the thalamus bilaterally, which appeared conjoined into one mass obliterating the third ventricle (Fig. 1 a). CT showed hypodensity of both thalami with no abnormal contrast enhancement. The patient could reach for objects and had a social smile 1 week after admission. Repeat sonography and CT showed almost no change, except for mild enlargement of the lateral ventricles (Fig. 1 b, c). Initially discharged without antiepileptic drugs, the patient was readmitted 2 months later for recurrent seizures and placed on phenobarbitone 30 mg/day. Developmental retardation was noted. Subsequently, she had two episodes of clustered attacks in spite of good compliance with the phenobarbitone. The final attack resulted in her death 8 months after the onset of her illness. Pathological examination of the brain showed mature thalamic infarcts.

#### Case 2

A previously healthy 10-month-old girl developed mild fever and a runny nose 2 days before admission. On the day of admission, she had several episodes of vomiting and diarrhoea; urine volume fell. Repetitive generalized convulsions occurred several hours later. Examination showed a rectal temperature of 37.8°C, pulse rate 164/min, respiratory rate 43/min and blood pressure 92/65 mm Hg. The anterior fontanelle was flat. The mucosae were mildly dry, but the skin was not dehydrated; heart sounds were normal. She was semicomatose and responded to deep pain only. No sign of increased intracranial pressure, meningitis nor any focal neurological deficit was found. Her blood pressure remained normal throughout the admission. Laboratory tests of blood and



**Fig. 1a-c.** Case 1. **a** Initial sonogram showing markedly increased echogenicity of both thalami which appear as a single mass. **b** A study 6 days later was almost the same except for enlargement of the lateral ventricles. **c** Follow-up 13 days later

cerebrospinal fluid showed no significant abnormality. The EEG revealed diffuse low voltage delta waves. Cranial sonography showed markedly increased echogenicity in both thalami (Fig. 2a), and CT revealed low density in the thalamus and periventricular areas bilaterally (Fig. 2b). Carotid and vertebral angiography performed 2 days later showed no vascular occlusion. She remained severely handicapped 16 months after the onset of her illness. Follow-up sonography showed less hyperechogenicity in the thalamic region and mild dilatation of the lateral ventricles (Fig. 2c). Decreased size of the thalamic and periventricular infarcts was demonstrated on CT 10 days after the onset (Fig. 2d).

### Case 3

A previously normal 14-month-old girl developed mild fever 3 days and vomiting 1 day prior to admission. Her fluid intake and urinary output decreased. On the day of admission, she had diarrhoea followed by a generalized seizure. Physical examination showed that she was afebrile with pulse rate 128/min, respiratory rate 44/min and blood pressure 98/64 mm Hg. The anterior fontanelle was flat, the mucosae were dry and the skin appeared dehydrated. The heart sounds were normal. She was semicomatose, but no sign of increased intracranial pressure, meningitis, or focal neurological deficit could be found. Investigations were normal, apart from serum AST: 164 units/l; BUN: 31 mg %; PT and PTT: 17 s (control 12.7) and > 100 s (control 31.8) respectively and blood ammonia: 292 µg % (normal 40–110 µg %); 2 days after admission these values all returned to normal apart from the AST, which dropped to 60 units/l 5 days after admission. Sonography showed marked hyperechogenicity of both thalami (Fig. 3a). CT showed hypodensity of both thalami and mild dilatation of the lateral ventricles (Fig. 3b). Blood pressure was normal throughout the course. Her consciousness did not improve much. Ten months after onset, she had spontaneous eye opening but no visual following. She moved limbs aimlessly and did

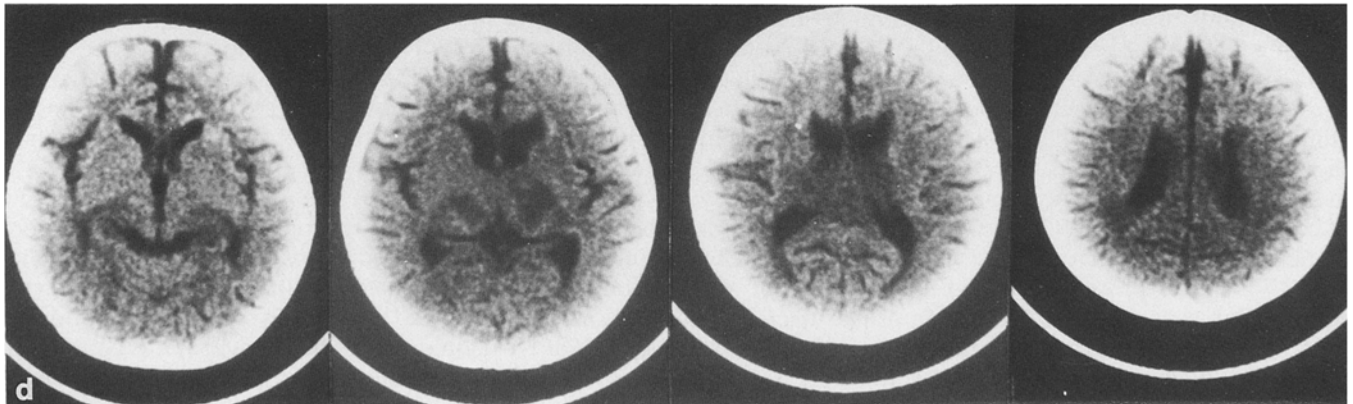
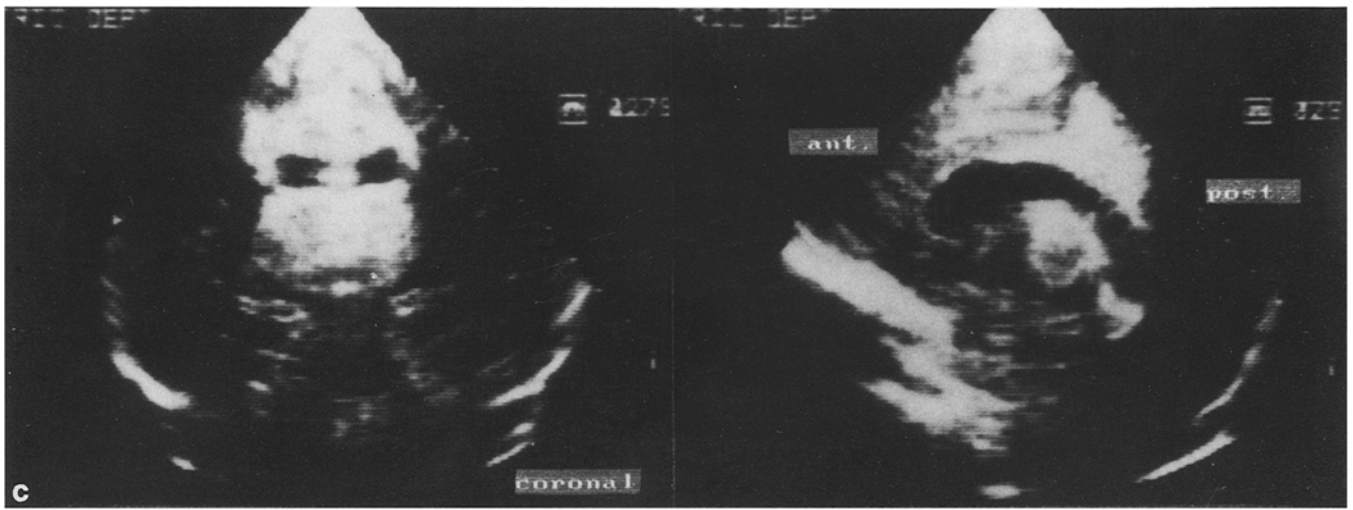
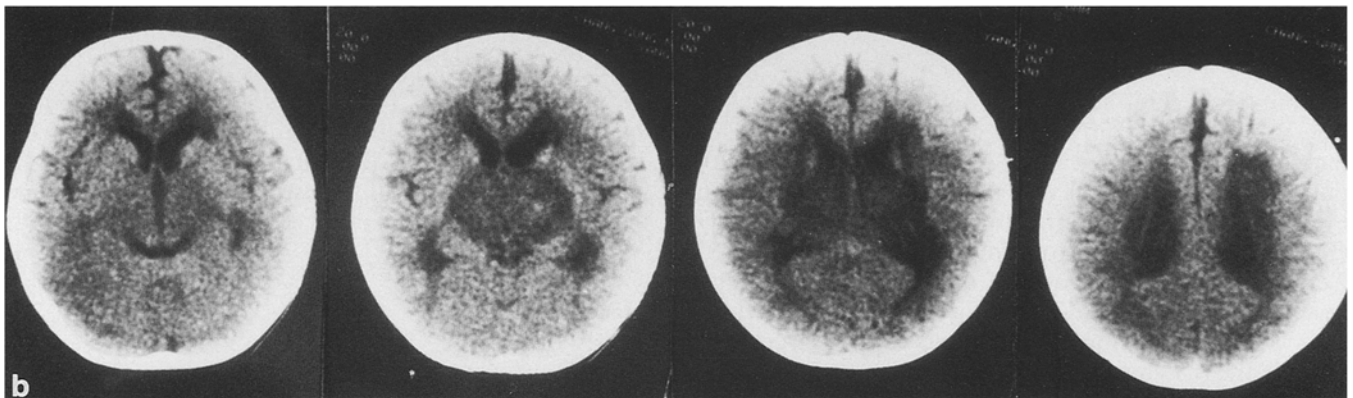
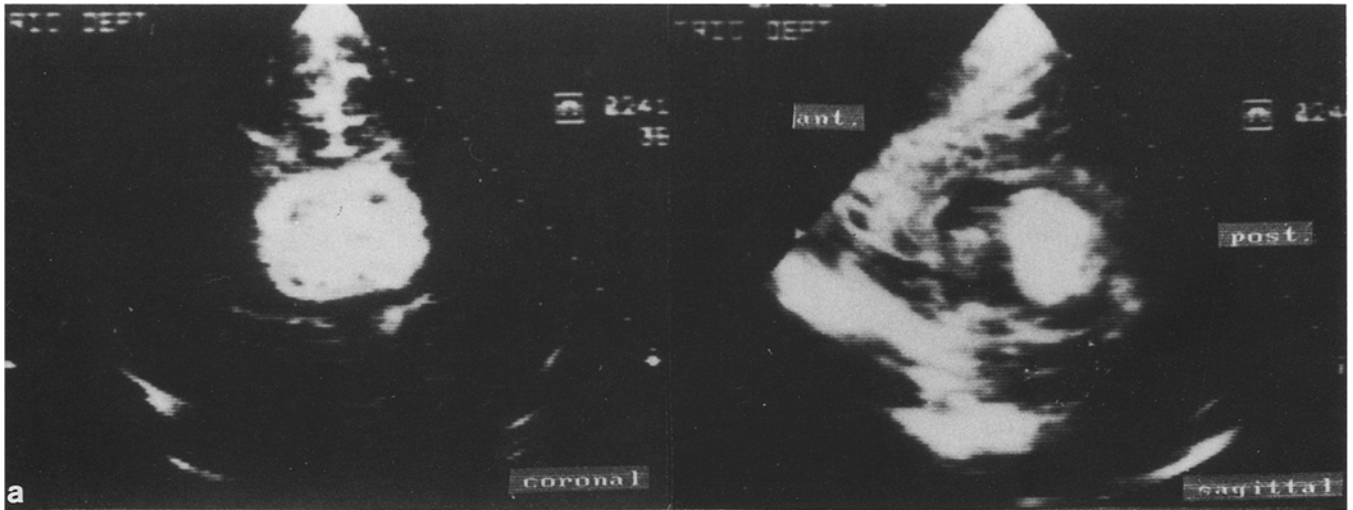
not respond socially. Follow-up sonography showed less hyperechogenicity of the thalami and the appearance of brain atrophy (Fig. 3c). Gradually decrease in size of the thalamic infarcts was demonstrated on CT scan 1 and 1.5 years after the onset of the illness (Fig. 3d).

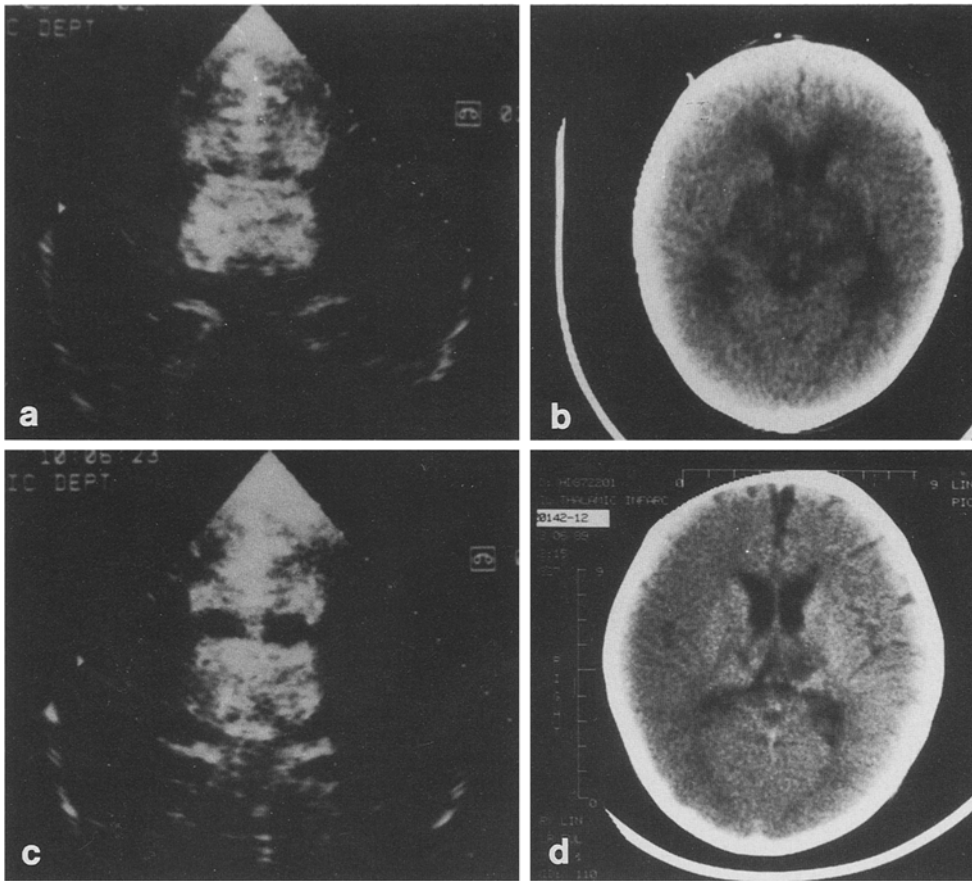
### Discussion

In adults, thalamic infarction is usually unilateral and lacunar [16]. Some cases of bilateral paramedian thalamic infarction may result from occlusion of a thalamo-subthalamic perforating artery which supplies the medial thalamus on both sides, as reported in adults with underlying risk factors of hypertension or atherosclerosis [17–21]. Deep cerebral venous thrombosis causing symmetrical, diffuse thalamic infarcts has been demonstrated by CT and/or MRI in a few cases [22–24], but the margins of thalamic infarcts seen on CT were not as sharp and clear-cut as in our cases.

The three patients reported here had acute onset of seizures and disturbed consciousness beginning after a few days of non-specific minor illness. Their ages at the onset of disease were 9, 10 and 14 months. Central nervous system infection, intoxication, Reye's syndrome, and haemorrhagic shock syndrome were all excluded by the clinical course and laboratory findings. No risk factor for thromboembolism existed, except minimal fluid depletion [25]. CT showed no direct signs of deep cerebral venous thrombosis [24]. A normal anion gap excluded the possibility of organic acidemia. Since the clinical course in the two survivors showed neither deterioration nor recurrence, the possibility of an inborn error of metabolism was considered remote.

The clinical course of the three patients was quite similar; all had minor prodromal disease causing poor oral intake and increased GI loss. A component of dehydration is possible as two patients had diminished urine output, and one had transiently marked elevation of AST, PT, PTT, ammonia and BUN which was considered as evidence of the ischaemic insult being caused by circu-





**Fig. 3a–d.** Case 3. **a** Sonogram at onset showed markedly increased echogenicity of both thalami. **b** Initial CT showed hypodensity of both thalami and periventricular areas. **c** Sonogram 6 days later showed fading of the bright thalamus. **d** CT 6 months later showed the infarct to have decreased in area

latory insufficiency. These patients had no evidence of low blood pressure before or after their change of consciousness. Nevertheless, a relative circulatory insufficiency or impending shock may have existed. The patients' condition was not considered severe until the onset of seizures. Their circulatory status could have been further compromised with the occurrence of seizures.

Possible causative factors may have been excessive metabolic requirements and relative vascular insufficiency of those thalamic areas which were infarcted. Symmetrical, diffuse thalamic infarction, so-called status marmoratus, is not uncommon in survivors of neonatal asphyxia [9]. In the newborn period, the thalamus is particularly vulnerable to hypoxaemia and/or ischaemia because of its high metabolic requirement [26]. Rorke [27] suggested that selective damage to the thalamus or deep grey nuclei might be the result of diminution of blood flow in branches of basal penetrating vessels or of selective neuronal vulnerability. Our patients could have sustained episodes of partial and total asphyxia which injured the thalamus in particular as Myers suggested [28].

The outstanding appearance of a “bright thalamus” on sonography may serve as a landmark of profound asphyxial damage [10–14], not only in postasphyxial neonates but also in infants with acute encephalopathy, as in our patients. Their prognoses were grave. Early, adequate hydration of infants with poor intake and increased gastrointestinal loss may help to avoid this tragedy.

## References

1. Leech RW, Alvord EC Jr (1977) Anoxic-ischemic encephalopathy in the human neonatal period. *Arch Neurol* 34: 109–113
2. Kotagal S, Toce S, Kotagal P, Archer C (1983) Symmetric bithalamic and striatal hemorrhage following perinatal hypoxia in a term infant. *J Comput Assist Tomogr* 7: 353–355
3. Trounce JQ, Dodd KL, Fawer CL, Fiedler AR, Punt J, Levene HI (1985) Primary thalamic haemorrhage in the newborn. *Lancet* I: 190–192
4. Primhak RA, Smith MF, Hill AE, Morgan MEI (1985) Primary thalamic haemorrhage in first week of life. *Lancet* I: 635
5. Donn SM (1985) Possible mechanisms of primary thalamic haemorrhage in the newborn. *Lancet* I: 823
6. Weissman BM, Foster D, Baley JE (1987) Primary thalamic hemorrhage in a preterm infant. *Pediatr Neurol* 3: 121–122
7. Adams C, Hochhauser L, Logan WJ (1988) Primary thalamic and caudate hemorrhage in term neonates presenting with seizures. *Pediatr Neurol* 4: 175–177
8. Volt T, Lemburg P (1987) Damage of thalamus and basal ganglia in asphyxiated full-term neonates. *Neuropediatrics* 18: 176–181
9. Colamaria V, Curatolo P, Cusmai R, Bernardina BD (1988) Symmetrical bithalamic hyperdensities in asphyxiated full-term new-

**Fig. 2a–d.** Case 2. **a** Sonogram at onset showed markedly increased echogenicity of both thalami. **b** Initial CT showed low density within both thalami and the periventricular areas. **c** Sonogram 2 weeks later showed fading of the bright thalamus. **d** Decrease in the area of the thalamic low density was shown on CT 10 days after the onset

- borns: an early indicator of status marmoratus. *Brain Dev* 10: 57–59
10. Babcock DS, Ball WS Jr (1983) Postasphyxial encephalopathy in full-term infants: ultrasound diagnosis. *Radiology* 148: 417–423
  11. Kreuzer KL, Schmidt RE, Shackelford GD, Volpe JJ (1984) Value of ultrasound for identification of acute hemorrhagic necrosis of thalamus and basal ganglia in an asphyxiated term infant. *Ann Neurol* 16: 361–363
  12. Shen EY (1984) The “bright thalamus”. *Arch Dis Child* 59: 695
  13. Hertzberg BS, Pasto ME, Needleman L, Kurtz AB, Rifkin MD (1987) Postasphyxial encephalopathy in term infants: sonographic demonstration of increased echogenicity of the thalamus and basal ganglia. *J Ultrasound Med* 6: 197–202
  14. Shen EY, Huang CC, Chyou SC, Hung HY, Hsu CH, Huang FY (1986) Sonographic finding of the bright thalamus. *Arch Dis Child* 61: 1096–1099
  15. Shen EY, Lin JCT, Shih CC (1988) Pathological echogenicity of the thalamus in newborn and young infants. *J Formosan Med Assoc* 87: 891–897
  16. Bogousslavsky J, Regli F, Uske A (1988) Thalamic infarcts: clinical syndromes, etiology, and prognosis. *Neurology* 38: 837–848
  17. Castaigne P, Lhermitte F, Buge A, Escourolle R, Hauw JJ, Lyon-Coen O (1981) Paramedian thalamic and midbrain infarct: clinical and neuropathological study. *Ann Neurol* 10: 127–148
  18. Bewermeyer H, Dreesbach HA, Rackl A, Neveling M, Heiss W-D (1985) Presentation of bilateral thalamic infarction on CT, MRI and PET. *Neuroradiology* 27: 414–419
  19. Gerber O, Gudesblatt M (1986) Bilateral paramedian thalamic infarctions: a CT study. *Neuroradiology* 28: 128–131
  20. Gentilini M, De Renzi E, Crisi G (1987) Bilateral paramedian thalamic artery infarcts: report of eight cases. *J Neurol Neurosurg Psychiatry* 50: 900–909
  21. Eick JJ, Miller KD, Bell KA, Tutton RH (1981) Computed tomography of deep cerebral venous thrombosis in children. *Radiology* 140: 399–402
  22. Kim KS, Walczak TS (1986) Computed tomography of deep cerebral venous thrombosis. *J Comput Assist Tomogr* 10: 386–390
  23. Gupta KL, Kapila A, Duvall ER (1987) Computed tomographic evaluation of deep cerebral venous thrombosis. *Ala J Med Sci* 24: 41–45
  24. Ashforth RA, Melanson D, Ethier R (1989) MR of deep cerebral venous thrombosis. *Can J Neurol Sci* 16: 417–421
  25. Vomberg PP, Breederveld C (1987) Cerebral thromboembolism due to antithrombin III deficiency in two children. *Neuropediatrics* 18: 42–44
  26. Vannucci RC, Voorhies TM (1984) Perinatal cerebral hypoxia-ischemia: pathogenesis and neuropathology. In: Sarnat HB (ed) *Topics in neonatal neurology*. Grune and Stratton, Orlando, pp 27–59
  27. Rorke LB (1982) *Pathology of perinatal brain injury*. Raven Press, New York
  28. Myers RE (1975) Four patterns of perinatal brain damage and their conditions of occurrence in primates. *Adv Neurol* 10: 223–234

Dr. H.-S. Wang  
 Department of Pediatrics  
 Chang Gung Memorial Hospital  
 199, Tung-Hua North Road  
 Taipei, Taiwan 10591  
 Republic of China