

Nonverbal Amnesia and Asymmetric Cerebral Lesions Following Encephalitis

PAUL J. ESLINGER,* HANNA DAMASIO,† ANTONIO R. DAMASIO,†
AND NELSON BUTTERS‡

**Departments of Medicine (Division of Neurology) and Behavioral Science, Pennsylvania State University College of Medicine, The Milton S. Hershey Medical Center;*

†Department of Neurology, Division of Behavioral Neurology and Cognitive Neuroscience, University of Iowa College of Medicine;

and ‡Department of Psychiatry, University of California, San Diego, Psychology Service, VAMC

Global amnesia after herpes simplex encephalitis has been typically associated with lesions of anterior and medial temporal lobe, inferior and medial frontal lobe, and insula. The neuropathologic correlates of this disease are usually considered to be bilateral and similar across cases. We describe a 27-year-old woman whose chronic amnesia and cerebral lesions after viral encephalitis indicate a different pattern. Two features distinguish her presentation: (1) markedly asymmetric lesions extensively involving the right temporal lobe but sparing almost all of the same structures on the left and (2) severe compromise of nonverbal learning and a nonverbal retrograde amnesia in contrast to disproportionately small impairments of verbal learning and retention. The findings suggest that encephalitis patients cannot be treated as a homogeneous group and that detailed analysis of variability in their anatomic lesions may be an important explanatory factor in neural accounts of these severe human amnesias. © 1993 Academic Press, Inc.

INTRODUCTION

Herpes simplex encephalitis has been associated with profound anterograde and retrograde amnesia which affects virtually all sensory modalities and material-specific forms of learning (Rose & Symonds, 1960; Barbizet, Duizabo, & Poirer, 1978; Damasio, Eslinger, Damasio, Van Hoesen, & Cornell, 1985). These "global" amnesias have been correlated most consistently with anterior temporal lobe damage which often extends to the orbital and mesial frontal lobes and to the insula. The

We thank Tricia Johnson for preparation of the manuscript. Supported by NINDS Program Grants NS 19632 and NS 26985. Address reprint requests to Paul J. Eslinger, Ph.D., Division of Neurology, The Milton S. Hershey Medical Center, 500 University Drive, Hershey, PA 17033.

distribution of cerebral lesions in this disease has been thought to be similar across cases, with bilateral and symmetric involvement of limbic and paralimbic system structures. However, early postmortem studies frequently noted highly asymmetric cerebral lesions (Drachman & Adams, 1962; Hierons, Janota, & Corsellis, 1978). In patients who survived the encephalitis and were in stable, chronic phases of recovery, it was difficult to establish at that time the importance of right vs. left lesion distribution because of the limited availability of standardized and experimental neuropsychological studies and informative *in vivo* neuroimaging studies. We describe a patient whose neuroimaging studies and profound amnesia after viral encephalitis bear upon anatomic and cognitive issues. Two aspects of her presentation brought her to special attention: (1) a remarkable asymmetry of cerebral lesions, with near-complete damage of the right temporal lobe, but minimal involvement of the left mesial temporal lobe; and (2) a prominent nonverbal amnesia in the retrograde as well as anterograde compartments of memory. The findings support a powerful dissociation between right and left temporal lobe processing in retrograde as well as anterograde memory and indicate that herpes simplex encephalitis may lead to different forms of amnesia and varied patterns of limbic system lesions.

CASE DESCRIPTION

Clinical Course

The patient, known as LD, was 17 years old at the time of her encephalitis. Past medical and psychological histories were unremarkable. Her birth and development milestones were entirely normal. Throughout school she maintained average grades and graduated from high school at 17 years of age. She was described by family as quite independent and socially active, owning her own car and working as a bookkeeper/receptionist after graduation.

While on a brief domestic vacation in 1981, she began to experience "flu" symptoms which steadily worsened. The next day she returned home quite weak, dizzy, and nauseous. At a local hospital, she was initially diagnosed with viral meningitis and treated conservatively. Over the next few days, she became agitated, irritable, and belligerent, complaining of photophobia and severe headache. Upon transfer to another hospital, she was diagnosed with herpes simplex encephalitis. At this time (one week after initial symptoms), she became less responsive and developed seizures as well as right hemiparesis.

During the ensuing weeks, the patient spoke only in short sentences which were often incoherent and incomplete. She demonstrated no recognition of her name, personal history, circumstances, or family members. Her visual perception was noted to be very poor, as she could describe

only the outline of objects. She appeared unable to recognize food, losing 30 pounds, and one day attempted to eat a plastic fork. Hallucinations and random, purposeless activity were frequent. She remained in the hospital for 5 months. At discharge, she ambulated normally, could speak, see and hear normally, but was unable to smell or taste. Upon arriving home, she evidenced no recognition of the house or her personal effects. She gradually came to recognize a few family members, particularly her mother and brother, but could not recognize her boyfriend of 3 years. She entered a rehabilitation center and received cognitive and memory retraining for 3 months. Since that time, she has received continuing neuropsychological studies.

Neuroimaging Studies

Neuroimaging studies were completed on the patient 3 years after onset of her encephalitis. Procedures included CT scan without contrast and MR scan with T₁- and T₂-weighted images. Anatomical analysis of these images was performed with the method of Damasio and Damasio (1989) by an investigator blinded to the identification and clinical neuropsychological history of the patient. CT scan images are presented in Fig. 1, T₁-weighted MR images in Fig. 2, and depiction of the lesion on our appropriate template system in Fig. 3. These images demonstrate a large, well-demarcated area of abnormal signal in the *right* hemisphere. With the exception of the posterior sector of the superior temporal gyrus (areas 41, 42, and posterior 22), the entire right temporal lobe is damaged. The lesion encompasses: (a) the temporal pole; (b) the medial temporal region, including the extent of the parahippocampal gyrus and hippocampus proper; (c) the anterior half of the superior temporal gyrus; and (d) all of the middle and inferior temporal gyri. The insula is also damaged as the lesion extends further rostrally and caudally. The rostral division reaches to the most anterior and inferior portions of the cingulate gyrus (part of area 24), as well as posterior ventromedial frontal lobe including the basal forebrain and gyrus rectus. The posterior and superior divisions of the lesion extend into the inferior parietal lobule, compromising part of the supramarginal gyrus (area 40) and most of the angular gyrus (area 39), and even into lateral occipital lobe (area 19).

In the left hemisphere there is comparatively little damage. The lesion is limited to the region of the collateral sulcus, to the inferior portion of the insula, and minimally to the posterior ventromedial sector of the frontal lobe.

Neuropsychological Studies

We present an integrated summary of the patient's examination findings based on our studies as well as separate, later analysis by O'Connor,

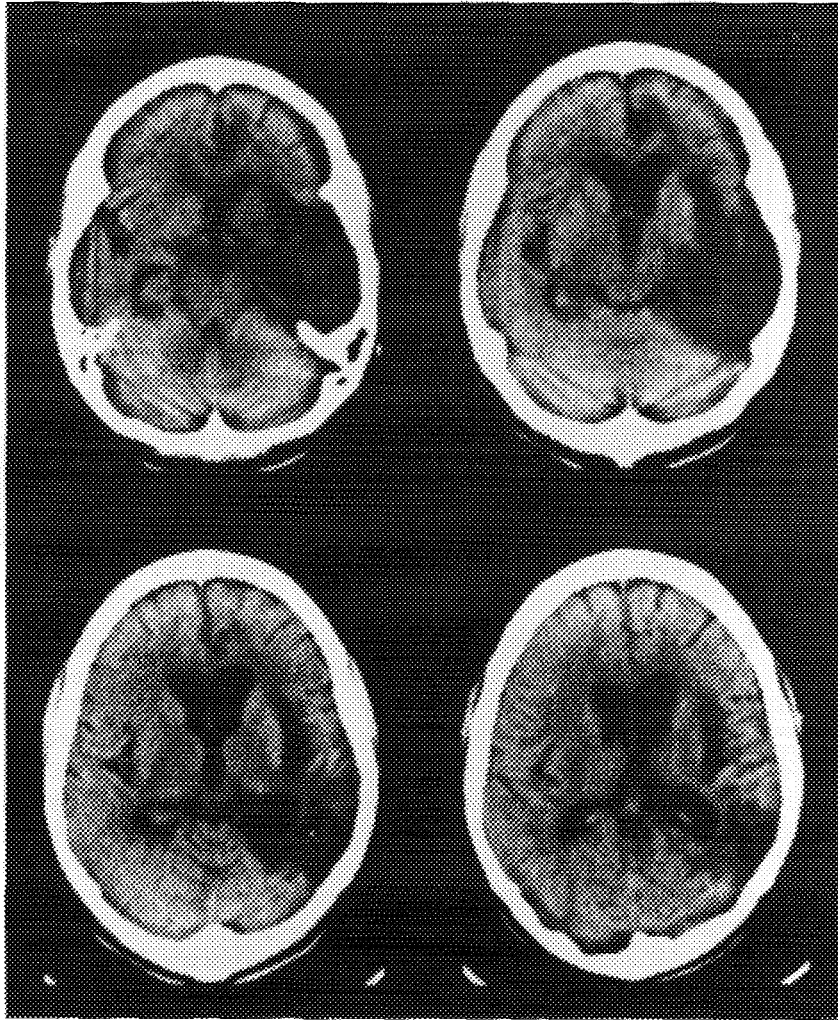


FIG. 1. CT scan without contrast of patient LD in the chronic phase of her recovery, 3 years after onset. In this series, the right hemisphere is on the right.

Butters, Miliotis, Eslinger and Cermak (1992). The two phases of examination showed a high degree of consistency.

In the chronic phase of recovery, the patient's measured intellect has remained stable in the low average range (WAIS-R Full Scale IQ = 83, 12th percentile), with the visually based performance IQ consistently lower (Performance IQ = 81, 10th percentile; Verbal IQ = 87, 20th percentile).

Assessment of audition and language did not reveal any significant abnormalities. Screening audiometry, sound recognition, and dichotic lis-

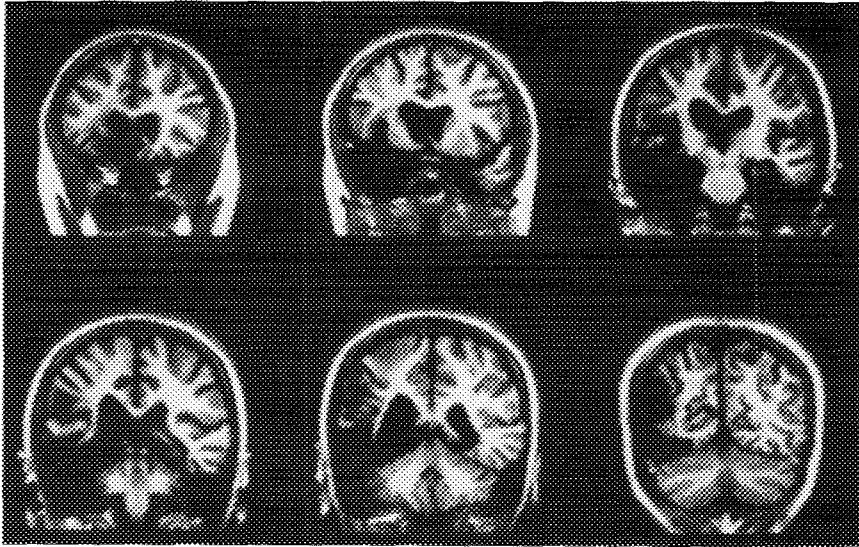


FIG. 2. Patient LD's T_1 -weighted MR scan in coronal cuts taken 3 years after onset. In this series, the right hemisphere is on the left.

tening (Damasio & Damasio, 1979) were all within the normal range. Speech was fluent, nonparaphasic, and well-articulated. Assessment of language with the Multilingual Aphasia Examination (Benton, 1976) revealed normal levels of visual naming, digit repetition, aural comprehension, spelling, controlled oral word association, and writing. Reading of sentences and paragraphs from the Boston Diagnostic Aphasia Examination (Goodglass & Kaplan, 1983) was normal. Grade achievement levels (WRAT-R; Jastak & Wilkinson, 1984) in spelling and oral word reading were compatible with her academic background.

Examination of visual processing indicated intact visual fields to confrontation, visual acuity, color perception, and geometric form perception. In addition, object recognition and usage were always accurate and prompt, and there was no evidence of visual neglect or extinction. However, several complex visual perceptual and parietal lobe functions were impaired. Visual spatial perception, measured with the Judgment of Line Orientation Test (Benton, Hamsher, Varney, & Spreen, 1983), was in the borderline range (9th percentile). Prominent disturbances were evident, though, in visual pattern perception such as Benton's (1983) discrimination of unfamiliar faces (4th percentile), Mooney and Ferguson's (1951) visual closure task (70% correct: impaired), and Hooper's (1983) task of visual synthesis (high probability of impairment). O'Connor *et al.* (1992) report that the patient also had some difficulty recognizing visually complex items of the Boston Naming Test, particularly specific members of a class (e.g., 4-legged animals) and very low frequency items (e.g., abacus).

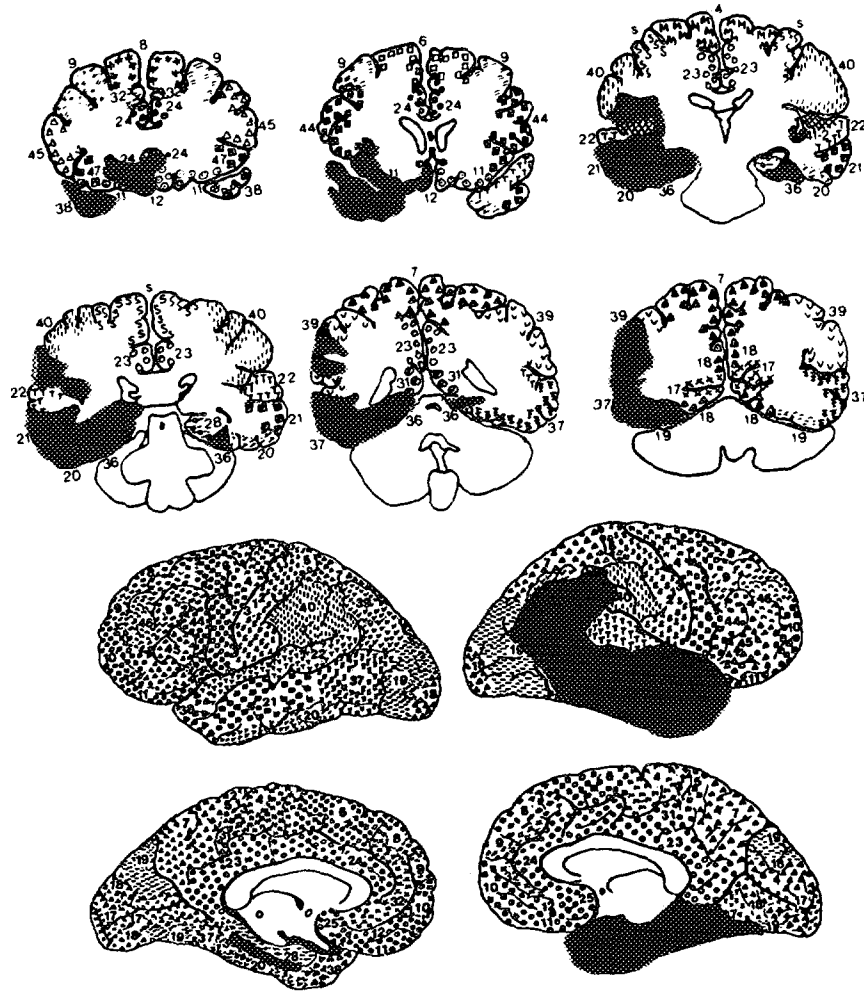


FIG. 3. Depiction of the lesion as seen in Fig. 2 on the appropriate coronal templates. There was extensive right temporal lobe damage and involvement of inferior-medial frontal lobe, insula and portions of the parietal lobe and parietal-occipital junction. In the left hemisphere there is very limited, selective damage to the region of the collateral sulcus, anterior insula, and posterior ventromedial sector of the frontal lobe.

Constructional praxis varied with the complexity and structure of the task. Copying simple geometric forms was intact. 3-D block construction, under highly structured conditions, was intact (Benton *et al.*, 1983). Copy of the Rey-Osterrieth Complex Figure (Rey, 1941; Osterrieth, 1944) was impaired (<10th percentile) and characterized by spatial distortions and a disorganized approach, although all elements were eventually drawn.

Spatial orientation was very impaired in any type of geographic orientation or geographic knowledge task. She could neither construct nor recognize the outline of the United States. She could not localize prominent cities and states, including those in her local region. Right-left discrimination was intact on herself, but on confrontation testing, she performed normally only if she could physically turn herself around.

Tests of frontal lobe functions indicated that the patient could initiate and generate a normal range of appropriate responses in divergent production tasks such as verbal associative fluency (77th percentile) and category fluency. In contrast to this normal range of spontaneous flexibility, reactive flexibility was more problematic. Although she could abstract and eventually achieve six categories on the Wisconsin Card Sorting Test (Heaton, 1981), the number of perseverative errors and perseverative responses were 2 standard deviations above the mean of normal subjects less than 40 years of age. Performance on Trails B was also significantly impaired. Later testing by O'Connor *et al.* (1992) indicated improved performance on these tasks, suggesting that the patient has the capacity to learn from certain experiences. Overall, the patient was consistently disorganized in her approach to unstructured tasks and impulsive in her responses, including cognitive estimation responses. She benefited from greater structure in laboratory, personal, and work-related tasks.

Studies of Learning and Memory

Measures of verbal and visual attention span and of concentration were consistently in the average to high-average range. The most striking aspect of her profile was the severely impaired visual-nonverbal learning. Reproduction of geometric designs (Benton, 1974) was consistently poor (3 correct, 13 errors; expect 7 correct, 5 errors). Error types on this test were predominantly spatial (i.e., misplacements and rotations) and pattern distortions. When encouraged to actively mediate an equivalent form in verbal terms, the patient improved her performance slightly (4 correct, 9 errors) but remained in the impaired range. Figural memory as well as visual paired associates were significantly impaired, resulting in a WMS-R Visual Memory index of 70 (Wechsler, 1987). Later testing by O'Connor *et al.* (1992) indicated a Visual index of 72. Retention of the Rey-Osterrieth Complex Figure was difficult (8/36: <10th percentile) and much out of proportion to her moderate difficulty (26/36) in copying the stimulus figure. Her retention of the design across 2 days revealed a stable but deficient pattern of recalling only the outline of the figure and the "straight lines and a little circle with three dots" as she described it. Clinically, the patient demonstrated a profound anterograde prosopagnosia (Tranel & Damasio, 1985) and nonverbal amnesia. She was unable to

learn any spatial information, except when it could be entirely mediated in verbal terms. She follows her route to work only by memorization of specific and unchanging directions that utilize obvious and highly verbalizable landmarks. If the route is spatially rearranged by detour, she must call home to obtain new verbal directions. She can retain the location of her car in a parking lot only by verbal markers. If she loses this information, she must visit each car to examine the license plate. She has learned locations of bathrooms and work areas strictly in verbal terms.

In contrast, the patient processed and retained new verbal information at normal to near-normal levels. This was especially true for free recall (Logical Memory, 50th percentile) and digit sequence learning (45th percentile) paradigms. Similar patterns were evident for the Rey and California auditory verbal learning tasks (Rey, 1964; Delis, Kramer, Kaplan, & Ober, 1987), where her learning curve improved across trials at an average level. Despite a 36% reduction in delayed free recall, her verbal recognition memory was at a normal level and commensurate with level of learning. Verbal paired associate learning was more difficult for her, particularly learning and recall of the novel word pairs that had no semantic linkage. Overall measure of verbal learning and retention placed her in the low average range (WMS-R Verbal index = 83). Later testing by O'Connor *et al.* (1992) revealed a WMS-R Verbal index of 91. Encoding of consonant trigrams, release from proactive interference, and levels of processing all showed a normal pattern. She also demonstrated a priming effect with word stem completions. Clinically, the patient had disproportionately fewer deficits in verbal learning and memory, both in laboratory and naturalistic settings.

Motor learning, assessed through pursuit rotor and mirror-tracing procedures, revealed a normal learning curve and full retention over 3 days.

Retrograde memory was probed with standardized measures of recognition of famous faces and recall of famous events from the decade prior to her encephalitis. She benefited from verbal cuing in these circumstances, but showed a significant impairment (Famous Faces: 6/37, 15/37 with cues; Famous Events: 5/29, 9/29 with cues). Autobiographical details were also examined, with factual and episodic information provided by her mother serving as criterion. With the exception of recognizing her mother and brother, her recall was composed of verbal facts that were devoid of any personal awareness or recollection of those experiences. Hence, while she could give the name of her grade school and high school, she could recall no specific episodes, impressions or emotional experiences from those years. Names of teachers and classmates were limited to those she had been retaught from her yearbooks. She thought she had been told she visited Florida and California (which she had), but did not know why, when, or specifically where. She could neither recall nor consistently recognize any jobs prior to her illness, any

school-related activities, or any friends. This pattern of findings has been recently confirmed by O'Connor *et al.* (1992), who report that in free association, autobiographical, and past public events tests, the patient shows profound retrograde amnesia in comparison to her brother, who is 3 years younger and of similar educational background. With the exception of shreds of verbal factual knowledge (both personal and public domains), the patient has been unable to generate specific information emanating from either nonverbal or verbal stores of memory.

DISCUSSION

LD's neurologic presentation and course were as expected for herpes simplex encephalitis. After initial flu-like symptoms, there was progressive obtundation, seizures, and unresponsiveness. Her neuroimaging studies were also characteristic, revealing limbic system damage, although in a strikingly asymmetric manner. The cognitive consequences included a predominant nonverbal amnesia, affecting retrograde as well as anterograde memory. Both memory and anatomic features indicate a markedly different profile from global amnesias and other well-studied cases of herpes simplex encephalitis, with the following characteristics.

Retrograde Memory

The patient's retrograde amnesia affects multiple domains of knowledge. Most strikingly, there is pervasive loss of autobiographic memory, which became evident very early in her illness and has remained a stable feature. She has come to recognize family members and a few items from standardized tests of public events and faces prior to onset of her illness, but her accuracy remains well below normal. While she can offer verbal descriptions that structure her past (such as birthplace, schools, family pets), these facts appear to be isolated from any broader knowledge base that permits a sense of past personal experience over time and space. She particularly offers no recollection of her recent or remote past from any nonverbal experiences (e.g., in visual, tactile, auditory, temporal, spatial, or emotional domains) and frequently explains that she knows of her past only from what she has been told. Unlike the postencephalitic patient Boswell (Damasio *et al.*, 1985), who demonstrates a more extensive retrograde amnesia and sustained large, bilateral limbic system lesions, this patient has been able to retain parts of her personal history and public event knowledge (supplemental by intensive rehabilitation). However, this knowledge appears to be available to her only as verbal facts. Considering the highly asymmetric pattern of cerebral damage, the findings would suggest that the right temporal lobe (possibly in combination with the basal forebrain and insula) is a critical neural substrate for

retrograde memory. The highly limited damage to the left temporal region, actually sparing the hippocampus, amygdala and most of the parahippocampal gyrus, could not adequately account for this extensive impairment, although some contribution may be possible. Furthermore, this pattern of damage clearly affected not only past visual–nonverbal experiences and knowledge, but also specific verbal linkages in the domain of personal and public events knowledge, although to a lesser extent. This raises the possibility of some degree of critical *interdependence* of right and left temporal lobe processing in autobiographical and contextual aspects of retrograde memory.

In many other domains of past knowledge, the patient appears to be unaffected. She readily recognizes commonly occurring objects, features, and actions, despite the perceptual changes we detected. Her retrograde memory is most accurate when recognition requires the least amount of retrieval of *unique visual details*. For instance, while she recognizes the generic class of dogs, she fails to recognize her dog of many years as well as his particular breed. This requires retrieval of varying degrees of unique features that differentiate among members of a category, such as different animals whose shapes are ambiguous (see Damasio, 1990; Damasio, Damasio, Tranel, & Brandt, 1990). Thus, her retrograde amnesia encompasses not only items usually classified under episodic memory (Tulving, 1983), but also certain items that belong to a nonepisodic knowledge system that has a strong visual or other nonverbal basis not bound by time, space, or specific personal experience. In this regard, the patient's retrograde amnesia is more extensive than that associated with medial and polar temporal lobe damage. It is possible that the additional lesion to right temporal cortex, and possibly inferior parietal lobule, led to this more extensive retrieval impairment in the visual–nonverbal domain.

Anterograde Learning and Memory

A strong dissociation was evident between nonverbal and verbal learning. Prior studies of right medial temporal lobe surgery for intractable epilepsy have documented nonverbal learning impairments in the laboratory (e.g., Kimura, 1963; Milner, 1968; Smith & Milner, 1981). The patient's defect in this area is especially severe and appears to be related to destruction of the entire right medial temporal region. On a daily basis, she is completely unable to learn and retain new nonverbal information, despite offering accurate descriptions of her immediate environment. New verbal knowledge, however, is consistently evident and lexical interrelationships appear to operate normally. Although she navigates safely in city traffic, the patient requires thorough verbal mediation of landmarks and directions in order to reach her destination. Similar to her

retrograde memory, newly acquired verbal descriptors appear to have no connection to a broader, possibly nonverbal knowledge base.

The impairment of nonverbal learning, despite its severity, has not precluded some aspects of learning. In spite of her inability to recognize new faces consciously (e.g., her examiners), the patient has generated consistent and significantly larger skin conductance responses to certain new faces (Tranel & Damasio, 1985). The results indicate that covert learning can take place. However, this processing appears to be unavailable to conscious experience, and, as far as can be determined, is not connected to verbal knowledge.

Anatomic Comparisons

The pattern of cerebral damage in the patient contrasts markedly with that seen in the postencephalitic patients Boswell (Damasio *et al.*, 1985) and SS (Eslinger & Cermak, 1988). The latter two patients suffered more extensive and symmetric limbic system lesions and more pervasive amnesia, particularly in the anterograde sphere. Although this pattern is considered typical of herpes simplex encephalitis, previous postmortem studies have described highly asymmetric lesions in 12 of 19 cases (Haymaker, 1949; Drachman & Adams, 1962; Hierons *et al.*, 1978). Recent report of *in vivo* neuroimaging in a series of postencephalitic patients also found a high frequency of asymmetric limbic system lesions (Eslinger, Alexander, Cermak & Grattan, 1990).

Establishing the anatomic details of viral encephalitic lesions provides neurobiologic data that are critical to understanding amnesia and the neural substrate of memory. As the results of this study illustrate, the anatomic and cognitive sequelae of herpes simplex encephalitis may vary dramatically, and patients with this diagnosis cannot be assumed to have homogenous syndromes. As an example, Warrington and McCarthy (1988) described a postencephalitic patient who benefited significantly from verbal cues in recalling past famous faces and names. By CT scan report, the patient's cerebral lesion was highly asymmetric, with much greater involvement of the right than the left temporal lobe. However, the possible implications of this anatomic asymmetry favoring the left temporal lobe was not considered in analysis of the cognitive dissociations. Although the specific tasks varied in our patient, she, too, showed a beneficial effect of verbal cuing, improving her recognition of past famous faces from 16% (without cues) to 40% (with cues), and past events from 17% (without cues) to 31% (with cues). Hence, two patients with sparing of left temporal lobe structures show a beneficial effect of verbal cuing on retrograde memory. Patient Boswell (Damasio *et al.*, 1985), by contrast, suffered extensive damage to both temporal lobes and does not show any benefit from verbal cues in tasks of past facial and event

recognition. The occasional famous name that he can recognize or generate from first name and surname cues surfaces without regard to accompanying facial pictures or context, suggesting that they represent simply over learned verbal associations. Therefore, the particular characteristics of amnesia may not be generalizable from diagnostic information alone, but rather require correlation to neuroanatomic data.

In conclusion, the findings in this case indicate that different profiles of amnesia can result from herpes simplex encephalitis and that powerful dissociations in learning and memory may be related to cerebral lesions that vary by intra- and interhemispheric location. Therefore, it is critical that neurobiologic formulations of amnesias consider anatomic results of individual cases. Scientific analysis of these variations in lesion anatomy and cognitive deficit may, in fact, advance our understanding of the neural substrate of memory.

REFERENCES

- Barbizet, J., Duizabo, P. H., & Poirer, J. 1978. Etude anatomo-clinique 'un cas d'encephalite amnesiante d'origine herpetique. *Revue Neurologique*, **134**, 241-253.
- Benton, A. L. 1974. *The visual retention test*, 4th ed. New York: The Psychological Corp.
- Benton, A. L. 1976. *The multilingual aphasia examination*. Iowa City, IA: Department of Neurology.
- Benton, A. L., Hamsher, K. des., Varney, N., & Spreen, O. 1983. *Contributions to neuropsychological assessment*. New York: Oxford Univ. Press.
- Damasio, A. R. 1990. Category-related recognition defects as a clue to the neural substrates of knowledge. *Trends in Neurosciences*, **13**, 95-98.
- Damasio, A. R., Damasio, H., Tranel, D., & Brandt, J. P. 1990. The neural regionalization of knowledge access devices: Preliminary evidence. *Symposia on Quantitative Biology*, **55**.
- Damasio, A. R., Eslinger, P., Damasio, H., Van Hoesen, G. W., & Cornell, S. 1985. Multimodal amnesic syndrome following bilateral temporal and frontal damage: The case of patient DRB. *Archives of Neurology*, **42**, 252-259.
- Damasio, H., & Damasio, A. R. 1979. "Paradoxical" ear extinction in dichotic listening: Possible anatomic significance. *Neurology*, **19**, 644-459.
- Damasio, H., & Damasio, A. R. 1989. *Lesion localization in neuropsychology*. New York: Oxford Univ. Press.
- Delis, D. C., Kramer, J. H., Kaplan, E., & Ober, B. A. 1987. *California Verbal Learning Test*. Research ed. New York: The Psychological Corp.
- Drachman, D. A., & Adams, R. D. 1962. Herpes simplex and acute inclusion-body encephalitis. *Archives of Neurology*, **7**, 45-63.
- Eslinger, P. J., & Cermak, L. 1988. Anatomic correlates of retrograde amnesia. *Society for Neuroscience Abstracts*, **14**, 1289.
- Eslinger, P. J., Alexander, M. P., Cermak, L. S., & Grattan, L. M. 1990. Different profiles of human amnesia and cerebral damage associated with encephalitis. *Society for Neuroscience Abstracts*, **16**, 286.
- Goodglass, H., & Kaplan, E. 1983. *The assessment of aphasia and related disorders*. 2nd ed. Philadelphia, PA: Lea & Febiger.
- Haymaker, W. 1949. Herpes simplex encephalitis in man with a report of three cases. *Journal of Neuropathology and Experimental Neurology*, **8**, 132-154.

- Heaton, R. K. 1981. *Wisconsin Card Sorting Test. Manual*. Odessa, Fla: Psychological Assessment Resources.
- Hierons, R., Janota, I., & Corsellis, J. A. N. 1978. The late effects of necrotizing encephalitis of the temporal lobes and limbic areas: A clinicopathological study of 10 cases. *Psychological Medicine*, **8**, 21-42.
- Hooper, H. E. 1983. *Hooper Visual Organization Test (VOT). Manual*. Los Angeles, CA: Western Psychological Services.
- Jastak, S., & Wilkinson, G. S. 1984. *Wide Range Achievement Test—Revised. Manual*. Wilmington, DE: Jastak Associates.
- Kimura, D. 1963. Right temporal lobe damage. *Archives of Neurology*, **8**, 264-271.
- Milner, B. 1968. Visual recognition and recall after right temporal lobe excision in man. *Neuropsychologia*, **6**, 191-209.
- Mooney, C. M., & Ferguson, G. A. 1951. A new closure test. *Canadian Journal of Psychology*, **5**, 129-133.
- O'Connor, M., Butters, N., Miliotis, P., Eslinger, P. J., & Cermak, L. 1992. The dissociation of anterograde and retrograde amnesia in a patient with herpes encephalitis. *Journal of Clinical and Experimental Neuropsychology*, **14**, 159-178.
- Osterrieth, P. A. 1944. Le test de copie d'une figure complexe. *Arch. Psychol.*, **30**, 206-356.
- Rey, A. 1941. L'examen clinique in psychologie dans les case d'encephalopathie traumatique. *Arch. Psychol.*, **28**, 286-340.
- Rey, A. 1964. *L'examen Clinique in Psychologie*. Paris: Presses Univ. de France.
- Rose, F. C., & Symonds, C. P. 1960. Persistent memory defect following encephalitis. *Brain*, **83**, 195-212.
- Smith, M. L., & Milner, B. 1981. The role of the right hippocampus in the recall of spatial location. *Neuropsychologia*, **19**, 781-793.
- Tranel, D., & Damasio, A. R. 1985. Knowledge without awareness: An autonomic index of facial recognition by prosopagnosics. *Science*, **228**, 1453-1454.
- Tulving, E. 1983. *Elements of episodic memory*. New York: Oxford Univ. Press.
- Warrington, E. K., & McCarthy, R. A. 1988. The fractionation of retrograde amnesia. *Brain and Cognition*, **7**, 184-200.
- Wechsler, D. 1987. *Wechsler Memory Scale—Revised. Manual*. New York: The Psychological Corp.