

Spontaneous Midbrain Hemorrhage: Report of Seven New Cases

Michael J. Link, M.D., J. D. Bartleson, M.D., Glenn Forbes, M.D.,
and Fredric B. Meyer, M.D.

Departments of Neurosurgery, Neurology, and Diagnostic Radiology, Mayo Clinic and Mayo Foundation,
Rochester, Minnesota

Link MJ, Bartleson JD, Forbes G, Meyer FB. Spontaneous midbrain hemorrhage: report of seven new cases. *Surg Neurol* 1993;39:58-65.

Spontaneous midbrain hemorrhage is a unique brain-stem vascular lesion. Sixty-six cases have been reported in the literature, to which we add seven.

Of the total of 73 patients reviewed, most presented acutely (66%), but subacute (22%) and chronic onsets (12%) also occurred. Neuro-ophthalmologic abnormalities were found in 88% of patients. Some alteration of consciousness and headache occurred in most patients. Hemiparesis, hemisensory loss, and ataxia were less frequent manifestations.

Vascular malformations were suspected or proved in 37% of patients, hypertension was present in 21%, and a bleeding diathesis was noted in 5%. No underlying cause was apparent in 37%.

Most patients improved with supportive care only. At follow-up, 23% of patients had no neurologic deficits. In 51% of patients, minor neurologic deficits persisted, related chiefly to cranial nerves III and IV. Moderate deficits persisted in 16% of patients, and 5% of patients died.

KEY WORDS: Midbrain; Hemorrhage; Arteriovenous malformation; Uppgaze paresis

Primary midbrain hemorrhage is a rare clinical event. An extensive search of the literature through 1990 for cases of spontaneous, isolated, nontraumatic midbrain hemorrhage revealed 48 publications reporting 66 such patients [1,2,4-10,12-16,18,20-25,27-30,36-39,41,43-49,51-58,60,62,63]. The Mayo Clinic experience has been seven patients with spontaneous midbrain hemorrhage (SMH) between 1976 and 1990. The cases from the literature and those from the Mayo Clinic records were reviewed to help determine the incidence, etiology, clinical presentation, methods of diagnosis, possible treatment options, and prognosis for SMH.

Address reprint requests to: J. D. Bartleson, M.D., Mayo Clinic, 200 First Street SW, Rochester, Minnesota 55905.

Received April 20, 1992; accepted May 13, 1992.

Methods

The medical records of all Mayo Clinic patients with the diagnosis of intracranial hemorrhage between January 1, 1976, and December 31, 1990 were reviewed (i.e., since the widespread availability of computed tomography). Included were patients who had a spontaneous, nontraumatic, intra-axial hemorrhage that affected and was largely confined to the midbrain. Cases were not excluded if obstructive hydrocephalus or moderate intraventricular hemorrhage was present. Computed tomographic (CT) and magnetic resonance imaging (MRI) scans were reviewed by one of the authors (G.F.) to verify the location of the bleeding.

Results

Seven Newly Described Patients

Case 1. A 75-year-old man was found unconscious with a fixed, dilated right pupil. He had a history of hypertension and was taking warfarin because of a history of transient ischemic attacks. His prothrombin time was prolonged (57 s; control 10.9-12.8 s). A CT scan showed a large hemorrhage affecting the entire midbrain with some blood in the third ventricle and obstructive hydrocephalus. His condition deteriorated, and he died 36 hours after onset.

Case 2. A 55-year-old man presented with a 3-month history of progressive left limb weakness with at least one episode of sudden worsening. There was a history of hypertension. A CT scan showed a 1-cm hemorrhage in the right cerebral peduncle. An angiogram was normal. His deficit stabilized.

Case 3. A 51-year-old woman noted the sudden onset of dysequilibrium followed by right-sided numbness, drowsiness, blurred vision, bilateral tinnitus, and some headache. On examination, she was drowsy, with bilateral ptosis and speech and gait ataxia. There was a history of migraine. CT and MRI scans showed a 1-cm hemorrhage in the left midbrain tectum, with mild hydrocephalus.

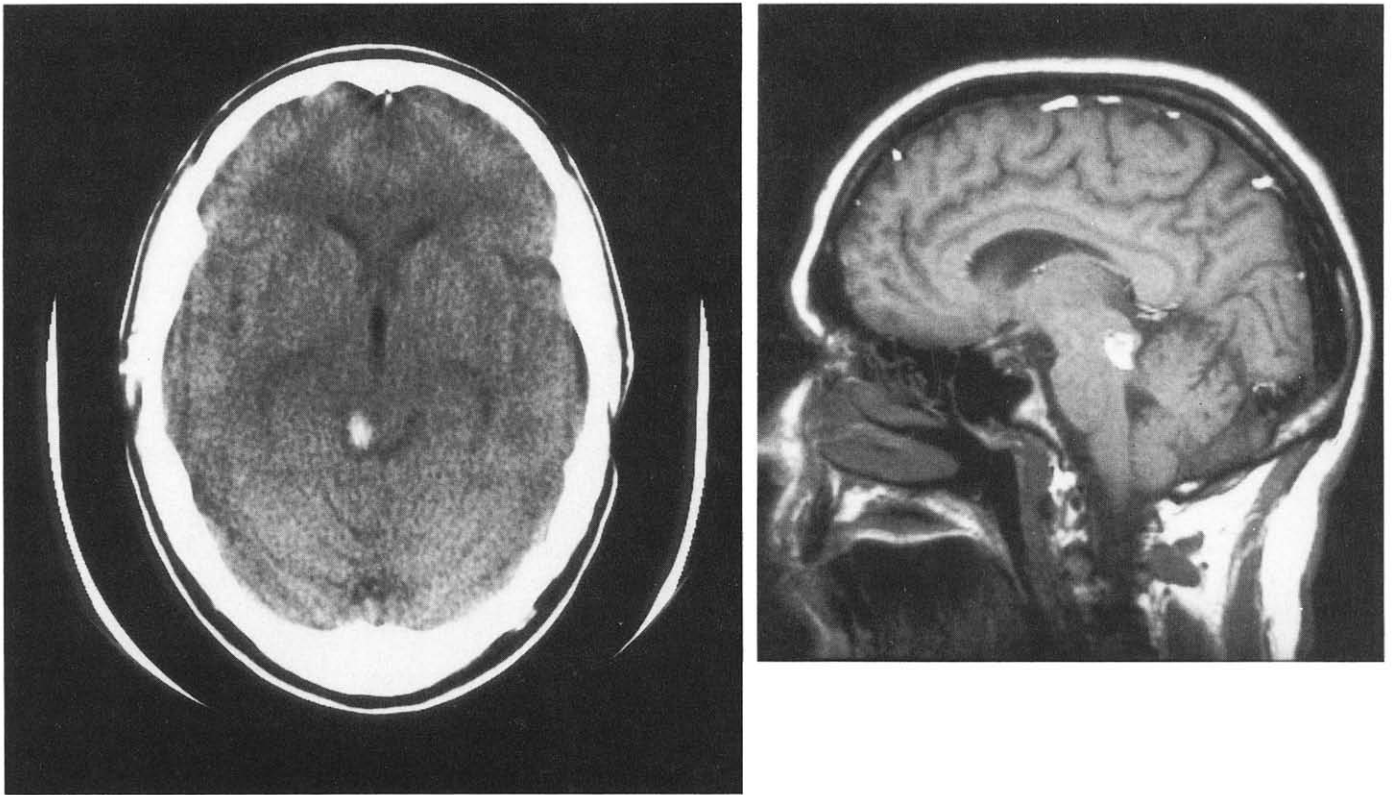


Figure 1. Case 4. (Left) Unenhanced CT scan on day of hemorrhage, showing hyperdense zone representing hemorrhage in right side of midbrain tectum. (Right) MRI scan 6 days later, showing hyperintense signal on short-TE/short-TR sequence within the inferior colliculus, consistent with a subacute or chronic component of hemorrhage.

lus. An angiogram showed an arteriovenous malformation in the collicular plate. She underwent surgical exploration elsewhere, but the malformation was unresectable. She then underwent gamma knife irradiation. One year later, persistent diplopia developed. Three years after her bleed she had mild memory loss, bilateral ptosis, nystagmus, paresis of both medial recti and left superior rectus muscles, and moderate speech and mild gait ataxia.

Case 4. A 44-year-old woman noted the sudden onset of headache, dizziness, bilateral tinnitus, and transient drowsiness. On examination, she was noted to have mild left lower facial weakness, mild left hemihypalgesia, and a subtle left fourth nerve paresis. CT and MRI scans showed a 0.5-cm hemorrhage in the right midbrain tectum (Figure 1). An angiogram was normal. Her signs and symptoms completely resolved within 3 months.

Case 5. A 71-year-old man noted the sudden onset of transient unconsciousness followed by headache and

confusion (which cleared), left limb numbness, and diplopia. Examination showed mild gait ataxia and a left fourth nerve paresis. He had been taking 5 grains of aspirin a day. A CT scan showed a 0.5-cm hemorrhage in the right midbrain tectum. An angiogram was normal. A subtle left fourth nerve paresis persisted.

Case 6. Lethargy, bilateral ptosis, and left hemiparesis developed in an 87-year-old man over 24 hours on the day after a left axillary artery thrombectomy and heparinization. Examination showed stupor, Cheyne-Stokes respirations, bilateral third nerve paresis (greater on the right side), and left hemiparesis. There was a history of diabetes mellitus, chronic atrial fibrillation, and remote stroke. A CT scan showed a 1.25-cm hemorrhage in the right cerebral peduncle (Figure 2). He was improving neurologically when he died in a nursing home of medical complications 4 weeks after the hemorrhage.

Case 7. Ataxia, headache, and lethargy developed in a 30-year-old woman during her seventh month of pregnancy. During her ninth month, these symptoms increased and diplopia developed. After cesarean section, her condition worsened again. Examination showed stupor, bilateral third nerve paresis (greater on the left side), and diffuse hyperreflexia. At age 14 years, she had had a right hemiparesis, ataxia, and diplopia and was

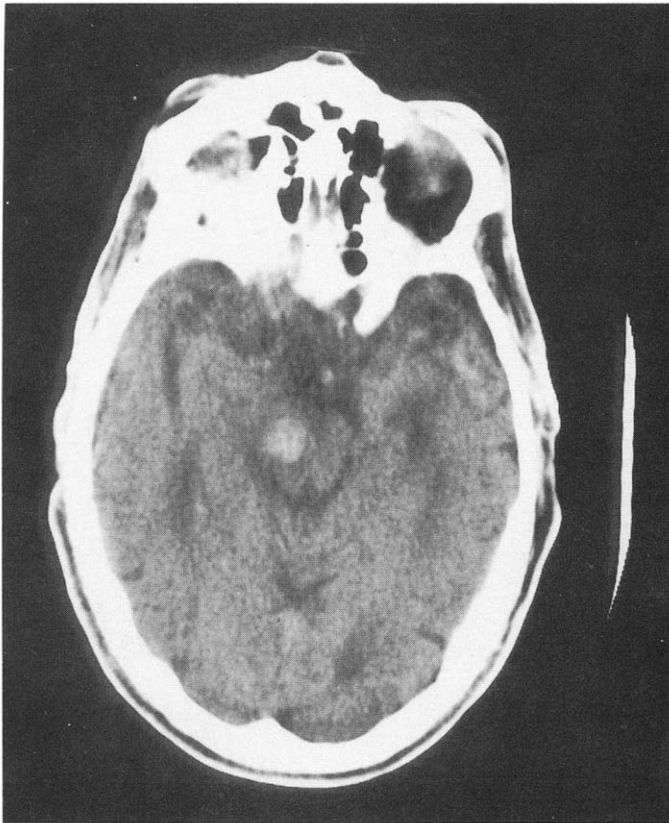

Figure 2. Case 2. Unenhanced CT scan, showing 1.25-cm hyperdense zone representing hemorrhage in right cerebral peduncle.

found to have an enlarged brain stem. She was treated with a shunt and irradiation at that time. CT and MRI scans obtained during her current episode showed multiple angiographically occult vascular malformations with a 3-cm hemorrhage in the central midbrain. A cerebral angiogram was negative. She slowly and incompletely improved.

Literature Cases

The 66 cases in the literature are summarized and compared to our seven patients in Tables 1 through 6.

Discussion

Incidence

The true incidence of isolated SMH is difficult to determine. The frequency of SMH has been variously related to the number of intracerebral hemorrhages, posterior fossa hemorrhages, and brain-stem hemorrhages. Thus, comparison of reports is difficult, if not impossible. The majority of brain-stem hemorrhages, especially those associated with hypertension, are pontine. There were no cases of midbrain hemorrhage in Freytag's anatomopathologic series of 393 patients who died from hyper-

tensive intraparenchymal hemorrhage [17]. Dinsdale [11] also noted no midbrain lesions among 510 intracerebral hemorrhages in 19,000 autopsies over 20 years, predominantly in a hypertensive population. Roig et al [43] reported that of 277 patients in whom the diagnosis of intracerebral hemorrhage was made by clinical examination and CT, three had localized midbrain hemorrhages. Mangiardi and Epstein [34] collected from the literature 51 cases of brain-stem hematomas that underwent neurosurgical intervention and found that the site was in the midbrain in five.

The medical records of approximately 1750 patients with the diagnosis of intracranial hemorrhage seen at the Mayo Clinic were reviewed, and seven with SMH as defined above were discovered. Patients with a history of trauma or a primary infarction with secondary hemorrhage were excluded. Not all patients with the diagnosis of intracranial hemorrhage underwent an appropriate imaging procedure or autopsy examination. Thus, we estimate that the frequency of SMH is between 0.5% and 1.0% of all spontaneous, primary intracranial hemorrhages seen at our institution.

Etiology

A clear cause for SMH can be difficult to identify. Hemorrhage secondary to a vascular malformation (VM) is the most frequently cited cause. Such malformations include arteriovenous malformations (AVMs), cavernous malformations, venous malformations, and telangiectasias. AVMs are visible on angiography; venous malformations can be seen in the venous phase only. Cavernous malformations and telangiectasias are not usually seen on angiography [50]. Cryptic or thrombosed malformations may be detected with either CT or MRI, and indeed, a higher level of detection of such incidental lesions can now be expected, with the more widespread use of MRI.

Of the cases reported in the literature, 10 patients (15%) had small midbrain VMs detected at operation, by angiography, or at autopsy. Fifteen patients (23%) were suspected to have VMs by the reporting authors, but no abnormal vessels were demonstrated at angiography. These cryptic VMs were thought to have been destroyed at the time of hemorrhage. In 15 patients (23%), hypertension may have been a contributing factor. Two patients had mildly prolonged prothrombin times due to alcoholic liver disease, and their hemorrhages may have been secondary to a bleeding diathesis. For 24 patients (36%), no cause was apparent (Table 1). For one of the patients with an unknown etiology for the hemorrhage, the reporting authors suspected an infarct that then became hemorrhagic [4]. There is no radiologic proof of this; however, it offers another possible mechanism of midbrain hemorrhage.

Table 1. Cause of Spontaneous Midbrain Hemorrhage

Cause	Literature cases (n = 66)	Mayo cases (n = 7)	Combined series (n = 73)
Documented VM	10	2	12
Presumed VM	15	0	15
Hypertension	15	0	15
Unknown	24	3	27
Clotting disturbance	2	2	4

Abbreviation: VM, vascular malformation.

Of the seven patients in our series, case 3 had an AVM identified by angiography and visualized at operation. Case 7 had multiple intracranial cavernous malformations; one was in the midbrain and was the cause of her SMH. For cases 2, 4, and 5, no cause was apparent. Case 2 also had hypertension, but his chronic course was inconsistent with a hypertensive bleed. Two patients were on anticoagulants at the time of hemorrhage. Case 1 was on warfarin and had a markedly prolonged prothrombin time as well as a questionable history of hypertension. Heparin anticoagulation was suspected to be the main contributing factor for the midbrain hemorrhage in case 6 (Table 1). One of our patients (case 7) and one from the literature [29] were pregnant at the time of SMH; both had VMs. Pregnancy has been reported to be associated with an increased risk of VM rupture [59].

Rupture of a VM is a commonly proven or proposed mechanism of SMH. Angiographically visible VMs of the posterior fossa are relatively rare and represent 5% to 16% of all intracranial VMs in several clinical series [3,42,61]. Similarly, Lobato et al [32] reviewed 260 angiographically occult VMs and found that 34 (13%) were infratentorial, three of which (1%) were located in the midbrain. In contrast, McCormick and Nofzinger [35] found 147 (48%) of 308 "cryptic" VMs were infratentorial, with 85 (28%) being located in the brain stem.

Abe et al [1] reported a series of 63 brain-stem VMs, half of which were angiographically occult and diagnosed only by CT or MRI brain scanning. It remains possible that very small (1- to 2-mm) VMs located in the midbrain might not be demonstrated on a prehemorrhage imaging study (if one is obtained) and are not seen after bleeding because they are obliterated, substantially reduced in size, or overshadowed by the accompanying hemorrhage. Although the existence of such small VMs remains speculative, they may occur and are likely to be responsible for at least some cases of SMH.

Comparison of Major Etiologic Groups

The location of the bleeding in the midbrain was compared in VM-related hemorrhages and those likely due

Table 2. Age and Sex of Patients with Spontaneous Midbrain Hemorrhage

	Literature cases (n = 66)*	Mayo cases (n = 7)	Combined series (n = 69)
Age range	3 mo to 71 yr	30 to 87 yr	3 mo to 87 yr
Sex distribution	37M/25F	4M/3F	41M/28F
Average age (yr)	46	59	47
Median age (yr)	49	55	49

* Information available for only 62 of 66 literature cases.

to hypertension. Among the 12 patients with documented VMs, the bleeding was localized to the tectum in four [7,54,57 and patient 3 in this study] and the tegmentum in five [14,21,27,29 and patient 7 in this study], with extension into the third ventricle in two of the latter cases [21,27]; involved the tectum and tegmentum in two [1,12]; and was isolated to the peduncle in one case [45]. Of the 15 patients with a history of hypertension, one had bleeding isolated to the tectum [60]; nine had hemorrhage primarily in the tegmentum [12,16,20,36-38,41,43,56], four of whom also had extension into the third ventricle [12,36,37,43]; two had involvement of the tectum and tegmentum [10,43]; one had involvement of the tegmentum and peduncle [10]; and two had bleeding isolated to the cerebral peduncle [39,46]. Although a greater percentage of hemorrhages from VMs were isolated to the tectum (33% compared with 7%), no further definite conclusions can be drawn from the overall comparison about differences in predilection for location between VM-related hemorrhages and those attributed to hypertension.

The average age of the patients with VM-related hemorrhages was 34 years, whereas it was 58 years for those with hypertension-associated bleeding.

The outcomes were similar for both etiologic groups: most recovered with mild or no deficits (82% in VM-related hemorrhage, 67% in hypertensive bleeding), and one patient from each group died.

Clinical Presentation

In the literature cases, patient ages ranged from 3 months to 71 years. There was a male predominance (3:2) in the 62 cases in which sex was reported. All six of the patients under age 19 years were male. The patients in our series ranged in age from 30 to 87 years; four were men and three were women (Table 2).

Various clinical syndromes related to lesions of the midbrain have been described including Weber's, Benedikt's, Claude's, Nothnagel's, and Parinaud's syndromes. In the cases reported here and those in the literature, identifiable midbrain syndromes were rare. Because of the complex anatomy of the midbrain, a

multitude of neurologic signs and symptoms can result from even a small lesion. A few patients have had classic findings.

Roig et al [43] described a patient with Claude's syndrome evolving into Benedikt's syndrome. One of Weisberg's [58] patients had findings consistent with Benedikt's syndrome and another had Weber's syndrome. Gaymard et al [18] also described a patient with Weber's syndrome. Two cases of Nothnagel's syndrome have been reported [22,47]. Three cases of SMH causing pure sensory stroke have been reported [2,56,57]. There have been three cases of SMH causing an isolated nerve III palsy as the only clinical manifestation [28,48,49]. In three patients, peduncular hallucinosis developed secondary to SMH [21,43,58]. Ono and Inoue [41] described a patient with cheiro-oral syndrome (sensory disturbance of the corner of the mouth and palm of the ipsilateral hand). Miyashita et al [38] reported a case of vertical one-and-a-half syndrome (bilateral upgaze palsy and monocular paresis of downgaze).

Thus, the presentation of SMH is variable with regard to neurologic findings. Neuro-ophthalmologic abnormalities relating to cranial nerve III and/or IV were the most frequent findings, being present in 58 (88%) of the 66 cases in the literature. Conjugate upward gaze paresis was present in 33 (57%) of these 58. This may be the single most helpful diagnostic finding for localizing the lesion to the midbrain. Disturbance of consciousness, often transient and ranging from somnolence and lethargy to coma, was present in 33 patients (50%). Headache, with or without nausea and vomiting, was noted in 34 patients (52%); it frequently was the initial symptom of the midbrain hemorrhage. Corticospinal tract deficits were present in 32 patients (48%); 22 of these 32 also had evidence of corticobulbar involvement, with dysarthria being present in 14. Twenty-one patients (32%) had lost one or more sensory modalities, usually contralateral to the site of the hemorrhage if the hemorrhage was lateralized. Twenty-two (33%) of the 66 patients had an ataxic gait. Two patients had tinnitus and one patient experienced hyperacusis, suggesting involvement of the inferior colliculus (Table 3).

Of the seven patients in our series, six had abnormalities of cranial nerve III or IV: two (cases 4 and 5) had nerve IV palsies as their only abnormality of eye movement, and four had evidence of nerve III involvement. Cases 6 and 7 had conjugate paralysis of upward gaze out of proportion to their nerve III deficits. In six of the seven patients in our series, some degree of alteration of consciousness developed. Two patients (cases 1 and 5) experienced sudden loss of consciousness as the first manifestation of their SMH. Four patients (cases 3, 4, 5, and 7) reported headache associated with their SMH, but it was not prominent or lasting (Table 3).

Table 3. Clinical Findings in Patients with Spontaneous Midbrain Hemorrhage

Finding	Literature cases (n = 66)	Mayo cases (n = 7)	Combined series (n = 73)
Cranial nerve III or IV paresis	58	6	64
Disturbance of consciousness	33	6	39
Headache	34	4	38
Corticospinal tract deficits	32	4	36
Corticobulbar deficits	22*	2	24
Hemisensory deficits	21	3	24
Gait ataxia	22	2	24
Visual hallucinations	3	0	3
Tinnitus or hyperacusis	3	2	5

* One patient had corticobulbar deficit without a corticospinal deficit.

The temporal profile of brain hemorrhage usually is acute, with signs and symptoms reaching a peak within 24 hours. This occurred in 43 (65%) of the 66 SMH cases in the literature. Sixteen (24%) of the literature cases followed a subacute course (1 day to 1 month), and seven (11%) had a chronic course (greater than 1 month) (Table 4). When a complete description was given, many of the cases with apparent subacute or chronic temporal profiles actually had a stepwise progressive course.

Five of the seven patients with SMH in our series had a single acute event. One patient (case 7) had multiple acute episodes over several months, and another (case 2) may have had multiple acute hemorrhages that presented as a slowly progressive course (Table 4). The frequency with which temporal profiles other than acute occurred in the literature cases (23 of 66 cases, 35%) and cases 2 and 7 in our series suggests that often several, small, nonfatal hemorrhages can occur before the diagnosis of SMH is made.

Table 4. Clinical Presentation in Patients with Spontaneous Midbrain Hemorrhage

Presentation	Literature cases (n = 66)	Mayo cases (n = 7)	Combined series (n = 73)
Acute onset (peak in 24 h)	43	5	48
Subacute onset (peak 1 d to 1 mo)	16	0	16
Chronic course (onset > 1 mo)	7	2	9

Diagnosis and Differential Diagnosis

CT and MRI are rapid, noninvasive, accurate methods for diagnosing SMH (Figures 1 and 2). Since it became widely available in the mid-1970s, CT has been 100% successful in the cases reported. That is, no lesion has been identified by another imaging modality or at operation or autopsy that was missed by CT. Although CT is preferred for detecting acute hemorrhage, MRI is more useful for following the evolution of a hemorrhage. MRI also may reveal an angiographically occult VM [19,31,40] and should be performed on all patients with SMH.

Prior to the performance of a CT or MRI scan, the diagnosis of SMH often is not considered or the lesion is misdiagnosed. Three cases have been reported in which the initial diagnosis was multiple sclerosis, indicating that SMH can follow a remitting and relapsing course [1,22,46]. Humphreys [23] initially diagnosed a left supratentorial mass in his patient who had a midbrain hemorrhage. Preoperatively, La Torre et al [54] expected to find a hemorrhagic tumor of the quadrigeminal plate. In one of the cases reported by Dhopes et al [10], the diagnosis was hypertensive encephalopathy before CT revealed the hemorrhage. In another of the Dhopes et al cases and in a case reported by Brismar et al [5], the diagnosis was midbrain infarction. In the majority of cases reported in the literature, the clinical presentation and examination suggested a vascular lesion that was correctly localized to the midbrain.

Treatment

In most cases of SMH, conservative, supportive treatment is sufficient to ensure a good outcome. If hydrocephalus is present, a diversionary shunting procedure can be lifesaving, as in seven of the literature cases (in two of these, surgical exploration also was performed).

Mangiardi and Epstein [34] and Kashiwagi et al [26] recommended surgical exploration for documented brain-stem vascular malformations with a progressive course. Of note, the majority of the hemorrhages they referred to were in the pons. Lobato et al [32] suggested that every intracranial angiographically occult VM that caused clinical symptoms should be resected, irrespective of location. They did not make a distinction between cases with hemorrhage and those without.

Seven of the SMH cases in the literature underwent surgical exploration of the midbrain. In five of these, clotted blood was evacuated, and in two, the exploration was negative; a shunting procedure was performed in one case in each of these groups. The outcome was good in six of these seven cases; one patient died 2 days postoperatively (in this last case, the exploration had

Table 5. Interventions in Spontaneous Midbrain Hemorrhage

Intervention	Literature cases (n = 66)	Mayo cases (n = 7)	Combined series (n = 73)
Exploration with evacuation of clot	5 (1 also shunted)	0	5
Surgical exploration without evacuation of clot	2 (1 also shunted)	1	3
Total shunting procedures	7	0	7

been negative and ventriculocisternal shunting had been performed) [14]. Thus, all five patients who underwent successful surgical evacuation improved postoperatively. Five other patients had diversionary shunts only and had improvement in their neurologic status (Table 5).

Case 3 in our series had an unsuccessful attempt to remove her midbrain AVM and hematoma (Table 5). Obliteration of the AVM was then performed by stereotactic gamma knife radiosurgery. Gamma knife radiosurgery is a promising new treatment option for deep-seated VMs [33]. The remaining six patients in our series received only supportive treatment for their SMH.

Outcome

The course of SMH can be surprisingly benign. In 16 (24%) of the 66 reported cases in the literature, the neurologic findings were normal at follow-up. In the majority of the literature cases (35 patients, 53%), relatively minor neurologic deficits persisted, related chiefly to cranial nerve III or IV, or both. All the patients with minor neurologic deficits were able to return to independent living. In 10 cases (15%), moderate neurologic deficits persisted and the patients required long-term care. Three patients (5%) died, and for two, no follow-up was available (Table 6). The mean duration of

Table 6. Outcome in Spontaneous Midbrain Hemorrhage

Outcome	Literature cases (n = 66)	Mayo cases (n = 7)	Combined series (n = 73)
Normal	16	1	17
Mild neurologic deficits	35	2	37
Moderate to severe deficits	10	2	12
Death	3	1	4
No follow-up	2	1	3

follow-up was 9.4 months for the 66 patients in the literature (range 0 to 87 months).

Case 4 in our series was neurologically normal at follow-up. Two patients (cases 3 and 5) continued to experience mild abnormalities of extraocular movements as their chief complaint. Cases 6 and 7 required nursing home placement following hospitalization for SMH. Patient 1 in our series died shortly after admission, and no follow-up could be obtained for case 2 (Table 6). Mean follow-up was 22.1 months for our series (range 0 to 53 months).

Two patients in our series who had a poor outcome (cases 1 and 6) were on anticoagulants at the time of their hemorrhage, which no doubt contributed to the extent of their bleeding. In two of the literature cases, the prothrombin time was mildly prolonged; one of these patients had a large hemorrhage [10,36]. An anticoagulated state at the time of hemorrhage may predispose to a worse outcome.

There were no instances of subsequent hemorrhage among the patients who presented acutely with SMH. However, the duration of follow-up in these cases usually was a matter of weeks to months.

References

1. Abe M, Kjellberg R, Adams RD. Clinical presentations of vascular malformations of the brain stem: comparison of angiographically positive and negative types. *J Neurol Neurosurg Psychiatry* 1989;52:167-75.
2. Azouvi Ph, Tougeron A, Hussonois C, Schouman-Claeys E, Bussel B, Held JP. Pure sensory stroke due to midbrain haemorrhage limited to the spinthalamic pathway. *J Neurol Neurosurg Psychiatry* 1989;52:1427-8.
3. Batjer H, Samson D. Arteriovenous malformations of the posterior fossa: clinical presentation, diagnostic evaluation, and surgical treatment. *J Neurosurg* 1986;64:849-56.
4. Bolling J, Lavin PJ. Combined gaze palsy of horizontal saccades and pursuit contralateral to a midbrain haemorrhage. *J Neurol Neurosurg Psychiatry* 1987;50:789-91.
5. Brismar J, Hindfelt B, Nilsson O. Benign brainstem hematoma. *Acta Neurol Scand* 1979;60:178-82.
6. Burns J, Lisak R, Schut L, Silberberg D. Recovery following brainstem hemorrhage. *Ann Neurol* 1980;7:183-4.
7. Chambers AA, McLennan JE. Pericolicular syndromes. *Neuroradiology* 1978;16:547-8.
8. Cocito D, Amedeo G, Gallo G, Vischia F, DeLucchi R. Hematoma of the inferior colliculus: uncommon cause of trochlear nerve deficit and contralateral sensory hemisyndrome. *Ital J Neurol Sci* 1990;11:71-4.
9. Von Cramon D. Bilateral cerebellar dysfunctions in a unilateral meso-diencephalic lesion. *J Neurol Neurosurg Psychiatry* 1981;44:361-3.
10. Dhopes VP, Greenberg JO, Cohen MM. Computed tomography in brainstem hemorrhage. *J Comput Assist Tomogr* 1980;4:603-7.
11. Dinsdale HB. Spontaneous hemorrhage in the posterior fossa: a study of primary cerebellar and pontine hemorrhages with observations on their pathogenesis. *Arch Neurol* 1964;10:200-17.
12. Durward QJ, Barnett HJM, Barr HWK. Presentation and management of mesencephalic hematoma: a report of two cases. *J Neurosurg* 1982;56:123-7.
13. Dussaux P, Plas J, Brion S. Parésie bilatérale du muscle grand oblique, par hématome de la calotte mésencéphalique. *Rev Neurol (Paris)* 1990;146:45-7.
14. Escobar A, Vega-Gama JG, Rodriguez-Carbajal J. Malformación arteriovenosa mesencefálica estudio clínico y patológico de un caso. *Gac Med Mex* 1982;118:195-200.
15. Fingerote RJ, Shuaib A, Brownell AKW. Spontaneous midbrain hemorrhage. *South Med J* 1990;83:280-2.
16. Fleet WS, Rapcsak SZ, Huntley WW, Watson RT. Pupil-sparing oculomotor palsy from midbrain hemorrhage. *Ann Ophthalmol* 1988;20:345-6.
17. Freytag E. Fatal hypertensive intracerebral haematomas: a survey of the pathological anatomy of 393 cases. *J Neurol Neurosurg Psychiatry* 1968;31:616-20.
18. Gaymard B, Larmande P, De Toffol B, Autret A. Reversible nuclear oculomotor nerve paralysis: caused by a primary mesencephalic hemorrhage. *Eur Neurol* 1990;30:128-31.
19. Gomori JM, Grossman RI, Goldberg HI, Hackney DB, Zimmerman RA, Bilaniuk LT. Occult cerebral vascular malformations: high-field MR imaging. *Radiology* 1986;158:707-13.
20. Han SH, Roh JK, Myung HJ. Mesencephalic hemorrhage—a report of 3 cases. *J Korean Med Sci* 1989;4:1-5.
21. Hayakawa I, Okajima S, Sato K, Saito T, Tazaki Y. Hallucinoise pedunculaire in a patient with localized midbrain hemorrhage caused by arterio-venous malformation. *Rinsho Shinkeigaku* 1984;24:472-5.
22. Hino H, Segawa K, Furuhashi N, Kanda T, Tazaki Y. Nothnagel syndrome associated with mid-brain hemorrhage. A case report. *Shinkei Naika* 1985;23:350-4.
23. Humphreys RP. Computerized tomographic definition of mesencephalic hematoma with evacuation through pedunculotomy. *J Neurosurg* 1978;49:749-52.
24. Iwanaga K, Kinoshita I, Ohe N. Brainstem ptosis (midbrain ptosis) associated with mesencephalic hemorrhage. *Rinsho Shinkeigaku* 1990;30:793-5 (in Japanese).
25. Kamei T, Uchiyama F, Fukuyama J. Primary tectal mesencephalic hemorrhage with isolated trochlear nerve palsy. A case report. *Rinsho Shinkeigaku* 1987;27:1167-9.
26. Kashiwagi S, van Loveren HR, Tew JM Jr, Wiot JG, Weil SM, Lukin RA. Diagnosis and treatment of vascular brain-stem malformations. *J Neurosurg* 1990;72:27-34.
27. Kawamura S, Suzuki A, Yasui N. Midbrain arteriovenous malformation causing bilateral total ophthalmoplegia as an initial ocular symptom—a case report. *No To Shinkei* 1988;40:171-7.
28. Keane JR. Isolated brain-stem third nerve palsy. *Arch Neurol* 1988;45:813-4.
29. Kida Y, Naritomi H, Sawada T, Ogawa M, Kanako T. Unilateral asterixis caused by midbrain hemorrhage. *Rinsho Shinkeigaku* 1987;27:172-6.
30. Ksiazek SM, Repka MX, Maguire A, Harbour RC, Savino PJ, Miller NR, Sergott RC, Bosley TM. Divisional oculomotor nerve paresis caused by intrinsic brainstem disease. *Ann Neurol* 1989;26:714-8.
31. Kucharczyk W, Lemme-Plegos L, Uske A, Brant-Zawadzki M, Doooms G, Norman D. Intracranial vascular malformations: MR and CT imaging. *Radiology* 1985;156:383-9.
32. Lobato RD, Perez C, Rivas JJ, Cordobes F. Clinical, radiological, and pathological spectrum of angiographically occult intracranial vascular malformations. *J Neurosurg* 1988;68:518-31.
33. Lunsford LD, Flickinger J, Coffey RJ. Stereotactic gamma knife

- radiosurgery: initial North American experience in 207 patients. *Arch Neurol* 1990;47:169-75.
34. Mangiardi JR, Epstein FJ. Brainstem haematomas: review of the literature and presentation of five new cases. *J Neurol Neurosurg Psychiatry* 1988;51:966-76.
 35. McCormick WF, Nofzinger JD. "Cryptic" vascular malformations of the central nervous system. *J Neurosurg* 1966;24:865-75.
 36. Mehler MF, Ragone PS. Primary spontaneous mesencephalic hemorrhage. *Can J Neurol Sci* 1988;15:435-8.
 37. de Mendonça A, Pimentel J, Morgado F, Ferro JM. Mesencephalic haematoma: case report with autopsy study. *J Neurol* 1990;237:55-8.
 38. Miyashita K, Sawada T, Satomi M. Upgaze palsy and monocular paresis of downgaze caused by ipsilateral thalamomesencephalic hemorrhage: a so-called vertical "one and a half syndrome." *Rinsho Shinkeigaku* 1987;27:1407-11.
 39. Morel-Maroger A, Metzger J, Bories J, Gardeur D, Verger JB, Noël MC. Les hématomes bénins du tronc cérébral chez les hypertendus artériels. *Rev Neurol* 1982;138:437-45.
 40. New PFJ, Ojemann RG, Davis KR, Rosen BR, Heros R, Kjellberg RN, Adams RD, Richardson EP. MR and CT of occult vascular malformations of the brain. *AJNR* 1986;7:771-9.
 41. Ono S, Inoue K. Cheiro-oral syndrome following midbrain haemorrhage. *J Neurol* 1985;232:304-6.
 42. Perret G, Nishioka H. Report on the cooperative study of intracranial aneurysms and subarachnoid hemorrhage, section VI, arteriovenous malformations. An analysis of 545 cases of cranio-cerebral arteriovenous malformations and fistulae reported to the cooperative study. *J Neurosurg* 1966;25:467-90.
 43. Roig C, Carvajal A, Illa I, Escartin A, Grau JM, Barraquer L. Hémorragies mésencéphaliques isolées: trois cas diagnostiqués par tomodensitométrie. *Rev Neurol* 1982;138:53-61.
 44. Sand JJ, Biller J, Corbett JJ, Adams HP Jr, Dunn V. Partial dorsal mesencephalic hemorrhages: report of three cases. *Neurology* 1986;36:529-33.
 45. Sano K. Spontaneous brain stem haematoma. *Neurosurg Rev* 1983;6:71-7.
 46. Scoville WB, Poppen JL. Intrapeduncular hemorrhage of the brain: successful operative approaches, with evacuation of clot and a seven and a one-fourth year observation period. *Arch Neurol Psychiatry* 1949;61:688-94.
 47. Shiino A, Ichikawa M, Matsuda M, Handa J. A midbrain hemorrhage presenting Nothnagel syndrome. *Arch Jpn Chir* 1986;55:789-95.
 48. Shuaib A, Israelian G, Lee MA. Mesencephalic hemorrhage and unilateral pupillary deficit. *J Clin Neuro Ophthalmol* 1989;9:47-9.
 49. Shuaib A, Murphy W. Mesencephalic hemorrhage and third nerve palsy. *J Comput Tomogr* 1987;11:385-8.
 50. Stein BM, Mohr JP. Vascular malformations of the brain. *N Engl J Med* 1988;319:368-70.
 51. Stern LZ, Bernick C. Spontaneous, isolated, mesencephalic hemorrhage. *Neurology* 1986;36:1627.
 52. Sugawara T, Ishibashi Y, Ishibashi T. Hemorrhage in the quadrigeminal plate—a case report. *No Shinkei Geka* 1987;15:965-9.
 53. Tachibana H, Mimura O, Shiomi M, Oono T. Bilateral trochlear nerve palsies from a brainstem hematoma. *J Clin Neuro Ophthalmol* 1990;10:35-7.
 54. La Torre E, Delitala A, Sorano V. Hematoma of the quadrigeminal plate: case report. *J Neurosurg* 1978;49:610-3.
 55. Tronci S, Congia S. Spontaneous mesencephalic hemorrhage: case report and physiopathological interpretation of its course. *Ital J Neurol Sci* 1989;10:183-5.
 56. Turtle PV, Reinmuth OM. Midbrain hemorrhage producing pure sensory stroke. *Arch Neurol* 1984;41:794-5.
 57. Ueki H, Nishimaru K. Pure sensory stroke due to midbrain hemorrhage—case report. *No To Shinkei* 1985;37:171-2 (English abstract).
 58. Weisberg LA. Mesencephalic hemorrhages: clinical and computed tomographic correlations. *Neurology* 1986;36:713-6.
 59. Wiebers DO. Subarachnoid hemorrhage in pregnancy. *Semin Neurol* 1988;8:226-9.
 60. Wise J, Gomolin J, Goldberg LL. Bilateral superior oblique palsy: diagnosis and treatment. *Can J Ophthalmol* 1983;18:28-32.
 61. Yasargil MG. Microneurosurgery. Vol IIIB: AVM of the brain, clinical considerations, general and special operative techniques, surgical results, nonoperated cases, cavernous and venous angiomas, neuroanesthesia. Stuttgart: Georg Thieme Verlag, 1988, pp 358-99.
 62. Yura S, Sako K, Yonemasu Y. Primary midbrain hemorrhage with up-beat vertical nystagmus. *Shinkei Naika* 1985;23:601-4.
 63. Zuccarello M, Iavicoli R, Pardatscher K, Scanarini M, Fiore D, Andrioli GC. Primary brain stem haematomas. Diagnosis and treatment. *Acta Neurochir (Wien)* 1980;54:45-52.