

## Subarachnoid hemorrhage as presenting feature of isolated neurosarcoidosis

K. Berek<sup>1</sup>, S. Kiechl<sup>1</sup>, J. Willeit<sup>1</sup>, G. Birbamer<sup>1,2</sup>, G. Vogl<sup>1</sup>, and E. Schmutzhard<sup>1</sup>

<sup>1</sup> Universitätsklinik für Neurologie, Innsbruck

<sup>2</sup> Institut für Magnetresonanztomographie und Spektroskopie, Innsbruck

**Summary.** A 35-year-old man presented with the clinical picture of spontaneous subarachnoid hemorrhage. Four weeks after the first symptoms he noticed blurred vision, and ophthalmological examination detected bitemporal hemianopia. At this time cerebral computed tomography and magnetic resonance imaging showed enlargement of the optic chiasm, and visual evoked potentials revealed delayed latencies. In the cerebrospinal fluid cells and protein content were elevated, and angiotensin-converting enzyme was detectable. Under steroid treatment the patient recovered completely and computed tomography, magnetic resonance imaging, visual evoked potentials, and cerebrospinal fluid findings became normal. Although a great variety of neurological symptoms may occur in neurosarcoidosis, to our knowledge spontaneous subarachnoid hemorrhage as the presenting feature has never been reported before.

**Key words:** Subarachnoid hemorrhage – Cerebrospinal fluid – Angiotensin-converting enzyme – Neurosarcoidosis

Sarcoidosis is a multisystem granulomatous disorder of unknown etiology, most commonly affecting young adults and frequently presenting with bilateral hilar lymphadenopathy, pulmonary infiltration, and skin or eye lesions. Involvement of the nervous system is a rare manifestation of sarcoidosis, occurring in about 5% of patients with this disease [4, 5, 7, 10, 11]. In 8% [4] to 48% [11] of all patients suffering from neurosarcoidosis no extracerebral manifestations can be found. We report a case of isolated neurosarcoidosis, which

initially presented with the clinical picture of subarachnoid hemorrhage (SAH).

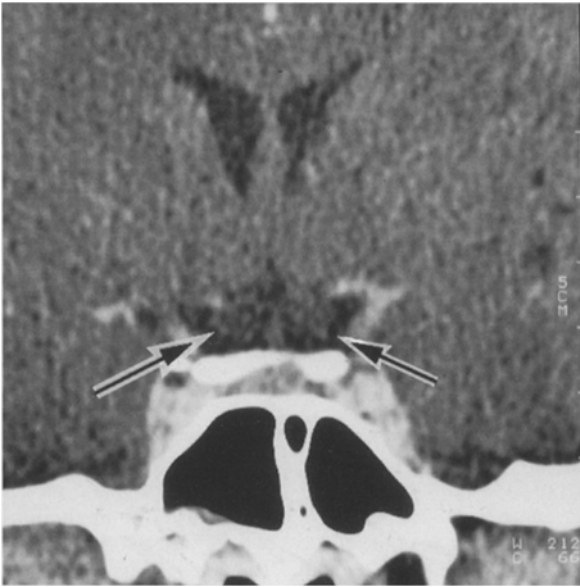
### Case report

A 35-year-old man suddenly felt a throbbing headache originating from his neck and spreading to the forehead after coughing vigorously. On admission 10 days later the patient complained of headache and nausea; clinically he presented with meningism and a temperature of 37.8° C.

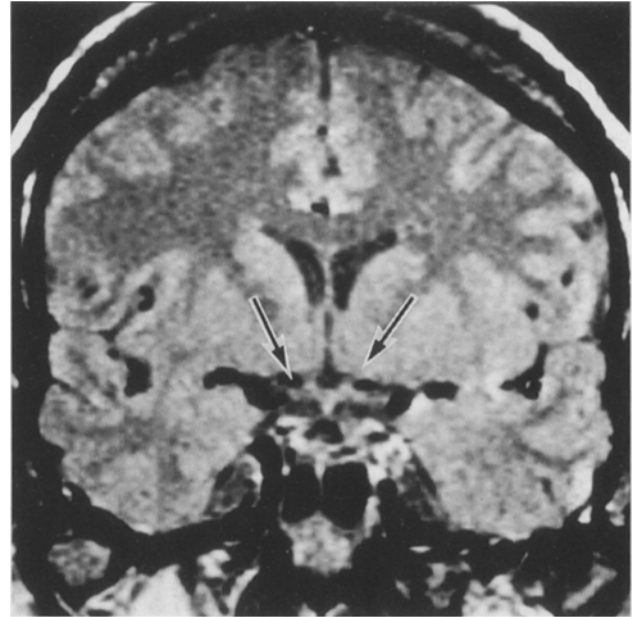
Examination of the cerebrospinal fluid (CSF) revealed xanthochromia, lymphocytic pleocytosis of 267 cells/cm<sup>3</sup>, and elevated protein content of 100 mg/dl with an increased IgG index; CSF glucose concentration was decreased to 40 mg/dl with a glucose ratio of 0.37. On cytological examination siderophages were found, giving evidence of past hemorrhage into the subarachnoid space. At this time cranial computed tomography (CT), magnetic resonance imaging (MRI), cerebral panangiography, electroencephalography (EEG), visual (VEP) and brainstem evoked potentials, and X-ray of the chest were normal. Erythrocyte sedimentation rate (ESR) and C-reactive protein (CRP) were elevated; all other laboratory findings including markers of collagen-vascular diseases were within normal limits. CSF cultures for bacteria, acid-fast bacilli, and fungi were negative, as well as serological results of neurotropic viruses, *Toxoplasma gondii*, *Borrelia burgdorferi*, *Treponema pallidum*, and human immunodeficiency virus antibodies and antigen.

Four weeks after his first complaints, the patient noticed blurred vision, and ophthalmological examination detected bitemporal hemianopia. CT (Fig. 1) and MRI (Fig. 2) now showed an enlarged optic chiasm; VEP revealed bilaterally delayed latencies; cultures, serology, and routine laboratory findings were unchanged; electromyography and nerve conduction velocities were normal. Angiotensin-converting enzyme (ACE) was elevated to 72 U/l (normal <55 U/l) in serum and to 35 U/l

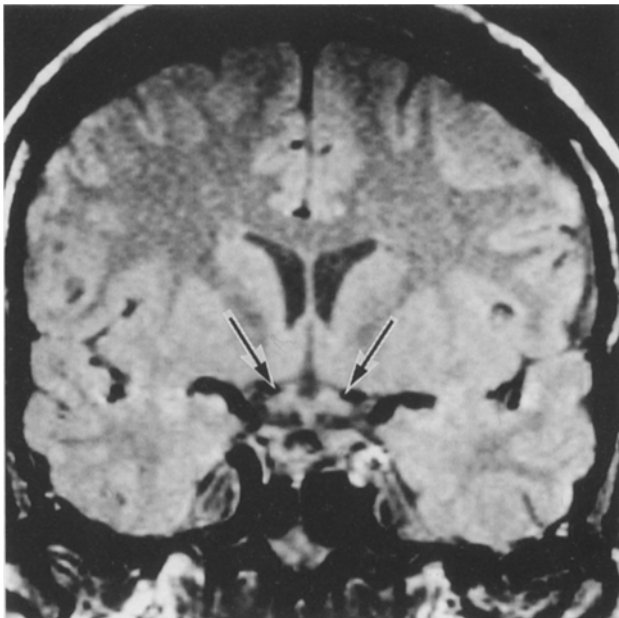
**Abbreviations:** ACE=angiotensin-converting enzyme; CRP=C-reactive protein; CSF=cerebrospinal fluid; CT=computed tomography; ESR=erythrocyte sedimentation rate; MRI=magnetic resonance imaging; SAH=subarachnoid haemorrhage; VEP=visual evoked potentials



**Fig. 1.** Coronary CT with metrizamide, 2 mm slice thickness. *Arrows*, enlarged optic chiasm without enhancement



**Fig. 3.** Coronary PD-weighted images (TR = 2400 ms, TE = 15 ms). Normal appearance of the optic chiasm after steroid treatment



**Fig. 2.** Coronary PD-weighted images (TR = 2400 ms, TE = 15 ms). *Arrows*, marked enlargement of the optic chiasm

in CSF, which still showed siderophages, lymphocytic pleocytosis, elevated protein content with increased IgG index, and hypoglycorrhachia. X-ray and CT of the chest were unremarkable; results of Tine test were negative; a whole-body gallium scan showed increased meningeal activity, whereas pulmonary findings were negative.

Suspecting isolated sarcoidosis of the CNS, we instituted treatment with prednisone 60 mg daily. After 1 week bitemporal hemianopia and blurred vision disappeared, MRI (Fig. 3) and CT became normal, and VEP showed evident improvement. CSF changes confirmed the success of steroid treatment with normal protein content and IgG index, near normal cell count and ACE no longer being detectable. ACE in serum, ESR, and CRP returned to normal ranges as well. The patient has recovered completely; he has returned to work and is seen regularly in our outpatient clinic.

## Discussion

Diagnosis of neurosarcoidosis does not present a great problem if systemic sarcoidosis is present, but it may be difficult if neurological signs are the first type of presentation. The main criteria for diagnosing isolated neurosarcoidosis are pathological examination of neural or muscle tissue or a clinical course consistent with neurosarcoidosis without any evidence of other neurological diseases [5].

Sarcoidosis can produce a variety of neurological involvements. Most common is granulomatous leptomeningitis, often producing hydrocephalus [4]. As a more unusual pattern, sarcoid granuloma may produce signs and symptoms of a brain tumor [4]. Another striking pathological feature is the in-

vasion and destruction of the wall of especially small arteries and veins, causing stenosis and total thrombosis [4]. Autopsy findings often reveal this complication [7]; however, clinical reports are rare. SAH appearing in the course of granulomatous angiitis of the CNS has been reported in some instances [3, 9], but to our knowledge it has never been reported as the presenting feature of neurosarcoidosis, as was the case in our patient.

The diagnosis of spontaneous SAH was based on history and CSF findings of xanthochromia and siderophages. Negative results of cerebral four-vessel angiography exclude neither SAH nor cerebral vasculitis, affecting predominantly small arteries and veins [6]. Lymphocytosis, elevated protein content with increased IgG index, decreased glucose level in CSF [1, 4, 10], and enlargement of the optic chiasm are consistent with neurosarcoidosis [2]. Inflammatory disorders other than sarcoidosis were excluded by negative cultures, serological results, and laboratory findings; neoplastic diseases were excluded by CSF findings and the clinical course, which showed complete recovery during corticosteroid treatment. Further clues to diagnosis were VEP [8, 10], ACE levels in serum and CSF [10], and anergy to tuberculin, which is found in two-thirds of all patients suffering from sarcoidosis because of reduced cellular immunity response [10].

Although none of the reported findings is specific, the combination of appropriate CT, MRI, electrophysiological, and CSF findings allowed establishment of the diagnosis of neurosarcoidosis, which was indirectly supported by the outcome following steroid treatment. Small vessel vasculitis may be the cause of SAH in our patient.

## References

1. Borucki SJ, Nguyen BV, Ladoulis CT, McKendall RR (1989) Cerebrospinal fluid immunoglobulin abnormalities in neurosarcoidosis. *Arch Neurol* 46:270-273
2. Char DH, Unsöld R, Sobel DF, Salvolini U, Newton TH (1988) Ocular and orbital pathology. In: Newton TH, Hasso AN, Dillon WP (eds) *Computed tomography of the head and neck*. Raven Press, New York, pp 9.1-9.64
3. Edwards KR (1977) Hemorrhagic complications of cerebral arteritis. *Arch Neurol* 34:549-552
4. Kumpe DA, Krishna Rao CVG, Garcia JH, Heck AF (1979) Intracranial neurosarcoidosis. *J Comput Assist Tomogr* 3:324-330
5. Luke RA, Stern BJ, Krumholz A, Johns CJ (1987) Neurosarcoidosis: the long-term clinical course. *Neurology* 37:461-463
6. Moore PM (1989) Diagnosis and management of isolated angiitis of the central nervous system. *Neurology* 39:167-173
7. Oksanen V (1986) Neurosarcoidosis: clinical presentations and course in 50 patients. *Acta Neurol Scand* 73:283-290
8. Oksanen V, Salmi T (1986) Visual and auditory evoked potentials in the early diagnosis and follow-up of neurosarcoidosis. *Acta Neurol Scand* 74:38-42
9. Reske-Nielsen E, Harmsen A (1962) Periangitis and panangitis as a manifestation of sarcoidosis of the brain: report of a case. *J Nerv Ment Dis* 135:399-412
10. Schlegel U (1987) Neurosarkoidose: Diagnostik und Therapie. *Fortschr Neurol Psychiatr* 55:1-15
11. Stern BJ, Krumholz A, Johns C, Scott P, Nissim J (1985) Sarcoidosis and its neurological manifestations. *Arch Neurol* 42:909-917

Received: July 23, 1992

Accepted: October 19, 1992

Dr. K. Berek  
 Universitätsklinik für Neurologie  
 Anichstrasse 35  
 A-6020 Innsbruck  
 Austria