

# Palinopsia

J. C. MEADOWS<sup>1</sup> AND S. S. F. MUNRO

*From Atkinson Morley's and St. George's Hospitals, London, and the Victoria Eye Hospital, Hereford*

**SUMMARY** Three cases of palinopsia (visual perseveration) are described. In each case, evidence pointed to a lesion in the right occipitotemporal region. Pathological findings are reported in one of the three. Previous reports have stressed the importance of posteriorly placed cerebral lesions, more commonly right sided than left, but have not demonstrated more precise localisation within the hemisphere.

Palinopsia (visual perseveration) is a rare disorder in which images persist or recur after removal of a visual stimulus. In some cases the images are not noticed immediately but appear after an interval. Occasionally they may persist for quite long periods, even until the following day. Distinction between those illusions that occur immediately and those that are delayed has led some authors (for example, Mouren and Tatossian, 1963) to consider two separate disorders. However, judging from published case reports, the two types may be associated in the same patient, and other authors, such as Critchley (1951), have laid little emphasis on such a separation. In both the immediate and the delayed forms, the illusory image often becomes incorporated appropriately into the visual scene being perceived; in the first patient to be described below, for example, a Santa Claus beard became superimposed appropriately upon the faces of people at a party.

Patients with palinopsia usually have visual field disturbances, and these are more commonly left sided, reflecting the importance of posteriorly placed, right sided cerebral lesions (Bender *et al.*, 1968). According to Bender *et al.*, palinopsia occurs in visual fields that are defective but not blind. Apart from visual field defects, a number of other clinical features may be associated (Critchley, 1951; Mouren and Tatossian, 1963; Bender *et al.*, 1968). Illusions of movement may occur, as may visual perseveration in space (illusory visual spread) so that, for example, the pattern of a wallpaper appears to spread to adjacent structures. Sometimes there may be frank visual hallucinations, as in case 2 described in this paper. One particularly interesting feature, which occurs in a

minority of cases, is the rare and curious symptom of monocular diplopia or polyopia. In this illusion, which may take a number of clinical forms (Bender, 1945; Mouren and Tatossian, 1963), the characteristic feature is the persistence of the diplopia or polyopia when viewing is monocular, whichever eye is closed.

The mechanism underlying palinopsia is unknown. Because of the association with monocular diplopia or polyopia and with illusory visual spread, it is natural to question whether the simultaneously occurring, additional visual images that occur in these illusions might have a similar pathophysiological mechanism to the consecutively occurring additional visual images of palinopsia. The possible role of epilepsy in the pathogenesis of palinopsia (which will be discussed again later) and the relationship to after-imagery, have also been discussed in an aetiological context by several authors (Kinsbourne and Warrington, 1963; Mouren and Tatossian, 1963; Bender *et al.*, 1968). The general subject of visual imagery certainly bears examination for, at a superficial level, palinopsia can be likened to the common ability of normal subjects to revisualise, the much rarer phenomenon of eidetic imagery, and the hallucinations of confusional and pathological states.

There are wide individual differences in the expression of such forms of visual imagery. This raises the possibility that palinopsia might, itself, be an idiosyncratic response, in certain susceptible individuals, to posteriorly placed cerebral damage, without the precise location of the lesion being important. Alternatively (or additionally), a specifically sited lesion might underlie palinopsia. To date, clinicopathological correlations have been few and have generally shown large space-occupying lesions such as haemorrhages and tumours involving the posterior part of one cerebral hemisphere, more commonly the right (see, for example, Critchley,

<sup>1</sup> Address for correspondence: J. C. Meadows, Atkinson Morley's Hospital, Copse Hill, Wimbledon SW20 0NE.

Accepted 16 September 1976

1951; Bender *et al.*, 1968). These cases, unfortunately, are of limited value from the viewpoint of precise anatomical localisations because of their size, and the secondary effects of displacement and distortion. The purpose of the present paper is to report a case of palinopsia in which there was a pathologically proven and discrete infarct within the territory of the right posterior cerebral artery, and to present clinical evidence supporting a similar location of lesion in two additional cases.

### Case 1

(80572) An intelligent and alert 73 year old housewife, who gave a history of angina and intermittent claudication but not of neurological dysfunction, one day developed severe headache which settled within a few hours. The following day, at a Christmas party, she noticed that a replica of the white beard of the attendant Santa Claus was superimposed upon the face of everyone she spoke to. From time to time during the following day, she saw people in a red coat and Santa Claus cap, and mentioned palinoptic illusions of red candles and artificial eyelashes. Four days later, she consulted an ophthalmologist (S.S.F.M.) and was then still experiencing perseveratory illusions, particularly of the wallpaper pattern in her home. A full ophthalmological examination was normal, except for a congruous, left upper quadrantic homonymous field defect. She was unaware of this defect, so its duration was unknown. Visual acuity was 6/9 in the right eye and 6/12 in the left. Optic fundi, external ocular movements, and pupillary reactions were normal, and there were no other ophthalmological abnormalities. There were no other overt neurological abnormalities, but she died suddenly two days later, before seeing a neurologist.

### PATHOLOGICAL EXAMINATION

Postmortem examination revealed evidence of recent myocardial infarction. There were no other relevant abnormalities except in the central nervous system.

The brain weighed 1263 g and its superficial appearance was normal except for a discoloured area, 1–2 cm in diameter, on the under surface of the right occipital lobe. The entire brain was sliced at 1 cm intervals, and the posterior 8 cm of each cerebral hemisphere was sliced at 0.5 cm intervals. The only lesion seen was an elongated, shrunken, cystic infarct involving the lingual and fusiform gyri in the right occipitotemporal region (Fig. 1). Posteriorly, the infarct reached within 5 mm of the occipital lobe tip. Anteriorly, the cyst extended as an increasingly slender area into the temporal lobe to a distance of about 10 mm in front of the trigone of the lateral ventricle.

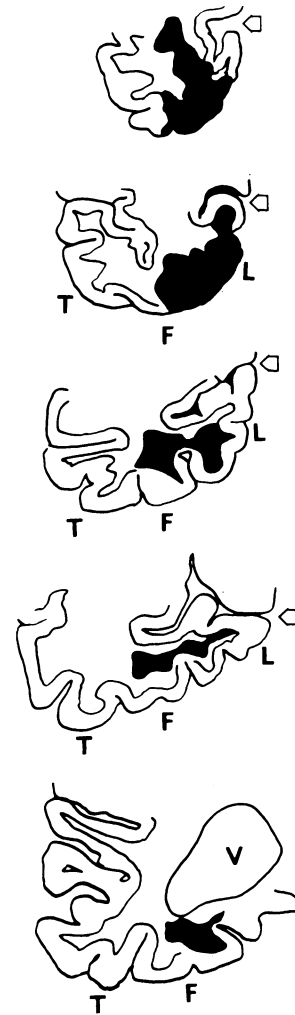


Fig. 1 Tracings from photographs of coronal sections through the posterior part of the right cerebral hemisphere of case 1, approximately 9, 18, 28, 34, and 57 mm from the occipital lobe tip. Arrow points to calcarine sulcus.

L = lingual gyrus, F = fusiform gyrus, T = inferior temporal gyrus, V = lateral ventricle.

Infarcted area shown in black. Microscopically, there was neuronal loss from cortex of lingual and fusiform gyri overlying this area.

Microscopic examination confirmed that the overlying cortex of the fusiform and lingual gyri, including the infracalcarine striate cortex, was destroyed. Further forward, the most posterior part of the hippocampus was destroyed. The remainder of the temporal lobe was not involved. The lower half of the optic radiation and about 90% of fibres in the posterior

column of the fornix failed to stain for myelin (Loyez). The appearances were those of an infarct of at least two months' standing.

## Case 2

(81331) A 56 year old housewife underwent craniotomy at another hospital in 1960 for removal of a right occipitotemporal meningioma causing headache and 'confusion'. Full details were not available. Her progress was followed at irregular intervals. She remained well, except for a left upper quadrantic homonymous field defect and, initially, some attacks in which she appeared dazed, confused and inaccessible to conversation, and for which phenytoin was prescribed. Twelve years after the craniotomy she noticed some visual deterioration and was found to have glaucoma, for which bilateral Scheie's operations were performed.

In 1975, she suddenly became unable to see at all for several seconds. She felt generally unwell for the next week, and then began to have shortlived episodes of palinopsia which continued for about three days. The part of her husband's face that fell in her left visual field—that is, the right side of his face—and part of the window frame, were most often involved. After several days, these were replaced by formed visual hallucinations in which a fountain of light crowned by a group of faces would appear in her left visual field and persist for about 40 seconds. Profound fear and an epigastric sensation accompanied these episodes. Phenytoin (which she had been taking regularly until two years previously) was prescribed and the episodes ceased within two to three days. When withdrawn temporarily a few days later, the hallucinations recurred, unaccompanied by palinopsia.

Examination revealed an extremely anxious woman. Higher cortical function testing was normal and there was no evidence of aphasia, apraxia, perceptual difficulty, or disturbance of orientation. A left homonymous visual field defect, complete in the upper quadrants and relative in the lower quadrants, was present. Visual acuity was 6/9 in the right eye but only 6/60 in the left, because of a cataract. These were the only abnormalities in the cranial nerve territory. Examination of the limbs was normal, except for minimal weakness of left hip flexors and a slightly brisker left knee jerk. Both plantar responses were flexor.

An EEG showed a reduction of alpha rhythm on the right and some excess slow activity in the right occipitotemporal region. Skull radiograph and Tc brain scan were normal. On right carotid angiography, the angular branch of the middle cerebral artery was not demonstrated. An EMI scan showed no abnormality at this site but revealed the area of resection (Fig. 2A) and an adjacent low density area (Fig. 2B). The more anterior part of this low density area did not show well on a repeat scan six months later but the two tomograms were not entirely comparable and the patient declined to have the investigation repeated. The possibility of a recent infarct was raised but cannot be substantiated. There was no evidence of tumour recurrence.

## Case 3

(61968) A 56 year old ambidextrous gamekeeper was beating his birds towards a line of gunfire when he lost his way in the woodland paths. He was extremely familiar with these paths and had never previously lost his way.

A similar episode occurred one week later, this time

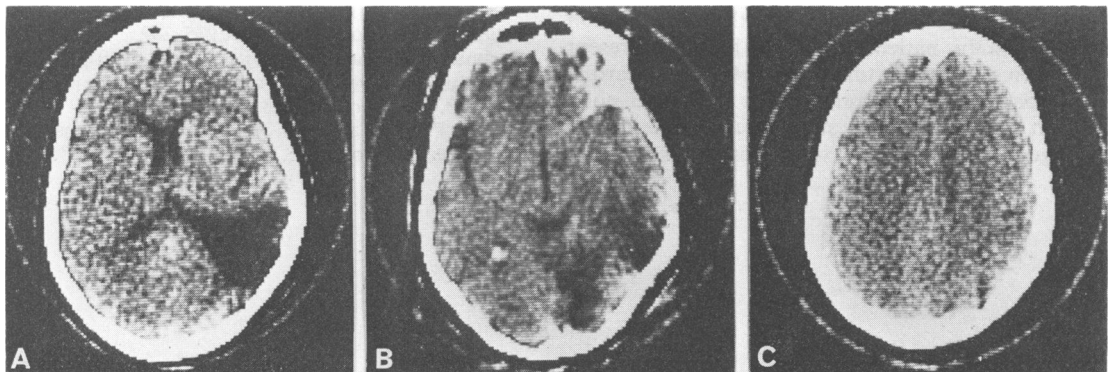


Fig. 2 Case 2. Computerised transverse axial (EMI) tomograms, showing (A) the wedge-shaped occipitotemporal resection area, (B) diminished density throughout much of the occipital and posterior temporal regions inferiorly, and (C) the absence of any lesion at parietal level.

associated with palinopsia and some headache. Wherever he looked, he saw the barley that he had been scattering earlier to feed the birds. The whole episode lasted for about five minutes. He had noticed no other symptoms and remained well until he was admitted for investigation six weeks later.

Examination on admission revealed a left upper quadrantic homonymous visual field defect. This was the only abnormality on initial neurological or general examination, but it was noted after a few days that he did have rather more difficulty than expected in finding his way about a somewhat complicated ward.

Psychological testing revealed a full WAIS IQ of 110 but a low score (6) on picture arrangement, and a poor performance on a memory-for-design test, the findings being felt to favour a right temporal lobe deficit. Skull radiographs, EEG, Tc brain scan, and right carotid angiogram were normal.

### Discussion

The main reason for reporting these cases of palinopsia is that, in each case, the evidence points to a lesion in the right occipitotemporal region. In case 1, infarction was demonstrated pathologically within the territory of the right posterior cerebral artery, affecting mainly the lingual and fusiform gyri. In the remaining cases, pathological verification was not obtained, but the presence of left sided homonymous visual field defects, confined to the upper quadrants in case 3, and more marked in the upper quadrants in case 2, point to similarly sited lesions. In case 2, computerised tomography showed changes only in the right occipitotemporal region, these being due to the meningioma that had previously been removed from this region, and possibly also to a recent stroke. In case 3, the palinopsia was associated with topographical memory loss, itself a feature of occipitotemporal damage (Meadows, in preparation).

There is an important difficulty in the interpretation of case 1. In this patient, palinopsia had been present for only five days at the time of death from myocardial infarction, yet the cerebral infarct found on post-mortem examination was at least several weeks old. The age of the lesion in case 2 is also open to some

question; the occurrence of a recent infarct in this case was not certain, but a meningioma had been removed many years earlier. In this context, some previous observations, particularly those of Bender *et al.* (1968), might be relevant, for Bender suggests that palinopsia may sometimes be an epileptic phenomenon. A similar argument has been presented in the case of the corresponding auditory phenomenon, palinacousis (Jacobs *et al.*, 1973). If an epileptic phenomenon is responsible for one form of palinopsia, the late onset of this symptom in cases 1 and 2 can be explained; focal epilepsy may occur for the first time long after the localised cerebral injury responsible for it. The fact that the lesions in these cases were all right sided accords with the evidence suggesting that right sided lesions cause palinopsia more commonly than left sided ones (Bender *et al.*, 1968).

There are many issues that have not been considered in this brief paper, which is concerned only with localisation of the lesion. It is hoped that further case reports will help in clarifying these.

Our thanks are due to Professor William Blackwood and his staff, for kindly preparing and aiding in the examination of the pathological sections, and to Professors Ian McDonald and John Marshall, under whose care cases 2 and 3 were admitted, for permission to publish these reports.

### References

- Bender, M. B. (1945). Polyopia and monocular diplopia of cerebral origin. *Archives of Neurology (Chic.)*, **54**, 323–338.
- Bender, M. B., Feldman, M., and Sobin, A. J. (1968). Palinopsia. *Brain*, **91**, 321–338.
- Critchley, M. (1951). Types of visual perseveration: 'palinopsia' and 'illusory visual spread'. *Brain*, **74**, 267–299.
- Jacobs, L., Feldman, M., Diamond, G. P., and Bender, M. B. (1973). Palinacousis: persistent or recurring auditory sensations. *Cortex*, **9**, 275–287.
- Kinsbourne, M., and Warrington, E. K. (1963). A study of visual perseveration. *Journal of Neurology, Neurosurgery, and Psychiatry*, **28**, 468–475.
- Mouren, P., and Tatossian, A. (1963). Les illusions visuo-spatiales, étude clinique. *Éncephale*, **52**, 517–573.