

## Serial Regional Blood Flow and Visual Evoked Responses in Transient Cortical Blindness

Ch.-W. Wong, T.-Y. Chen, J.-J. Liao, and D.-L. You<sup>1</sup>

Division of Neurosurgery, Department of Surgery, and <sup>1</sup>Department of Nuclear Medicine, Chang Gung Memorial Hospital, Taipei, Taiwan, Republic of China

### Summary

Normal regional blood flow was documented by Single Photon Emission Computed Tomograms 5 and 20 hours before the full recovery of cortical blindness in two patients, lending itself to the possibility of being a prognostic factor. Rubbing of the posterior cerebral arteries against the tentorial edges during trauma instead of traction was believed to cause blindness in one patient and embolization due to hammering bone grafts home during cervical spinal fusion, in the other. Pattern reversal visual evoked responses (PRVERs) were absent during blindness; upon recovery P 100 with full amplitude and normal latency appeared despite the presence of tunnel vision. These are consistent with the fact that the central 8–10 degrees of visual field represented in the posterior occipital poles being the main sources of P 100 in association with the x-cells in the centre of the retina.

**Keywords:** Blindness; visual evoked potentials; head injury; regional cerebral blood flow.

Cortical blindness is characterized by the loss of vision in patients with normal pupillary reflexes and ophthalmic fundi. Aetiological factors include trauma<sup>9, 11, 13</sup>, infarction<sup>23</sup>, embolization<sup>10</sup>, migraine<sup>3, 12, 14</sup>, cardiac arrest<sup>17</sup>, meningitis<sup>8</sup> and hydrocephalus with a malfunctioning shunt<sup>6</sup>. Prognoses vary<sup>1</sup>.

We report the Single Photon Emission Computed Tomograms (SPECT) and the Pattern Reversal Visual Evoked Responses (PRVERs) before and after the recovery of cortical blindness in two patients.

### Patient Reports

*Patient A* (CGMH: 3209793)

A 36 year-old motorcyclist with 2 children on board had a brake failure and bumped her motorcycle into the rear of a car, throwing herself over the road. While the children sustained skin abrasions the patient remained drowsy for 7 hours. As she regained conscious-

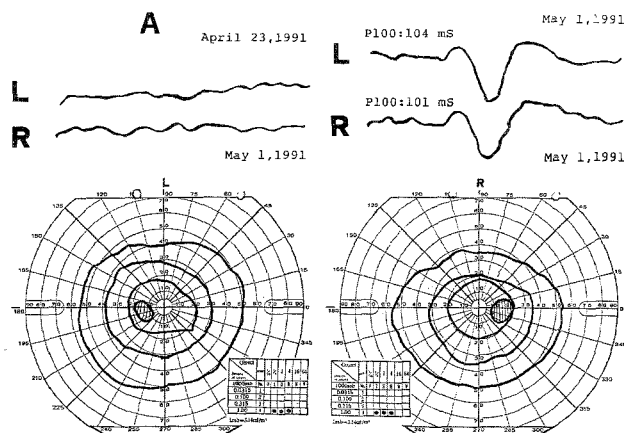


Fig. 1. Abnormal PRVERs during blindness and normal PRVERs after recovery of useful vision despite the constricted visual fields. *A*: Patient A. *L*: left eye. *R*: right eye. Checkerboard, 2 Hz

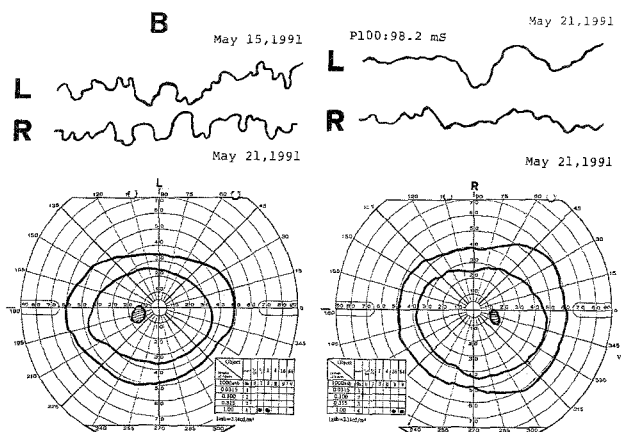


Fig. 2. Abnormal PRVERs during blindness and normal PRVERs after recovery of useful vision despite the constricted visual fields. *B*: Patient B. *L*: left eye. *R*: right eye. The hyperopia in the right eye was not corrected. Checkerboard, 2 Hz

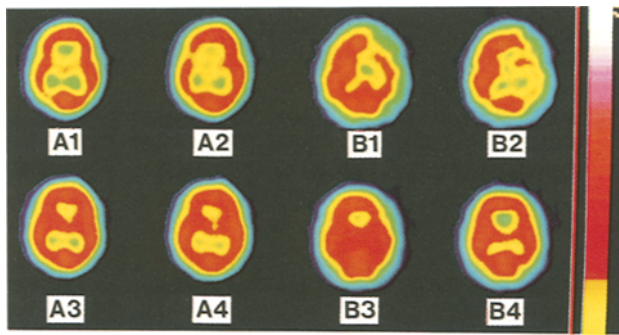


Fig. 3. A 1, A 2 and B 1, B 2: SPECT before recovery of useful vision in patient A and B respectively. A 3, A 4: 3 days and B 3, B 4: 6 days after the first SPECTs respectively, all being normal. Methods: Technetium-99m hexamethyl-propyleneamine oxime 15 mCi Cerebral Blood Flow Planar (Elscont apex 609 RG), slice thickness: 6 mm

ness all she saw was black and all she remembered was the moment she put on the brake. On admission she complained of mild headache, no past history of migraine. A laceration of the forehead, bilateral raccoon eyes and a subgaleal haematoma in the occiput were evident. She remained calm, identified objects by touch but could not do so by sight. The direct and consensual light reflexes in both eyes were present, the fundi and the rest of the neurological examination was normal. Computed Tomography (CT) scans were normal and the PRVERs were absent (Fig. 1, April 23, 1991) 14 and 31 hours after the accident respectively. The patient perceived light at 50 hours and SPECT at 54 hours revealed normal blood flow in the visual cortices (Fig. 3, A 1-A 2). At 74 hours she counted fingers and saw the patterns in a red tie but could not read Chinese characters because of blurring of vision. Confrontation test demonstrated tunnel vision. PRVERs at 79 hours were normal and nearly identical to those recorded 1 week (Fig. 1, May 1, 1991) and 2 weeks later. Having been able to read and understand Chinese characters at 98 hours, the patient reported that in paroxysms she saw her husband walk from one side to the other although she knew her husband actually was standing in front of her. The visual hallucination disappeared after closing eyes for 1 minute and, within 2 days, ceased. Although she had enjoyed rapidly improving visual fields since the recovery of light perception, the perimetry did not demonstrate normal fields until 3 weeks after the accident.

#### Patient B (CGMH: 735627)

A 43-year-old labourer presented with incapacitating spastic gait and deltoid muscle fasciculation bilaterally for 1 year. He had had right lens extraction because of trauma. No peripheral vascular disease or diabetes mellitus was evident. Myelograms and CT scans revealed 3 herniated discs of the 4th, 5th, 6th and 7th cervical vertebrae which were removed through an anterior approach from the right side of the neck and fused with 3 bone grafts. The neuroanaesthetist observed no abnormality during the procedure. In the recovery room the patient developed tachycardia, excessive sweating, nystagmus and paroxysmal spasms of all limbs yet able to obey commands when less agitated; lateralizing signs were absent. When asked he admitted that everything before him was black. The direct and consensual light reflexes of the left pupil as well as the fundi of

both eyes were normal. SPECT scans 44 hours after the operation revealed normal perfusion of the visual cortices and hypoperfusion in the left middle cerebral artery territory (Fig. 3, B 1-B 2). No PRVERs was found at 47 hours (Fig. 2, May 15, 1991). At 49 hours the patient was able to perceive light, read and understand the Chinese characters on the red ruler, tunnel vision being demonstrated by confrontation test, nystagmus was absent and CT scans normal. He identified the key in either of his hands without looking at it. At 70 hours the patient reported that with his left eye he saw a girl in red and a boy in green climbing up and down the intravenous set in front of him and moving to the left and the right. He also reported hearing the voice of a man using foul language, threatening to beat him up. All the hallucinations subsided after the use of Haloperidol for 1 day. The PRVERs at 188 hours were normal in the left eye (Fig. 2, May 21, 1991) and remained so 8 weeks later. Although he had enjoyed rapidly improving visual fields since the recovery of light perception, the perimetry did not demonstrate normal fields until 2 months after the operation. The spastic gait remains unchanged.

#### Discussion

Normal regional blood flow has been documented by SPECT in two patients 5 and 20 hours respectively before they regained the ability to count fingers. These suggest that regional blood flow studies by SPECT might be sensitive enough to serve as a prognostic factor. In the event of cortical blindness after angiography, the finding of regional hypoperfusion indicating visual cortical embolization may justify the use of anticoagulants to lessen the risk of permanent visual loss, provided that haemorrhagic infarction has been excluded by CT.

In patient B the transient hypoperfusion in the left middle cerebral artery territory in the SPECT suggests embolization being the cause of cortical blindness: when hammering the bone grafts home a piece of atherosclerotic plaque in one vertebral artery got dislodged, migrating to the basilar tip<sup>10</sup>, blocking the posterior cerebral arteries for a while, then moving to the left posterior communicating artery and stopping its flow to the middle cerebral artery. The postoperative tachycardia, sweating and agitation in this patient suggest sympathetic "overdischarges" from the ischaemic posterior hypothalamus due to inadequate flow of the thalamoperforating arteries, fed by the posterior cerebral arteries. In patient A bilateral occipital oedema, concussion or contusion<sup>11</sup> as the cause of cortical blindness was not substantiated in the CT and the SPECT scans<sup>19</sup>. Movement of her brain to and fro twice in the anterior-posterior direction was evident by the wounds in the forehead and the occiput. During brain shifts in trauma the posterior cerebral arteries might impinge against the tentorial edges resulting in vasospasm and

transient occlusion, whereas the oculomotor nerves are less susceptible to this type of injury, due to their tentorial insertions. This mechanism contrasts with the traction mechanism<sup>12, 14</sup> in which the oculomotor nerves are more readily exposed to traction injury than the posterior cerebral arteries. The finding of normal regional blood flow in the SPECT before the recovery of useful vision does not weaken the position of "scratch" or border zone hypoxia<sup>17</sup> inducing blindness in this patient because ischaemia of 1–2 minutes could lead to permanent visual loss. It does strengthen however the position of the traumatic spreading cortical depression which tends to occur in younger patients with milder injuries<sup>20</sup>.

While visual hallucinations occurring in both patients, the auditory hallucination only affected patient B whose SPECT showed hypoperfusion in the left middle cerebral artery territory in the presence of normal CT. These findings suggest that auditory hallucinations presumably arising from the temporal lobes could be effected by disturbances of the posterior circulation.

Absence of PRVERs during blindness<sup>2, 4, 8, 18</sup> and rapid recovery of P 100 amplitude with normal latency accompanying tunnel vision were documented in our patients. These findings were consistent with the observation that central vision within 8 to 10 degrees circumference is represented at the posterior limit of the calcarine fissure<sup>5, 22</sup>. Collateral blood supply from the middle cerebral artery ensures its quicker functional recovery from an ischaemic insult. Furthermore the posterior occipital poles are the main sources of P 100<sup>21</sup> in association with the x-cells in the centre of the retina<sup>16</sup>. The possibility exists of having patients with central visual fields good enough to produce PRVERs but not good enough to serve useful functions<sup>2, 15</sup>. This contrasts with the unique patient cited by Celesia *et al.* of complete cortical blindness whose PRVERs were normal and whose visual fields documented to be no more than 2 degrees of the arc<sup>7</sup>.

### Acknowledgements

We thank MS P. Y. Wang, Ms Linda Chang, Ms Yun Shu and MR D. J. Tsai for their kind assistance.

### References

- Aldrich MS, Alessi AG, Beck RW, Gilman S (1987) Cortical blindness: etiology, diagnosis and prognosis. *Ann Neurol* 21: 149–158
- Barnet AB, Manson JJ, Wilner E (1970) Acute cerebral blindness in childhood: six cases studied clinically and electrophysiologically. *Neurology* 20: 1147–1156
- Bodian M (1964) Transient loss of vision following head injury. *NY State J Med* 64: 916–920
- Bodis-Wollner I (1977) Recovery from cerebral blindness: evoked potential and psychophysical measurements. *Electroenceph Clin Neurophysiol* 42: 178–184
- Bramwell B, Bolton JS, Robinson W (1915) Bilateral lesion of the occipital lobes with retention of macular as distinct from panoramic vision. *Brain* 38: 447–472
- Cedzich C, Schramm J, Wenzel D (1990) Reversible visual loss after shunt malfunction. *Acta Neurochir (Wien)* 105: 121–123
- Celesia GG, Archer CR, Kuroiwa Y, Goldfaber PR (1980) Visual function of extrageniculo-calcarine system in man: relationship to cortical blindness. *Arch Neurol* 37: 704–706
- Duchowny MS, Weiss IP, Majlessi H, Barnet AB (1974) Visual evoked responses in childhood cortical blindness after head trauma and meningitis: a longitudinal study of six cases. *Neurology* 24: 933–940
- Eldridge PR, Punt JAG (1988) Transient traumatic cortical blindness in children. *Lancet* 1: 815–816
- Fischer-Williams M, Gottschalk PG, Browell JN (1970) Transient cortical blindness: an unusual complication of coronary angiography. *Neurology* 20: 353–355
- Gjerris F, Mellempgaard L (1969) Transitory cortical blindness in head injury. *Acta Neurol Scand* 45: 623–631
- Greenblatt SH (1973) Posttraumatic transient cortical blindness: association with migraine and seizure diatheses. *JAMA* 225: 1073–1078
- Griffith JF, Dodge PR (1968) Transient blindness following head injury in children. *New Engl J Med* 278: 638–651
- Haas DC, Sovner RD (1969) Migraine attacks triggered by mild head trauma, and their relation to certain post-traumatic disorders of childhood. *J Neurol Neurosurg Psychiatry* 32: 548–554
- Harden A, Pampiglione G (1970) Neurophysiological approach to disorders of vision. *Lancet* 1: 805–809
- Hess CW, Meienberg O, Ludin HP (1982) Visual evoked potentials in acute occipital blindness: diagnostic and prognostic value. *J Neurol* 227: 193–200
- Hoyt WF, Walsh FB (1958) Cortical blindness with partial recovery following acute cerebral anoxia from cardiac arrest. *Arch Ophthalmol* 60: 1061–1069
- Kooi KA, Sharbrough III FW (1966) Electrophysiological findings in cortical blindness. Report of a case. *Electroenceph Clin Neurophysiol* 20: 260–263
- Madsen FF (1990) Regional cerebral blood flow after a localized cerebral contusion in pigs. *Acta Neurochir (Wien)* 105: 150–157
- Oka H, Kako M, Matsushima M, Ando K (1977) Traumatic spreading depression syndrome: review of a particular type of head injury in 37 patients. *Brain* 100: 287–298
- Rietveld WJ, Tordoir WE, Duyff JW (1965) Contribution of fovea and parafovea to the visual evoked response. *Acta Physiol Pharmacol Neerl* 13: 330–339
- Spalding JMK (1952) Wounds of the visual pathway. Part II: the striate cortex. *J Neurol Neurosurg Psychiatry* 15: 169–181
- Symonds C, Mackenzie I (1957) Bilateral loss of vision from cerebral infarction. *Brain* 80: 415–455

Correspondence and Reprints: Dr. Cheuk-Wah Wong, Division of Neurosurgery, Department of Surgery, Chang Gung Memorial Hospital, 199 Tunhwa North Road, Taipei 105, Taiwan R.O.C.