

Brief Report

Reflex Blepharospasm Associated with Bilateral Basal Ganglia Lesion

R. Larumbe, J. Vaamonde, J. Artieda, J. L. Zubieta, and J. A. Obeso

Movement Disorders Unit and Clinical Neurophysiology Service, Department of Neurology and Neuroradiology Unit, Department of Radiology, Clinica Universitaria, University of Navarra Medical School, Pamplona, Spain

Summary: A patient with a bilateral striatal lesion secondary to anoxia presented reflex blepharospasm associated with parkinsonism and dystonia in the limbs. The blink reflex excitability curve was enhanced and the R-2 response prolonged as in patients with essential blepharospasm. The findings in this patient support the notion that blepharospasm may be secondary to basal ganglia dysfunction through abnormal facilitation of reticular formation neurons controlling facial nucleus motoneuron excitability. **Key Words:** Blepharospasm—Blink reflex—Striatal lesion.

Blepharospasm is the involuntary spasmodic closing of the eyelids. It generally occurs spontaneously but may be triggered by external stimuli such as bright light, cold, air, and so forth (1). More rarely, stretching the orbicularis oculi (OO) muscle may elicit blepharospasm (*reflex blepharospasm*). Spontaneous blepharospasm secondary to structural focal lesions has been described in quite a few patients (2–13). Reflex blepharospasm has been described following large cerebral infarction (14), within a family (15), and in more detail in a patient with unknown cause (16). We report a patient with bilateral infarction of the basal ganglia secondary to anoxia during surgery who developed a dystonic–parkinsonian syndrome associated with stretch reflex blepharospasm.

CASE REPORT

A 13-year-old girl with no known personal or familial history of neurological disease had cardiac surgery for supravulvar aortic stenosis in 1989. During surgery, blood pressure was relatively low (systolic 40–60 mmHg) for about 2 h. No other as-

sociated risk factor was known from her history or with relation to the surgical procedure. She was in a coma for 3 days after surgery. On recovering consciousness, neurological examination revealed hypomimia, severe bradykinesia and rigidity in all four limbs, and brief multifocal myoclonic jerks.

Occasionally blepharospasm occurred spontaneously. Any attempt to open the patient's eyes passively or stretch any part of OO with the eyes open led to sustained spasms. Visual threatening also provoked blepharospasm although much less frequently and with quick adaptation. In the following weeks, generalized dystonia became apparent. Computed tomographic brain scan and magnetic resonance imaging (MRI) revealed bilateral symmetrical involvement of the basal ganglia affecting the striatum (putamen and caudate) and lateral globus pallidus (Fig. 1). The brainstem and cerebellum were intact. Routine blood tests and copper, ceruloplasmine, lactic and pyruvic acids, and lysosomal enzymes were all normal.

Electromyographic (EMG) recording with surface electrodes over the OO (Fig. 2) confirmed the occurrence of blepharospasm elicited by rapid and sustained stretching produced by movement of the blunt end of a pin of either the inferior or superior parts of the orbital section of the OO. The blink reflex and its excitability cycle were studied by the

Address correspondence and reprint request to Dr. J. A. Obeso, Department of Neurology, Clinica Universitaria, Apdo. 192, 31080 Pamplona, Spain.

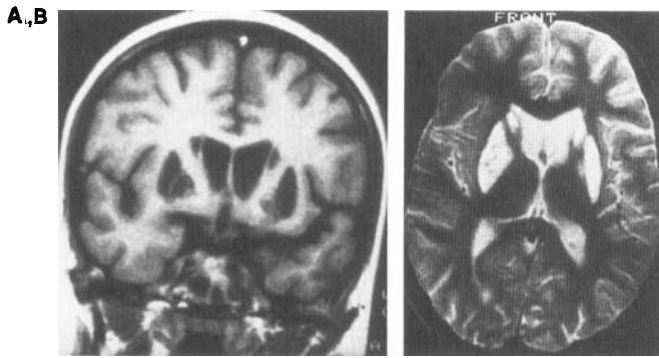


FIG. 1. Cerebral magnetic resonance imaging (MRI) of the patient. A. T-1 (coronal view at the level of the basal ganglia) showing hypoxic infarction (dark signal) of the putamen and head of the caudate nucleus bilaterally and of the external globus pallidus in the right hemisphere. B. Horizontal axial section (T2) showing a similar distribution (high signal intensity) of the lesion.

standard method (17,18). The right supraorbital nerve was electrically stimulated with supramaximal intensity, giving a single stimulus (control) or paired stimuli separated by 20, 50, 100, 150, 200, 300, and 500 ms. Ten unconditioned and conditioned stimuli were given for each point of the excitability curve. Single stimulation evoked a normal R-1 response. The R-2 component had normal latency bilaterally but prolonged duration (260 ms in the patient vs. 30 to 50 ms for normal controls) (Fig. 3). The excitability of the blink reflex was also increased. Thus, the R-2 response was recovered by 50% for an interstimulus interval of 147 ms [normal values for 50% recovery, 920 to 1,200 ms (17-19; authors' personal experience)].

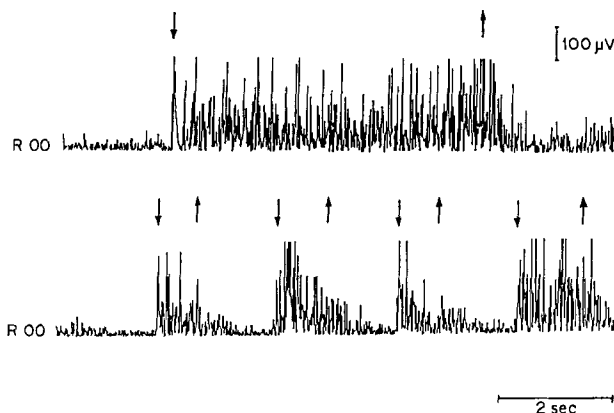


FIG. 2. Electromyographic (EMG) recording from the right orbicularis oculi (R OO) muscle. Sustained stretch of the muscle (starting and ending point indicated by upgoing and downgoing arrows, respectively) elicited a long-lasting spasm (upper half) and short stretches provoked phasic EMG responses (lower half).

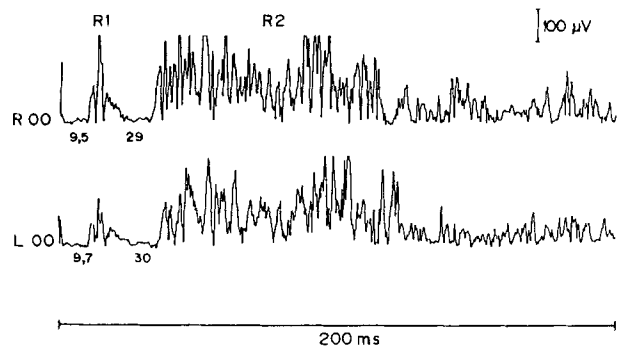


FIG. 3. Blink reflex of the patient after electrical stimulation of the right supraorbital nerve. The latency of the R1 (9.5 and 9.7 ms) and R2 (29 and 30 ms) components is normal but the duration of the R2 is prolonged bilaterally. R, right orbicularis oculi. L OO, left orbicularis oculi.

DISCUSSION

Blepharospasm secondary to lesion of the putamen bilaterally and upper brainstem has been previously documented (2-13). Among those reports, there are a few patients (5-7) whose blepharospasm was noticed to increase following physical attempts by the examiner to open their eyes, but this contingency was not further explored. Reflex blepharospasm was not the only clinical manifestation of striatal infarction in our patient. However, there was no clinical or radiological evidence of lesion outside the lenticular nucleus. It should be admitted nevertheless that anoxia may have damaged other neuronal groups, i.e., the brainstem reticular formation, which could be primarily involved in the origin of blepharospasm. With this limitation in mind, this is the first case of reflex blepharospasm, to our knowledge, associated with a known pathological basis and with physiological documentation.

The clinical and electrophysiological features of the patient here described are identical to the patient reported by Obeso et al. (16). Reflex blepharospasm may be one extreme of the clinical spectrum of blepharospasm and may have a common pathophysiological basis regardless of the cause. Indeed, the capability to aggravate or trigger blepharospasm by external stimuli is well recognized (1,12), and enhanced excitability of the blink reflex is a well-established characteristic of patients with essential blepharospasm and other forms of focal dystonia (18-20).

The R2 response of the blink reflex is mediated by a polysynaptic pathway that goes from the sensory nuclei of the trigeminal nerve through the bulbo-pontino reticular formation before targeting

onto the facial nucleus (21). Blepharospasm and increased excitability of the R2 response have also been described in patients with Parkinson's disease (17). Ballard et al. (22) also observed blepharospasm in patients with parkinsonism secondary to MPTP intoxication. All these data suggest that the basal ganglia exerts a tonic control of the excitability of the blink reflex. Regardless of the cause and associated clinical features, the R-1 response of the blink reflex is normal, and the R-2 is enhanced in patients with blepharospasm. This dissociation indicates a discrete effect of the basal ganglia on brainstem neurons controlling the excitability of the R-2 response. In conclusion, this observation supports the evidence from patients with idiopathic blepharospasm (18–20) suggesting that abnormal functioning of reticular formation neurons may be the ultimate pathophysiological basis of blepharospasm.

Acknowledgment: Ms. M. Mar López and Mrs. Carol Elsdon edited the article for publication.

REFERENCES

1. Jankovic J, Havins WE, Wilkins RB. Blinking and blepharospasm. *JAMA* 1982;248:3160–3164.
2. Jankovic J, Patel SC. Blepharospasm associated with brainstem lesions. *Neurology* 1983;33:1237–1240.
3. Lang AE, Sharpe JA. Blepharospasm associated with palatal myoclonus and communicating hydrocephalus. *Neurology* 1984;34:1522.
4. Sandyk R, Gillman MA. Blepharospasm associated with communicating hydrocephalus. *Neurology* 1984;34:1522–1523.
5. Jankovic J. Blepharospasm with basal ganglia lesions. *Arch Neurol* 1986;43:866–868.
6. Keane JR, Young JA. Blepharospasm with bilateral basal ganglia infarction. *Arch Neurol* 1985;42:1206–1208.
7. Powers JM. Blepharospasm due to unilateral diencephalon infarction. *Neurology* 1985;35:283–284.
8. Day TJ, Lefroy RB, Mastaglia FL. Meige's syndrome and palatal myoclonus associated with brainstem stroke. A common mechanism? *J Neurol Neurosurg Psychiatry* 1986;48:1324–1325.
9. Leenders KL, Frackowiack RSJ, Quinn N, Brooks D, Sumner D, Marsden CD. Ipsilateral blepharospasm and contralateral hemidystonia and parkinsonism in a patient with a unilateral rostral brainstem–thalamic lesion: structural and functional abnormalities studied with CT, MRI and PET-scanning. *Mov Disord* 1986;1:51–58.
10. Schiffman JJ, Fletcher WA, Hoyt WF, Maitland CG. Blepharospasm, sustained upgaze after Bell's phenomenon, and downgaze palsy from mesodiencephalic infarctions. *Neurology* 1986;36(suppl 1):250.
11. Palakurthy PR, Iyer V. Blepharospasm accompanying hypoxic encephalopathy. *Mov Disord* 1987;2:131–134.
12. Grandas F, Elston J, Quinn N, Marsden CD. Blepharospasm: a review of 264 patients. *J Neurol Neurosurg Psychiatry* 1988;51:767–772.
13. Poewe W, Benke TN, Felber ST, Aichner F. Symptomatic blepharospasm accompanying the paramedian diencephalic syndrome: report of a case. *Behav Neurol* 1989;2:143–151.
14. Fisher CM. Reflex blepharospasm. *Neurology* 1963;13:77–78.
15. Irvine AR, Daroff RB, Sanders MD, Hoyt WF. Familial reflex blepharospasm. *Am J Ophthalmol* 1968;65:889–890.
16. Obeso JA, Artieda J, Marsden CD. Stretch reflex blepharospasm. *Neurology* 1985;35:1378–1380.
17. Kimura J. Disorder of interneurons in parkinsonism. The orbicularis oculi reflex to paired stimuli. *Brain* 1973;96:87–96.
18. Nakashima K, Rothwell JC, Thompson PD, et al. The blink reflex in patients with idiopathic torsion dystonia. *Arch Neurol* 1990;47:413–416.
19. Tolosa E, Montserrat L, Bayes A. Blink reflex studies in focal dystonias: enhanced excitability of brainstem interneurons in cranial dystonia and spasmodic torticollis. *Mov Disord* 1988;3:61–69.
20. Berardelli A, Rothwell JC, Day BL, Marsden CD. Pathophysiology of blepharospasm and oromandibular dystonia. *Brain* 1985;108:593–608.
21. Ongerboer De Visser BW, Kuypers HGJM. Late blink reflex changes in lateral medullary lesions. An electrophysiological and neuro-anatomical study of Wallenberg's syndrome. *Brain* 1978;101:285.
22. Ballard PA, Tetrud JW, Langston JW. Permanent human parkinsonism due to 1-methyl-4-phenyl-1,2,3,6-tetrahydropyridine (MPTP): seven cases. *Neurology* 1985;35:949–956.