

# Acquired agraphia caused by focal brain damage \*

Steven W. Anderson, Jeffrey Saver, Daniel Tranel  
and Hanna Damasio

*The University of Iowa College of Medicine, Iowa City, USA*

Motor and linguistic aspects of writing were evaluated in 31 subjects with focal damage in 1 of 3 regions of the left hemisphere: (1) dorsolateral frontal lobe sparing primary motor cortex (group FL), (2) parietal lobe (group PL), or (3) temporal lobe (group TL). A standard procedure was used to evaluate writing for grapheme formation, spatial arrangement, spelling, word selection, grammar, and perseveration. It was predicted that agraphia would be observed in all 3 groups, and that the most severe impairments would be associated with frontal lobe damage, particularly in aspects of writing dependent on sequencing (grapheme formation, spelling, and grammar). It was found that agraphia was common in all groups, particularly in the acute epoch, and that all groups showed considerable recovery of writing by the chronic epoch. Few differences were found between groups. However, the FL group was impaired on spelling and grammar relative to the PL group in the acute epoch and impaired on grammar relative to the TL group in the chronic epoch. The findings are consistent with the notion that writing relies on a distributed neuroanatomical network, which acts in concert to link fragments of visuomotor activity with component linguistic elements.

The ability to communicate and create through the use of handwriting is a multifaceted and uniquely human behavior which relies on a distributed neuroanatomical network. As such, writing is susceptible to disruption by a variety of neuropathological factors. The clinical significance of acquired writing impairments has long been recognized, and the term 'agraphia' was used as early as the 1860's in

*Correspondence to:* S.W. Anderson, Dept. of Neurology, Division of Behavioral Neurology & Cognitive Neuroscience, The University of Iowa College of Medicine, Iowa City, IA 52242, USA.

\* Supported by NINDS grant PO1 NS19632.

separate works by Benedikt (1865) and by Ogle (1867) to refer to impairments of handwriting caused by brain dysfunction. By the beginning of the 20th century, Wernicke (1886) and Dejerine (1891) had provided descriptions of agraphia which continue to influence current work. Despite this lengthy history as a topic of inquiry, the neural underpinnings of agraphia are not yet well understood.

There are several factors which have contributed to this situation. Perhaps foremost is the conflated nature of the writing process, which requires integration of several dissociable cognitive functions, including components of memory, language, perception, and movement. The final product may be rendered defective by dysfunction in any of the various subcomponents, which could potentially implicate many parts of the cerebral cortex.

Research on the neural basis of agraphia has also been constrained by the limited number of research subjects appropriate for addressing issues of anatomical localization. Agraphia usually occurs in the context of brain dysfunction caused by relatively non-circumscribed neurological conditions, e.g., dementia, traumatic brain injury, metabolic encephalopathy, or space occupying lesions such as tumors (Chedru and Geschwind 1972; Leischner 1969). Involvement of multiple brain areas and incomplete ability to visualize the areas of neural dysfunction make it virtually impossible to relate acquired impairments of handwriting to specific areas of brain damage in such cases (Anderson et al. 1990b; Damasio and Damasio 1989). Animal models make an important but obviously limited contribution to questions of anatomical localization of agraphia. Lesion studies in nonhuman primates have helped define the critical role of premotor cortex in the execution of complex movement sequences (e.g., Deuel 1977), but will never address fully the uniquely human, linguistic aspects of writing.

Lesion studies in humans, when applied with appropriate attention to potential methodological pitfalls, provide a means of studying the component cognitive processes and neuroanatomical systems involved in writing. The development of improved neuroimaging techniques has provided ever-increasing opportunities for specifying the neural underpinnings of agraphia. However, this has been a relatively recent development, whose potential is just beginning to be realized. Current knowledge of agraphia is based largely on a limited number of case reports and small group studies, often lacking precise anatomical characterization.

The literature on agraphia is rife with classification schemes that distinguish various forms of writing impairment. A partial list of the more common terms used to refer to subtypes of agraphia would include: alexia with agraphia, amnesic, apraxic, constructional, frontal, ideational, jargon, linguistic, literal, motor, parietal, phonological, primary, pure, secondary, semantic, spatial, subcortical, transcortical, and verbal. Rather than emphasizing agraphia subtypes or diagnostic categories, the present study attempts to relate multiple features of writing, such as grapheme formation, spelling, and grammar, to neuroanatomical variables, and to use this information to shed light on the neural-cognitive basis of writing. Before describing the study, we will briefly consider selected neuropsychological findings which bear on the role of focal damage in the left temporal, parietal, and frontal lobes in the etiology of agraphia. The reader is referred to the following for more comprehensive reviews of the literature on agraphia: Bub and Chertkow (1988), Leischner (1969), and Roeltgen (1985).

*Temporal lobe damage and agraphia:* Temporal lobe lesions often result in impairments of auditory-vocal language, which may be accompanied by impairments of reading and writing. Damage to the posterior superior temporal area is associated with a constellation of language defects which commonly fall under the rubric of Wernicke's aphasia (Benson 1989; Damasio 1992). Receptive language abilities, including aural and reading comprehension, are typically the most severely impaired. Speech is produced fluently and without effort, and many aspects of spoken language are relatively unaffected, such as prosody, volume, articulation, and phrase length. However, spoken output is characterized by paraphasic errors, including word substitution, phonemic errors, and neologistic errors. There is often a notable paucity of substantive words, such as nouns. Goodglass and Hunter (1970) found that a Wernicke's aphasic made more errors in speech than in writing, but the writing impairments in Wernicke's aphasia appear to more or less parallel the impairments of spoken language (Kaplan and Goodglass 1981; Roeltgen 1985).

Virtually every aspect of writing has a sequential component. The formation of individual letters requires sequential activation of a series of perceptuo-motor fragments; the formation of a word involves sequential production of letters, and so on. Extensive left temporal

lobe damage can result in impairments in aspects of representational sequencing (i.e., using signs from American Sign Language), when the lesion includes destruction of the anterior mesial temporal lobe and connections to the frontal lobe (Anderson et al. 1992). As discussed below, there is also considerable evidence suggesting that the frontal lobe plays an important role in sequential behavior.

*Parietal lobe damage and agraphia:* The parietal lobe includes multi-modal association cortex, with input from primary visual, auditory, and tactile cortices. Not surprisingly, several types of agraphia have been described in association with left parietal lobe damage. Apraxic agraphia is characterized by poorly formed graphemes, and sometimes occurs in the context of ideomotor apraxia (Heilman et al. 1973; Heilman et al. 1974; Valenstein and Heilman 1979). Ideomotor apraxia refers to impairment of the ability to carry out purposeful hand movements, such as those required to perform gestures (e.g., hitchhiking or saluting) or to manipulate objects such as tools. Other cases have been described in which poorly formed graphemes occurred in the context of normal praxis (Margolin and Binder 1984; Roeltgen and Heilman 1983). In virtually all cases of apraxic agraphia, the ability to produce nonverbal constructions, such as drawings, is defective as well. The ability to spell orally is preserved.

A second type of agraphia is often referred to as parietal agraphia, or alexia with agraphia, which involves letter distortion and impaired spelling, together with alexia in the absence of significant aphasia. First described by Dejerine (1891), this impairment is usually associated with damage to the angular or supramarginal gyrus. Also, a relatively isolated form of agraphia involving paraphasias and neologisms has been described following superior parietal lobe lesions (reviewed by Vignolo 1983). Damage to the nondominant parietal lobe may result in spatial disorganization in writing, but not in linguistic defects. This typically occurs in the context of generalized visuospatial defects and left side neglect.

Much of the recent neuropsychological research on agraphia has focused on patterns of spelling errors while writing single words (see Roeltgen, 1985, for discussion). Among these patterns are: (1) phonological agraphia, consisting of an inability to spell pronounceable nonwords despite good spelling of legitimate words, and (2) lexical or surface agraphia, consisting of an inability to spell orthographically

ambiguous or irregular words despite ability to spell regular words and nonwords to dictation. Phonological agraphia may occur in the setting of various aphasic syndromes, including Wernicke's, Broca's, transcortical sensory, and others, and has in some cases been linked to damage of the left supramarginal gyrus or insula (e.g., Roeltgen et al. 1983). Lexical agraphia may also occur in the setting of various aphasias, and has been linked in part to angular gyrus lesions or the parieto-occipital junction (Roeltgen and Heilman 1984).

*Frontal lobe damage and agraphia:* There are several reasons to believe that, within the distributed neuroanatomical system which provides the foundation for writing, a particularly crucial role is played by frontal cortex, specifically the left dorsolateral frontal cortex. With obvious relevance to writing are not only the primary and association motor cortex for the dominant hand, but also afferent and efferent connections with posterior language-related cortices, as well as projections to subcortical nuclei, the cerebellum, and brainstem nuclei.

Within the primary motor cortex (area 4), the hand has a disproportionately large representation, and it is known from microelectrode stimulation studies that individual muscles are represented at more than one site within this area (for further discussion, see Hepp-Reymond 1988). While the size of the primary motor cortex remains constant in proportion to body weight across primate species, the size of the premotor area increases sixfold from the macaque monkey to humans. Clearly this region warrants consideration as part of the anatomical system underlying a uniquely human motor activity such as writing. Also of potential importance in writing is the higher order association cortex situated anterior to the premotor region, referred to as the prefrontal cortex (reviewed by Fuster 1989). Damage to this morphologically and functionally complex area may affect certain organizational or planning aspects of writing.

Before describing the agraphias associated with left dorsolateral frontal lesions, we will consider two other cognitive impairments which result from damage to this region, and which may be of importance for understanding agraphia. The first has to do with the ability to plan and perform sequential behaviors. As noted earlier, writing is a highly sequential behavior, and there is considerable evidence showing that patients with frontal lobe damage have impair-

ments on tasks which require the planning and execution of a sequence of responses. For example, learning to maneuver through a spatial maze requires that a sequence of behaviors be performed in a particular order, and subjects with frontal lobe lesions have been found to be defective in various maze learning tasks (e.g., Porteous 1965; Milner 1965; Canavan 1983). Also, Shallice (1982) found that patients with lesions involving the left frontal lobe were impaired on the Tower of London task, which requires the planning of the optimal order of a sequence of simple moves.

Petrides and Milner (1982) contrasted the effect of lesions in the frontal lobe with the effect of lesions in the temporal lobe on self-ordered tasks that require the organization of a sequence of pointing responses. Patients with frontal lobe excisions had significant impairments in all sequential tasks, whereas the patients with temporal excisions either had no impairment or, when their lesions encompassed the hippocampus, exhibited material-specific deficits. It is of interest that the patients with left frontal lobe excisions were impaired in both verbal and nonverbal tasks, but patients with right frontal lobe excisions were impaired only in nonverbal ones, suggesting left hemisphere dominance for the programming of voluntary actions.

The second cognitive impairment which has been related to frontal lobe damage and which may provide clues to understanding agraphia is the guidance of behavior on the basis of contingent associations. This refers to the selection of specific behaviors from a repertoire on the basis of changing stimulus conditions. For example, Petrides (1982, 1985) has investigated, in both nonhuman primates and human subjects with frontal lobe ablations, the ability to select, from a number of possible alternative responses, the correct response given the current stimulus configurations. Patients with unilateral frontal lobe excisions were impaired, relative to patients with temporal lobe excisions, on tasks which required the subject to point to different locations or display various hand shapes in response to specific stimuli. These tasks involve selection of spatial locations and distinct movements, both of which are relevant to writing. Many of the component behaviors involved in writing are contingent on the context in which they are produced. For example, the form and position of a letter are influenced by the letters which precede and follow it, and grammatical rules require observation of specific relationships among words.

The study of agraphia associated with dorsolateral frontal damage has been limited by the fact that these lesions usually cause motor impairment of the dominant arm and hand. In this context, three types of agraphia have been described following damage in this area. Two of these occur in the setting of Broca's aphasia: (1) an agrammatic agraphia, in which letters and words are well formed, but written sentence structure is agrammatic, and (2) an agraphia characterized by poor grapheme production and impaired spelling (Goodglass and Kaplan 1981). The third type of agraphia is associated with lesions in the superior aspect of the left premotor cortex, referred to as 'Exner's area', after his description of 5 cases with lesions in this area, all of whom displayed isolated agraphia (Exner 1881). Lesions in Exner's area typically result in defective grapheme formation, which may occur in isolation or in the context of alexia (Anderson et al. 1990a; Eskridge and Parkhill 1896; Gordinier 1899; Hodges 1991).

In sum, focal damage to each of the left temporal, parietal, and frontal regions has been associated with agraphia, and lesion location appears to at least partially determine the form of the writing defect. There also appears to be considerable overlap in the types of writing impairments associated with damage to these various anatomical regions. Published case reports and clinical experience indicate that the writing impairments in any one case are often multifaceted. Although studies of agraphia typically emphasize specific elements of writing impairment, it is often noted that several aspects of writing were impaired. It is also of interest that studies of agraphia associated with focal brain lesions have often been conducted during the first few weeks after onset. This is a period typically marked by ongoing behavioral and neuronal recovery and resolution of temporary dysfunction.

In light of the fact that descriptions of agraphia associated with focal brain lesions tend to be based on a limited number of non-standard case reports and small groups, often studied without modern neuroimaging techniques, we have begun to profile systematically several features of agraphia associated with focal brain lesions.

In this study, we formed subject groups on the basis of neuroanatomical criteria and then evaluated handwriting samples according to a standard procedure. There were two primary purposes of this investigation. First, we wanted to test the hypothesis that damage to

left frontal cortex results in relatively severe agraphia, with specific impairments in grapheme formation and linguistic elements dependent on contingent sequencing (i.e., spelling and grammar). The second purpose was to examine a standardized data base of handwriting impairments associated with various focal lesions, in order to address issues such as intersubject consistency and recovery of function.

## Method

The study involved 31 adult subjects retrieved from our data base. Criteria for selection included a single left hemisphere lesion caused by stroke, surgical resection, or viral encephalitis. Subjects with hemiparesis of the dominant hand were excluded. It was required that the subjects had normal developmental histories and had acquired the brain damage in adulthood. All subjects had at least an eighth grade education, and most had completed high school. All were right handed as determined by the Geschwind-Oldfield questionnaire (Oldfield 1971). Subjects with a history of developmental learning disability, neurologic disease other than the single lesion, or psychiatric disorder were excluded.

Three subject groups were defined on the basis of lesion location within the left hemisphere: (1) dorsolateral frontal lobe sparing<sup>1</sup> primary motor cortex ( $n = 14$ ; referred to as FL), (2) parietal lobe sparing frontal and temporal areas ( $n = 7$ ; referred to as PL), and (3) temporal lobe sparing frontal and parietal areas ( $n = 10$ ; referred to as TL). Twenty-three subjects (10 FL, 5 PL, and 8 TL) were studied in both the acute epoch (1–3 weeks post-onset) and the chronic epoch (3 months or more post-onset); 2 subjects (1 FL and 1 PL) were studied only in the acute epoch, and 6 subjects (3 FL, 1 PL, and 2 TL) were studied only in the chronic epoch.

Two methods were used for the neuroanatomical study. The first was based on analysis of computerized tomography (CT) and magnetic resonance (MR) images according to our standard procedures (Damasio and Damasio 1989). The method calls for patient identification to be masked in all film transparencies, and for investigators blind to the patient's neuropsychological status to select an appropriate template system for plotting of the areas of abnormal signal, and chart the position of those images on a standard protocol. In addition, several images were analyzed by means of a newly developed three-dimensional voxel reconstruction procedure also using MR images (Damasio and Frank 1992). The anatomical studies were based on images obtained at least three months after the neurologic event, because the areas of abnormal signal on acute CT and MR do not necessarily correspond to areas of neural dysfunction (Damasio and Damasio 1989). It can be stated with relative certainty that the areas of abnormal signal on the chronic images correspond to areas

<sup>1</sup> Sparing is defined as less than 25% involvement of immediately adjacent anatomical subregions (Damasio and Damasio 1989).



of dysfunction in both the acute and chronic epochs. But, it is important to keep in mind that temporary dysfunction of additional regions in the acute epoch might have existed.

Subjects had completed standardized measures of nonverbal visuoconstructional ability and language, including: the Block Design Subtest from the Wechsler Adult Intelligence Scale-Revised (WAIS-R) (Wechsler 1981), Rey-Osterrieth Complex Figure Test (Lezak 1983), and the Multilingual Aphasia Examination (MAE) (Benton and Hamsher 1978). Additionally, each subject was requested to produce 4 written sentences. Two sentences were written to dictation and 2 were generated by the subject. No time constraints were placed on the writing tasks. Six dependent measures were obtained from each writing sample: (1) grapheme formation, (2) spatial arrangement, (3) word selection, (4) spelling, (5) grammatical form, and (6) perseveration. Each of these variables consisted of a score based on a Likert rating scale ranging from 1 (normal) to 7 (severely defective). Sample items from the writing scale are presented in fig. 1. Scores for grapheme formation, spatial arrangement, spelling, and perseveration were based on combined ratings of writing to dictation and spontaneous writing. Scores for word selection were based on writing to dictation only, and scores for grammatical form were based on spontaneous writing only. Writing samples were evaluated independently by 2 raters according to a standard procedure. Raters were blind to the subjects' neuroanatomical status and to each other's ratings. Pearson correlations revealed good inter-rater reliabilities (in the range of 0.80 to 0.89), and the mean scores of the two raters were used for the analyses.

## Results

To determine if FL damage resulted in relatively severe agraphia, differences between the FL group and the PL and TL groups on each of the variables were assessed with one tail *t*-tests. In the acute epoch, there were no significant differences between the FL group and the PL group. However, the FL group was impaired relative to the TL group on spelling (FL  $\bar{x} = 5.8$ ,  $SD = 1.3$ ; TL  $\bar{x} = 3.6$ ,  $SD = 1.3$ ,  $p = 0.009$ ), and grammatical form (FL  $\bar{x} = 5.7$ ,  $SD = 1.5$ ; TL  $\bar{x} = 3.6$ ,  $SD = 1.6$ ,  $p = 0.007$ ). In the chronic epoch, there was a trend toward the FL group being impaired relative to the PL group on grammatical form (FL  $\bar{x} = 3.5$ ,  $SD = 1.5$ ; PL  $\bar{x} = 2.0$ ,  $SD = 1.4$ ,  $p = 0.048$ ). There were no significant differences between the FL group and the TL group in the chronic epoch. There were no significant differences between the PL and TL groups in either the acute or chronic epoch. As illustrated in fig. 2, there were nonsignificant trends suggesting poorer grapheme formation by the FL group. In contrast to clinical lore regarding a specific relationship between FL damage and perseveration, no differences were found between groups on this measure.

### *Acute-chronic dimension*

A theme which runs throughout the findings is that, for all groups and all variables, the most severe writing impairments were seen in the acute epoch. Most

**A. INDIVIDUAL GRAPHEME FORMATION:**

1	2	3	4	5	6	7
Normal			Approx. 50% of letters recognizable			No letter- like characters

- 1--No errors.  
 2--< 10% malformed letters.  
 3--10-40% malformed letters.  
 4--40-60% malformed letters.  
 5--60-99% malformed letters.  
 6--Letter-like characters, but no legible letters.  
 7--No letter-like characters.

For this scale, attend only to *grapheme formation*. Do not penalize subject for spelling errors, missing letters, etc.

**B. GRAMMATICAL FORM:**

1	2	3	4	5	6	7
Well preserved grammar			Some preservation of major sentence elements			No word sequences

- 1--Two or more sentences demonstrating variety or complexity of grammatical constructions.  
 2--Two or more sentences produced without grammatical errors.  
 3--At least one sentence which is not simplistic (e.g., subject-verb-object), and which is without grammatical errors.  
 4--All sentences have grammatical errors or are simplistic (e.g., subject-verb-object).  
 5--At least one identifiable sentence, which may contain grammatical errors.  
 6--At least one meaningful word sequence, but no identifiable sentences.  
 7--No meaningful word sequences.

Fig. 1. Sample items from the writing evaluation scale: A: Individual grapheme formation, and B: Grammatical form.

subjects were able to perform the writing tasks with limited difficulty and error in the chronic epoch. However, the subjects' informal self-reports suggested that even those with the most complete recovery experienced chronic changes in their writing, such as reduced speed and a need for greater concentration. For the 23 subjects evaluated in both acute and chronic epochs, measures of recovery were obtained by subtracting scores from the chronic evaluation from scores obtained in the acute evaluation. These scores suggested that for some aspects of writing, frontal lobe damage may have been associated with greater improvement between the first and second evaluations than were parietal lobe or temporal lobe damage. However, there was considerable variability within each group. For example, on grapheme formation, the mean

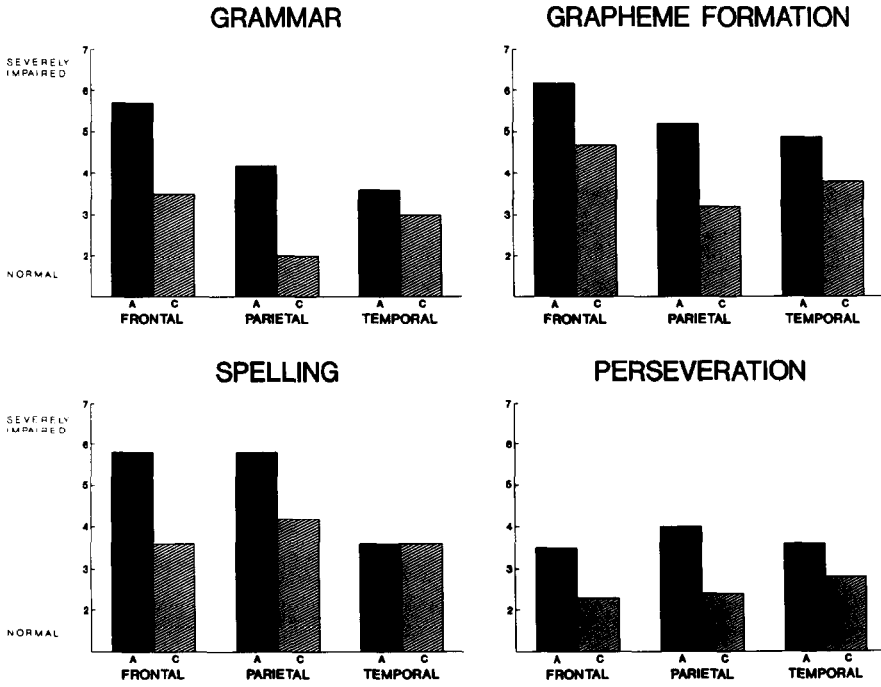


Fig. 2. Mean group performances in grammar, grapheme formation, spelling, and perseveration. A = Acute epoch; C = Chronic epoch.

change scores and standard deviations were as follows: FL  $\bar{x} = 1.75$ ,  $SD = 2.25$ ; PL  $\bar{x} = 0.67$ ,  $SD = 0.58$ ; TL  $\bar{x} = 0.63$ ,  $SD = 1.69$ . This trend also was evident for grammar (FL  $\bar{x} = 2.88$ ,  $SD = 1.46$ ; PL  $\bar{x} = 2.33$ ,  $SD = 2.08$ ; TL  $\bar{x} = 1.13$ ,  $SD = 1.36$ ). When multiple regression was used to control for initial severity of defects, lesion location did not account for a significant portion of the variance in change scores.

### *Pure agraphia*

No subject had 'pure agraphia'. In all cases, agraphia was accompanied by some degree of impairment in other aspects of language or visuoconstructional ability. Examining the relationships between the writing variables and performances on the MAE subtests, it was found that written grammar was correlated with MAE Reading Comprehension ( $r = 0.52$ ,  $p = 0.001$ ) and Aural Comprehension ( $r = 0.46$ ,  $p = 0.001$ ). No other writing variables were correlated with the MAE scores. None of the writing variables were significantly correlated with measures of visuoconstruction. For example, the correlation between WAIS-R Block Design and grapheme formation was 0.23 ( $p = 0.07$ ).

## ACUTE

## WRITING TO DICTATION

SHE CAN'T SEE THEM.

She come

TAKE THIS HOME.

The ~~go~~ over

## SPONTANEOUS WRITING

1. She is watching

## CHRONIC

## SPONTANEOUS WRITING

I want to take Child Development and behavior of disability and (flunk<sup>SP</sup> Keebley) behavior. And how to control these types of behaviors.

Fig. 3. Writing sample from case 1.

*Illustrative cases*

Two cases are presented to help illustrate the nature of the writing impairments and the neuropsychological context in which these occurred. Both cases demonstrated substantial recovery in the months following onset of agraphia. However, unlike the majority of subjects, these patients were left with significant long-term writing impairments. Case 1 (RS1198) was a 28-year-old woman with a high school education who was studying to be a nurse when she suffered an infarction in the left premotor cortex. Examples of her writing are presented in fig. 3, and a voxel reconstruction of the brain based on thin-cut volume acquisition MR is presented in fig. 4. She initially had a moderately severe Broca-type aphasia and mild impairments of nonverbal visuoconstructional ability. Writing in the acute epoch was extremely slow and effortful, and her written output was quite limited. Graphemes were often poorly formed, and there were frequent spelling errors. She was virtually unable to form meaningful sequences of words. Three years after the event, speech remained hesitant, but was without paraphasic errors. Her nonverbal visuoconstructional abilities were within normal limits. Writing was still slow and effortful, but improved from the acute epoch. She wrote meaningful sentences, but continued to make frequent grammatical and spelling errors.

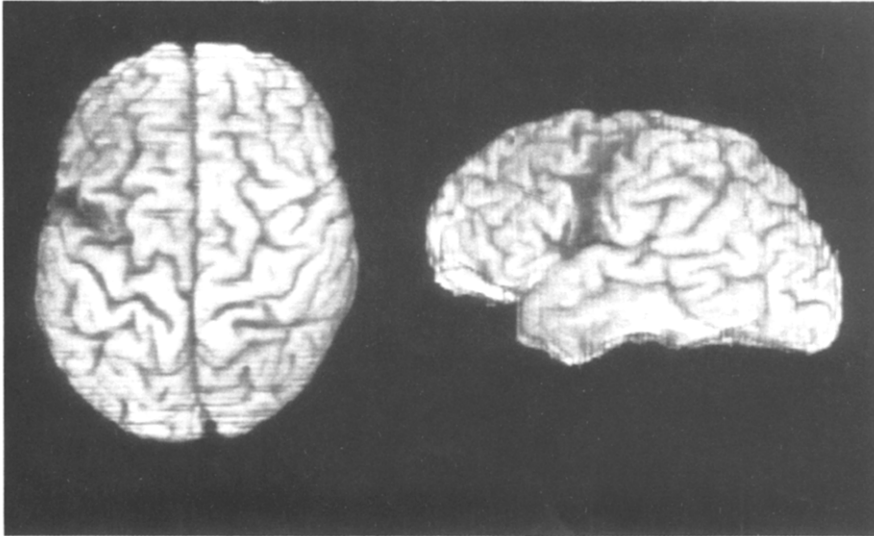


Fig. 4. Brain of case 1 reconstructed from 124 1.5 mm thick coronal MR sections. On the left is a superior view and on the right is a lateral view. The lesion is in the anterior half of the precentral gyrus and the posterior segment of the frontal operculum, as well as the middle frontal gyrus. The posterior half of the precentral gyrus as well as the banks of the central sulcus are intact, in keeping with the lack of motor deficits.

Case 2 (OP1564) was a 66-year-old woman with a 10th grade education who was employed as a small business manager. She suffered an intracerebral hemorrhage in the posterior aspect of the left temporal lobe. Examples of her writing are presented in fig. 5, and the voxel reconstruction of the brain is presented in fig. 6. Initially, her speech was fluent, but contained occasional semantic paraphasic errors. Aural and reading comprehension were defective, as was nonverbal visuoconstructional ability. Her writing was relatively effortless, with good grapheme formation and meaningful sentences, but was notable for spelling errors and perseveration. One year after the event, her speech was improved, but she continued to show selective impairments of auditory-vocal language (i.e., mild impairments of aural comprehension and naming) and alexia. Nonverbal visuoconstructional ability was within normal limits. Her writing remained notable for spelling errors which often had a perseverative quality.

## Discussion

Previous studies have indicated that agraphia may result from damage to various regions within the left hemisphere. Using a standard behavioral assessment procedure in a group of subjects with

**ACUTE****SPONTANEOUS WRITING**

*O the clove*  
*I ned to get groceries today*

**CHRONIC****WRITING TO DICTATION**

**SHE CAN'T SEE THEM.**

*Shee cant see them*

**THE BARN SWALLOW CAPTURED THE PLUMP WORM.**

*the barn swallo a plump worme*

**SPONTANEOUS WRITING**

*I love to go fishing*  
*we love to play in the snow*

Fig. 5. Writing sample from case 2.

well-defined focal brain lesions, the current study demonstrated that agraphia can result from focal damage to each of the left frontal, temporal, and parietal areas. While frontal lobe damage was associated with somewhat more severe agraphia than was damage to temporal or parietal areas, the differences between these anatomically defined groups generally were not large. It appears that locus of brain damage interacts with other factors (such as time since onset and individual efforts to compensate for acquired defects) in order to determine patterns of writing impairment. There was variability across subjects with comparable lesions and similarity of defect across subjects with lesions in different areas, as well as considerable recovery from the acute effects of brain damage. It seems that as a culturally transmitted skill which has risen to importance late in brain evolution, the neural circuits underlying writing are far from 'hard wired'.

Clearly, multiple routes can be used to arrive at the final common end point of writing. The present study considered only the ability to

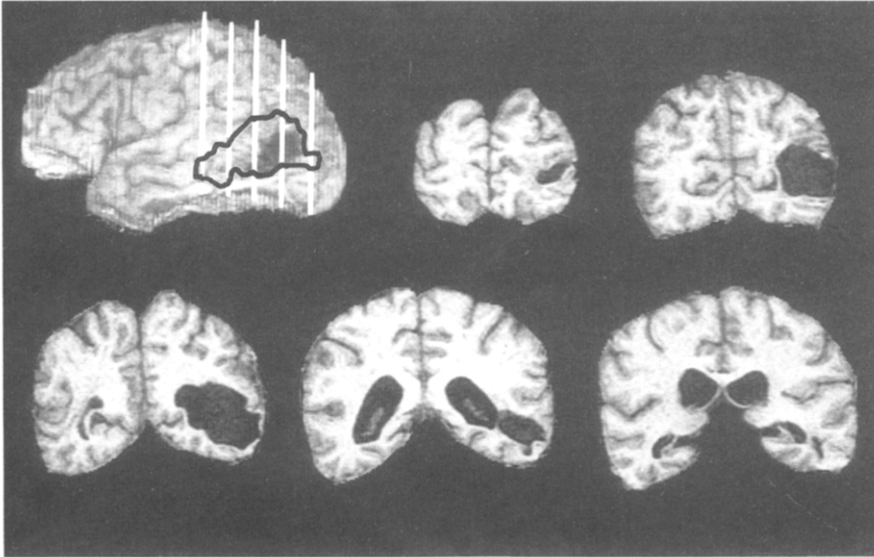


Fig. 6. Brain of case 2 reconstructed from 124 1.5 mm thick coronal MR sections. The lesion involves the posterior aspect of the left temporal lobe. The white vertical lines in the lateral view indicate the planes of the 5 coronal sections which are shown. The dark line in the lateral view depicts the subcortical extension of the lesion projected onto the lateral surface.

recover from agraphia using the preferred hand. Other examples can be found in the ability to learn to write with the nonpreferred hand, or even the feet or mouth if the upper extremities are rendered dysfunctional by damage to the peripheral nervous system or muscles. The capacity to recover from or compensate for the effects of damage to one part of the neural system for writing is consistent with a network that involves both anatomically distributed brain areas and redundancy of cognitive operations.

At a systems level, we would describe writing as the product of sequential coactivation of fragments of visuomotor activity, linked with linguistic knowledge via learned associations based on arbitrary rules. Convergence zones in higher order association cortices, as described by Damasio (1989, 1990), would serve to coordinate activation of elementary component representations in primary and early association cortices. The finding that agraphia rarely or never occurs in isolation suggests that writing depends on a particular use of multipurpose representations.

The region known as Exner's area and its surround in the left dorsolateral frontal lobe is not an isolated writing center, but is well suited to serve as a convergence area for many aspects of the writing process. This area appears to have a unique capacity for coordinated sequential activation of stored representations, and is richly interconnected with primary and association motor cortices for the dominant arm and hand, as well as frontal and posterior language-related cortices. Although this area could serve to coordinate much of the neural activity underlying writing, the system appears to be sufficiently distributed and robust enough so that considerable recovery is usually possible from agraphia arising from focal damage to any one cortical region.

## References

- Anderson, S.W., A.R. Damasio and H. Damasio, 1990a. Troubled letters but not numbers: Domain specific cognitive impairments following focal damage in frontal cortex. *Brain* 113, 749–766.
- Anderson, S.W., H. Damasio and D. Tranel, 1990b. Neuropsychological impairments associated with lesions caused by tumor or stroke. *Archives of Neurology* 47, 397–405.
- Anderson, S.W., H. Damasio, A.R. Damasio, U. Bellugi, E. Klima and J.P. Brandt, 1992. Acquisition of signs from American Sign Language in hearing individuals following left hemisphere damage and aphasia. *Neuropsychologia* 30, 329–340.
- Benedikt, M., 1865. Über Aphasie, Agraphie und verwandte Pathologische Zustände. *Wiener Medizinische Presse* 6, 897–899.
- Benson, F., 1989. 'Aphasia'. In: F. Boller and J. Grafman (eds.), *Handbook of neuropsychology*, Vol. 2. Amsterdam: Elsevier.
- Benton, A.L. and K. Hamsher, 1978. *Multilingual aphasia examination manual*. Iowa City, IA: AJA Associates, Inc.
- Bub, D. and H. Chertkow, 1988. 'Agraphia'. In: F. Boller and J. Grafman (eds.), *Handbook of neuropsychology*, Vol. 1. Amsterdam: Elsevier.
- Canavan, A.G.M., 1983. Stylus-maze performance in patients with frontal-lobe lesions: Effects of signal valency and relationship to verbal and spatial abilities. *Neuropsychologia* 21, 375–382.
- Chedru, F. and N. Geschwind, 1972. Writing disturbances in acute confusional states. *Neuropsychologia* 10, 343–353.
- Damasio, A.R., 1989. Time-locked multiregional retroactivation: A systems-level proposal for the neural substrates of recall and recognition. *Cognition* 33, 25–62.
- Damasio, A.R., 1990. Synchronous activation in multiple cortical regions: A mechanism for recall. *Seminars in the Neurosciences* 2, 287–296.
- Damasio, A.R., 1992. *Aphasia*. *New England Journal of Medicine* 326, 531–539.
- Damasio, H. and A.R. Damasio, 1989. *Lesion analysis in neuropsychology*. New York: Oxford University Press.
- Damasio, H. and R. Frank, 1992. Three dimensional *in vivo* mapping of brain lesions in humans. *Archives of Neurology*, 49, 137–143.



- Dejerine, J., 1891. Sur un cas de cécité verbale avec agraphie suivi d'autopsie. *Mémoires de la Société de Biologie* 3, 197–201.
- Deuel, R.K., 1977. Loss of motor habits after cortical lesions. *Neuropsychologia* 15, 205–215.
- Eskridge, J.T. and C. Parkhill, 1896. Cyst of the brain in the foot of the left second frontal convolution. *Medical News, Philadelphia*, 122–129.
- Exner, S., 1881. Untersuchungen über die Lokalisation der Funktionen in der Großhirnrinde des Menschen. Wien: W. Braumüller.
- Fuster, J.M., 1989. *The prefrontal cortex*, 2nd ed. New York: Raven Press.
- Goodglass, H. and M. Hunter, 1970. A linguistic comparison of speech and writing in two types of aphasia. *Journal of Communication Disorders* 3, 28–35.
- Goodglass, H. and E. Kaplan, 1981. *The assessment of aphasia and related disorders*, 2nd ed. Philadelphia, PA: Lea and Febiger.
- Gordinier, H.C., 1899. A case of brain tumor at the base of the second left frontal convolution. *American Journal of Medical Science* 117, 526–535.
- Heilman, K.M., J.M. Coyle, E.F. Gonyea and N. Geschwind, 1973. Apraxia and agraphia in the left hander. *Brain* 96, 21–28.
- Heilman, K.M., E.F. Gonyea and N. Geschwind, 1974. Apraxia and agraphia in a right hander. *Cortex* 10, 284–288.
- Hepp-Reymond, M.C., 1988. 'Functional organization of motor cortex and its participation in voluntary movements'. In: H.D. Steklis and J. Irwin (eds.), *Comparative primate biology*, Vol. 4. New York: Liss.
- Hodges, J.R., 1991. Pure apraxic agraphia with recovery after drainage of a left frontal cyst. *Cortex* 27, 469–473.
- Kaplan, E. and H. Goodglass, 1981. 'Aphasia-related disorders'. In: M.T. Sarno (ed.), *Acquired aphasia*. New York: Academic Press.
- Leischner, A., 1969. 'The agraphias'. In: P.J. Vinken and G.W. Bruyn (eds.), *Handbook of clinical neurology*, Vol. 4. Amsterdam: North-Holland.
- Lezak, M.D., 1983. *Neuropsychological assessment*, 2nd ed. New York: Oxford University Press.
- Margolin, D.I. and L. Binder, 1984. Multiple component agraphia in a patient with atypical cerebral dominance: An error analysis. *Brain and Language* 22, 26–40.
- Milner, B., 1965. Visually-guided maze learning in man: Effects of bilateral hippocampal, bilateral frontal and unilateral cerebral lesions. *Neuropsychologia* 3, 317–338.
- Ogle, J.W., 1867. Aphasia and agraphia. *St. George's Hospital Reports, Reports of the Medical Research Council (London)* 2, 83–122.
- Oldfield, R.C., 1971. The assessment and analysis of handedness: The Edinburgh inventory. *Neuropsychologia* 9, 97–113.
- Petrides, M., 1982. Motor conditional associative learning after selective prefrontal lesions in the monkey. *Behavioral Brain Research* 5, 407–413.
- Petrides, M., 1985. Deficits on conditional associative learning tasks after frontal and temporal lobe lesions in man. *Neuropsychologia* 23, 601–614.
- Petrides, M. and B. Milner, 1982. Deficits on subject ordered tasks after frontal and temporal lobe lesions in man. *Neuropsychologia* 20, 249–262.
- Porteus, S.D., 1965. *The maze test. Fifty years' application*. Palo Alto, CA: Pacific Books.
- Roeltgen, D.P., 1985. 'Agraphia'. In: K.M. Heilman and E. Valenstein (eds.), *Clinical neuropsychology*, 2nd ed. New York: Oxford University Press.
- Roeltgen, D.P. and K.M. Heilman, 1983. Apraxic agraphia in a patient with normal praxis. *Brain and Language* 18, 35–46.
- Roeltgen, D.P. and K.M. Heilman, 1984. Lexical agraphia. *Brain* 107, 811–827.
- Roeltgen, D.P., S. Sevush and K.M. Heilman, 1983. Phonological agraphia: Writing by the lexical-semantic route. *Neurology* 33, 755–765.

- Shallice, T., 1982. Specific impairments of planning. *Philosophical Transactions of the Royal Society of London* 298, 199–209.
- Valenstein, E. and K.M. Heilman, 1979. Apraxic agraphia with neglect-induced paraphasia. *Archives of Neurology* 36, 506–508.
- Vignolo, L.A., 1983. 'Modality-specific disorders of written language'. In: A. Kertesz (ed.), *Localization in neuropsychology*. New York: Academic Press.
- Wechsler, D., 1981. *Wechsler Adult Intelligence Scale-Revised*. New York: The Psychological Corporation.
- Wernicke, C., 1886. Die neueren Arbeiten über Aphasie. *Fortschritte der Medizin* 4, 371–377.