

## Trigeminal Artery and Occlusive Cerebrovascular Disease

G. KHODADAD, M.D.

**SUMMARY** Two patients with persistent trigeminal artery who had an ipsilateral cerebral stroke are presented. The relevant literature is reviewed. The significance of the trigeminal artery in

occlusive cerebrovascular disease is discussed and it is concluded that the presence of a trigeminal artery in patients with occlusive cerebrovascular disease may not be of major protective value.

ALTHOUGH the association of a trigeminal artery with disorders such as cerebral aneurysms,<sup>1-9</sup> arteriovenous malformations,<sup>9-11</sup> tumors,<sup>11-14</sup> and tic douloureux<sup>15</sup> has been described and discussed, not much is written about the significance of this artery in occlusive cerebrovascular disease. In reviewing the literature, we found only three reports which dealt very briefly with stroke patients.<sup>9, 16, 17</sup> Thus, it is not known whether or not the trigeminal artery has any protective role in patients with occlusive cerebrovascular disease.

The purpose of this paper is to describe two patients with trigeminal artery who had ipsilateral cerebral strokes and, after a brief review of the literature, to discuss the significance of this artery in patients with occlusive cerebrovascular disease.

### Case Reports

#### Case 1

This 54-year-old hypertensive (heavy cigarette smoker) and non-diabetic man had no neurological symptoms until August, 1968, when he started to experience episodes of dizziness, headaches, and weakness and numbness of the left arm. He was admitted to the hospital in August, 1969, for neurological evaluation.

His general and neurological examination revealed no major abnormality except for high blood pressure which was different in the arms: right arm 200/80 mm Hg, and left arm 140/90 mm Hg. Based on clinical findings, the diagnosis of a left subclavian steal syndrome was made and the patient had an arch aortogram. The aortogram revealed no filling of the proximal segment of the left subclavian artery. Late films in the series, however, showed retrograde filling of the left vertebral artery and subsequent opacification of the subclavian artery. A left subclavian endarterectomy was carried out successfully and the patient was discharged from the hospital symptom-free.

He was asymptomatic until mid-1970 when he again

started experiencing dizziness, headaches, light-headedness, diplopia, and episodes of weakness and numbness in the left arm. His symptoms did not improve with medical treatment, so he was again admitted to the hospital in December, 1974, for further evaluation.

The general and neurological examinations on this admission revealed blood pressures of 200/80 mm Hg in the right arm and 90/80 mm Hg in the left arm. In addition, a soft bruit was heard on the right subclavian and right carotid arteries. The patient experienced momentary dizziness at the time of change of posture but exercise of the left arm did not induce any dizziness. The cerebral angiograms, which included an arch aortogram, a right brachial and a left carotid arteriogram, revealed the following: (a) occlusion of the left subclavian artery proximal to the origin of the left vertebral artery, (b) evidence of a steal from the right vertebral artery to the left vertebral artery without any visualization of the basilar artery, (c) evidence of a steal from the left occipital artery to the left subclavian artery, (d) about 40% stenosis of the right internal carotid artery at its origin, (e) about 60% stenosis of the left internal carotid artery at its origin with ulceration, (f) a left trigeminal artery which supplied all the branches of the basilar artery and possibly the posterior inferior cerebellar arteries, (g) both the left and the right posterior cerebral arteries were the continuation of a large left and right posterior communicating artery, respectively, and (h) probable hypoplastic proximal posterior cerebral artery bilaterally (figs. 1 and 2).

A left common carotid subclavian bypass graft was done uneventfully, and the patient recovered from his symptoms. He was discharged from the hospital and was instructed to return for repair of the left internal carotid artery after two months. However, the patient failed to return until he had a stroke five months later. When seen in the hospital, he was aphasic and had weakness and numbness of the right side of his body. The blood pressure in the right arm was 150/90 mm Hg and in the left arm 130/90 mm Hg. The cerebral angiograms which included a right brachial, a left brachial and a left carotid arteriogram showed the following: (a) about 50% narrowing of the right internal carotid artery at its origin, (b) cross-filling of the left anterior and middle cerebral arteries as well as the left internal carotid artery as

The Department of Surgery, Division of Neurosurgery, University of Cincinnati Medical Center, and the Veterans Administration Hospital, Cincinnati, Ohio.

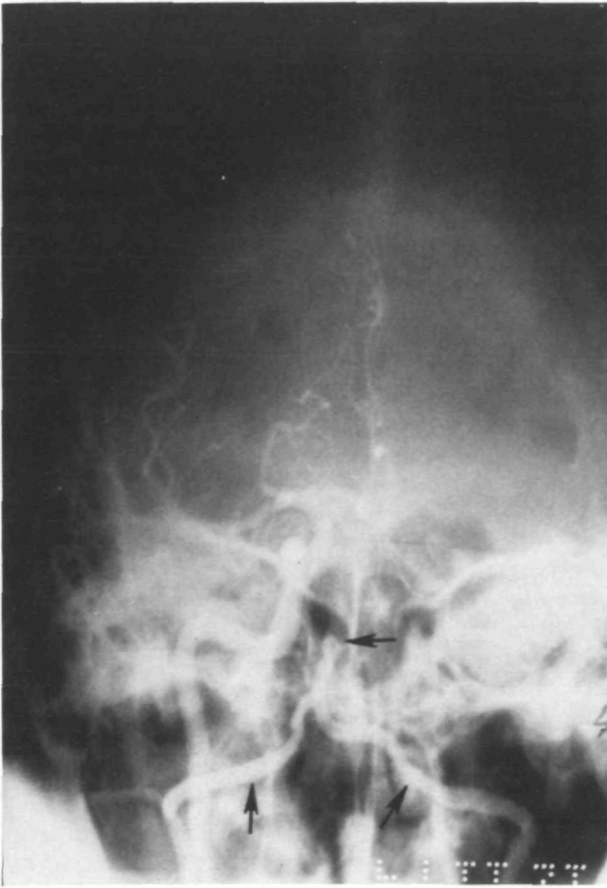


FIGURE 1. (Case 1) An anteroposterior view of the right brachial arteriogram showing the lack of opacification of the basilar artery (upper arrow). Instead, the left vertebral artery (lower right arrow) is visualized due to the subclavian steal phenomenon.

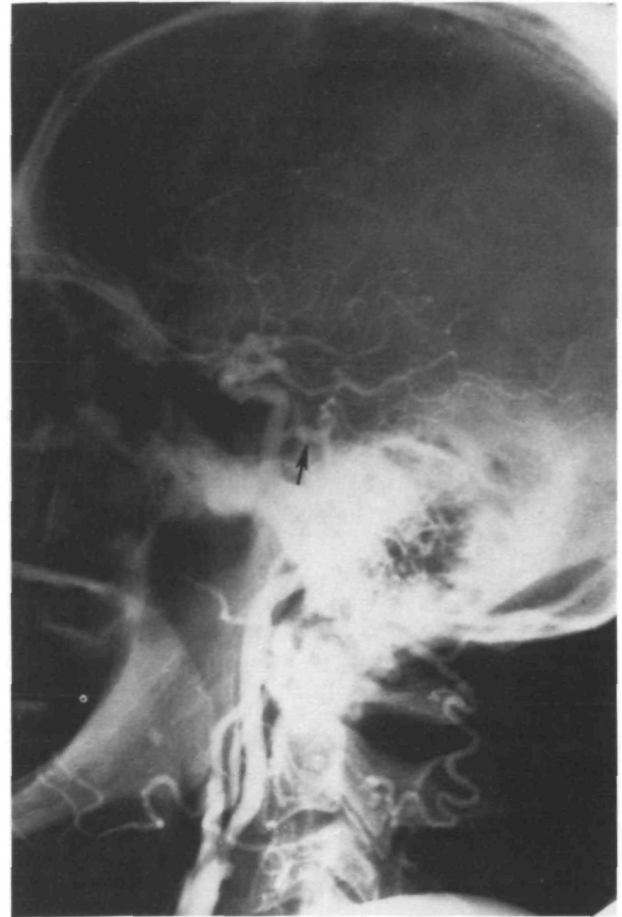


FIGURE 2. (Case 1) A lateral view of the left carotid arteriogram showing the trigeminal artery (arrow) and narrowing of the internal carotid artery at its origin.

far as the cavernous portion, (c) normal right vertebral artery but neither the basilar artery nor any of its branches were visualized, (d) occlusion of the left internal carotid artery, and (e) patent left common carotid subclavian bypass graft and opacification of the left trigeminal artery via the left vertebral artery (figs. 3 to 5). It was thought that his stroke was probably not embolic in nature, and that it was perhaps related to the reduction of the blood flow since the left carotid artery was occluded.

A left common carotid petrous carotid bypass vein graft was attempted but could not be completed because of technical difficulties. Two weeks later, a left superficial temporal-middle cerebral artery branch anastomosis was performed successfully (fig. 6). The patient gradually improved and at the time of discharge, he had no difficulty in walking and demonstrated only a slight expressive dysphasia. Two months later, the patient was re-admitted for an endarterectomy of the right carotid artery which was done without any difficulty, and the postoperative angiogram showed a well-repaired artery. At the present time, the patient is doing well and the only neurological abnormality that he has is mild expressive dysphasia.

#### Case 2

This 46-year-old non-hypertensive and non-diabetic woman was admitted to the hospital because of a sudden onset of speech impairment and weakness and numbness of the right side of her body. The neurological examination on admission revealed a mixed dysphasia and mild right hemiparesis.

The cerebral angiograms which consisted of a left carotid, right carotid, left vertebral and a right vertebral angiogram revealed the following: (a) about 80% stenosis of the left internal carotid artery at its origin without any ulceration, (b) poor visualization of the left anterior and middle cerebral arteries by the left carotid injection, (c) hypoplastic posterior communicating artery bilaterally, (d) faint cross-filling of the left anterior and middle cerebral arteries, (e) faint filling of a left trigeminal artery and the left middle cerebral artery through a small left vertebral artery, and (f) good opacification of the trigeminal artery and the left middle cerebral artery via the right vertebral circulation (figs. 7 to 9).

A left carotid endarterectomy was suggested to the patient, but it was refused. She gradually improved and left the hospital without having any neurological deficit.

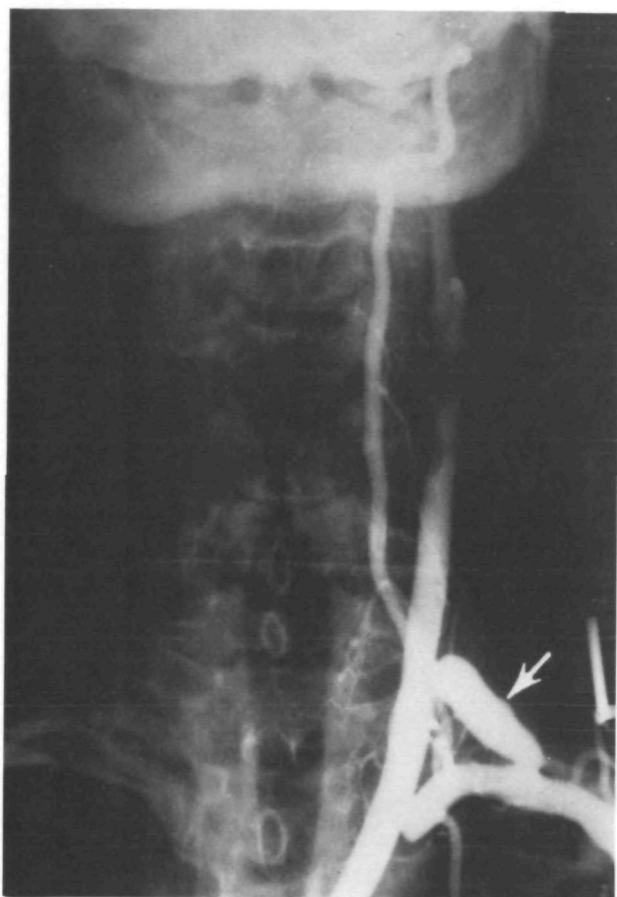


FIGURE 3. (Case 1) An anteroposterior view of the left brachial arteriogram showing the carotid-subclavian bypass graft (arrow) and opacification of the vertebral artery cephalad.

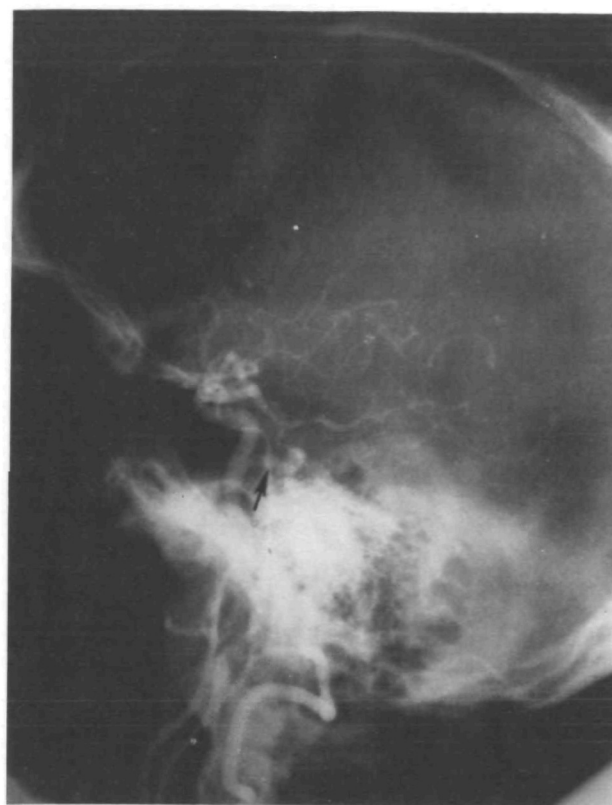

FIGURE 4. (Case 1) A lateral view of the left brachial arteriogram performed following the spontaneous occlusion of the left internal carotid artery and subsequent left common carotid-subclavian artery bypass graft. It demonstrates the reversal of the blood flow in the trigeminal artery (arrow) from the basilar artery to the carotid artery.

### Discussion

In reviewing the literature, only three papers on trigeminal artery were found which dealt briefly with occlusive cerebrovascular disease.<sup>9, 16, 17</sup> A total of six patients were described. The trigeminal artery in four of these cases was on the same side that the neurological symptoms and signs occurred and in one patient (second case of Fields<sup>17</sup>) in whom basilar insufficiency was suspected, no vertebral angiograms were performed. Among these six cases, only the one reported by Nielsen and Jonson<sup>16</sup> perhaps demonstrated some relationship between the trigeminal artery and the neurological symptoms. This was a 54-year-old man with two years' history of a left-sided headache who subsequently experienced vertigo and vomiting after turning his head while driving his automobile. The acute symptoms soon subsided. The left carotid angiogram showed slight narrowing of the internal carotid artery. The right carotid angiogram showed a severe stenosis of the origin of the internal carotid artery with poor visualization of the anterior cerebral artery only. A left subclavian angiogram failed to show the vertebral artery. A right subclavian angiogram showed a large right trigeminal artery. It was the authors' opinion<sup>16</sup> that the

direction of the blood flow had reversed from vertebral to the carotid system because of the stenosis of the right internal carotid artery. Although no comments were made on the relationship between the trigeminal artery and the patient's symptoms, one may speculate that the head turning closed off the already severely stenotic right carotid artery, and it further reduced the blood flow to the posterior circulation and caused symptoms of basilar insufficiency. One may also theorize that if the trigeminal artery were not present, the patient would then probably have had symptoms of right carotid insufficiency. Therefore, the role of the trigeminal artery in this patient was probably protective toward the ipsilateral carotid circulation but hazardous toward the vertebrobasilar circulation.

The second case of this study is somewhat similar to the case reported by Nielsen and Jonson. The patient, however, had neurological abnormalities related to the left cerebral hemisphere rather than to the brain stem. Nevertheless, the flow in the trigeminal artery was reversed from the basilar to the carotid system. It is of interest that in spite of the assisting blood flow coming from the trigeminal artery into the carotid artery and the left cerebral hemisphere, the patient had a stroke on that side. One may speculate that if

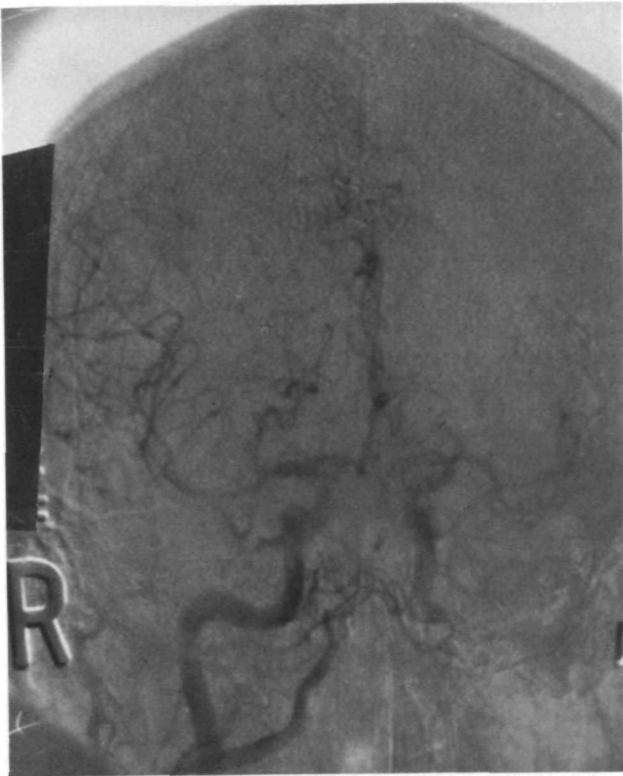

FIGURE 5. (Case 1) An anteroposterior view of the right brachial arteriogram carried out following the spontaneous occlusion of the left internal carotid artery and subsequent left common carotid-subclavian artery bypass graft. The left anterior and middle cerebral arteries are filled via the anterior communicating artery.

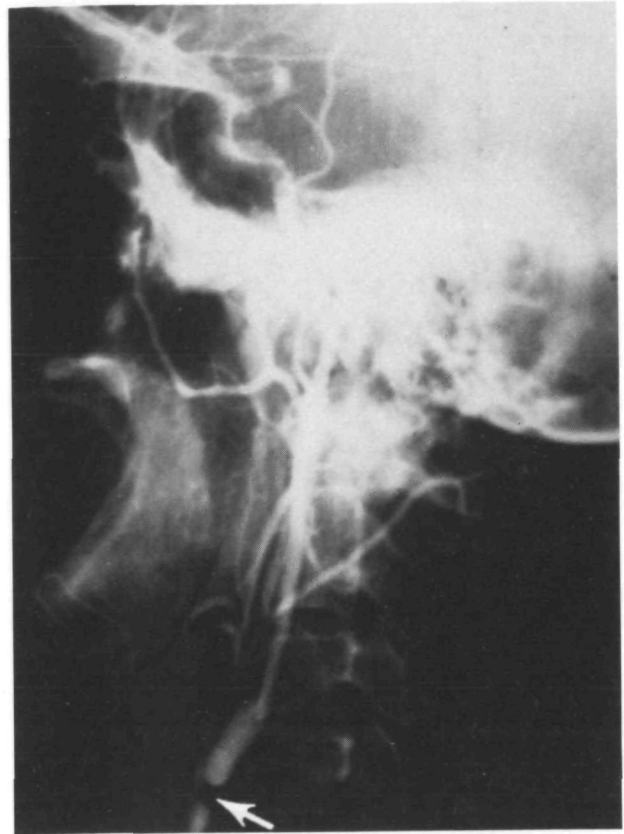


FIGURE 7. (Case 2) A lateral view of the selective left carotid arteriogram showing a severe stenosis of the internal carotid artery at its origin.

the trigeminal artery did not exist, the patient's stroke probably would have been more severe.

In the first case of this study, the symptoms of the subclavian steal still developed in spite of the trigeminal artery's

supplying the brain stem. Furthermore, a left cerebral stroke subsequently occurred, with the presence of the trigeminal artery supplying blood to the left cerebral hemisphere.

Careful analysis of the case reported by Nielsen and Jon-

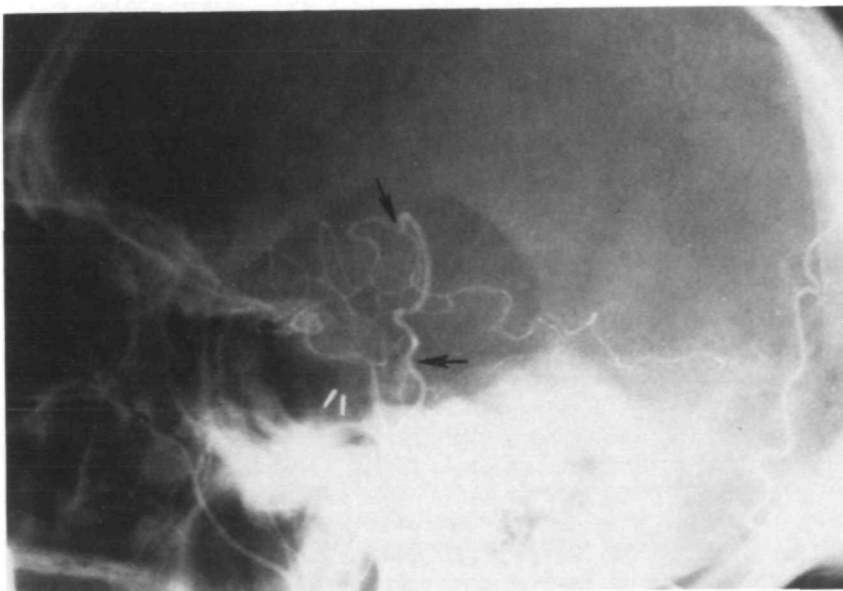


FIGURE 6. (Case 1) A left superficial temporal-middle cerebral artery branch anastomosis. The lower arrow shows the superficial temporal artery and the upper arrow the site of anastomosis.

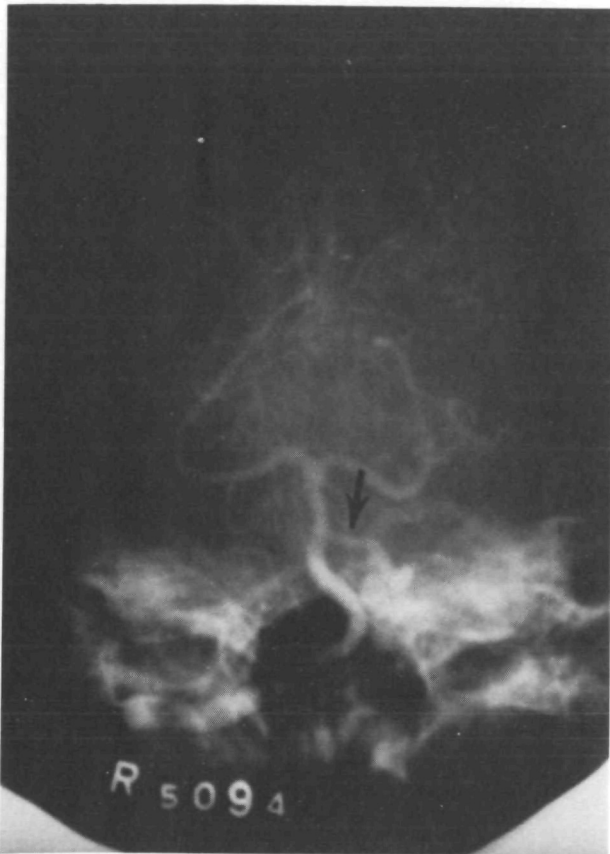

FIGURE 8. (Case 2) An anteroposterior view of the selective right vertebral arteriogram opacifying both the left trigeminal artery (arrow) and the left middle cerebral artery.

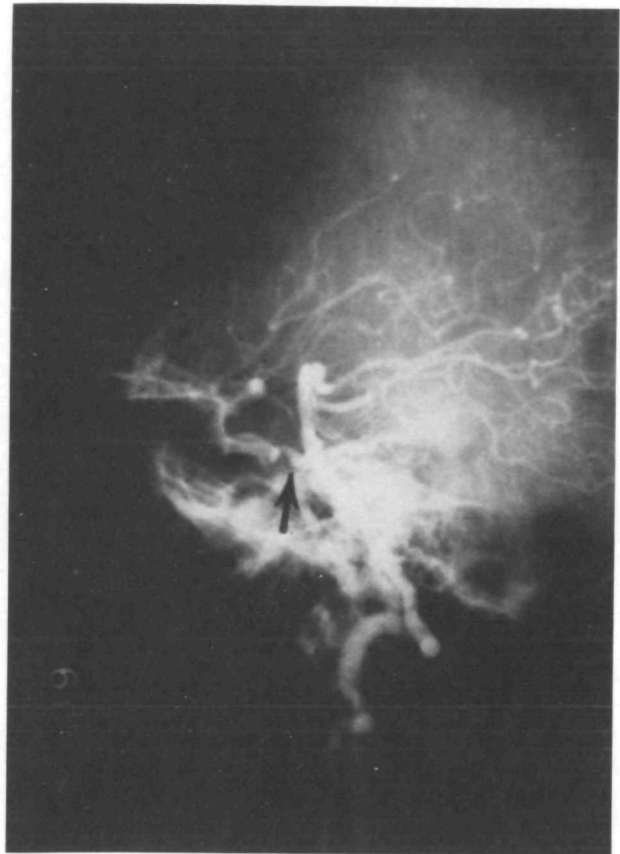

FIGURE 9. (Case 2) The corresponding lateral view of the selective right vertebral arteriogram seen in figure 8. It also demonstrates both the trigeminal artery (arrow) and the middle cerebral artery.

son and the two cases presented here reveals that the sequence of events in these patients was probably not much different from other stroke patients who have similar occlusive cerebrovascular disease and that the size of both the ipsilateral posterior communicating artery and the proximal posterior cerebral artery were relatively large but no trigeminal artery was present. Since a relatively competent posterior communicating-proximal posterior cerebral artery complex is present in the majority of individuals with or without a persistent trigeminal artery, it appears that the presence of a trigeminal artery may not significantly alter the occurrence of neurological abnormalities in patients with occlusive cerebrovascular insufficiency. It also seems that when a stroke is caused by reduction of the cerebral blood flow due to multiple occlusions of the proximal arteries, the real help may come only from the replacement of the lost flow to the brain either by opening the occluded arteries, or by a new source of blood supply and not so much by a distal channel communicating already connected channels.

#### References

- Dickmann GH, Parda C, Amezu L, et al: Persistencia de la arteria trigeminal (7 casos). *Acta Neurochir (Wien)* 17: 205-216, 1967
- Wise BL, Palubinskas AJ: Persistent trigeminal artery (carotid-basilar anastomosis). *J Neurosurg* 21: 199-206, 1964
- Wolpert SM: The trigeminal artery and associated aneurysms. *Neurology* 16: 610-614, 1966
- Davis RA, Wetzel N, Davis L: An analysis of the results of treatment of intracranial vascular lesions by carotid artery ligation. *Ann Surg* 143: 641-650, 1956
- Bingham WG, Hayes GJ: Persistent carotid-basilar anastomosis. Report of two cases. *J Neurosurg* 18: 398-400, 1961
- Murtagh F, Stauffer HM, Harley RD: A case of persistent carotid-basilar anastomosis associated with aneurysm of the homolateral middle cerebral artery manifested by oculomotor palsy. *J Neurosurg* 12: 46-49, 1955
- Schaerer JP: A case of carotid-basilar anastomosis with multiple associated cerebrovascular anomalies. *J Neurosurg* 12: 62-65, 1955
- Kawafuchi J, Kamei T, Kaneko H, et al: A case of persistent trigeminal artery associated with diffuse leptomeningeal metastasis of lung cancer. *Gumma J Med Sci* 14: 151-160, 1965
- Lamb J, Morris L: The carotid-basilar artery. A report and discussion of five cases. *Clin Radiol* 12: 179-186, 1961
- Gannon WE: Malformation of the brain. Persistent trigeminal artery and arteriovenous malformation. *Arch Neurol* 6: 496-498, 1962
- Campbell RL, Dyken ML: Four cases of carotid-basilar anastomosis associated with central nervous system dysfunction. *J Neurol Neurosurg Psychiatr* 24: 250-253, 1961
- Sutton D: Anomalous carotid-basilar anastomosis. *Br J Radiol* 23: 617-619, 1950
- Rath S, Mathai KV, Chandy J: Persistent trigeminal artery. *Arch Neurol* 19: 121-122, 1968
- Harrison CR, Luttrell C: Persistent carotid-basilar anastomosis. Three arteriographically demonstrated cases with one anatomical specimen. *J Neurosurg* 10: 205-215, 1953
- Jackson IJ, Garza-Mercado R: Persistent carotid-basilar artery anastomosis: Occasionally a possible cause of tic douloureux. *Angiology* 11: 103-107, 1960
- Nielsen PB, Jonson M: Persistent primitive trigeminal artery demonstrated by vertebral arteriography. *Am J Roentgenol* 101: 47-51, 1967
- Fields WS: The significance of persistent trigeminal artery. *Radiology* 91: 1096-1101, 1968