

Electric Injury With Cerebral Venous Thrombosis

Case Report and Review of the Literature

A. Patel, MD, FRCPC, and R. Lo, MD, FRCPC

Background and Purpose: A case of accidental electrocution with previously unreported arteriographic evidence of cerebral vein thrombosis is presented. A brief description of early and late neurological complications and current theories attempting to explain the histopathological findings of electric injury are reviewed. The occurrence and persistence of late neurological complications are elucidated.

Case Description: A report of an accidental electrocution with 800 V of alternating current in a young man is presented. Cerebral angiography showed a cerebral vein thrombosis. The immediate complications included loss of consciousness, confusion, memory loss, and headache. Late complications of right-sided clumsiness, sensory loss, hemianopsia, and neglect persisted for more than 1 year despite the brain being outside the current pathway.

Conclusions: High-voltage electric injury may cause cerebral vein thrombosis with significant early and delayed brain injury even when the brain lies outside the current pathway. (*Stroke* 1993;24:903–905)

KEY WORDS • electric injuries • thrombosis

Electric injuries are common, but fortunately few are fatal. The severity of electric injury depends on voltage, skin resistance, current, and pathway of the current within the body. Exposure to more than 25 V is potentially dangerous,¹ but fatal accidents have been reported with voltages as low as 46 V.² Alternating current with frequencies of 40–150 Hz is twice as dangerous as direct current of the same voltage because it induces tetanic muscle contraction, causing the victim to become locked to the point of contact with the current.^{2,3} The current selects the shortest pathway from contact to contact and passes through tissue as through a structureless gel.⁴

In this report we describe a case of an accidental electrocution in a young man who was struck by 800–1,500 V. The case is interesting because of the rarity of surviving a high-voltage shock and because of the development of an intracerebral venous thrombosis, which has not previously been reported after electrocution.

Case Report

A 31-year-old right-handed Vietnamese man was admitted to the hospital after an electric shock injury. His right hand contacted a capacitor with a 15,000-V capacity while he was repairing a microwave oven 3 days before admission. The capacitor had been unplugged for 3 minutes, and the patient estimated that he suffered a shock with approximately 800 V of alternating current. He felt a “shocklike” sensation in both arms and his

head. Soon afterward, he apparently lost consciousness for 5–30 minutes. His coworker found him sitting dazed in the room. He complained of a severe headache, redness in his right arm, and weakness in his right arm and leg. His wife noticed periodic confusion and deterioration of his recent memory. His medical history was unremarkable, and he was taking no medications.

Physical examination on admission revealed an alert man in no acute distress who was oriented to time, place, and person. He had a right visual field defect, right facial numbness, and a mild numbness and weakness in his right arm. Deep tendon reflexes were 3+ and symmetrical. There was an upgoing toe on his left foot.

Laboratory investigations included normal blood count, sedimentation rate, electrolytes, blood sugar, liver enzymes, and complement (C3 and C4) levels. Chest x-ray film and electrocardiogram were normal. Antinuclear antibody, rheumatoid factor, cold agglutinins, and hepatitis screen were negative. Protein C, protein S, antithrombin III, and plasminogen levels were normal. A computed tomographic (CT) scan of the head with and without contrast enhancement was normal. Cerebrospinal fluid analysis including cell count, glucose, protein, and cultures was normal. An echocardiogram was normal. An electroencephalogram (EEG) showed left parietal slowing with irregular theta elements and sharp waves. A cerebral angiogram showed a thrombus at the distal end of the vein of Labbé (a superficial vein traversing the temporoparietal cortex) on the left side projecting into the transverse sinus (Figure 1). There was also patchy filling of the left internal cerebral vein and the left vein of Galen, which was suggestive of thrombus.

One month later the patient showed no clinical improvement. A repeat cerebral angiogram showed

From the Departments of Medicine (A.P.) and Neurology (R.L.), McMaster University Medical Centre, Hamilton, Canada.

Address for correspondence: Dr. R. Lo, 710-155 James Street S., Hamilton, Ontario, Canada, L8P 3A4.

Received June 18, 1992; revision received January 12, 1993; accepted February 15, 1993.

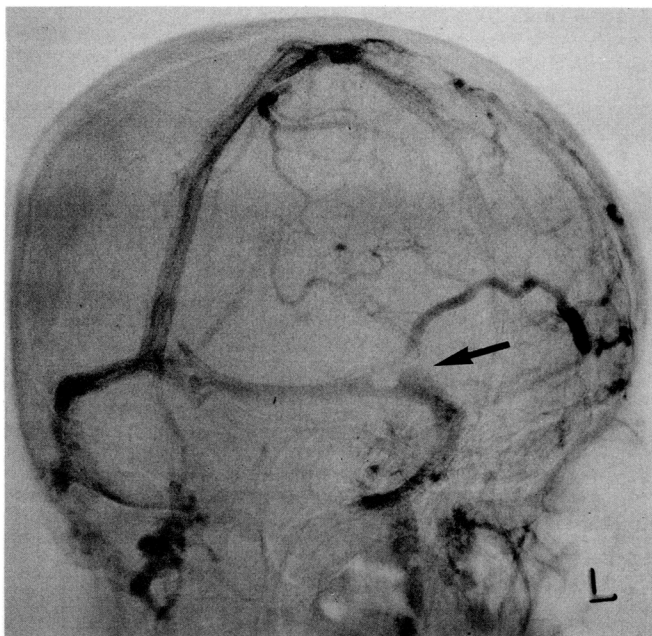


FIGURE 1. Angiogram showing a thrombus (arrow) obstructing the distal left (L) vein of Labbé.

persistence of the thrombus. A 6-month trial with warfarin resulted in no improvement.

Over the next 2 years there was gradual improvement, but the patient's gait remained ataxic and he had a constant headache and memory problems. Psychological testing demonstrated poor concentration, and he was withdrawn and depressed.

Discussion

The clinical effects of electric injury may be classified into immediate and late manifestations. The immediate manifestations include cardiac and respiratory arrest, loss of consciousness, motor and sensory disturbances, amnesia, and confusion. The longer the period of unconsciousness, the more severe are the amnesia and confusion that follow. Old age, fatigue, atherosclerotic arterial disease, and hypothyroidism may lower an individual's susceptibility to electric injury.⁵

The late manifestations may be divided into focal and nonfocal deficits and may occur days to months after the electric injury. Focal deficits include cerebral (hemiplegia, aphasia), spinal (transverse myelitis, progressive muscular atrophy, amyotrophic lateral sclerosis), and peripheral nerve (neuropathies, radiculopathies) manifestations.^{5,6} Nonfocal symptoms such as psychoneurotic behavior, personality changes, confusion, amnesia, and headache are common, and their occurrence is not restricted to cases in which the brain lies in the electric current pathway. Abnormal EEGs have been documented in cases in which the brain is outside the current pathway.^{6,7} In this case there were prominent nonfocal findings, and the brain was outside the current pathway. Despite this, the EEG showed left parietal abnormalities. Although the CT scan was normal in this case, abnormalities that have been described include basal ganglia and parieto-occipital hemorrhages, basal ganglia hematoma, and basilar artery thrombosis.⁸⁻¹⁰ There

are no reports of intracerebral venous thrombosis after electric injury.

Four theories have been considered to explain the histopathologic findings of electric injury. The electrostatic theory¹¹ suggests that if the victim is not grounded, electric charges build up in the body, producing electrostatic effects. Particles with similar charges repel each other, resulting in a sudden expansile force of the body tissues that gives rise to waves of decompression under the skin. This may account for the tissue rupture seen at autopsy, but it does not explain the unilateral predominance of clinical effects or abnormalities beyond the current pathway. The vascular theory⁸ suggests vasoconstriction as the mechanism of the acute manifestations. Intimal injuries and subsequent vascular thrombosis may account for the delayed manifestations. Animal studies have shown that pial vessels constrict when exposed to electric stimulation.¹² The heat theory⁸ suggests thermal injury to the brain tissue as the mechanism for the pathological findings. Cerebrospinal fluid temperatures as high as 145°F have been recorded 5 hours after legal electrocution. The mechanical theory¹¹ suggests that the injury is caused by a violent jarring of the tissue by the electrical current. Critically ill burn patients possess three predisposing factors associated with venous thrombosis: prolonged immobilization, hypercoagulability, and changes in blood volume and blood vessel permeability.^{13,14} This complication is rare and occurs only in patients with severe burns. Our patient had minimal burns despite the high-voltage shock.

It appears that no single theory will explain all the pathological findings, and it is conceivable that a combination of the mechanisms mentioned above may play a role in the production of the histopathologic changes. In our patient, the current pathway was from the right arm to the legs. The immediate effects included loss of consciousness, confusion, memory loss, and headache. This was followed by right-sided clumsiness, sensory loss, hemianopsia, and neglect. The latter symptoms persisted for a year, and he was left with a persistent headache, personality change, and short-term memory deficit.

The focal clinical findings were corroborated by the EEG and angiographic abnormalities in the left parietal region. His personality change, memory loss, and headache reflect a more diffuse and bilateral cortical involvement. The intracerebral venous thrombosis is likely a marker of the extent of the vascular injury at that particular region rather than the cause of all his symptoms. The intracerebral venous thrombosis may be explained by the vascular theory (vasospasm and intimal damage). An alternative or concomitant mechanism for the intimal damage may be related to the heating effect of the electricity. Hypoxic damage may have contributed to the central nervous system findings.

There is no evidence to guide the use of anticoagulation in a patient who has an intracerebral thrombosis. Our patient received anticoagulant medication for 6 months without showing significant benefit. The patient refused to have a repeat cerebral angiogram after anticoagulation.

This patient demonstrated that cerebral manifestations may occur even when the brain is outside the shortest current pathway. Diffuse cerebral dysfunction

is common and may be long lasting. In patients with nonfatal electric injury, routine investigations may include CT scan and EEG. Further investigations such as cerebral angiography may be of value even if the CT scan is normal.

References

1. Jaffe RH: Electropathology: A review of the pathologic changes produced by electrical currents. *Arch Pathol* 1928;5:837-870
2. Stevenson LD: Electrical injuries to the nervous system. *Arch Neurol Psychiatry* 1942;48:179-186
3. Urquhart RWI: The nature of electrical shock. *Ontario Med Rev* 1951;18:54-56
4. Weeks AW, Alexander L: Distribution of electric current in animal body: Experimental investigation of 60 cycle alternating current. *J Industr Hyg Toxicol* 1939;21:517-525
5. Critchley M: Neurological effects of lightning and of electricity. *Lancet* 1934;1:68-72
6. Farrell DF, Starr A: Delayed neurological sequelae of electrical injuries. *Neurology* 1968;18:601-606
7. Panse F: Die schädigungen des nervensystems durch technische elektrizitat. *Msschr Psychiat Neurol* 1931;78:193-213
8. Stanley LD, Suss RA: Intracerebral hematoma secondary to lightning stroke: Case report and review of the literature. *Neurosurgery* 1985;16:686-688
9. Mann H, Kozic Z, Boulos MI: CT of lightning injury. *AJNR* 1983;4:976-977
10. Lindenmayer JP, Pappenheim E: A case of accidental electrocution: A clinical pathological report. *Psychiatr Q* 1973;47:218-227
11. Pritchard EAB: Changes in the central nervous system due to electrocution. *Lancet* 1934;1:1163-1167
12. Echlin FA: Vasospasm and focal cerebral ischemia: An experimental study. *Arch Neurol Psychiatry* 1942;47:77-95
13. Sevitt S: A review of the complications of burns: Their origin and importance for illness and death. *J Trauma* 1979;19:358-369
14. Curreri PW, Katz AJ, Dotin LN, Pruitt BA Jr: Coagulation abnormalities in the thermally injured patient. *Curr Topics Surg Res* 1970;2:401-411