

Brain SPECT in a Patient With Post-Stroke Hallucination

S. M. KIM, M.D., C. H. PARK, M.D., C. M. INTENZO, M.D., AND J. ZHANG, Ph.D.

A patient developed visual hallucinations following a left-sided cerebrovascular accident (CVA). Brain SPECT using Tc-99m HMPAO demonstrated increased perfusion at the biparieto-occipital lobes. Following antiepileptic medication, repeat brain SPECT showed interval decrease in perfusion in the same areas with the symptomatic relief of hallucinatory episode. While it is possible that the interval decrease is due to natural resolution, the authors believe that it is likely due to drug treatment.

BRAIN SPECT STUDY using N-isopropyl iodoamphetamine (I-123 IMP) or Tc-99m hexamethylpropylene amine oxime (HMPAO) has been used successfully for the evaluation of stroke, dementia, and seizure and psychiatric disorders (1-5).

In 1988, Matsuda et al (6) reported an alcoholic patient with auditory hallucinations showing increased cerebral blood flow (CBF) in the left superior temporal area corresponding to the primary and secondary auditory centers.

We report a post-stroke patient with visual hallucinations inducing increased CBF on brain SPECT. After therapy with anti-epileptic medications, repeat brain SPECT indicated an interval decrease in CBF.

Case Report

A 70-year-old woman presented with a chief complaint of seeing "ghosts" for one month. She had no history of seizures and was not taking any antiseizure medications. She had a past medical history of hypertension, asthma, diabetes mellitus, and an old left CVA. Physical examination showed a fully alert, oriented woman with mild dementia and decreased short term memory. Language was not fluent but speech

From the Department of Radiation Oncology and Nuclear Medicine, Thomas Jefferson University Hospital, Philadelphia, Pennsylvania

was not slurred. Pupils were equal, reactive to light, and extraocular muscle movement was intact, and there was no nystagmus or visual field defect. There was mild facial weakness with the tongue deviated to the right and soft palate raised, and there was a good gag reflex. The right upper and lower extremities showed mild motor weakness, sensory examination was normal, and finger-to-nose with dysmetria on the right was observed.

Laboratory tests showed no anemia, electrolytes were normal, BUN 27 (normal 12-27 mg/dl), creatinine 1.7 (normal 0.7-1.4 mg/dL), glucose 79 (normal 60-110 mg/dL), calcium 9.2 (normal 8.5-10.5 mg/dL), phosphate 3.5 (normal 2.5-4.5 mg/dL). Thyroid function tests, B-12, and folate levels were normal. Lyme titer was less than 0.8 (abnormal greater than 1). 24-hour electroencephalogram monitoring was free of abnormal seizure activity.

The initial SPECT study was performed 2 days after the woman had been admitted to the hospital. SPECT imaging was obtained using a Triad triple-head detector (Trionix Research Inc., Twinsburg, Ohio). Twenty millicuries of Tc-99m HMPAO were injected intravenously with the patient's eyes closed under dim light in a noise free environment. Data was acquired into a 128 × 128 matrix, 40 steps (3° each) per each detector for 35 seconds per angle. After preprocessing data with the ramp filter, set to a cut-off frequency of 0.75/cm, the filtered back projection method was used for image reconstruction. Tomographic slices were analyzed along with three-dimensional reprojection images.

Initial SPECT imaging, transaxial (Fig. 1, first and third rows) and sagittal slices (Fig. 2, first and third rows) demonstrated decreased perfusion in the left

Received for publication May 15, 1992; revision accepted June 29, 1992.

Reprint requests: S. M. Kim, M.D., Division of Nuclear Medicine, Thomas Jefferson University Hospital, 11th and Walnut Streets, Philadelphia, Pennsylvania 19107.

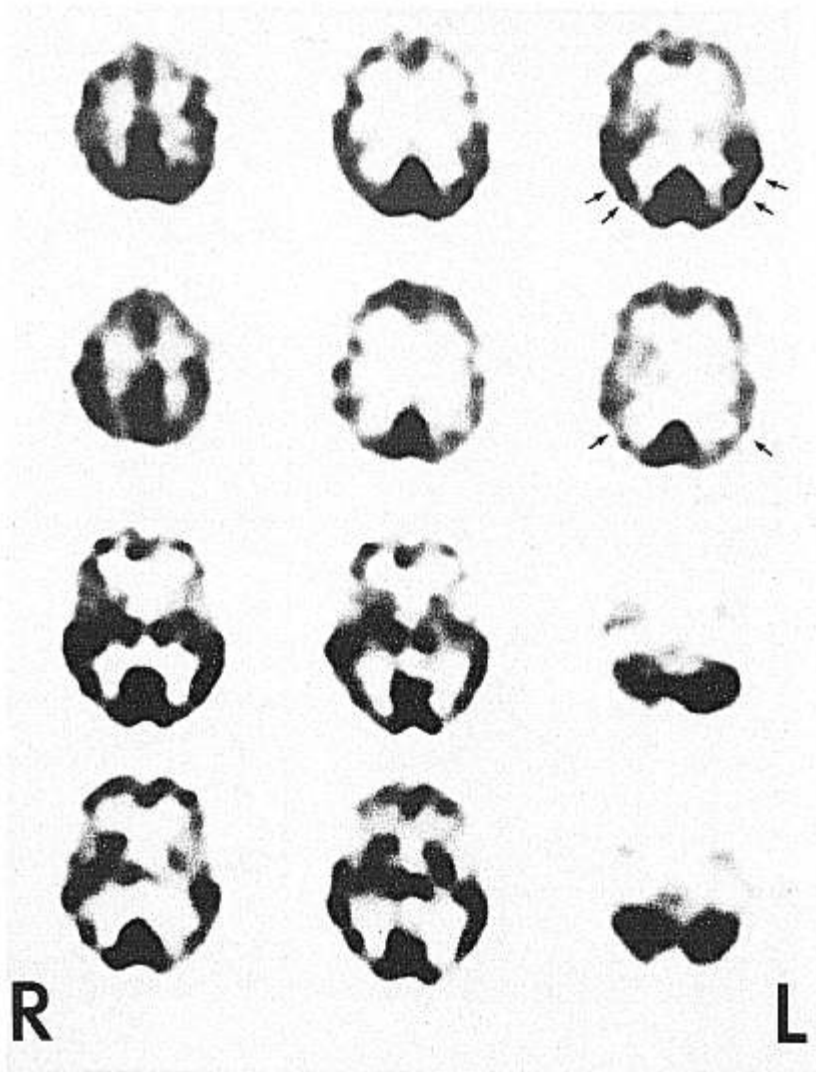


Fig. 1. Initial transaxial slices (first and third rows) show marked increased cerebral blood flow (CBF) to the occipito-parietal cortices bilaterally (double arrows). Decreased CBF is evident in the left fronto-temporal and left basal ganglia due to stroke and in the right cerebellum due to crossed cerebellar diaschisis. Posttreatment transaxial slices (second and fourth rows) depict interval decrease in CBF to the occipito-parietal regions (arrows).

frontal and temporal lobes as well as in the left basal ganglia (due to stroke) and decreased flow to the right cerebellum (due to crossed cerebellar diaschisis). There was marked increased perfusion in the occipito-parietal lobes bilaterally, which is likely due to seizure foci related to the visual hallucinations. The patient received antiseizure medications as well as a tranquilizer.

Six days later, a second SPECT study was performed; transaxial (Fig. 1, second and fourth rows) and sagittal views (Fig. 2, second and fourth rows) showed interval decreased perfusion within the occipito-parietal lobes and slight improvement of perfusion in the left frontal and left basal ganglia. At this time, the patient no longer was experiencing hallucinatory episodes. A CT scan of the patient performed three days after being discharged showed ischemic changes

within the white matter and a lacunar infarction in the left basal ganglia.

Discussion

Cerebral blood flow studies can effectively be used to monitor changing events in seizure disorders. Increased cerebral blood flow is now well documented during the ictal period of auditory hallucinations in an alcoholic patient (6). Our case shows increased blood flow during visual hallucinosis (organic hallucinosis). Continuous neuronal electrical firing is probably the cause of increased blood flow during the hallucinations.

It is reported that the occurrence of acute visual hallucinosis, with the exception of peduncular hallucinosis, can occur without a localizing focus within the

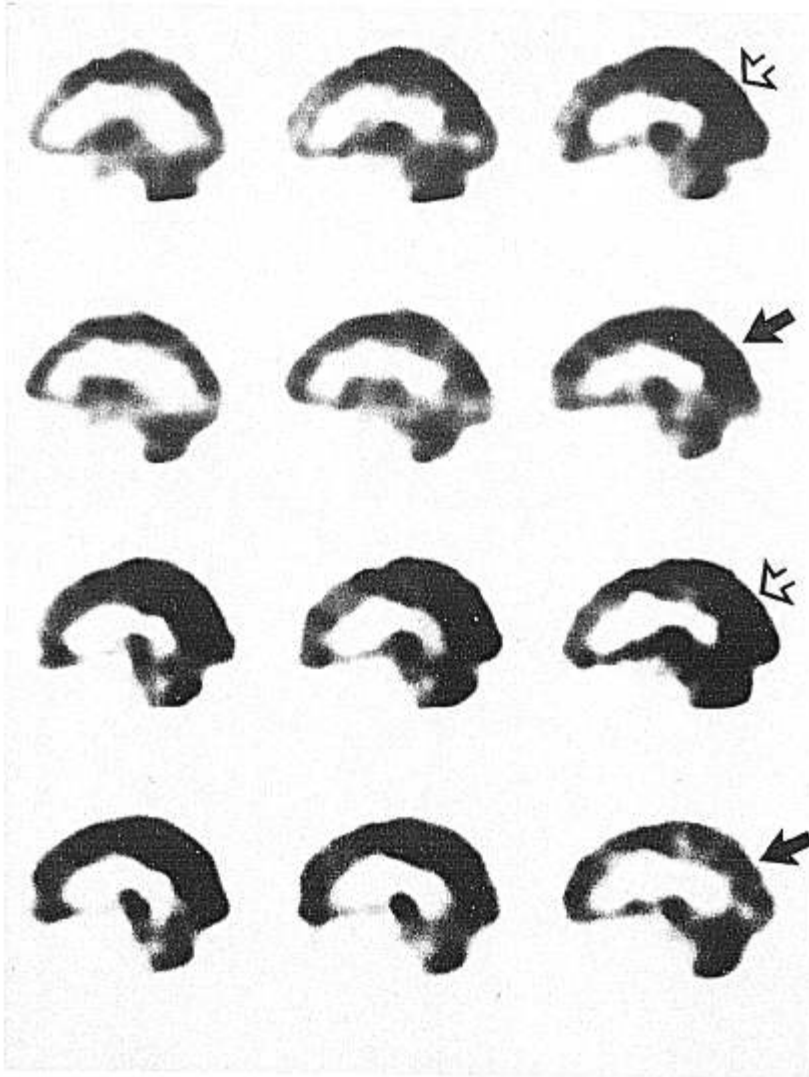


Fig. 2. Initial sagittal slices (first row through the right hemisphere and the third row through the left hemisphere) reveal increased CBF to both occipito-parietal regions (open arrows). Repeat sagittal slices (second row through the right hemisphere and fourth row through the left hemisphere) demonstrate decreased CBF to the occipito-parietal cortices bilaterally (arrows).

central nervous system (7). The visual hallucination is associated with a lesion anywhere in the visual pathway. When the focus is in the temporal lobe, the complex stereotypical images are reported. When the focus is in the occipital lobe, brief stereotypical flashes of light or color are described. Because of the wide overlapping with symptoms originating in other regions, it is difficult to localize the focus on clinical grounds.

Brain SPECT has been used in monitoring the treatment response in the dementia of AIDS as well as in Alzheimer's dementia, Parkinson's disease, and schizophrenia (8-11). Although it is possible that interval improvement could be due to spontaneous resolution, we believe that interval improvement is more likely due to the drug treatments. The SPECT study, in this case report, proved to be very useful in both

localizing visual hallucinations and in monitoring the therapeutic effect of antiseizure medications.

References

1. Hill TC, Holman BL, Lovett R, et al: Initial experience with SPECT of brain using I-123 IMP. *J Nucl Med* 1982; 23:191-195.
2. Katz, Rose A, Lind SJ and Spencer S: SPECT in patients with epilepsy partialis continua. *Neurology* 1990; 40:1848-1850.
3. Sharp P, Gemmell H, Cherryman G et al: Application of I-123-labelled IMP imaging to the study of dementia. *J Nucl Med* 1986; 27:761-768.
4. Cohen MB, Graham LS, Lake R, et al: Diagnosis of Alzheimer's disease and multiple infarct dementia by tomographic imaging of I-123-IMP. *J Nucl Med* 1986; 27:769-774.
5. LaFrance ND, Wagner HN Jr., Whitehouse P, et al: Decreased accumulation of isopropyl-iodoamphetamine in brain tumors. *J Nucl Med* 1981; 22:1081-1083.

6. Matsuda H, Gyobu T, Li M, et al: Iodine-123 iodoamphetamine brain scan in a patient with auditory hallucination. *J Nucl Med* 1988, 29:558-560.
7. Geller TJ, Bellur SN. Peduncular hallucinosis: Magnetic resonance imaging confirmation of mesencephalic infarction during life. *Ann Neurol* 1987; 21:602-604.
8. Rottenberg DA, Moeller JR, Satrother FW, et al: The metabolic pathology of the AIDS dementia complex. *Ann Neurol* 1987 22:700.
9. Pizzolato G, Dam M, Borsato N, et al: Tc-HMPAO SPECT in Parkinson's disease. *J Cereb blood flow metabol* 1988; 8:S101.
10. Smith FW, Gemmell HG, Sharp PF, et al: Tc-99m-HMPAO SPECT imaging in patient with basal ganglia disease. 1988 *Br J Radiol* 1988, 61:914.
11. Bajc M, Medved B, Basic M et al: Acute effect of electroconvulsive therapy on brain perfusion assessed by Tc-HMPAO and SPECT. *Acta Psychiatr Scan* 1989; 80:421.