

B. Zahner  
C.J.G. Lang  
A. Engelhardt  
P. Thierauf  
B. Neundörfer

Department of Neurology, University of  
Erlangen-Nuremberg, Germany

# A Case of Alzheimer's Disease with Extensive Focal White Matter Changes

## Key Words

Alzheimer's disease  
Focal white matter changes

## Abstract

The case of a patient is reported who suffered from disturbed concentration and memory and constructive apraxia. She had only mild neuropsychological deficits at the first examination. T2-weighted MRI presented extensive focal white matter changes. A brain biopsy showed changes typical for Alzheimer's disease (AD). The extent of the white matter lesions was surprising compared to the mild clinical signs she had. This case confirms that AD may result in prominent white matter disease caused by incomplete infarction or demyelination.

## Introduction

The association of white matter changes (WMC) with Alzheimer's disease (AD) has been widely discussed recently. There is disagreement whether there is any specificity in these changes or whether their severity correlates with the severity of dementia. Many authors believe that the lesions are the result of subacute hypoperfusions for which congophilic angiopathy is believed to be responsible [1].

Our patient was not diagnosed as having AD before brain biopsy, since neuropsychological tests did not disclose marked dementia and MRT showed widespread subcortical hyperintensities on T2-weighted images. The distribution of these changes was uncommon, because they were located not only periventricularly but reached widely into the temporal lobes. Compared to other cases with WMC they were very circumscribed on neuroimaging. Because WMC are unspecific and similar in several disorders on the basis of brain imaging only, a wide range of disorders causing leukoariosis [2] had to be considered.

## Case Report

At the age of 52 the patient first noticed an increasing disability to concentrate and memorize things and a lack of orientation. At the time of the first hospital examination these deficits were so minor that her family had not noticed them. The patient had suffered from some uncharacteristic symptoms such as occasional headache and pain which according to her description might have been a symptomatic trigeminal neuralgia.

The patient had no history of hypertension or diabetes. In her family, her father, uncle and an aunt on the father's side became demented around the age of 60 years for unknown reasons.

In 1991, on the first neurological examination, she only showed weakness of her left face, myocloni of both lids, slight pronation of the right arm and myocloni of both arms, when she tried to stretch them out simultaneously, and bradydiadochokinesia. There were no release phenomena.

The routine laboratory parameters were normal except for mild anemia. Serum arylsulfatase A and HIV tests were normal. CSF was completely inconspicuous. No tumor or signs of an immunological disease were found.

The electrophysiological assessment (electroencephalography, electromyography, nerve conduction velocities, visual and sensory evoked potentials) was normal, but central motor conducting velocity was delayed to the right side.

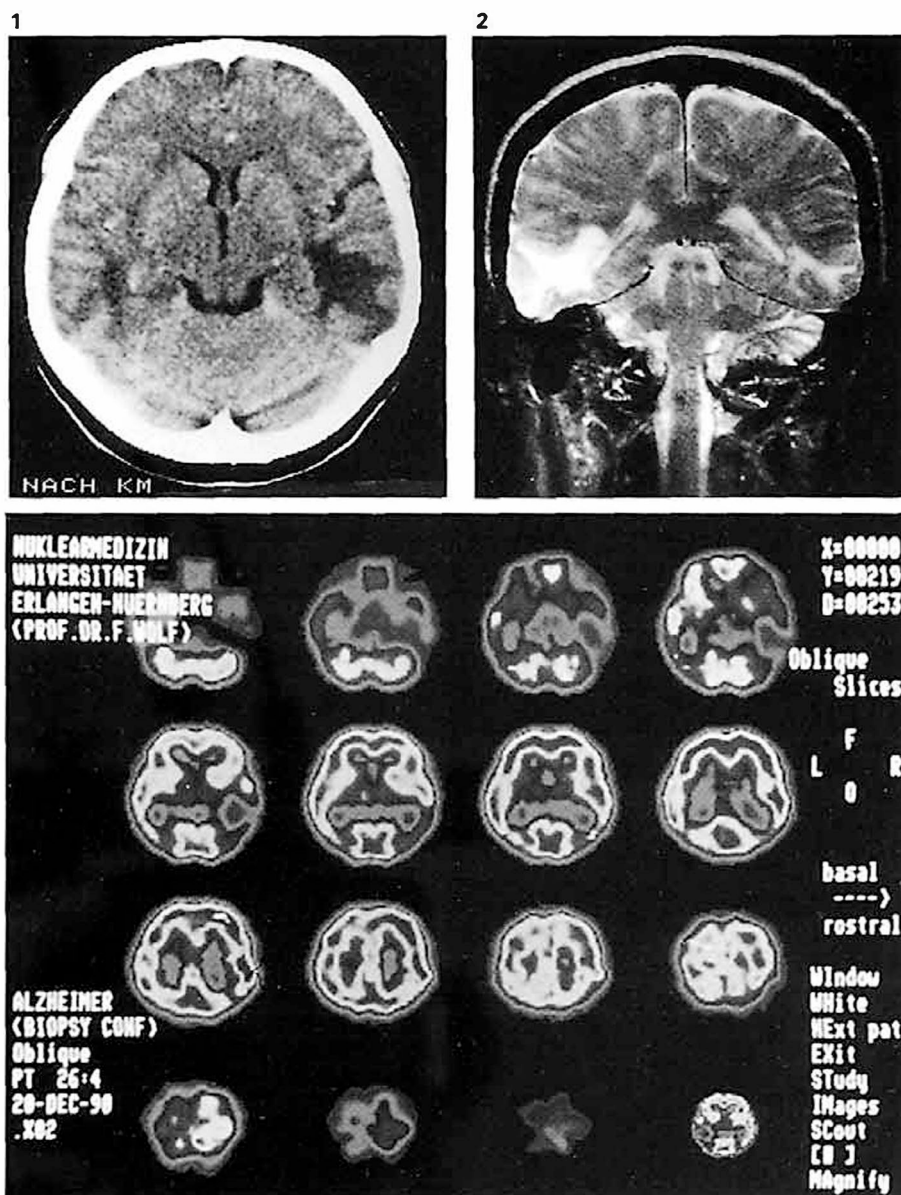
Accepted:  
December 19, 1994

Dr. Birgit Zahner  
Neurologische Universitätsklinik Erlangen  
Schwabachanlage 6  
D-91054 Erlangen (Germany)

© 1995 S. Karger AG, Basel  
1013-7424/95/0065-0294  
\$8.00/0

**Fig. 1.** CT scan showing an extensive hypodensity in the white matter of the right temporal lobe and to a less severe extent on the left side.

**Fig. 2.** Large white matter signal hyperintensities seen on the T2-weighted MRI scan of both temporal lobes, more marked on the right side.



**Fig. 3.**  $^{99}\text{Tc}$ -HMPAO-SPECT shows an area of decreased HMPAO enrichment measuring  $5 \times 4$  cm in the right temporal lobe, perfusion of the other areas is normal.

Cranial computed tomography (CT) (fig. 1) showed temporoparietal white matter hypodensities bilaterally, more pronounced on the right side. Magnetic resonance imaging (MRI) (fig. 2) also clearly disclosed white matter changes (WMC) more prominent in the right than the left temporal lobe. Therefore degenerative, tumorous, inflammatory or vascular disease was suspected.

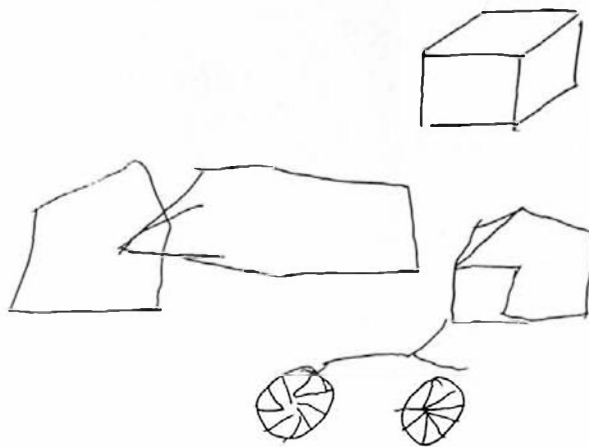
$^{99}\text{Tc}$ -HMPAO-SPECT examination showed an area of decreased enrichment in the right temporal lobe measuring  $4 \times 4$  cm; perfusion of other areas was normal (fig. 3).

In the neuropsychological evaluation dementia scales, tests for handedness, verbal and nonverbal memory, attention and a behavioral rating were given.

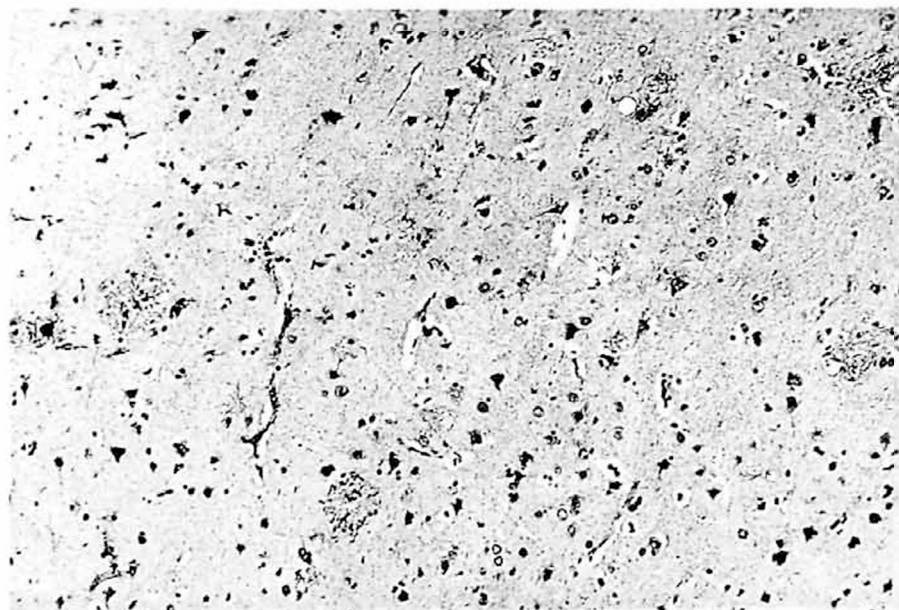
The patient was strongly right-handed (90%, Edinburgh Handedness Inventory) also preferring the right eye and leg, respectively.

Premorbid intelligence estimate [3] was IQ = 92 (low normal range). Drawing was severely defective. The patient was neither able to copy a cube in perspective view nor to give the details of a bicycle (fig. 4). Angles were rendered distorted.

Despite unequivocal impairments (table 1) the patient scored above the cutoff level for dementia in the Mini-Mental State Examination [4] at the first testing. Nevertheless the patient was considered mildly demented since the combination of global memory impairment [5] and constructive deficits (drawing, visual reproduction) agreed with the DSM-III-R definition [6]. Although not tested formally, no language disorders were apparent. Altogether the neuropsychological status was interpreted as indicating right hemisphere (temporoparietal) involvement superimposed on a global memory impairment.



**Fig. 4.** The patient tried to draw a bicycle, two intersecting pentagons, to copy a cube (right upper corner), all severely defective.



**Fig. 5.** Brain biopsy. Bodian silver impregnation.  $251 \times 200$ . Senile plaques in the cortex.

Relatives' rating of behavioral symptoms disclosed marked depression (55/70 points) and decreased motivation (10/20) with preserved or only mildly disturbed emotional stability, level of activation, self-care and social behavior. Attention and concentration, communicative abilities and insight were also rated as normal, whereas intellectual abilities and orientation were considered mildly, memory markedly abnormal. There were no psychotic signs or symptoms.

The brain biopsy from the right temporal lobe, where the MRI lesions were most marked, showed many plaques and congophilic angiopathy as well as mild cortical and subcortical astrogliosis (fig. 5). The pathologists diagnosed AD. Because of the neuropsychological test results that ranged above the score 'demented' the patient was asked for a new neuropsychological and neurological evaluation after 6 months.

Six months later no significant change of the neurological status, the neuroimaging or the patient's self-report was noted. The results of the neuropsychological assessment not only did not deteriorate (table 1), they even showed a mild (insignificant) trend towards improvement. Once again performance was poorest in those tests which required visuomotor processing or memory. Since on second examination there was no clearcut global memory deficit, the diagnosis of dementia was questioned because there was mild improvement in some of the subtests within 6 months and according to the Mini-Mental status the patient still did not score as 'demented'. Compared to a sample of clinically diagnosed Alzheimer patients our patient fell within  $\pm 1$  SD of their scores in only one of five subtests of the Mattis Dementia Rating Scale [7] at each test session.

2½ years later the patient was examined again because of increasing apathy and depression plus sudden uncontrolled aggressive epi-

**Table 1.** Neuropsychological assessment of the patient's mental impairment

Test	Maximum score	Normal range	January 22, 1991 first examination		July 12, 1991 second examination		March 3, 1994 third examination	
			raw score	interpretation	raw score	interpretation	raw score	interpretation
Mini Mental Status Examination (severity of dementia) <sup>1</sup> [4]	30	24–30 (not demented)	25	not demented	29	not demented	22	demented
Dementia Rating Scale (severity of dementia) [7]	144	134–144	120	impaired	30	mildly impaired	91	severely impaired
Attention	37	35–37	35	normal	36	normal	32	subnormal
Initiation and perseveration	37	34–37	24	impaired	31	mildly impaired	16	subnormal
Construction	6	6	6	normal	3	impaired	1	impaired
Conceptual thinking	39	35–37	39	normal	39	normal	28	mildly impaired
Memory	25	23–25	16	impaired	21	mildly impaired	14	impaired
Multiple Choice Vocabulary Test (verbal intelligence) [8]	37	17–32	20	IQ = 89 (low normal range)	16	IQ = 83 (subnormal)	19	IQ = 88 (low normal range)
Raven's Standard Progressive Matrices (nonverbal intelligence) [9]	60	(18–40)	8	IQ = 63.6 (floor effect; distinctly impaired)	13	IQ = 63.6 (floor effect; distinctly impaired)	8	IQ = 63.6 (floor effect; distinctly impaired)
Wechsler Memory Scale (global memory) [10, 11]	93	50–70	32.5	MQ = 72.5 (subnormal)	32.5	MQ = 86 (low normal)	32.5	MQ = 67 (subnormal)
Information	6	6	4	subnormal	5	subnormal	3	subnormal
Orientation	5	5	4	subnormal	5	normal	3	subnormal
Mental control	9	4–8	3	subnormal	5	normal	5	normal
Semantic memory	23	5–13	4.5	subnormal	5	normal	1.5	subnormal
Digit span	15	8–12	7	subnormal	8	normal	8	normal
Visual reproduction	14	6–12	2.5	subnormal	3	subnormal	6.5	subnormal
Verbal paired associated learning	21	11–19	7.5	subnormal	11	normal	8	subnormal
Selective Reminding Test (verbal memory) [3, 11]	40	(25–40) (reproduction)	20	(subnormal)	21	(subnormal)	19	(subnormal)
Recurring Figures Test (visual memory) [12]	56	17–36	–1	T = 25 (severely impaired)	3	T = 28 (severely impaired)	3	T = 28 (severely impaired)
Continuous Figure Recognition (visual memory) [13]	66	(26–64)	34	normal range	39	normal range	16	subnormal
Syndrome Short Test (memory and attention) [14]	0 (maximum score of 27 = maximum deficit)	0–4	9	mild deficit	8	questionable or very mild deficit	18	severely impaired

<sup>1</sup> Comments in parentheses indicate functions assessed.

sodes. The neurological status did not show any change. CT scan revealed the defect caused by a brain biopsy and the same findings as before. SPECT also gave the same result as in the previous examination.

The relatives of the patient now reported severe memory deficits. The neuropsychological examination showed a deterioration of most subtests performed: constructive-apractic disturbances were most severe. The result of the Mini-Mental status was within the demented range for the first time, the memory quotient of the Wechsler Memory Scale was obviously subnormal. The results of the Syndrome Short Test and the Dementia Rating Scale according to Mattis also disclosed impressive deterioration (table 1). The diagnosis of AD could not be questioned any more.

## Discussion

### *Differential Diagnosis*

According to the results of serial neuropsychological examinations and the brain biopsy we diagnosed AD. The extensive WMC in MRI and the reduction of perfusion raised some possibilities of other differential diagnoses. Progressive multifocal leukoencephalopathy was excluded because tumor search was negative and the course too benign, encephalitis was not likely because CSF was normal. Metachromatic leukodystrophy was an unlikely diagnosis since serum arylsulfatase A was normal. Binswanger's disease was not probable, because the patient did not suffer from diabetes or hypertension. In the absence of risk factors there was not much reason to suppose she might have a severe atherosclerosis or arteriolosclerosis as an underlying disease, although this cannot be excluded from the performed imaging devices. The histopathological results also showed no signs of arteriolosclerosis.

Although the changes were much more pronounced on the right side, there were also signal alterations on the left side, which made tumor a very unlikely diagnosis.

### *Occurrence of WMC*

Recently many authors have described WMC in patients with AD [2, 15, 16, 18–25]. There is still considerable disagreement about the nature and significance of these changes in healthy persons, persons with cardiovascular risk factors, AD patients with early onset and AD patients with late onset.

Some authors think that WMC are unspecific occurring in all kinds of diseases such as senile dementia of Alzheimer type, Binswanger's disease [16] and even in clinically healthy persons [26].

Beyond a certain age, periventricular changes were found in almost 80% of patients older than 50 years with a

history of cerebrovascular risk factors [27], subcortical lesions being a very frequent incidental finding in elderly patients without having clinical significance. Therefore, some studies assume that WMC are not more frequent or relevant in AD patients than in healthy controls [25, 28], whereas others report differences in the frequency of WMC between AD patients and normal elderly [29].

However, the appearance of WMC in Alzheimer patients is usually different. Their distribution is more diffuse and they are not as hypodense as incidental findings.

### *Clinical Relevance of WMC for the Course of AD*

There is also disagreement about the clinical relevance of WMC for the course of AD and their relation to the severity of dementia. White matter lucencies, also termed leukoaraiosis, might represent a marker for early dementia [31]. They also may predict the development of clinically significant cerebrovascular disease [32]. Because WMC may only be found in some cases of AD, many authors [24, 25, 30] assume a high correlation between the age of disease onset and the presence of WMC. WMC are supposed [24, 30] to be more frequent and severe in the late-onset form of AD (age at onset beyond 66 years). One of these studies [30] might be questioned, because patients with vascular risk factors were not excluded. In contrast, some studies [20] suggest an association of the presence of white matter low attenuation not only with higher age but with a more severe degree of dementia and increased CSF/serum albumin ratio. Others could not establish a correlation of MRI white matter and periventricular hyperintensities with Mini Mental State Examination scores [25]. Another investigator assumes [16] that WMC are neither related to the severity nor to the regional appearance and accentuation of the cortical Alzheimer process. We believe that, as reported by Besson et al. [15] and Almkvist et al. [33], specific regional WMC and local perfusion deficits may result in specific focal neuropsychological impairment measurable by psychometric tests relating to certain brain areas. Our case does not support the notion of a correlation between severity of WMC and dementia but rather the existence of a relationship between localization of WMC and neuropsychological deficits. In spite of extensive changes on MRI our patient was not severely demented at the time the extensive focal WMC were noticed first and she had a normal CSF/serum albumin ratio. Thus, the case of our patient, who was 52 years old at onset and presented WMC, cannot support the notion of early onset being associated with less frequent or severe WMC.



The large MRI alterations were located prominently in the right hemisphere and the patient's constructive and spatial orientation deficits also pointed to the right hemisphere, whereas her other deficits were only mild and not very typical of AD at the early stage. Therefore the establishment of this diagnosis was difficult. It was only after follow-up that dementia became more evident.

#### *Etiology and Morphology of WMC*

The etiology of leukoencephalopathy in the elderly consists mainly of arteriolosclerosis and atherosclerosis [1]. Surprisingly, Ferrer [1] found the same morphology of lesions in Binswanger's disease, multi-infarct encephalopathy and AD and suggested that this might be the result of subacute hyperperfusion or hypoxic damage caused by different etiologies in different diseases. The cause of hypoperfusion in AD may be congophilic angiopathy of the meningeal and cortical vessels with moderate arteriolar hyalinosis in the white matter, leading to incomplete infarction. In contrast to this, Besson [15] believes that WMC in AD are caused by a higher free-to-bound water ratio compared to healthy persons. Either way findings may be explained by alteration of myelin structures, or by fluid increase in glial cells or in the extracellular compartment following loss of nerve fibers.

Selective incomplete white matter infarctions were found [17, 18] in areas where a reduction of gangliosides and changes in the ganglioside pattern reflected the histological degree of severity of the infarctions.

These studies confirm the theory of WMC being a subtotal infarction of myelin and axon. The brain biopsy of our patient showed senile plaques and a congophil angiopathy with intramural storing of amyloid and cortical and subcortical astrogliosis. Thus, we conclude that some cases of AD may also belong to the vascular diseases [34], although there are probably many interfering pathomechanisms involved. As considered by some investigators [35], AD might be a heterogenous disease.

#### *Perfusion Deficits and WMC*

In the HMPAO-SPECT examination our patient had a large perfusion deficit in the right temporal lobe in an area where WMC on MRI scan were most distinct. The histology of the brain biopsy from this area showed senile plaques and congophilic angiopathy. In our case the angiopathy may have led to incomplete infarction as an underlying cause of the WMC. SPECT might be helpful to establish the diagnosis AD, but careful interpretation of the results is necessary, because changes are frequent but may not be specific for AD [36, 37]. A perfusion deficit as

circumscribed as in our patient seems to be very rare. Anyway, the SPECT examination in this patient also showed that hypoperfused regions may give a hint as to the area responsible for the cognitive deficits.

#### **Conclusions**

This case of AD is very interesting due to various aspects. First, many authors have described WMC in AD patients before, whereas signal alterations as extensive as those in our case, which are not widely distributed but rather focused in the temporal lobes, are rare [38]. Brain biopsy was taken directly from the area most severely involved and showed the changes typical of AD. Second, for the first 3 years the course of the disease was benign although the focal WMC were already extensive. This supports the notion that the correlation between severity of MRI changes and severity of dementia is rather low.

Summing up we may say that the diagnostic relevance of WMC in AD is not yet fully understood, but it may pathogenetically resemble other diseases that cause WMC by the mechanism they cause incomplete infarctions, which might either lead to signs and symptoms or remain asymptomatic.

In our opinion brain biopsy is only warranted if the diagnosis is doubtful and some benefit for the patient may be anticipated. Nevertheless, larger series of biopsies will be required in order to clarify the etiology and diagnostic significance of white matter changes in patients with AD.

## References

- Ferrer I, Bella R, Serrano MT, Martí E, Guionnet N: Arteriolosclerotic leucoencephalopathy in the elderly and its relation to white matter lesions in Binswanger's disease, multi-infarct encephalopathy and Alzheimer's disease. *J Neurol Sci* 1990;98:37-50.
- Hachinski V, Potter P, Merskey H: Leuko-Araiosis. *Arch Neurol* 1987;44:21-23.
- Kessler J, Denzler P, Markowitsch HJ: Demenztest. Weinheim, Beltz, 1988.
- Folstein MF, Folstein SE, McHugh PR: Mini-mental state: A practical method for grading the cognitive state of patients for the clinician. *J Psychiatr Res* 1975;12:189-198.
- Wechsler D: A standardized memory scale for clinical use. *J Psychol* 1945;19:87-95.
- American Psychiatric Association: Diagnostic and Statistical Manual of Mental Disorders, ed 3, revised, Washington, American Psychiatric Association, 1987.
- Mattis S: Dementia rating scale; in Bellak R, Karasu B (eds): *Geriatric Psychiatry*. New York, Grune & Stratton, 1976, pp 108-121.
- Lehrl S: Mehrfachwahl-Wortschatz-Intelligenz-Test. Manual zum MWT perimed, Erlangen, 1977.
- Raven JC: *The Standard Progressive Matrices*. London, Lewis, 1974.
- Böcher W: Erfahrungen mit dem Wechsler'schen Gedächtnistest (Wechsler Memory Scale) bei einer deutschen Versuchsgruppe von 200 normalen Versuchspersonen. *Diagnostica* 1963;9:56-58.
- Buschke H: Selective reminding for analysis of memory and learning. *J Verbal Learn Verbal Behav* 1973;13:543-550.
- Kimura D: Right temporal lobe damage. *Arch Neurol* 1963;8:264-271.
- Lang C: Continuous figure recognition in dementia and unilateral brain damage. *Neuropsychologia* 1989;25:619-628.
- Erzigkeit H: Manual zum SKT Formen A-E. Eberberg, Vless, 1986.
- Besson JA, Crawford JR, Parker DM, Ebmeier KP, et al: Multimodal imaging in Alzheimer's disease. The relationship between MRI, SPECT, cognitive and pathological changes. *Br J Psychiatry* 1990;157:216-220.
- Brun A, Englund E: A white matter disorder in dementia of the Alzheimer type: A patho-anatomical study. *Ann Neurol* 1986;19:253-262.
- Englund E, Brun A, Gustafson L: A white matter disease in dementia of Alzheimer's type - biochemical and neuropathological correlates. *Brain* 1988;111:1425-1439.
- Englund E, Brun A, Svennerholm L: White matter gangliosides in incomplete infarction. *Dementia* 1990;1:286-291.
- Erkinjuntti T, Ketonen L, Sulkava R, Vuorioho M, Palo J: CT in the differential diagnosis between Alzheimer's disease and vascular dementia. *Acta Neurol Scand* 1987;75:262-270.
- Erkinjuntti T, Sulkava R, Palo J, Ketonen L: White matter low attenuation on CT in Alzheimer's disease. *Arch Gerontol Geriatr* 1989;8:95-104.
- Erkinjuntti T, Lee DH, Gao F, Steenhus R, Eliasziw M, Fry R, Merskey H, Hachinski VC: Temporal lobe atrophy on magnetic resonance imaging in the diagnosis of early Alzheimer's disease. *Arch Neurol* 1993;50:305-310.
- Kertesz A, Polk M, Carr T: Cognition and white matter changes on magnetic resonance imaging in dementia. *Arch Neurol* 1990;47:387-391.
- George AE, de Leon HJ, Kalmin A, Rosner L, Goodgold A, Chase N: Leukoencephalopathy in normal and pathologic aging II. MRI of brain lucencies. *Am J Neuroradiol* 1986;7:567-570.
- Wallin A, Blennow K, Uhlemann C, Längström G, Gottfries CG: White matter low attenuation on computed tomography in Alzheimer's disease and vascular dementia - diagnostic and pathogenetic aspects. *Acta Neurol Scand* 1989;80:518-523.
- Leys D, Soetart G, Petit H, Fauquette A, Pruvo JP, Steinling M: Periventricular and white matter magnetic resonance imaging hyperintensities do not differ between Alzheimer's disease and normal aging. *Arch Neurol* 1990;47:524-527.
- Awad IA, Spetzler RF, Hodak JA, Awad CA, Carey R: Incidental subcortical lesions identified on magnetic resonance imaging in the elderly. I. Correlation with age and cerebrovascular risk factors. *Stroke* 1986;17:1084-1089.
- Gerard G, Weisberg LA: MRI periventricular lesions in adults. *Neurology* 1986;36:998-1001.
- Kozachuk WE, DeCarli C, Schapiro M, Wagner EE, Rapoport SI, Horwitz B: White matter hyperintensities in dementia of Alzheimer's type and in healthy subjects without cerebrovascular risk factors. *Arch Neurol* 1990;47:1306-1310.
- Rezek DL, Morris JC, Fulling KH, Gado MH: Periventricular white matter lucencies in senile dementia of the Alzheimer type and in normal aging. *Neurology* 1987;37:1365-1368.
- Blennow K, Wallin A, Uhlemann C, Gottfries CG: White-matter lesions on CT in Alzheimer patients: Relation to clinical symptomatology and vascular factors. *Acta Neurol Scand* 1991;83:187-193.
- Steingart A, Hachinski VC, Lau C, et al: Cognitive and neurological findings in demented patients with diffuse white matter lucencies on computed tomographic scan (leuko-araiosis). *Arch Neurol* 1987;44:32-35.
- Lopez OL, Becker JT, Rezek D, Wess J, Boller F, Reynolds III CF, Panisset M: Neuropsychiatric correlates of cerebral white-matter radiolucencies in probable Alzheimer's disease. *Arch Neurol* 1992;49:828-834.
- Almkvist O, Wahlund LO, Andersson-Lundmann G, Basun H, Bäckman L: White-matter hyperintensity and neuropsychological functions in dementia and healthy aging. *Arch Neurol* 1992;49:626-632.
- Lang C: Multiinfarkt- und Alzheimersche Demenz - Differentialdiagnostische Probleme. *Acta Histochem* 1992(suppl):42:13-18.
- Scheltens PH, Barkhof F, Valk J, Algra PR, Gerritsen van der Hoop R, Nauta J, Wolters ECH: White matter lesions on magnetic resonance imaging in clinically diagnosed Alzheimer's disease. Evidence for heterogeneity. *Brain* 1992;115:735-748.
- Curran SM, Murray CM, Van Beck M, Dougall N, O'Carroll RE, Austin MP, Ebmeier KP, Goodwin GM: A single photon emission computerised tomography study of regional brain function in elderly patients with major depression and with Alzheimer-type dementia. *Br J Psychiatry* 1993;163:155-165.
- Bonte FJ, Tintner R, Weiner MF, Bigio EH, White CL: Brain blood flow in the dementias: SPECT with histopathologic correlation. *Radiology* 1993;186:361-365.
- Jagust WJ, Cavies P, Tiller-Borich JK, Reed BR: Focal Alzheimer's disease. *Neurology* 1990;40:14-19.