

Siobhan M. Gormally  
William Bourke  
Barry Kierse  
Hugh Monaghan  
Joe McMenamin  
Brendan Drumm

## Isolated cerebral thrombo-embolism and Crohn disease

Received: 18 August 1994  
Accepted: 7 March 1995

S. M. Gormally · W. Bourke · B. Kierse  
H. Monaghan · J. McMenamin  
Department of Paediatrics,  
University College Dublin,  
Ireland

B. Drumm (✉)  
Department of Paediatrics,  
Our Lady's Hospital for Sick Children,  
Crumlin, Dublin 12, Ireland  
Te.: (01)45569101  
Fax: (01)4555307

**Abstract** Arterial thrombo-embolism is an unusual complication in inflammatory bowel disease in adults and children. Cerebral arterial disease has been reported on only a few occasions. There are only two previous case reports of arterial disease occurring in a child with Crohn disease. However in both instances the arterial disease was part of a generalised Takayasu arteritis which resulted in multi-organ involvement. This report describes a 14-year-old boy who developed seizures before a histological diagnosis of Crohn disease was made. These seizures were

the result of a vascular lesion which was confined to the right middle cerebral artery.

**Conclusion** Crohn disease as well as ulcerative colitis should be considered as a possible cause of cerebrovascular accidents in children

**Key words** Crohn disease · Childhood · Cerebral thrombo-embolism · Seizures

**Abbreviation** IBD inflammatory bowel disease

### Introduction

Crohn disease is a chronic, transmural, inflammatory process affecting any part of the bowel from mouth to anus in a discontinuous fashion [6, 7]. Histologically it is characterised by the presence of non-caseating granuloma. It has an overall incidence of 3.5 per 100,000 with a prevalence of 46 per 100,000 [2, 4, 5, 14]. Children with Crohn disease may present with nonspecific extra-intestinal manifestations and growth retardation [16].

Thrombo-embolic phenomena are a rare, but well-documented complication of inflammatory bowel disease (IBD) in adults [1, 3, 8, 17, 18]. The majority involve venous thrombo-embolism. There have been few case reports of children with vascular complications of IBD [9, 12, 13, 15, 20]. There are two reports of arterial disease occurring in children with Crohn disease [20, 22] but in both of these cases involvement was associated with a generalised Takayasu arteritis, which affected many major arteries.

We report the occurrence of an isolated cerebral arterial thrombo-embolism in a boy with Crohn disease.

### Case report

A 14-year-old boy was referred to the Gastro-enterology Department with a 5-month history of abdominal pain, weight loss, lethargy and anorexia. He had intermittent "red eyes" which were not painful. There was no family history of gastro-intestinal disease. Examination revealed a pale, cachectic boy whose weight of 36 kg was less than the 3rd percentile and who had clubbing. He had lower abdominal tenderness. A clean perianal fissure and two skin tags were noted. A decision was made to admit him over the following week for an upper and lower endoscopy to rule out IBD.

Three days later he was admitted to the hospital with a history of sudden onset right-sided headache. This was associated with a diminution in vision to the left. Subsequently he had two generalised tonic-clonic seizures. On examination he was drowsy, his pupils were equal and reacting to light and there was no papilloedema or neck stiffness. He was moving all limbs spontaneously but had generalised hypotonia and hyporeflexia. There were no localising signs.

He was admitted to hospital and over the following 12 h he had five convulsions beginning on the left side with generalisation. His eyes were consistently deviated to the left between seizures. Twelve hours post admission he developed status epilepticus.

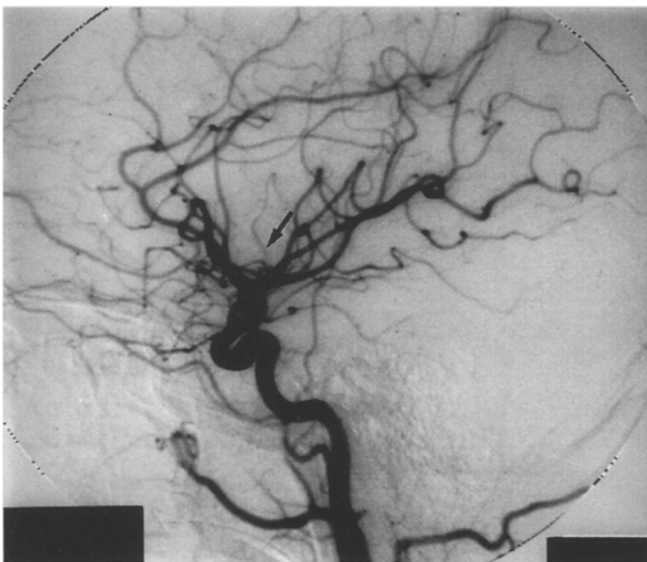
Investigations revealed a Hb 13.8 g/dl, white cell count  $28.1 \times 10^9/l$  (87.6% granulocytes), platelet count  $517 \times 10^9/l$ , plasma viscosity 1.53 mPa (normal values = 1.5–1.72 mPa) and an ESR of 60 mm/h. Prothrombin time, partial thromboplastin time, calcium, magnesium, urea and electrolytes were all normal. CSF was clear and colourless, with one white cell, 4 red cells per  $mm^3$  and protein content of 0.2 h/l. A toxicology screen was negative. A computed tomography of the brain on the night of admission was normal.

The seizures became intractable over the next 8 weeks, during which he was treated with intravenous phenytoin, phenobarbitone and paraldehyde. Intermittent Positive Pressure Ventilation was required due to the respiratory depressive effect of the anticonvulsant medication. EEG initially showed continuous bilateral and generalised spike wave activity without lateralisation, intermixed with periodic flattening. Subsequently studies confirmed periodic lateralising epileptiform discharges mainly over the right hemisphere.

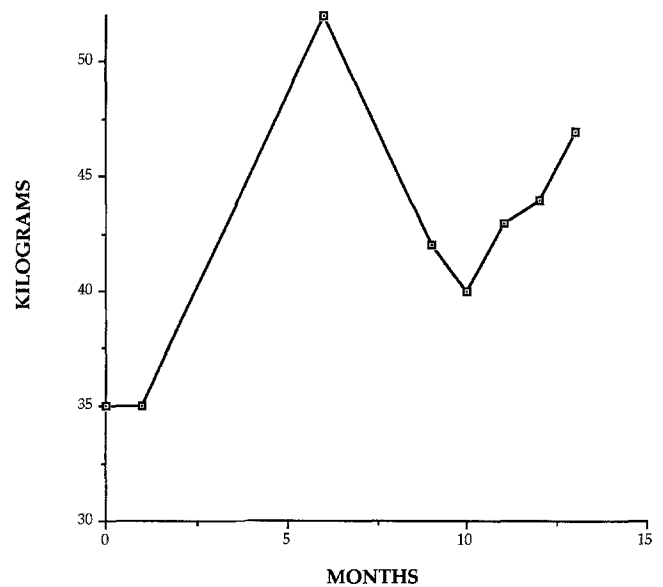
Neurological examination now revealed hypotonia in the left upper and lower limbs, and paucity of movements with a left facial weakness. When seizures eventually subsided with a chlormethiazole infusion, a dense residual left hemiplegia was apparent. A cerebral angiogram performed 4 weeks after admission showed a significant reduction in the calibre of the ascending prerolandic branch of the right middle cerebral artery consistent with thrombo-embolic occlusion (Fig. 1).

Repeated upper endoscopy and colonoscopy revealed a normal intestinal mucosa. Multiple gastro-intestinal biopsies were obtained from the stomach, duodenum, small bowel and colon. However histological evidence of inflammation was not identified. A barium meal showed dilated loops of jejunum with coarsening of mucosal folds. Ophthalmological examination showed no evidence of retinal vasculitis.

A decision was made to treat the patient empirically as having Crohn disease using corticosteroids (intravenous hydrocortisone 4 mg/kg/dose 4-hourly followed by prednisolone 1 mg/kg/day



**Fig. 1** The lateral carotid angiogram shows poor opacification of the ascending pre-central branch of the middle cerebral artery consistent with proximal embolic/thrombotic occlusion



**Fig. 2** Patient's weight over a 15-month period following initial presentation. An elemental diet consisting of 2400 kcal/day began at 2 months. The diet was discontinued at 6 months and reinstated at 10 months

orally when tolerated), total parenteral nutrition and subsequently an elemental diet. This tentative diagnosis of Crohn disease was supported by a dramatic response to such treatment. His weight increased to 52 kg over a period of 4 months and this was associated with a marked improvement in symptomatology. The abdominal pain resolved and there was an improvement in energy level and appetite. A temporary lapse in compliance with the elemental diet post discharge was associated with a recurrence of anorexia, abdominal pain and weight loss. These symptoms disappeared following reinstatement of the elemental diet (Fig. 2).

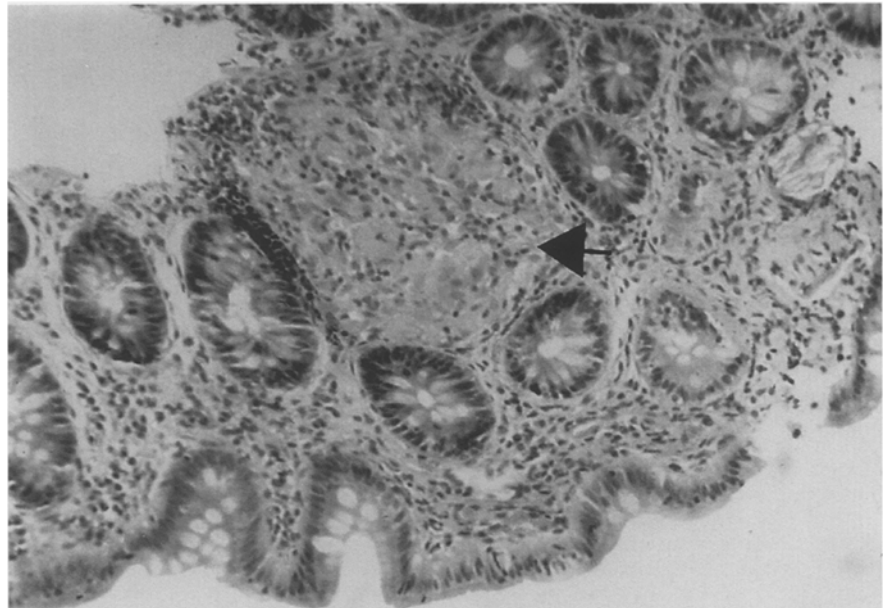
A programme of physical and occupational therapy was instituted. The patient's hemiplegia improved over a 6-month period. However, 18 months after presentation he continues to have a marked left hemiparesis with improvement over the past year.

Eight months after initial presentation a further colonoscopy was performed. Although bowel mucosa appeared normal, a non-caseating granuloma comprising of epithelioid cells, activated histiocytes and multinucleated giant cells, consistent with Crohn disease, was identified in a biopsy specimen taken from the caecum (Fig. 3).

## Discussion

Extra-intestinal symptoms are well-known in Crohn disease and may be the presenting features of the disease. Classically they comprise of growth failure, dermatological, ocular, skeletal and hepatobiliary manifestations. Vascular events in IBD are rare. There are, to our knowledge, ten case reports of thrombo-embolic events in children with IBD – seven of these occurring in association with ulcerative colitis. There are three putative cases reported in association with Crohn disease (Table 1). Two patients were described by Yassenger et al. [22] and Van Elburg et al. [20]. In both cases, arterial involvement was part of a

**Fig. 3** Histology of biopsy from caecum, showing a well formed epithelioid granuloma (arrow) in a lymphoid aggregate in the lamina propria



**Table 1** Vascular complications in children with Crohn disease

Reference	Age	Sex	Vascular involvement	CNS	Outcome
Yassinger et al. [22]	15	F	Multiple large vessel stenosis	Hemiparesis	Resolved
Van Elburg et al. [20]	14	F	Multiple large vessel stenosis	None	
Gormally et al. (present report)	14	M	Right middle cerebral artery narrowing	Hemiplegia	Marked hemiparesis

generalised Takayasu arteritis involving other major arteries in the body. The case reported by Van Elburg et al. [20] was similar to ours in that the histological diagnosis of Crohn post-dated the vascular involvement. A third case report by Lloyd-Still and Tomasi [12] while interesting, cannot be included in this group. These authors described a 3-month-old baby with a diagnosis of "enterocolitis" who simultaneously had intractable seizures and mental retardation. No angiographic studies were performed and at post-mortem, typical histological features of Crohn disease could not be detected.

The cause of vascular complications in IBD is unknown. There is speculation that they may be related to a hypercoagulable state. Haemostatic alterations include thrombocytosis, platelet dysfunction, increased levels of fibrinogen, factors V and VIII and a decrease in an-

tithrombin III activity but these have not been consistently identified [10, 11]. The exact pathological process involved in these vascular events has not been established. Necrotising vasculitis, Takayasu arteritis and giant cell arteritis have all been implicated [19, 22]. Takayasu arteritis would certainly explain the widespread involvement of arteries as described in the two previous reports [20, 22].

Histological examination of the arteries was not performed in this case therefore one can only speculate about the aetiology of the arterial lesion. The fact that arterial involvement was so localised makes Takayasu arteritis unlikely. Giant cell arteritis must be a possible underlying pathology as this is a patchy granulomatous inflammation that effects medium-sized arteries anywhere in the body [19, 21] and has a predilection for cranial arteries.

Cerebral arterial lesions in IBD can have catastrophic consequences. The widespread involvement of other major arteries has hitherto provided some clue to the underlying process in a child with IBD presenting with seizures. The vascular lesions in this case were confined solely to the right middle cerebral artery. It is of clinical importance therefore to be aware of the fact that neurological symptoms in IBD can be secondary to isolated cerebral vasculopathy and are not always accompanied by a widespread arteropathy as previously described.

**Acknowledgements** We wish to acknowledge the help of Dr. J. Toland, Consultant Neuroradiologist, Beaumont Hospital, Dublin, in interpreting the angiographic study and to Ms. Sharon Kearney for typing the manuscript.

## References

1. Bagen JA, Barker NW (1936) Extensive arterial and venous thrombosis complicating chronic ulcerative colitis. *Arch Intern Med* 58: 17-31
2. Booth IW (1991) Chronic inflammatory bowel disease. *Arch Dis Child* 66: 742-744
3. Braverman D, Bogoch A (1978) Arterial thrombosis in ulcerative colitis: *Am J Dig Dis* 23: 1148-1150
4. Burbidge FJ, Huang S, Bayless TM (1975) Clinical manifestations of Crohn's disease in children and adolescence. *Pediatrics* 55: 866
5. Calkins BM, Lilienfeld Am, Garland CF, Mendeloff AI (1984) Trends in incidence rates of ulcerative colitis and Crohn's disease. *Dig Dis Sci* 29: 913
6. Crohn BB (1967) Granulomatous disease of the large and small bowel, a histological survey. *Gastroenterology* 52: 767
7. Crohn BB, Ginzburg L, Oppenheimer GD (1932) Regional Enteritis: A pathological and clinical entity. *JAMA* 99: 1323
8. Kehoe EL, Newcomer KL (1964) Thromboembolic phenomena in ulcerative colitis. *Arch Intern Med* 113: 711-715
9. Koenigs KP, McPhedran P, Spiro HM (1987) Thrombosis in inflammatory bowel disease. *J Clin Gastroenterol* 9: 627-631
10. Lake AM, Stauffer JQ, Stuart MJ (1978) Hemostatic alterations in inflammatory bowel disease. *Dig Dis Sci* 23: 897-902
11. Lama A, Borda IT, Inwood MJ, et al (1975) Coagulation studies in ulcerative colitis and Crohn's Disease. *Gastroenterology* 68: 245-251
12. Lloyd-Still Jd, Tomasi L (1989) Neurovascular and thromboembolic complications of inflammatory bowel disease in childhood. *J Pediatric Gastroenterol Nutr* 9: 461-466
13. Markowitz RL, Ment LR, Gryboski JD (1989) Cerebral thromboembolic disease in pediatric and adult inflammatory disease: case report and review of the literature. *J Pediatric Gastroenterol Nutr* 8: 413-420
14. Miller RC, Jackson M, Larson E (1971) Regional enteritis in early infancy. *Am J Dis Child* 122: 301-311
15. Paradis K, Bernstein ML, Adelson JW (1985) Thrombosis as a complication of inflammatory bowel disease in children: a report of 4 cases. *J Pediatr Gastroenterol Nutr* 4: 659-662
16. Rankin GB, Watts HD, Melynk CS, et al (1979) The National Cooperative Crohn's Disease Study: extraintestinal manifestations and perianal complications. *Gastroenterology* 77: 914-920
17. Schneiderman JH, Sharpe JA, Sutton DMC (1979) Cerebral and retinal vascular complications of inflammatory bowel disease. *Ann Neurol* 5: 331-337
18. Talbot RW, Heppell J, Dazois RR, Beart RW (1986) Vascular complications of inflammatory bowel disease. *Mayo Clin Proc* 61: 140-145
19. Teja K, Crum CP, Friedman C (1980) Giant cell arteritis in Crohn's disease. An unreported association. *Gastroenterology* 78: 796-802
20. Van Elburg RM, Henar EL, Bijleverd MA, Pins TR, Heymans HSA (1992) Vascular compromise prior to intestinal manifestations of Crohn's disease in a 14 year old girl. *J Pediatric Gastroenterol Nutr* 14: 97-100
21. Wilske KR, Healey LA (1967) Polymyalgia rheumatica. A manifestation of systemic giant cell arteritis. *Ann Intern Med* 66: 77
22. Yassinger S, Adelman R, Cantor D, Bolt RJ (1976) Association of inflammatory bowel disease and large vascular lesions. *Gastroenterology* 71: 844-846