

2. Lederman RJ, Breuer AC, Hanson MR, et al. Peripheral nervous system complications of coronary artery bypass graft surgery. *Ann Neurol* 1982;12:297-301.
3. Hanson MR, Breuer AC, Furlan AJ, et al. Mechanism and frequency of brachial plexus injury in open-heart surgery: a prospective analysis. *Ann Thorac Surg* 1983;36:675-679.
4. Van der Salm TJ, Cereda JM, Cutler BS. Brachial plexus injury following median sternotomy. *J Thorac Cardiovasc Surg* 1980;80:447-452.
5. Ewing MR. Postoperative paralysis in the upper extremity. *Lancet* 1950;1:99-105.
6. Clausen EG. Postoperative ("anesthetic") paralysis of the brachial plexus. *Surgery* 1942;12:933-942.
7. Britt BA, Gordon RA. Peripheral nerve injuries associated with anaesthesia. *Can Anaesth Soc J* 1964;11:514-536.
8. Jackson L, Keats AS. Mechanism of brachial plexus palsy following anesthesia. *Anesthesiology* 1965;26:190-194.
9. Honet JC, Raikes JA, Kantrowitz A, et al. Neuropathy in the upper extremity after open-heart surgery. *Arch Phys Med Rehabil* 1976;57:264-267.
10. Kirsh MM, Magee KR, Gago O, et al. Brachial plexus injury following median sternotomy incision. *Ann Thorac Surg* 1971;11:315-319.
11. Curtis JA, Libshitz HI, Dalinka MK. Fracture of the first rib as a complication of midline sternotomy. *Radiology* 1975;115:63-65.
12. Stephens JW. Neurological sequelae of congenital heart surgery. *Arch Neurol* 1962;7:450-459.
13. Richardson JD, McElvein RB, Trinkle JK. First rib fracture. A hallmark of severe trauma. *Ann Surg* 1975;181:251-254.
14. Breslin FJ. Fractures of first rib unassociated with fractures of other ribs. *Am J Surg* 1937;38:384-389.
15. Holmes TW, Netterville RE. Complications of first rib fracture, including one case each of tracheoesophageal fistula and aortic arch aneurysm. *J Thorac Surg* 1956;32:74-91.
16. Keane JR. Oculosympathetic paresis: analysis of 100 hospitalized patients. *Arch Neurol* 1979;36:13-15.
17. Sears ML, Kier EL, Chavis RM. Horner's syndrome caused by occlusion of the vascular supply to sympathetic ganglia. *Am J Ophthalmol* 1974;77:717-724.
18. Giles CL, Henderson JW. Horner's syndrome: an analysis of 216 cases. *Am J Ophthalmol* 1954;46:289-291.
19. Adar R, Kurchin A, Zweig A, Mozes M. Palmar hyperhidrosis and its surgical treatment: a report of 100 cases. *Ann Surg* 1977;186:34-41.
20. Fleiss JL. Statistical methods for rates and proportions. 2nd ed. New York: Wiley, 1981.
21. Maries H, Joyau FH. Transient acute respiratory failure and thoracic epidural anesthesia. *Ann Fr Anesth Reanim* 1989;8:140-142.

Unilateral spatial neglect recovery after sequential strokes

P. Vuilleumier, MD; D. Hester, MD; G. Assal, MD; and F. Regli, MD

Article abstract—We describe a patient who had sequential strokes in both hemispheres with a severe unilateral spatial neglect after a first right-sided parietal infarct and abrupt disappearance of the neglect after a second left-sided frontal infarct. The first lesion involved the caudalmost right angular gyrus (area 39), whereas the second lesion involved the left frontal eye field (area 8) and surrounding cortex. Those two cortical areas are assumed to have a pivotal role in modulating both shifts of attention within extrapersonal space and saccadic eye movements through their connections with subcortical structures, in particular, superior colliculi and thalamic nuclei. Our case supports the existence of a distributed anatomic-functional network in subserving directed spatial attention.

NEUROLOGY 19;:184-189

Unilateral spatial neglect (i.e., failure to attend, respond, or orient to external stimuli in the hemispace opposite a brain lesion) can be produced by focal damage to several different cortical or subcortical areas in either of both hemispheres.¹⁻⁵ These structures probably interconnect in a distributed anatomic-functional network subserving the spatial distribution of directed attention.^{1,2,6} Although severe and persistent neglect occurs mostly after injury affecting the right parietal lobe,¹⁻⁶ frontal lobe lesions may cause a similar disorder,^{1,5,7-10} and in some studies investigators found an unexpected predominance of left-sided lesions in those cases.^{5,8}

We report a patient who showed typical left spa-

tial neglect after a first right-sided parietal infarct and whose neglect abruptly and completely cleared after a second left-sided frontal stroke a few days later. Daffner et al⁹ reported that sequential frontal/parietal strokes in the same hemisphere worsened the neglect syndrome. Our patient's recovery of neglect after a second lesion in the opposite hemisphere is the first to be reported.

Case report. Two days before admission to our department (February 7), a 74-year-old, right-handed man noticed sudden difficulty in using his left hand; he experienced clumsiness and slight weakness but had no sensory disturbances. The next day, he became aware of ill-defined

From the Departments of Neuropsychology (Drs. Vuilleumier, Hester, and Assal) and Neurology (Drs. Vuilleumier and Regli), Centre Hospitalier Universitaire Vaudois (CHUV), Lausanne, Switzerland.

Received December 6, 1994. Accepted in final form April 18, 1995.

Address correspondence and reprint requests to Dr. P. Vuilleumier, Division de neuropsychologie, Centre Hospitalier Universitaire Vaudois (CHUV), 1011 Lausanne, Switzerland.

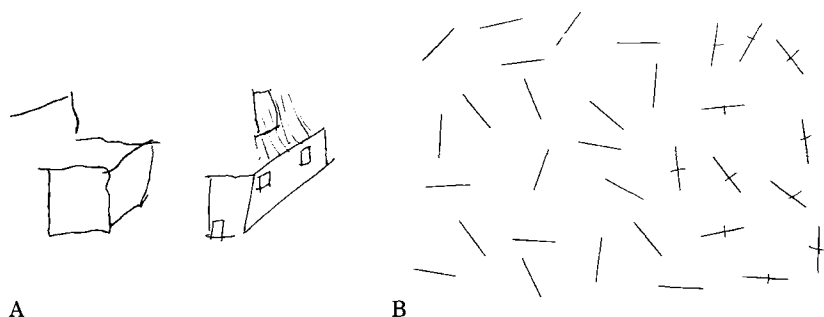


Figure 1. Left spatial neglect shown in (A) drawings of a cube and a house and in (B) a line-crossing task, 4 days after the first right-sided parietal stroke.

visual difficulties, especially when he tried to drive, and his wife reported that he was constantly drifting to the right. The patient had hypertension and hyperlipidemia, and he smoked cigarettes. Twenty-five years before, he had a myocardial infarction; fourteen years before, he had two transient ischemic attacks, with right arm weakness once and isolated diplopia once.

On admission (February 9), the patient was fully oriented and cooperative. The neurologic examination revealed only a slight pronation drift of outstretched arm and slowing of finger movements on the left side, with minimal terminal finger-to-nose dysmetria on eye closure. Strength and tendon reflexes were unremarkable and plantar response flexor and tact, pain, vibration, position, pressure, and directional sensation were all intact, as were graphesthesia and stereognosis. Only the localization with the opposite hand of a point touched by the examiner on the patient's left arm (topesthesia) was impaired. Cranial nerve functions were preserved, except for confrontational testing of the visual fields, suggesting a left homonymous hemianopia: Even a unilateral target in his left visual field was not detected by the patient, with marked demarcation on midline. Optokinetic nystagmus to the left was abolished. The general physical examination was otherwise unremarkable.

A first neuropsychological assessment¹¹ was performed 4 days after the stroke onset (February 11). The patient was alert and cooperative but moderately slow and easily tired. His facial expression was poor and he seemed irritable. He complained about visual difficulties and trouble with reading ("the letters get mixed up"). Language abilities were clearly preserved (fluent and informative speech, no naming or comprehension difficulties). He easily read letters and single words. When reading a text, however, the patient neglected words at the left and stopped, perplexed at the incoherence of the text. Writing upon dictation was unimpaired but confined to the right side of the page. The verbal span was excellent and his memory intact.

His praxic abilities were good, although neglect was again noticeable. The patient did not use his left upper limb when executing bimanual ideomotor actions that were demonstrated by the examiner in front of him. He omitted the left side of various drawings he was asked to reproduce (cube, house, flowers in a pot; figure 1A).

Performances of tasks such as crossing out lines and letter cancellation showed typical left hemispatial neglect (figure 1B). His line bisection showed a rightward deviation (mean, 3.2 cm; 16%). On the Gainotti et al¹² Overlapping Figures Recognition task, the patient mentioned no items situated on the left side. His description of the

Cookie Theft picture was the following: "Curtains, a window, a cupboard, cups . . . there is nobody." This corresponds to about one-fifth of the picture to the righthand side. The patient demonstrated a left ear extinction on bilateral auditory stimulation but no extinction on bilateral tactile stimulation. He lacked unilateral motor imper-sistence and motor extinction. His verbal evocation from memory of familiar city places or streets did not elicit representational neglect.

Testing of visual gnostic abilities showed that the patient had difficulties orientating himself on a geographical map, although he easily recognized the map. His schematic drawing of the hospital room was incorrect insofar as alteration of the relative spatial relationships of objects within it, but without evidence of unilateral spatial omissions. He was severely impaired on Benton's Line-Orientation Judgment test, even for lines situated on the righthand side of the page. Conversely, he could easily discriminate superimposed drawings of objects and had no trouble recognizing pictures of well-known personalities.

Brain CT on admission showed only an old lacunar infarct in the left supracapsular white matter, and a second CT 7 days after stroke onset (February 14) revealed a recent superficial parieto-occipital infarct on the right side, in the junctional territory between middle and posterior cerebral arteries (figure 2). Doppler ultrasounds revealed a marked stenosis (>70%) of the right internal carotid artery.

In the following days, the patient's left hemispatial neglect remained unvaryingly severe and was obvious in his daily activities, such as shaving only the right side of his face, eating from only right-sided dishes on the table, dressing only the right half of his body, looking for or asking for objects situated on the nearby left-sided night-table, and so on. There was no noticeable behavioral change on the neurologic examination performed every day by the medical staff on the patient's daily visit of the ward, nor according to the nurses' observations (the patient had been admitted in the Stroke Intensive Care Unit of our department).

On the tenth day (February 17), conventional arteriography was performed. According to protocol, the patient underwent a complete neurologic examination on the morning of this day at about 9 AM; left neglect was still present at that time. The angiogram was taken at 2 PM and confirmed the right internal carotid artery stenosis, but unfortunately, at the end of this procedure, a complication occurred and the patient became mute. A neurologic examination at 3 PM, while he was still in the arteriography room, revealed that the patient was awake, could execute semicomplex orders, and could respond with appropriate

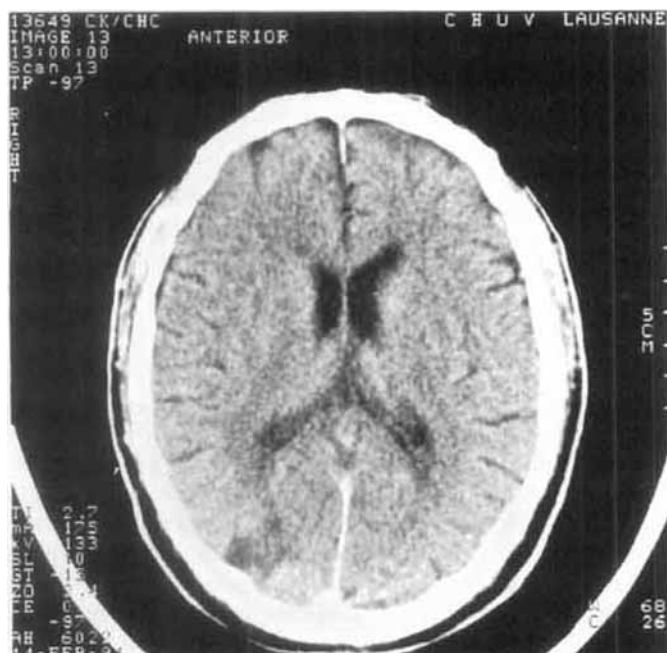

Figure 2. Brain CT showing infarct of the right posterior parietal lobe, 7 days after the first stroke onset.

facial expressions, but could not emit any sound nor write. He now had a right central facial palsy, right arm weakness, and hyperreflexia, with right hand grasping and a frank right Babinski sign. Spontaneous head and gaze deviation to the left was striking, as was the disappearance of the previously suspected left hemianopia and left hemispatial neglect signs. The patient could now point to visual stimuli presented in either visual field and showed no extinction on bilateral simultaneous stimulation. In spite of his leftward gaze deviation, he now correctly oriented himself to the right as well as to the left side when he was called by his name from different locations around his bed. He correctly rose either one or both of his arms to verbal command. On further bedside testing, his drawing of a cube on demand showed no evidence of unilateral (either left or right) neglect anymore, although he heavily persevered on single lines. Similarly, his unsuccessful and persevering attempts to write (usually repetitions of the first letters of his name or of dictated words) were equally distributed on both sides of the page. He also ate now both left- and right-sided food on his plate and spontaneously drank from his glass wherever it was in front of him. After remaining mute and apathetic for the 3 next days, the patient progressively regained nonfluent but informative language abilities, and the right hemiparesis receded.

A second neuropsychological assessment was performed 6 days after the second stroke (February 23). The patient was fully oriented and cooperative and less slow but still easily tired. He appeared distressed and perplexed at his new inability to speak, but he also laughed at times, rather unexpectedly. Speech assessment showed a transcortical/motor aphasia (nonfluent speech, with severe word-finding difficulties and a tendency for echolalia, low to normal score on the Boston Naming test, excellent repetition, agraphia, and moderate reading difficulties without evidence of neglect) and moderate alteration of comprehension (50% correct responses on the Token test).

Constructive and ideomotor praxic abilities were preserved, and this time no signs of hemineglect were noticed (figure 3A). There was no orofacial apraxia. The patient showed adequate visual scanning and description of complex drawings, and tests of crossing out lines and letter cancellation both failed to reveal any significant omission (figure 3B). He performed normally on the Bell Circling task of Gauthier et al.¹³ (circling of 35 bells drawn on a page among 265 distractors), as well as on the Overlapping Figures Recognition task of Gainotti et al.¹² Mean rightward deviation on line bisection regressed (1.6 cm, 8%).

To disclose more subtle impairment of searching strategies, we designed two additional tests. In the first test, one fine detail taken from a picture (black-and-white engraving) was presented to the patient, who was then asked to find the same detail on the whole A4-sized original picture. The patient detected the target detail on each of 12 trials with different pictures, equally promptly (mean time, 8 sec) for all the five spatial areas considered (i.e., four left/right and up/down quadrants, plus the central zone). In the second test, the patient was given arrays of 140 small line drawings on an A3 paper sheet and was asked to locate one unique drawing dissimilar to the surrounding 139 distractors, which consisted of five other different line drawings equally distributed. We divided the field into six equal sections (left/central/right and up/down) and compared the time used to find the target and the number in each one of them. No hemispatial neglect was evident in this task in more than 60 different trials. There was no neglect in an exploratory task, where the patient had to pick up small sticks from an array displayed on a table while he was blindfolded. There was no extinction on bilateral auditory, visual, or tactile stimulation.

Testing of visual gnostic abilities showed improved performances when drawing a map of the room. Performance on Benton's line-orientation judgment test was also improved but still moderately deficient. Recognition of superimposed-objects drawings and famous faces remained

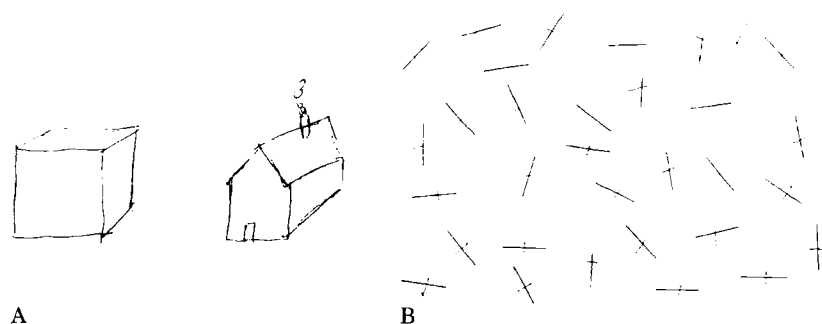


Figure 3. Resolution of neglect shown in (A) drawings of a cube and a house and in (B) a line-crossing task, 6 days after the second left-sided frontal stroke.

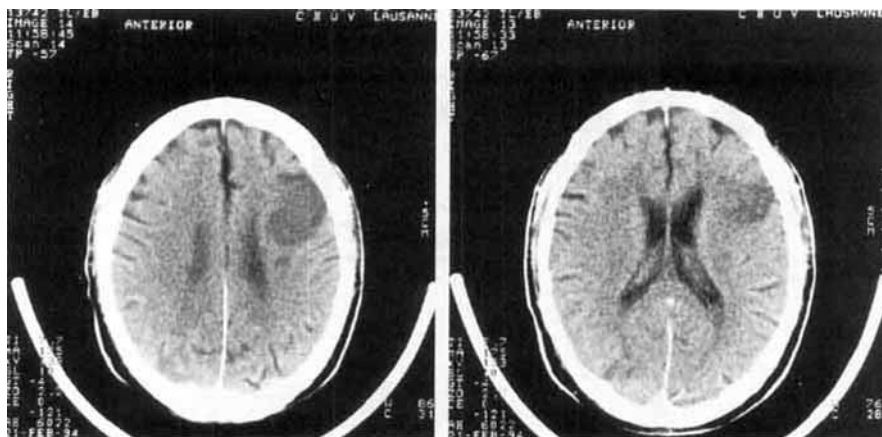


Figure 4. Brain CT showing infarct of the left dorsolateral frontal lobe, four days after the second stroke onset.

good. The copy of Rey's Figure was structurally disorganized.

Repeated brain CT (February 21) revealed a new cortical-subcortical infarction of the left dorsolateral frontal lobe and unchanged previously noted lesions (figure 4).

Discussion. After a first right-sided infarction in the posterior parietal lobe, our patient showed a typical left visuospatial neglect¹⁻³ that abruptly vanished after a second left-sided frontal stroke a few days later. At the time of the first stroke, neglect was severe and rather pure, unaccompanied by significant sensory or motor defects. The disorder was manifest in the patient's everyday behavior, as well as in reading and in several visuospatial tasks. It was associated with auditory but not tactile left extinction for bilateral stimuli.¹⁴ Left visual inattention was so severe that even unilateral stimuli on the left were ignored and we initially thought the patient had a superimposed hemianopia, which was later disproved. The visual pathways were thus undamaged, and pseudohemianopia probably arose because of the severe unilateral spatial neglect.^{15,16} Although the patient also failed to use his left limb in imitating bimanual postures, there was no motor neglect in bilateral movements to verbal command or to bilateral tactile stimulation,¹ nor in the spontaneous use of his left hand in everyday activities. This suggests that the patient's neglect resulted primarily from a failure of attentional mechanisms directed toward the contralesional extrapersonal space, rather than from action-intentional or representational disorders.¹

The patient's parietal lesion appeared to be centered on the dorsal aspect of Brodman's area 39, just beneath its junction with area 7 (figure 5).¹⁷ Damage to the caudal inferior parietal lobule appears to be critical in producing multimodal inattention toward the contralateral hemispace in both humans and monkeys.^{1-3,6,18} In monkeys, however, the inferior parietal lobule corresponds to area 7 and area 39 is absent, whereas in humans, the inferior parietal lobule consists of areas 39 (caudally) and 40 (rostrally) and area 7 corresponds to the superior parietal lobule.^{3,19}

The cortical area in the dorsal angular gyrus, constituting the ventral lip of the intraparietal sulcus, corresponds precisely to the architectonic pneumoencephalographic (PEG) area, which Eidelberg and Galaburda²⁰ found to have a rightward size lateralization in human brains. Our case thus supports the role of area 39 in the caudal inferior parietal lobule in mediating visuospatial attention in humans,^{1,21} as distinct from the superior parietal lobule,^{3,19} and we postulate that the PEG area represents an anatomic substrate for visual attention-orienting mechanisms in humans.

The patient's left hemispatial neglect was apparently instantaneously cancelled by the second stroke that occurred 10 days later in the left dorsolateral frontal lobe, opposite the first lesion. The previous pseudohemianopia vanished, as did all other neglect manifestations. Tasks that emphasize scanning or exploratory behavior, which are considered typical of attentional or intentional disorders caused by frontal lesions,^{1,3,9} did not disclose asymmetrical performances. We cannot totally exclude that neglect resolved independently of the second stroke. The first parietal stroke was small, and spontaneous recovery of neglect is more rapid with smaller lesions than with larger ones.²² However, in most patients with a hemispatial inattention disorder as severe as in our patient, recovery occurs progressively within several weeks.^{22,23} Furthermore, although there is a 12-day interval between the first and second detailed neuropsychological assessments, the presence of unilateral spatial neglect was clearly documented a few hours before the second stroke, just as the striking and abrupt change in the patient's behavior was evident from neurologic examination and bedside testing a few hours thereafter. Thus, we are convinced that recovery of neglect was directly linked to the second stroke. Moreover, because of the transient head and eye deviation to the left immediately after the second stroke, a slight degree of transient right neglect might even be suspected, although there was no other behavioral evidence of that. The crucial point of a very unusual and abrupt evolution of the neglect syndrome remains.

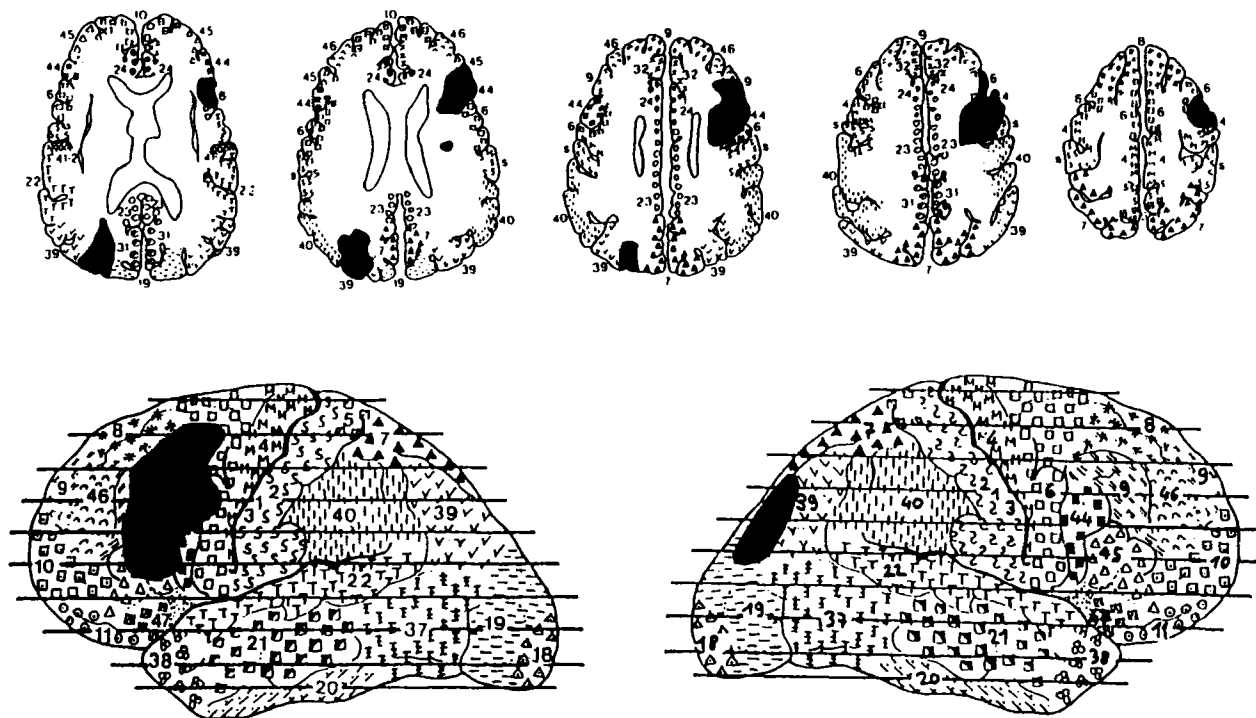


Figure 5. Plotting of the lesions seen on CT scans on Damasio and Damasio's¹⁷ corresponding anatomic templates shows that the first parietal infarct involved mainly the dorsal portion of Brodmann's area 39, just below its junction with area 7, and that the second frontal infarct involved the caudal end of the middle frontal gyrus (Brodmann's area 8) together with areas 9, 44, and 45.

Our case suggests that unilateral neglect did not occur because of the loss of the right hemisphere's potential to attend to the left hemisphere, but rather because of the imbalance between opponent systems for lateral orientation that was created by the first lesion. According to Kinsbourne's theory^{24,25} of a balance between the orienting attentional bias of each hemisphere toward the contralateral hemisphere, the suppression of our patient's neglect could be viewed as the result of the suppression of the interhemispheric imbalance created by the first stroke. However, the location of the second lesion is probably critical. After an initial parietal infarct producing contralateral visual neglect, a second opposite lesion can also induce complete, bilateral visual disorientation if it occurs in homologous parietal areas.²¹ The patient's transient head and eye deviation after his second stroke indicates involvement of the left frontal eye field (FEF),²⁶ which lies at the caudal end of the middle frontal gyrus (Brodmann's area 8) and was probably damaged together with portions of areas 6, 9, 44, and 45 in our patient (figure 5). The FEF and the surrounding cortex are one major cortical component of the anatomic-functional network subserving spatial distribution of attention,^{2,6} and unilateral lesions of the FEF cause neglect of contralateral space in humans as well as in monkeys.^{1,2,8,27} Some studies even found an unexpected predominance of left-sided lesions in frontal neglect cases.^{5,8}

In animals having severe and permanent contralateral visual neglect after ablation of large areas of the temporo-occipital neocortex, subsequent re-

moval of the superior colliculus opposite the cortical lesion and splitting of the collicular commissure both result in immediate and complete restoration of normal, visually guided behavior.²⁸ This finding is consistent with a functional inhibition of the superior colliculus ipsilateral to the cortical lesion and an interaction between cortical and midbrain levels in directing visual attention. Our patient's unilateral neglect after his first parietal stroke probably reflects a functional depression of a cortical-subcortical attentional system, the parietal cortex being responsible for preexciting (or disinhibiting) neurons in the superior colliculus for the generation of ocular saccades²⁹ as well as for disengaging attention from current focus.¹⁹ The second stroke in the FEF contralateral to the first lesion could restore the attentional orienting balance in a way similar to the removal of the superior colliculus in animals, as the FEF and superior colliculus have parallel roles in the control of ocular movement³⁰ and visually guided behavior.³¹ Alternatively, we cannot exclude the possibility that reversal of the spatial attentional bias could also be mediated by other cortical-subcortical interactions,³² such as frontal projections to the nucleus reticularis thalami, for which there is evidence of a gating function in directed attention.^{1,33} On the other hand, a direct transcallosal interhemispheric interaction seems unlikely, as unilateral neglect is either unchanged or worsened when callosotomy is superimposed to a lateralized hemispheric lesion.^{25,34}

Finally, although it is not predictable from current theories about visuospatial attention and neglect,

our case strongly supports the existence of a distributed anatomic-functional network subserving the spatial allocation of attention and shows that bilateral damage to such a network may result not only in confusional state, akinetic mutism, visuospatial disorientation, and bilateral neglect,¹⁻³ but also in recovery of unilateral attentional disorder, depending on the anatomic (and perhaps temporal) distribution of lesions.

Acknowledgment

Thanks to S. Schwartz for her comments on an early draft of the manuscript.

References

1. Heilman KM, Watson RT, Valenstein E. Neglect and related disorders. In: Heilman KM, Valenstein E, eds. *Clinical neuropsychology*. New York: Oxford University Press, 1993:279-336.
2. Mesulam MM. A cortical network for directed attention and unilateral neglect. *Ann Neurol* 1981;10:301-325.
3. Mesulam MM. Attention, confusional states and neglect. In: Mesulam MM, ed. *Principles of behavioral neurology*. Philadelphia: FA Davis, 1985:125-168.
4. Vallar G, Perani D. The anatomy of unilateral neglect after right-hemisphere stroke lesions. A clinical/CT-scan correlation study in man. *Neuropsychologia* 1986;24:609-622.
5. Ogden JA. Anterior-posterior interhemispheric differences in the loci of lesions producing visual hemineglect. *Brain Cogn* 1985;4:59-75.
6. Mesulam MM. Large-scale neurocognitive networks and distributed processing for attention, language, and memory. *Ann Neurol* 1990;28:597-613.
7. Heilman KM, Valenstein E. Frontal lobe neglect in man. *Neurology* 1972;22:660-664.
8. Damasio AR, Damasio H, Chang Chui H. Neglect following damage to frontal lobe or basal ganglia. *Neuropsychologia* 1980;18:123-132.
9. Daffner KR, Ahern GL, Weintraub S, Mesulam MM. Dissociated neglect behavior following sequential strokes in the right hemisphere. *Ann Neurol* 1990;28:97-101.
10. Van Der Linden M, Seron X, Gillet J, Bredart S. Hémignégligence par lésion frontale droite. A propos de trois observations. *Acta Neurol Belg* 1980;80:298-310.
11. Assal G. Batterie des examens neuropsychologiques du CHUV. 1985.
12. Gainotti G, D'Erme P, Monteleone D, Silveri MC. Mechanisms of unilateral spatial neglect in relation to laterality of cerebral lesions. *Brain* 1986;109:599-612.
13. Gauthier L, Dehaut F, Joanette Y. The bells test: a quantitative and qualitative test for visual neglect. *Int J Neuropsychol* 1989;11:49-54.
14. Barbieri C, De Renzi E. Patterns of neglect dissociation. *Behav Neurol* 1989;2:13-24.
15. Walker R, Findlay JM, Young AW, Welch J. Disentangling neglect and hemianopia. *Neuropsychologia* 1991;29:1019-1027.
16. Kooistra CA, Heilman KM. Hemispatial visual inattention masquerading as hemianopia. *Neurology* 1989;39:1125-1227.
17. Damasio H, Damasio AR. *Lesion analysis in neuropsychology*. New York: Oxford University Press, 1989.
18. Lynch JC. The functional organization of posterior parietal association cortex. *Behav Brain Sci* 1980;3:485-534.
19. Posner MI, Walker JA, Friedrich FJ, Rafal RD. Effects of parietal injury on covert orienting of attention. *J Neurosci* 1984;7:1863-1874.
20. Eidelberg D, Galaburda AM. Inferior parietal lobule: divergent architectonic asymmetries in the human brain. *Arch Neurol* 1984;41:843-852.
21. Pierrot-Deseilligny C, Gray F, Brunet P. Infarcts of both inferior parietal lobules with impairment of visually guided eye movements, peripheral visual inattention and optic ataxia. *Brain* 1986;109:81-97.
22. Hier DB, Mondlock J, Caplan LR. Recovery of behavioral abnormalities after right hemisphere stroke. *Neurology* 1983;33:345-350.
23. Wade DT, Wood VA, Hewer RL. Recovery of cognitive function soon after stroke: a study of visual neglect, attention span and verbal recall. *J Neurol Neurosurg Psychiatry* 1988;51:10-13.
24. Kinsbourne M. A model for the mechanism of unilateral neglect of space. *Trans Am Neurol Assoc* 1970;95:143-146.
25. Kinsbourne M. Mechanisms of unilateral neglect. In: Jeannerod M, ed. *Neurophysiological and neuropsychological aspects of spatial neglect*. North Holland: Elsevier Science, 1987:69-86.
26. Tijssen CC. Conjugate deviation of the eyes in cerebral lesions. In: Daroff RB, Neetens A, eds. *Neurological organisation of ocular movements*. Amsterdam: Kugler-Ghedini, 1990:245-258.
27. Rizzolatti G, Matelli M, Pavesi G. Deficits in attention and movement following the removal of postarcuate (area 6) and prearcuate (area 8) cortex in macaque monkeys. *Brain* 1983;106:655-673.
28. Sprague JM. Interaction of cortex and superior colliculus in mediation of visually guided behavior in the cat. *Science* 1966;153:1544-1547.
29. Pierrot-Deseilligny C, Rivaud S, Gaymard B, Agid Y. Cortical control of reflexive visually guided saccades. *Brain* 1991;114:1473-1485.
30. Schiller PH, True SD, Conway JL. Effects of frontal eye field and superior colliculus ablations on eye movements. *Science* 1979;206:590-592.
31. Collin NG, Cowey A, Lattin R, Marzi C. The role of frontal eye field and superior colliculi in visual search and non-visual search in rhesus monkeys. *Behav Brain Res* 1982;4:177-193.
32. Deuel RK. Neural dysfunction during hemineglect after cortical damage in two monkeys model. In: Jeannerod M, ed. *Neurophysiological and neuropsychological aspects of spatial neglect*. North Holland: Elsevier Science, 1987:315-334.
33. Watson RT, Valenstein E, Heilman KM. Thalamic neglect: possible role of the medial thalamus and nucleus reticularis in behavior. *Arch Neurol* 1981;38:501-506.
34. Watson RT, Valenstein E, Day AL, Heilman KM. The effect of corpus callosum lesions on unilateral neglect in monkeys. *Neurology* 1984;34:812-815.

Neurology®

Unilateral spatial neglect recovery after sequential strokes

P. Vuilleumier, D. Hester, G. Assal, et al.

Neurology 1996;46;184-189

DOI 10.1212/WNL.46.1.184

This information is current as of January 1, 1996

Updated Information & Services	including high resolution figures, can be found at: http://www.neurology.org/content/46/1/184.full.html
References	This article cites 27 articles, 2 of which you can access for free at: http://www.neurology.org/content/46/1/184.full.html#ref-list-1
Citations	This article has been cited by 11 HighWire-hosted articles: http://www.neurology.org/content/46/1/184.full.html#otherarticles
Permissions & Licensing	Information about reproducing this article in parts (figures,tables) or in its entirety can be found online at: http://www.neurology.org/misc/about.xhtml#permissions
Reprints	Information about ordering reprints can be found online: http://www.neurology.org/misc/addir.xhtml#reprintsus

Neurology® is the official journal of the American Academy of Neurology. Published continuously since 1951, it is now a weekly with 48 issues per year. Copyright Copyright 1996 by Advanstar Communications Inc.. All rights reserved. Print ISSN: 0028-3878. Online ISSN: 1526-632X.

