

## Prosodic Characteristics of Speech Pre- and Post-Right Hemisphere Stroke

LEE XENAKIS BLONDER,<sup>\*,†,‡,¶</sup> JOHN E. PICKERING,<sup>§</sup> ROBIN L. HEATH,<sup>\*,†,‡</sup>  
CHARLES D. SMITH,<sup>¶,||</sup> AND STEVEN M. BUTLER<sup>†,\*\*</sup>

*\*Department of Behavioral Science, †Sanders-Brown Center on Aging, ‡Department of Anthropology, ¶Department of Neurology, §Magnetic Resonance Imaging and Spectroscopy Center, and \*\*Department of Statistics at the University of Kentucky, and the §Communication Disorders Program at the College of Saint Rose*

Case-control studies have shown right hemisphere specialization in the production of intonation in speech. We examined spontaneous prosody in audiotapes of interviews with a 77-year-old right-handed woman recorded 6 months before and 6 weeks after she suffered a stroke affecting the right frontotemporo-parietal regions and the right basal ganglia. Post-stroke, the patient had a normal Mini-Mental Status Examination Score of 29, hemispatial neglect, and impairments in the comprehension of facial expression and prosody. Self-rated mood was within normal limits. We compared beginning, peak, and ending fundamental frequencies (*f*<sub>0</sub>) in breath groups, the timing of these *f*<sub>0</sub> changes, rate of speech, pause duration, and breath-group duration. We found that post-stroke, the patient had a more restricted *f*<sub>0</sub> contour, no changes in the timing of peak *f*<sub>0</sub>, an increased rate of speech, less variability in pause duration, and no changes in breath-group duration. © 1995 Academic Press, Inc.

### INTRODUCTION

Prosodic abnormalities have been observed in patients with damage to varying regions of the brain, including the cerebral cortex, the basal gan-

This research was supported in part by an NIH/NINDS FIRST Award NS29082 to L. X. Blonder and an NIH/NINDS Clinical Investigator Development Award NS01421 to C. D. Smith. We thank the following individuals for their contributions to the project: Thomas Arcury, Director of the Oral History of Kentucky Farm Families Research Program; Jeffrey Suchanek of the UK Oral History Program; Sara Quandt and Gun Roos of the UK Oral History Program and the Department of Anthropology; Sandra Kryst, Department of Anthropology; Joseph Fox, Chief of Audiology and Speech Pathology at the Veterans Administration Medical Center; John Haley, Biostatistics Consultant Service; and the staff of Cardinal Hill Hospital. Address correspondence and reprint requests to Lee Xenakis Blonder, Ph.D., Center on Aging, 101 Sanders-Brown Building, University of Kentucky, Lexington, KY 40536-0230. FAX: (606) 257-8990. E-mail: STR003 @ UKCC.UKY.EDU.

318

0093-934X/95 \$12.00

Copyright © 1995 by Academic Press, Inc.

All rights of reproduction in any form reserved.

glia, and the cerebellum (Monrad-Krohn, 1963; Darley, Aronson, & Brown, 1969; Kent & Rosenbek, 1982; Tucker, Watson, & Heilman, 1977; Odell, McNeill, Rosenbek, & Hunter, 1991; Ryalls & Behrens, 1988; Cancelliere & Kertesz, 1990). These abnormalities are diverse and include defects in syllabic stress, rate of speech, juncture, and intonation. In spite of conflicts in the literature concerning the neural representation of prosodic features, a large body of evidence supports a right hemisphere specialization in the production of intonation, particularly emotional intonation (Tucker et al., 1977; Ross & Mesulam, 1979; Ross, 1981; Weintraub, Mesulam, & Kramer, 1981; Hughes, Chan, & Su, 1983; Borod, Koff, Lorch, & Nicholas, 1985).

Tucker et al. (1977) found that patients with right parietal dysfunction and neglect had difficulty both discriminating and producing emotional prosody. Ross (1981) described several cases of patients with various types of aprosodias resulting from right hemisphere lesions, including "motor aprosody" characterized by monotone speech. Borod et al. (1985) showed that right hemisphere damaged (RHD) patients suffered impairments in emotional facial expression, prosody, and emotional speech. Speedie, Coslett, and Heilman (1984) noted that two patients with transcortical motor aphasia resulting from left hemisphere damage lacked emotional intonation during a prosodic repetition task. They suggested that these cases of aprosodia were caused by the disconnection of right hemisphere regions that mediate emotional prosody and the left perisylvian area. Weintraub et al. (1981) sought to determine whether prosodic disorders accompanying RHD were limited to emotional processing, and found that RHD patients were impaired in nonaffective prosodic comprehension, repetition, and spontaneous production.

The studies of aprosody described above rely on clinical observation or ratings made by judges. As such, they provide indirect evidence that the disorder is communicatively significant. A small number of investigators have undertaken acoustic quantification of speech in RHD patients. These results delineate more precisely the mechanical, physical, and linguistic nature of prosodic production following RHD.

Kent and Rosenbek (1982) did spectrographic analysis of prosody in patients with ataxic dysarthria, apraxia of speech, Parkinson dysarthria, and right hemisphere dysarthria. They found that the speech of RHD patients strongly resembled that of Parkinson patients in that both had a normal or increased rate of speech, decreased fundamental frequency ( $f_0$ ) variation, and decreased intensity in the resonance frequencies above 500 hz, due to nasalization. Cooper et al. (1984) measured  $f_0$  and duration in sentences read by RHD patients, left hemisphere damaged (LHD) aphasics, and normal controls. They noted that Broca's aphasics produced flatter intonation contours, longer utterances, and longer sentence final words than Wernicke's aphasics, RHD patients, and normal

controls. However, their data also show that RHD patients' intonation contours were flatter and the duration of their utterances and sentence final words slightly shorter than that of Wernicke's aphasics and normal controls. No statistical analyses were performed. Ryalls, Joannette, and Feldman (1987) compared average *fo* range, contour slope, and sentence duration in repeated sentences and found no significant differences between RHD and normal subjects. They did find a trend, however, for RHD patients tested prior to 100 days post-onset, to have narrower *fo* ranges than those tested at 100 days or more post-onset. These results suggest that the disorder may be a transient phenomenon. Alternatively, the non-emotional nature of the stimuli or the use of a repetition task may have influenced the performance of the RHD patients. Ross et al. (1988) found significant differences in *fo* slope, *fo* register, *fo* variation, and delta *fo* (a measure of deviation of intonation from a flat contour) on an emotional prosodic repetition task administered pre- and post-Wada testing. Behrens (1989) demonstrated that RHD patients' intonation contour was characterized by more restricted *fo* dispersion in declarative sentences and yes-no questions, and flatter *fo* decline in declarative sentences. Shapiro and Danly (1985) asked LHD patients and RHD patients with anterior, central, or posterior lesions, and a group of normal controls to read sentences using linguistic (interrogative, declarative) or emotional (happy, sad) prosody. They found that RHD patients with anterior and central lesions demonstrated more restricted *fo* range in both linguistic and emotional prosody, while patients with posterior RHD had exaggerated *fo* range during linguistic and emotional speech. The prosody of LHD patients was similar to that of normal controls.

In contrast to these studies of intonation following right hemisphere damage, acoustic investigations of lexical stress in RHD patients have found preserved production. Emmorey (1987) analyzed stress contrasts in compound nouns and noun phrases and concluded that RHD patients performed comparably to normal controls. Behrens (1988) also found that the production of lexical stress was preserved in RHD patients.

While the results of these studies are somewhat inconsistent, they suggest that the right hemisphere may mediate the modulation of *fo* over the length of an utterance (see Behrens, 1989). Although many studies find that the right hemisphere is particularly specialized in the production of emotional intonation, this may be a function of the research design in which comparisons with nonemotional prosodic production are not made.

With the exception of the study by Ross et al. (1988) which employed a within-subjects design pre- and post-Wada testing, the investigations described above are based on analyses of read, repeated, or experimentally elicited sentences produced by individuals after they have suffered right hemisphere damage. In this case study, we had the unique opportunity to examine prosody in spontaneous discourse produced by a woman

6 months before and 6 weeks after she suffered a right hemisphere infarct. Because psycholinguists have found significant correlations in interviewee utterance duration, pause duration, and reaction time latency for intervals up to 15 months (Matarazzo & Wiens, 1972), we felt justified in our assumption that prosodic characteristics should remain stable over the 7.5-month interval. We performed acoustic analysis of discourse using high quality audiotapes of pre and post-stroke interviews. We compared intonation (changes in *fo* over time), rate of speech, pause duration, and breath group duration in pre- and post-stroke speech samples. In addition, we compared aspects of verbal communication in the pre- and post-stroke interviews and obtained neurobehavioral and neuroimaging data following the stroke. Based on previous research, we predicted that our patient would manifest flatter intonation patterns and an increase in the rate of spontaneous speech following her right hemisphere infarct. We also predicted that indices of left hemisphere verbal competence, such as vocabulary diversity, syllables per word, and percentage of words that were prepositions, would remain stable.

### CASE REPORT AND METHODS

P.C. is a right-handed 77-year-old woman who suffered an embolus to her right frontotemporo-parietal region on January 16, 1992. She had a 10th-grade level of education and was a homemaker and a retired Soil Conservation District Supervisor. At the time of her stroke she was widowed and living in a rural area in an apartment complex for senior citizens. Her medical history was significant for rheumatic heart disease, hypertension, mild chronic renal insufficiency, and chronic atrial fibrillation. Her aortic and mitral valves were replaced in 1979. Neurologic examination at the time of her stroke showed that, with the exception of a moderate left central VII paresis, cranial nerves II through XII were intact. She had left-sided hyperreflexia without clonus and an upgoing toe on the left. Proprioception and stereognosis were impaired on the left side, particularly the left upper extremity, and there was left hemispatial neglect. A computerized tomographic (CT) scan performed on the day of the stroke revealed mild cortical atrophy consistent with age. A repeat CT scan performed four days later showed a large acute nonhemorrhagic infarct involving the right posterior frontal, anterior and middle temporal, and anterior parietal lobes, and the head of the caudate nucleus and the globus pallidus on the right. Medications at the time of our assessments were nifedipine 30 mg. PO b.i.d. (Procardia XL), Lanoxin .125 mg. PO q.d., and Coumadin 2.5 mg. PO q.d. Pre-stroke medications included all of the above with the exception that she had been taking dipyridamole (Persantin) rather than Coumadin for prophylactic anti-coagulation.

P.C. was participating in a study of emotional communication following unilateral stroke when we discovered that she had taken part in the University of Kentucky Family Farm Oral History Program six months before her stroke. In this project, residents of diverse counties are interviewed individually regarding their farming practices and dietary behaviors. Each of these interviews is recorded on a Sony TCM 5000 stereo cassette recorder using a Lavallier microphone in quiet conditions. The interview with P.C. was conducted in her home on July 12, 1991. The duration of this interview was 131 min. This interview had been transcribed, and both the original audiotapes and the transcription were made available to us. This release of data was permitted according to the Oral History project consent form approved by the University of Kentucky Institutional Review Board and

signed by the participant. We studied the contents of the transcript, paying particular attention to the types of questions asked, and performed a similar interview with P.C. post-stroke. The patient was simply told that we wanted to gain information on her background and past life, and was not informed as to our interest in the earlier interview or speech prosody. She was interviewed on February 29, 1992 (44 days post-stroke and 7.5 months after the initial interview) in a quiet room in the rehabilitation hospital where she was an inpatient, by RLH who recorded the interview on the same equipment that had been used to make the pre-stroke audiotape. The patient was a natural historian and did not remark on our interest in her past life or the similarity between our questions and those of the interviewer in the Oral History Project. The duration of the post-stroke interview was 126 min.

To analyze P.C.'s intonation before and after the right hemisphere stroke, the two transcribed oral history interviews were separated into breath groups. A breath group is a unit of speech prosody separated by inhalation (Lieberman and Blumstein, 1988). Acoustic analysis of selected breath groups was done using Kay Elemetrics Visi-Pitch (Model 6095/6097) interfaced with an IBM-compatible microcomputer. Each breath group was individually played into the Visi-Pitch using a Marantz Model PMD 430 stereo cassette recorder.

In preliminary comparisons, we found that the resolution and reliability of the Visi-Pitch were highest when using a 2-sec window and 0–600 Hz range. Thus, we limited the sample of breath groups analyzed to those not exceeding two seconds in length. The actual means and standard deviations for these restricted breath groups are 1.74 (.23) sec pre-stroke and 1.78 (.20) sec post-stroke. This comparison was not statistically significant [ $T(59) = -1.03$ ,  $p = .31$ ], ensuring that potential pre- and post-stroke differences in  $f_0$  range would not be secondary to differences in utterance length and concomitant reallocation of pulmonary air pressure (Ryalls 1982). Additionally, the pre- and post-stroke means in the duration of breath-groups in the restricted samples did not differ significantly from the pre and post-stroke means in two unrestricted samples of 40 breath groups each [pre-stroke mean; ( $SD$ ): 2.003 (.99); post-stroke mean 1.998 (.96)], suggesting that potential pre- and post-stroke differences in  $f_0$  measures would not be a function of differences in breath group duration between the restricted and unrestricted samples.

We sampled 60 breath groups of 2 sec or less in duration from each interview. The breath groups sampled were distributed across the interviews. They were played into the Visi-Pitch and analyzed acoustically. The Visi-Pitch provided a visual image corresponding to the intonation pattern produced for each breath group. Five acoustic measures were obtained for each breath group based on the visual image: (1) the  $f_0$  at the beginning of the breath group ( $f_0B$ ); (2) the highest  $f_0$  obtained in the breath group, or peak frequency ( $f_0P$ ); (3) the  $f_0$  at the end of the breath group ( $f_0E$ ); (4) the time between the beginning of the breath group and the peak fundamental frequency; and (5) the time between the peak fundamental frequency and the ending  $f_0$  of the breath group. The fundamental frequency is the lowest frequency component of a complex sound wave and represents the number of cycles per second of vocal fold vibration (Crystal, 1992). It has been measured repeatedly in research on intonation (see Ross et al., 1988, for further description). We chose to measure the beginning, peak and ending frequencies because these points represent the rise-fall intonation pattern characteristic of unmarked breath groups (Lieberman and Blumstein, 1988). The peak frequency consistently corresponded to the listener's perception of the stressed syllable within the breath group. Further, the  $f_0$  measures were obtained from voiced segments, principally vowels. The three  $f_0$  measures and the two duration measures provided the information needed to analyze the speaker's intonation patterns.

In addition to these measures, we compared rate of speech (syllables per minute) in 50 one minute samples of speech per interview, duration of pauses (in seconds) in a distributed sample of fifty pauses per interview, and duration of breath groups in a sample of 40 per interview (see above). Syllables per minute were counted using a digital stop watch. Pause

duration and duration of breath group were calculated using wide-band spectrograms generated by the Computerized Speech Laboratory (Kay Elemetrics).

In addition to the acoustic analyses, we performed select neurobehavioral tests post-stroke and examined aspects of verbal competence in the interviews. These latter measures included syllables per word, percentage of words that were prepositions, and vocabulary diversity, using a modification of the type-token ratio (Templin, 1957). The type-token ratio is the number of unique words divided by the total number of words used in a speech sample. We used the first 800 words of each interview as the denominator and the number of unique words in that sample as the numerator.

## RESULTS

### *Neurobehavioral Assessment*

Neurobehavioral testing, begun approximately 3 weeks post-stroke, revealed that P.C. performed eight out of eight tasks with her right hand, had no history of childhood left-handedness, and had no left-handed parents, siblings, or children. She obtained a score of 29 out of 30 on the Mini-Mental Status Examination (Folstein, Folstein, & McHugh, 1975), having lost one point as a result of constructional apraxia. She scored in the normal range on the Zung Depression Scale (Raw score: 27, SDS Index: 34; Zung, 1965), but was impaired in the perception of facial and prosodic emotion, and in cross-modal matching of facial and prosodic emotion on the Florida Affect Battery (Bowers et al., 1991; see Table 1). We also administered the Positive and Negative Affective Schedule (PANAS; Watson et al., 1988), which consists of 10 words that refer to positive emotions and 10 words that describe negative emotions. The subject responds by indicating the extent to which s/he feels each emo-

TABLE 1  
Post-Stroke Neurobehavioral Profile

Test	Score	Performance
Mini Mental Status Exam	29	Normal
Zung Depression Scale	34 (SDS Index)	Normal
PANAS	33 (Pos) 11 (Neg)	Normal
Florida Affect Battery:		
Facial ID Discrimination	50%	Impaired*
Facial Emot Discrimination	80%	Normal
Name Emotional Face	60%	Impaired*
Point to Emotional Face	60%	Impaired*
Match Emotional Face	45%	Impaired*
Neutral Prosody Discrimination	56%	Impaired*
Emot Prosody Discrimination	65%	Impaired*
Name Emotional Prosody	55%	Impaired*
Match Emot Prosody to Face	40%	Impaired*
Match Emot Face to Prosody	25%	Impaired*

\* Impaired score greater than 2 SD below normal control mean (Blonder et al., 1991)

tion on a 5-point scale. We asked P.C. to provide a rating based on the last few days. P.C. achieved a positive emotion score of 33 and a negative emotion score of 11. Both of these scores were within approximately one standard deviation of the normative means reported by Watson et al. (1988). P.C. did not manifest neglect on the Line Bisection or Draw a Clock subtests of the Florida Neglect Battery (Heilman et al., 1983), but did have left-sided neglect on the Crossing Out subtest.

#### *Neuroanatomical Mapping*

To determine more precisely the location of the patient's infarct, an experienced neurologist trained in neuroimaging (CDS) compared templates published by Damasio and Damasio (1989) and Matsui and Hirano (1978) to CT X-ray images of the brain acquired for clinical purposes at a community hospital using a standard CT scanner (General Electric CT-9800). Fourteen 5-mm axial slices oriented 17° to the inferior orbital-external acoustic meatal baseline were acquired [interslice gap: slices 1–7 (posterior fossa), 3.75 mm; slices 7–14, (cerebrum), 6.25 mm]. Determination of lesion location was done without knowledge of the patient's clinical or neurobehavioral findings.

On images acquired the day of the stroke, there was minimal generalized cerebral atrophy consistent with age. In addition, a very small area of hypodensity (1.5 × 2 mm) in the medial head of the left caudate nucleus was seen and interpreted as an old lacunar infarct (see Fig. 1). This lacunar infarct was clinically silent, as the patient had no documented prior history of stroke. Four days post-stroke, a well-defined hypodensity in the right hemisphere was accompanied by a 2-mm shift of the intraventricular septum to the left. No region of hyperintensity suggestive of hemorrhage was observed. Brain tissue hypodensity in the distribution of the right middle cerebral artery included virtually all of the pre-frontal, pre-central, and central branch territories in the frontal lobe and the temporo-polar, anterior temporal, middle temporal, and posterior temporal branch territories in the temporal lobe. The lenticulostriate vascular territory likewise showed hypodensity. This area includes the anterior limb of the internal capsule, the head of the caudate nucleus, the putamen, and the anterior portion of the globus pallidus. The posterior limb of the internal capsule was spared. A thin ribbon in the territory of the anterior insular branches showed relatively preserved intensity on these images. Although there was a loss of sulcal detail in the right posterior parietal and angular vascular territories (including the supramarginal gyrus), image intensity was preserved in these regions. Right hemispheric vascular territories of Heubner's artery, the anterior choroidal artery, and all branches of the anterior and posterior arteries were spared. In the left hemisphere, the only abnormality was the old lacunar infarct

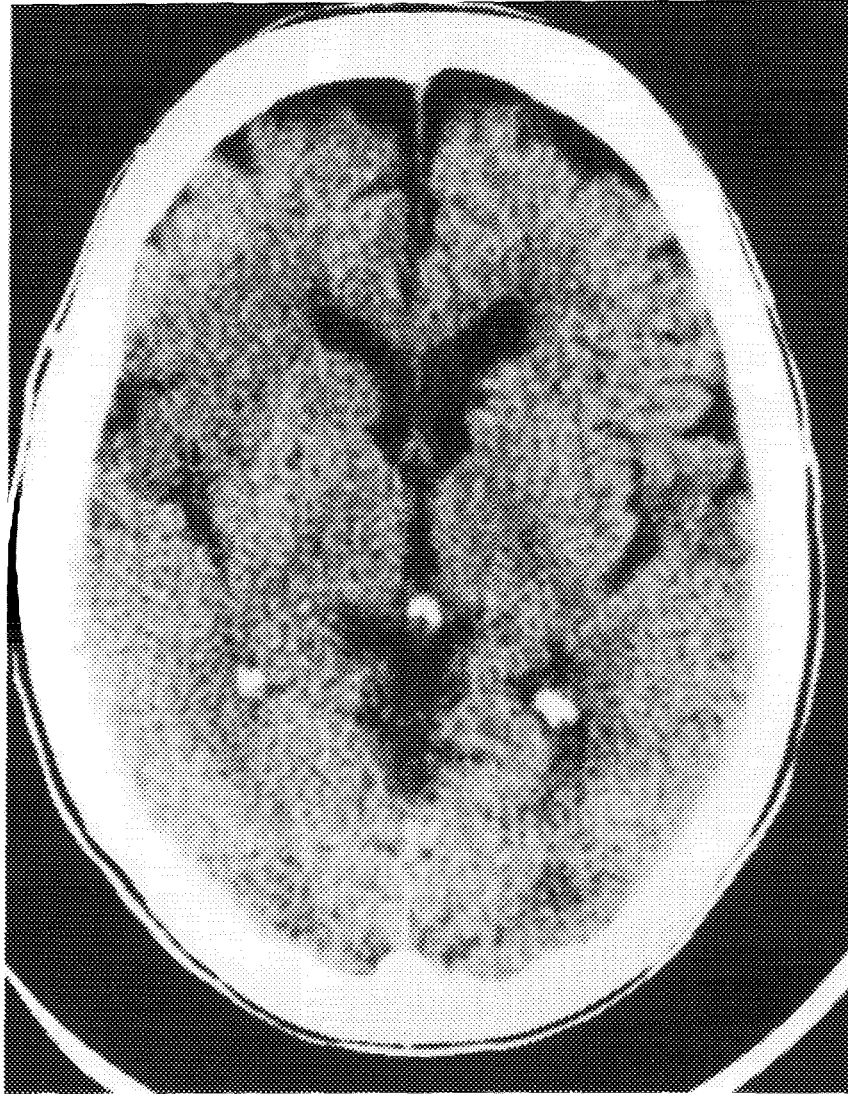


FIGURE 1

previously described. In summary, CT imaging showed an acute right fronto-temporal, anterior parietal middle cerebral artery infarct which included the right lenticulostriate vascular territory (anterior limb of the internal capsule, the head of the caudate nucleus, the putamen, and the anterior portion of the globus pallidus), but spared the angular gyrus and the superior parietal region (Figs. 2A and 2B).



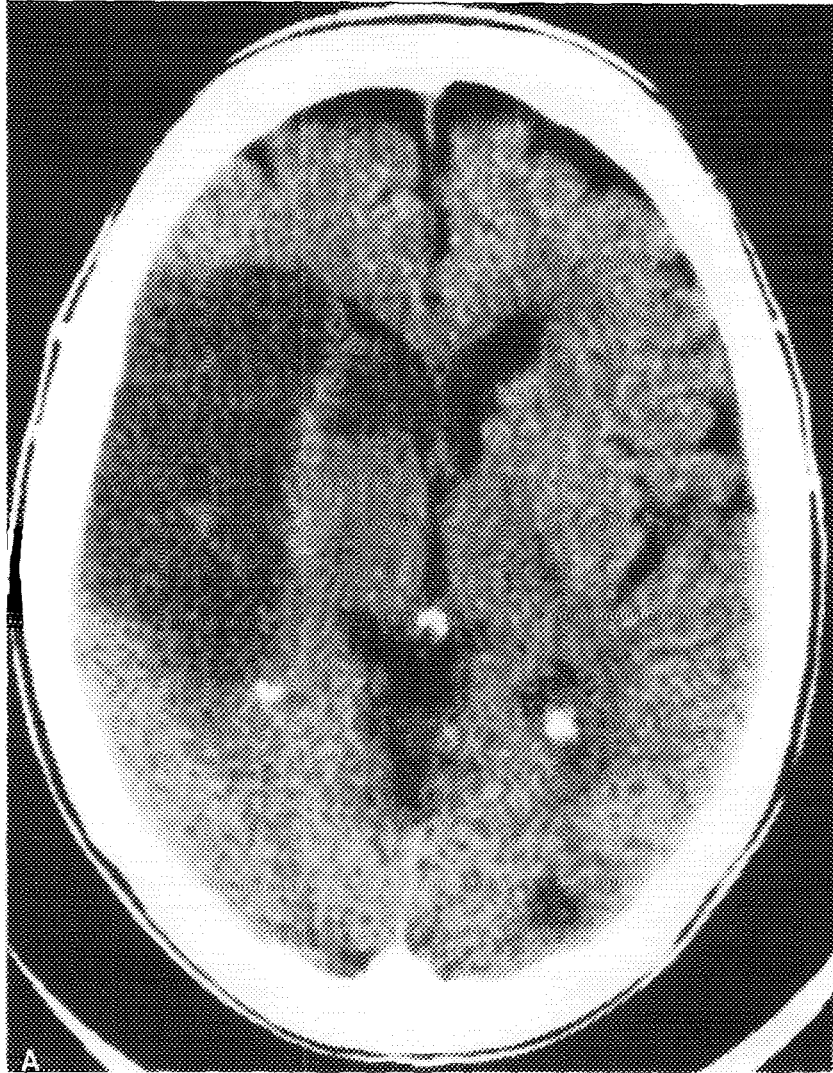


FIGURE 2

#### *Acoustic Analysis*

Because the observations under study derived from a single individual, we could not assume that the data points were independent and that the  $t$  and  $F$  would be appropriate statistical tests. We therefore performed Pearson Product-Moment correlations on adjacent pairs to assess auto-correlation (see Kazdin, 1982, for further discussion). The pre-stroke au-

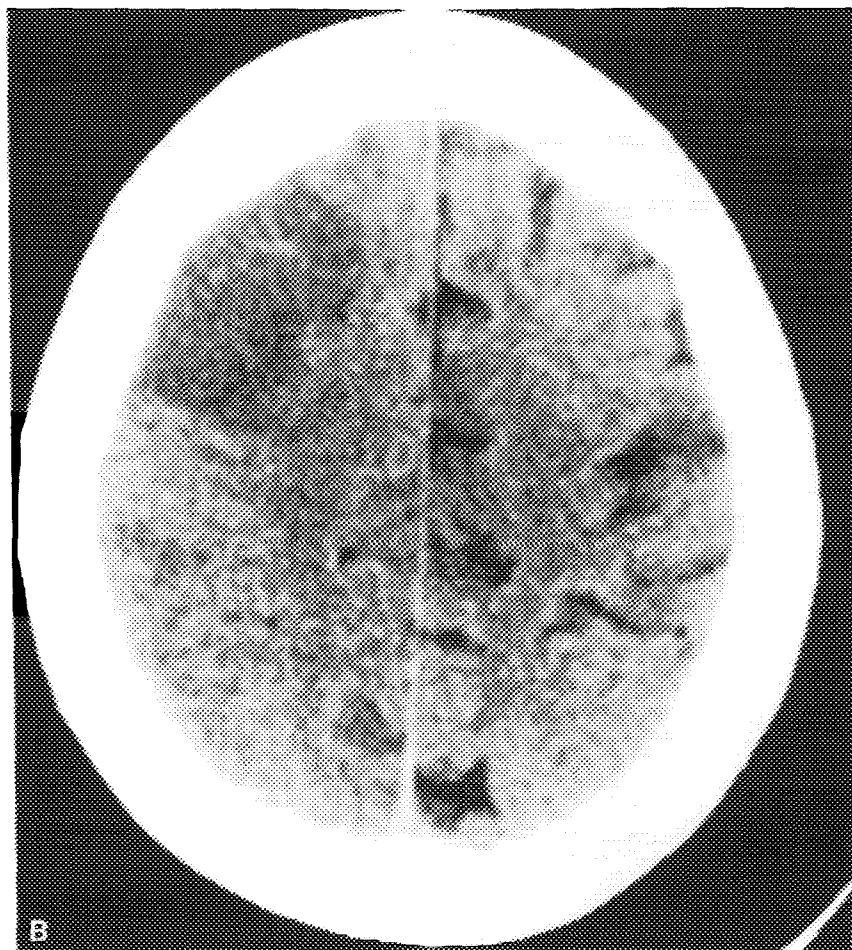


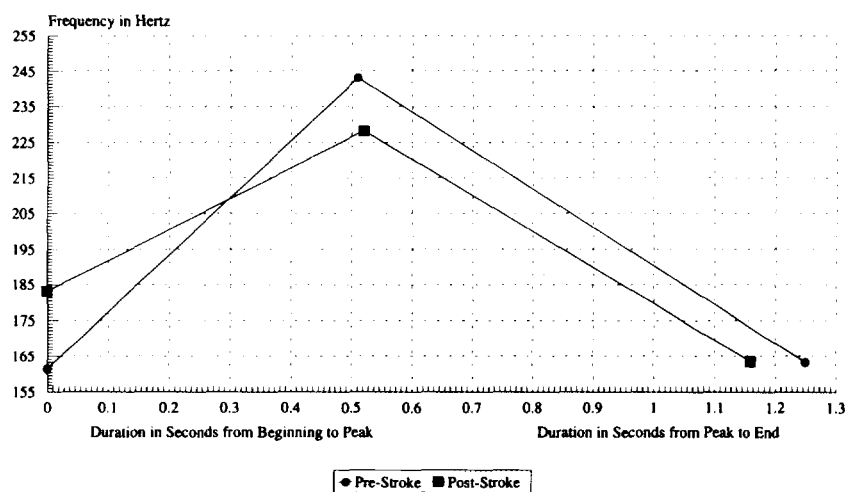
FIG. 2—Continued

tocorrelations for the variables under study were as follows: beginning *fo*:  $-.11$ ,  $p = .41$ ; peak *fo*:  $.08$ ,  $p = .53$ ; end *fo*:  $.20$ ,  $p = .12$ ; duration in seconds from beginning to peak *fo*:  $-.0070$ ,  $p = .96$ ; duration in seconds from peak to end *fo*:  $.08$ ,  $p = .54$ ; syllables per minute:  $.15$ ,  $p = .31$ ; pause duration:  $.11$ ,  $p = .44$ ; and breath group duration:  $.05$ ,  $p = .77$ . None of these variables displayed significant autocorrelation ( $\alpha \leq .05$ ) so they were analyzed using analysis of variance (ANOVA) or the *t* test.

We performed a  $2 \times 3$  repeated-measures ANOVA with no grouping factor and two within-group factors [stroke status (pre, post) and fundamental frequency (*foB*, *foP*, and *foE*)]. We found no main effect of stroke

status, meaning that the overall  $f_0$  level before and after stroke was comparable [Mean ( $SD$ ): 189.3 (36.5) hz pre and 191.6 (28.3) hz post]. There was a main effect of  $f_0$  [ $F(2, 118) = 213.7, p < .0001$ ]. Post-hoc comparisons using Fishers test revealed that overall, both the beginning frequency and the end frequency were significantly lower than the peak ( $p < .001$ ). This was expected given that declarative sentences are characterized by a rise and then a fall in  $f_0$ . We also found a frequency by status interaction [ $F(2, 118) = 9.24, p = .0002$ ] such that the beginning  $f_0$  pre-stroke was significantly lower than the beginning  $f_0$  post-stroke ( $p < .01$ ), and the peak  $f_0$  pre-stroke was significantly higher ( $p < .05$ ) than the peak frequency post-stroke. There were no statistically significant differences between ending  $f_0$  values. We also calculated  $f_0$  range for beginning, peak, and ending values pre- and post-stroke by subtracting the lowest recorded  $f_0$  value from the peak  $f_0$  value for each breath group. We found statistically significant differences [ $T(59) = 3.32, p = .002$ ] such that the  $f_0$  range pre-stroke was greater [99.1 hertz ( $SD$ : 46.4)] than the  $f_0$  range for these measurements post-stroke [73.9 hertz ( $SD$ : 30.2)]. Taken together, these results signify that the change in  $f_0$  over time was more restricted post-stroke, resulting in a flatter intonation contour (see Fig. 3).

We performed a  $2 \times 2$  repeated-measures ANOVA using stroke status (pre, post) and relative duration (time from beginning  $f_0$  to peak  $f_0$ ; time from peak  $f_0$  to end  $f_0$ ) as the within-group factors. There was no main effect of stroke status, meaning that the occurrence of a right hemisphere

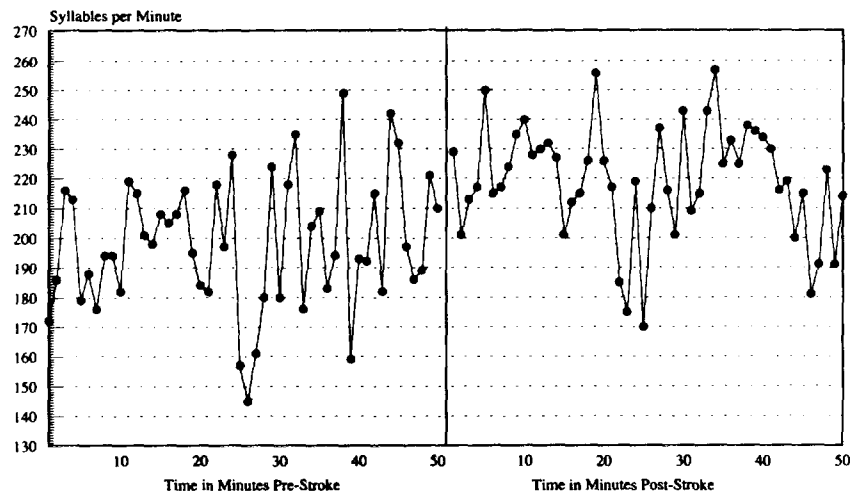


Main effect of Frequency:  $F(2,118) = 213.7, p < .0001$ ; Frequency x Stroke Status Interaction:  $F(2,118) = 9.24, p < 0.0002$ ;  
Main Effect of Duration:  $F(1,59) = 7.40, p < .01$ .

FIG. 3. Fundamental frequency in breath groups. Pre- and post-right hemisphere stroke.

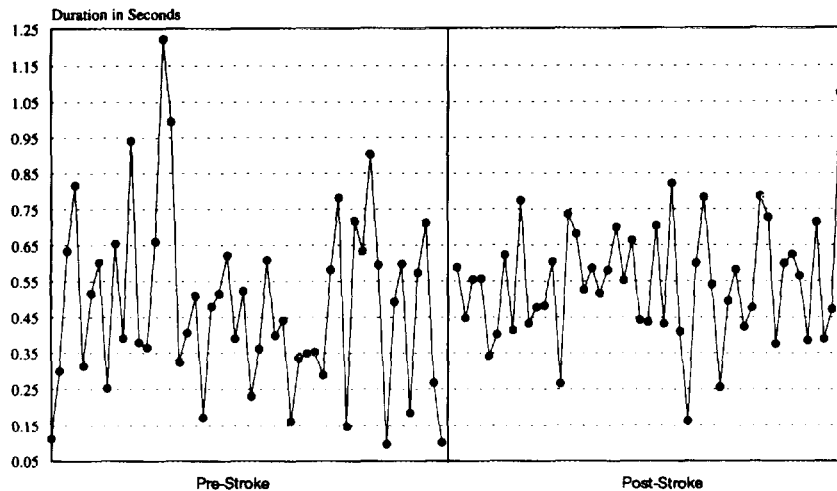
infarct did not affect the average time change (beginning to peak and peak to end *fo*). There was a main effect of relative duration [ $F(1, 59) = 7.40, p < .01$ ] such that the overall time from beginning to peak *fo* was significantly less than the time from peak to end *fo*. Again, this pattern is expected for declarative sentences. Finally, there was no relative duration by status interaction, suggesting that the timing of the peak frequency in relation to the beginning and end frequencies did not differ as a function of stroke (Fig. 3).

In order to examine the effects of this patient's right hemisphere stroke on rate of speech, we compared syllables per minute in 50 1-min samples of pre- and post-stroke discourse. These values were then subjected to a matched pairs *t* test. We found that P.C.'s rate of speech was significantly faster after her stroke than before [ $T(49) = 4.78, p < .0001$ ]. In particular, she spoke an average of 219.2 syllables per minute post-stroke ( $SD: 19.2$ ) compared with 198.1 (22.2) syllables per minute pre-stroke (see Fig. 4). Variances were homogeneous. We also compared the duration in milliseconds of 50 pauses before and 50 pauses after stroke and did not find significant differences [ $T(49) = 1.68, p = .10$ ; Pre-stroke mean: .48 (.25); Post-stroke: .55 (.17)]. These variances were not homogeneous [Levene (1, 98) = 7.08,  $p = .009$ ], indicating that variance in pause duration pre-stroke was greater than variance in pause duration post-stroke (see Fig. 5). Finally, we compared the duration in seconds of a non-restricted sample of 40 breath groups produced before the stroke and 40 produced



$T(49) = 4.78, p < .0001$

FIG. 4. Syllables per minute. Pre- and post-right hemisphere stroke.



$T(49) = 1.68, p < .10$ ; Levene's Test for Equality of Variance (1,98)=7.08,  $p = .009$

FIG. 5. Duration of pauses. Pre- and post-right hemisphere stroke.

after the stroke and found no significant difference, either in the mean or the variance [ $T(39) = -.02, p = .99$ ; Levene (1, 78): .23,  $p = .64$ ].

#### *Verbal Competency*

In our analysis of vocabulary diversity as indexed by the type-token ratio, we found that P.C. produced 270 unique words in a sample of 800 words taken from the beginning of the pre-stroke interview and 272 unique words in a sample of 800 words taken from the beginning of the post-stroke interview. These produced a type-token ratio of .34 both pre- and post-stroke, which is comparable to the mean TTR in 800 word samples of interview discourse produced by five healthy spouses of Alzheimer's patients in a prior study [spouse mean: .34 ( $SD$  .03); Blonder, Kort, & Schmitt, 1994]. We also computed the mean number of syllables per word in each 800 word sample pre- and post-stroke and found that P.C.'s pre-stroke mean was 1.280 and the post-stroke mean 1.269. Both of these values are within one standard deviation of our normal control mean in the Alzheimer's study [1.304 (.063); Blonder, et al., unpublished data]. Lastly, we calculated the percentage of words that were prepositions in these pre- and post-stroke interview samples and found that 10.75% of the pre-stroke 800 word sample were prepositions and 13% of the post-stroke 800 word sample were prepositions. Again, both of these values are within one standard deviation of our normal control mean [11.38 (1.94); Blonder et al., unpublished data].

## DISCUSSION

We analyzed the prosodic characteristics of speech in a right-handed 77-year-old woman using audiotaped interviews conducted before and after she suffered a massive right hemisphere stroke. During the subacute period post-stroke this patient demonstrated intact mental status and mood, but impaired spatial hemiattention and receptive facial and prosodic processing. Samples of spontaneous speech recorded 6 months before and 6 weeks after her stroke revealed expected verbal competence in vocabulary diversity, syllables per word, and percent of prepositions used. However, as predicted, significant differences in prosodic production were found on acoustic analysis. In particular, this patient produced significantly higher beginning *fo* and significantly lower peak *fo* after the stroke. Frequencies at the end of the breath groups did not differ. These results suggest that the post-stroke abnormality occurred during the rise portion of the rise-fall contour. Furthermore, the overall range in beginning, peak, and ending *fo* was significantly more restricted post-stroke. Ryalls (1982, 1986) has suggested that *fo* range may be a percentage of the average *fo*. Thus higher fundamental frequencies would be associated with wider *fo* range. However, since there were no differences in our patient's mean *fo* pre- and post-stroke, the post-stroke restriction in range is not secondary to a lowering in the average frequency of the patient's voice. Ryalls (1982) also suggested that restrictions in *fo* range found in Broca's aphasics during a sentence repetition task may have been due to a loss of pulmonary air pressure resulting from elongating utterances. Since the average pre- and post-stroke breath group duration did not differ in our patient, the decrease in *fo* range is also not the result of the patient elongating her utterances. It is noteworthy that although P.C.'s intonation is more restricted post-stroke, she did continue to produce a rise-fall contour. Furthermore, the relative timing of the patient's peaks in *fo* did not differ as a function of the stroke. These results suggest that some aspect of the "rule" used to generate declarative sentence intonation was preserved.

In addition, the patient's rate of speech as measured in syllables per minute was significantly faster following the stroke. Given that the patient's rate increased post-stroke in the absence of an increase in the duration of her breath groups, we propose that the neural mechanisms that control rate of speech and duration of breath groups may differ. Furthermore, although the mean duration of P.C.'s pauses did not differ, the post-stroke variance in pause duration was more restricted. If replicated in a larger sample of RHD patients, these results may signal an abnormality in the rhythm of discourse which in turn contributes to the monotonous impression often noted in RHD patients' speech.

Template analysis of this patient's CT scan performed 4 days post-stroke revealed involvement of the right fronto-temporal and anterior parietal regions as well as the anterior limb of the internal capsule, the head of the caudate nucleus, the putamen, and the anterior portion of the globus pallidus. The angular gyrus and the superior parietal region were spared. Our patient's receptive and expressive prosodic deficits are predictable based on the size and location of this lesion (see Ross, 1981). It is significant that this patient, and many of the aprosodic patients in previous studies, including Parkinsonians, had sustained damage to the basal ganglia. Recently, Cancelliere and Kertesz (1990) found that disorders of emotional prosodic expression were most often associated with basal ganglia damage, and that the frequency of such disorders did not differ as a function of hemispheric side of lesion. Lacking comparative data in patients with lesions limited to the right or left basal ganglia and the right or left cerebral cortex, the differential contribution of unilateral cortical versus subcortical structures to prosody remains uncertain. In a previous study, Blonder, Gur, and Gur (1989) found expressive prosodic deficits in patients with both right and left hemiparkinsonism, suggesting that the neural control of intonation may be bilateral at the level of the basal ganglia. This is consistent with an evolutionary model in that non-human primate calls, which resemble intonation in acoustic structure, are mediated by bilateral, subcortical brain regions (Jurgens 1979).

Several studies suggest that aprosody following RHD is emotional in nature (Tucker et al., 1977; Ross and Mesulam, 1979; Borod et al., 1985; Ross et al., 1988). However, these investigators did not assess the ability to produce non-emotional prosody. In a study using observer ratings to examine the effects of RHD on linguistic prosody, Weintraub and colleagues (1981) found that RHD patients were impaired in the repetition of statement-question intonation and the production of emphatic stress. Likewise, Danly and Shapiro (1985) used acoustic analysis to examine patients ability to produce interrogative, declarative, happy or sad prosody in sentences that were content neutral. They found that anterior RHD patients spoke with less *fo* variability while posterior RHD patients produced increased *fo* variability across both emotional and linguistic utterances.

Our prosodic data derive from interviews concerning the patient's early-life experiences. We surmise that the recounting of this information evoked a range of feelings in the speaker, and that these feelings should have been conveyed in part through prosody. However, the material is not structured so as to permit us to separate emotional and linguistic prosody. Furthermore, spontaneous discourse is rarely devoid of speaker attitude, and speaker attitude is more or less emotionally charged (Couper-Kuhlen, 1986). Many linguists challenge the view that a dichotomy

exists between emotional and linguistic prosody (Bolinger, 1972; Ladd, 1980). For example, Bolinger (1972, p. 233) dispels the notion that grammatical and emotional intonation are distinct by pointing out that questions are an expression of a speaker's uncertainty or curiosity, "which is suspiciously close to emotion." Ladd (1980, p. 109) hypothesizes that "intonation meaning involves both all-or-none contrasts between linguistic categories and dimensions of gradience within categories." In gradient phenomena, increases or decreases in *fo* range, loudness, and tempo tend to correspond to increases or decreases in the speaker's feelings about the subject matter under discussion (see Bolinger, 1986).

In a spectrographic study of lexical stress in compound words and noun phrases, Emmorey (1987) found that RHD patients' utterances were intact. Likewise, Behrens (1988) studied contrastive stress production using acoustic quantifiers and found that RHD patients were able to produce stress contrasts. These studies suggest that all-or-none contrastive intonation is spared in RHD. Our study and those by Kent and Rosenbek (1982) and Behrens (1989) suggest that gradient aspects of intonation are disrupted in RHD. Since gradient properties of intonation are often used to express emotion, the restriction variability in *fo* and pause duration that we report, may reflect a stroke-induced restriction in the patient's capacity to *experience* emotion. However, this is unlikely in P.C.'s case since she did not exhibit post-stroke depression according to her score on the Zung Depression Scale, nor did she display a reduction in her capacity to experience positive and negative emotions as indexed by her PANAS scores.

The characteristics of prosody that we have identified as impaired in this patient following her right hemisphere infarct, are precisely those used by speakers to create drama in speech. Thus, the prosodic disorder that we have observed may signify a loss of knowledge regarding the appropriate use of these cues to convey emotional or attitudinal meaning. Alternatively, this impairment could simply reflect a mechanical inefficiency on the part of the speaker to regulate *fo*, rate, and pause, which in turn results in a failure to arouse emotions in the *listener*. This would explain the repeated attempts by researchers and clinicians to characterize monotone speech in RHD patients as an aspect of *affective* flattening.

The findings derived from this case study point to several avenues of future research. These include case-control studies of speech rate and pause duration in spontaneous discourse by RHD versus LHD patients, listener arousal in response to RHD patients' spontaneous prosody; the relationship among RHD patients' emotional state, prosody, and laryngeal function; and comparisons of these functions in patients with discrete lesions in varying regions of right and left cortical and subcortical structures.



## REFERENCES

- Behrens, S. J. 1988. The role of the right hemisphere in the production of linguistic stress. *Brain and Language*, **33**, 104–127.
- Behrens, S. J. 1989. Characterizing sentence intonation in a right hemisphere-damaged population. *Brain and Language*, **37**, 181–200.
- Blonder, L. X., Gur, R. E., & Gur, R. C. 1989. The effects of right and left hemiparkinsonism on prosody. *Brain and Language*, **36**, 193–207.
- Blonder, L. X., Bowers, D., & Heilman, K. M. 1991. The role of the right hemisphere in emotional communication. *Brain*, **114**, 1115–1127.
- Blonder, L. X., Kort, E. D., & Schmitt, F. A. 1994. Conversational discourse in patients with Alzheimer's disease. *Journal of Linguistic Anthropology*, **4** (1), 50–71.
- Bolinger, D. 1972. *Intonation*. Harmondsworth, England: Penguin.
- Bolinger, D. 1986. *Intonation and its parts*. Stanford: Stanford Univ. Press.
- Borod, J. C., Koff, E., Lorch, M. P., & Nicholas, M. 1985. Channels of emotional expression in patients with unilateral brain damage. *Archives of Neurology* **42**, 345–348.
- Bowers, D., Blonder, L. X., & Heilman, K. M. 1991. *The Florida affect battery*. Gainesville, FL: University of Florida Press.
- Cancelliere, A. E. B., & Kertesz, A. 1990. Lesion localization in acquired deficits of emotional expression and comprehension. *Brain and Cognition*, **13**, 133–147.
- Cooper, W., Soares, C., Nicol, J., Michelow, D., & Goloskie, S. 1984. Clausal intonation after unilateral brain damage. *Language and Speech*, **27**, 17–24.
- Couper-Kuhlen, E. 1986. *An introduction to English prosody*. London: Edward Arnold.
- Crystal, D. 1992. *A dictionary of linguistics and phonetics*. Oxford, UK: Blackwell.
- Damasio, H., & Damasio, A. R. 1989. *Lesion analysis in neuropsychology*. New York: Oxford.
- Darley, F., Aronson, A., & Brown, J. 1969. Clusters of deviant speech dimensions in the dysarthrias. *Journal of Speech and Hearing Research*, **12**, 462–496.
- Emmorey, K. D. 1987. The neurological substrates for prosodic aspects of speech. *Brain and Language*, **30**, 305–320.
- Folstein, M. F., Folstein, S. E., & McHugh, P. R. 1975. Mini-mental state. *Journal of Psychiatric Research*, **12**, 189–198.
- Heilman, K., Bowers, D., Valenstein, E., & Watson, R. 1983. *Florida neglect battery*. Unpublished test, University of Florida.
- Hughes, C. P., Chan, J. L., & Su, M. S. 1983. Aprosodia in Chinese patients with right cerebral hemisphere lesions. *Archives of Neurology*, **40**, 723–736.
- Jurgens, U. 1979. Neural control of vocalization in nonhuman primates. In H.D. Steklis & M. J. Raleigh (Eds.), *Neurobiology of social communication in primates*. New York: Academic Press. Pp. 11–44.
- Kazdin, A. E. 1982. *Single-case research designs*. New York: Oxford Univ. Press.
- Kent, R. D., & Rosenbek, J. C. 1982. Prosodic disturbance and neurologic lesion. *Brain and Language*, **15**, 259–291.
- Ladd, D. R. 1980. *The structure of intonation meaning*. Bloomington, IN: Indiana Univ. Press.
- Lieberman, P., & Blumstein, S. E. 1988. *Speech physiology, speech perception, and acoustic phonetics*. Cambridge: Cambridge Univ. Press.
- Matarazzo, J. D., & Wiens, A. N. 1972. *The interview. Research on its anatomy and structure*. Chicago/New York: Aldine.
- Matsui, T., & Hirano, A. 1978. *An atlas of human brain for computerized tomography*. Tokyo: Igaku-Shoin.
- Monrad-Krohn, G. 1963. The third element of speech: prosody and its disorders. In L. Halpern (Ed.), *Problems of Dynamic Neurology*. Jerusalem: Hebrew Univ. Press. Pp. 101–117.

- Odell, K., McNeill, M. R., Rosenbek, J. C., & Hunter, L. 1991. Perceptual characteristics of vowel and prosody production in apraxic, aphasic, and dysarthric speakers. *Journal of Speech and Hearing Research*, **36**, 67–80.
- Ross, E. D. 1981. The aprosodias: Functional-anatomic organization of the affective components of language in the right hemisphere. *Annals of Neurology*, **38**, 561–589.
- Ross, E. D., & Mesulam, M. M. 1979. Dominant language functions of the right hemisphere? Prosody and emotional gesturing. *Archives of Neurology*, **36**, 144–148.
- Ross, E. D., Edmondson, J. A., Seibert, G. B., & Homan, R. W. 1988. Acoustic analysis of affective prosody during right-sided Wada test: A within-subjects verification of the right hemisphere's role in language. *Brain and Language*, **33**, 128–145.
- Ryalls, J. 1982. Intonation in Broca's aphasia. *Neuropsychologia* **20**, 355–360.
- Ryalls, J. 1986. What constitutes a primary disturbance of speech prosody? A reply to Shapiro and Danly. *Brain and Language*, **29**, 183–187.
- Ryalls, J., Joannette, Y., & Feldman, L. 1987. An acoustic comparison of normal and right hemisphere damaged speech prosody. *Cortex*, **23**, 685–694.
- Ryalls, J., & Behrens, S. J. 1988. An overview of changes in fundamental frequency associated with cortical insult. *Aphasiology*, **2**, 107–115.
- Shapiro, B. E., & Danly, M. 1985. The role of the right hemisphere in the control of speech prosody in propositional and affective contexts. *Brain and Language*, **25**, 19–36.
- Speedie, L. J., Coslett, H. B., & Heilman, K. M. 1984. Repetition of affective prosody in mixed transcortical aphasia. *Archives of Neurology*, **41**, 268–270.
- Templin, M. 1957. *Certain language skills in children. Their development and interrelationship*. Minneapolis: Univ. of Minnesota Press.
- Tucker, D., Watson, R., & Heilman, K. 1977. Discrimination and evocation of affectively intoned speech in patients with right parietal disease. *Neurology*, **27**, 947–950.
- Watson, D., Clark, L. A., & Tellegan, A. 1988. Development and validation of brief measures of positive and negative affect: The PANAS scales. *Journal of Personality and Social Psychology*, **54**, 1063–1070.
- Weintraub, S., Mesulam, M., & Kramer, L. 1981. Disturbances in prosody: a right hemisphere contribution to language. *Archives of Neurology*, **38**, 742–744.
- Zung, W. W. K. 1965. A self-rating depression scale. *Archives of General Psychiatry*, **12**, 63–70.