

Shinichiro Maeshima
Tomoaki Terada
Kunio Nakai
Hiroki Nishibayashi
Fuminori Ozaki
Toru Itakura
Norihiko Komai

Unilateral spatial neglect due to a haemorrhagic contusion in the right frontal lobe

Received: 20 December 1994
Received in revised form: 2 March 1995
Accepted: 11 March 1995

S. Maeshima (✉) · T. Terada · K. Nakai
H. Nishibayashi · F. Ozaki · T. Itakura
N. Komai
Department of Neurological Surgery,
Wakayama Medical College,
27 Nanaban-cho, Wakayama 640, Japan

Abstract We report two cases of unilateral spatial neglect associated with an isolated right frontal lobe lesion. Case 1 was a 59-year-old, right-handed man, who developed a left hemiplegia, disorientation, and frontal lobe neglect associated with a haemorrhagic contusion following a head injury. Case 2 was a 55-year-old, right-handed man, who also developed disorientation and frontal lobe neglect secondary to a haemorrhagic contusion following a head injury. ^{99m}Tc HM-PAO SPECT re-

vealed an isolated reduction in the regional cerebral blood flow (CBF) around the haematoma in the frontal lobe; blood flow to remaining parts of the brain was normal. Damage to the right frontal lobes of these patients was confirmed as being the cause of the unilateral spatial neglect in accordance with the results of CBF studies.

Key words Neglect · Cerebral contusion · Brain injury · Frontal lobe · Agnosia

Introduction

Unilateral spatial neglect occurs when a patient disregards objects existing in the contralateral hemisphere. This symptom is usually associated with lesions in parieto-occipital lobes of the non-dominant hemisphere [5], but rarely involves lesions in the frontal lobe [2–4, 6, 7, 10, 13], thalamus [8, 15], putamen [11], or left hemisphere [9]. Heilman and Valenstein [4] reported six cases of unilateral spatial neglect associated with frontal lobe lesions, naming the syndrome “frontal lobe neglect”. However, the causative lesions of the unilateral spatial neglect in their patients could not be precisely identified since their series was studied before the introduction of computed tomography (CT). Damasio et al. [3] reported five patients with frontal lobe neglect, two of whom demonstrated lesions in their basal ganglia and the other three manifesting left frontal lobe lesions. Meanwhile, Vallar and Perani [14] failed to demonstrate unilateral spatial neglect in 110 patients with right hemispheric strokes confined to the frontal lobe. Therefore, they suggested that frontal lobe neglect was a rare condition.

Unilateral spatial neglect is also thought to reflect a disturbance in the spatial distribution of directed attention [12]. Proposed mechanisms for unilateral spatial neglect include impairments of spatial processing, selective attention, mental representation, and awareness and/or premotor planning. However, the precise nature of such lesions and underlying mechanisms remains matter of debate. We describe two patients who each demonstrated unilateral spatial neglect caused by a right frontal lobe lesion.

Case reports

Case 1

A 64-year-old, right handed man, with an educational history of 12 years was admitted to our hospital on 19 July 1994, the day following a closed head injury. CT demonstrated a right, unilateral, frontal haemorrhagic contusion.

On admission, he was unconscious, responding only to painful stimuli, and demonstrated a left hemiparesis (Glasgow Coma Scale score: 11). He rapidly regained his normal level of consciousness within 24 h with conservative treatment. He had full visual fields by confrontational testing, as well as normal extraocular movements, but manifested a mild left hemiparesis. Perception of pain,

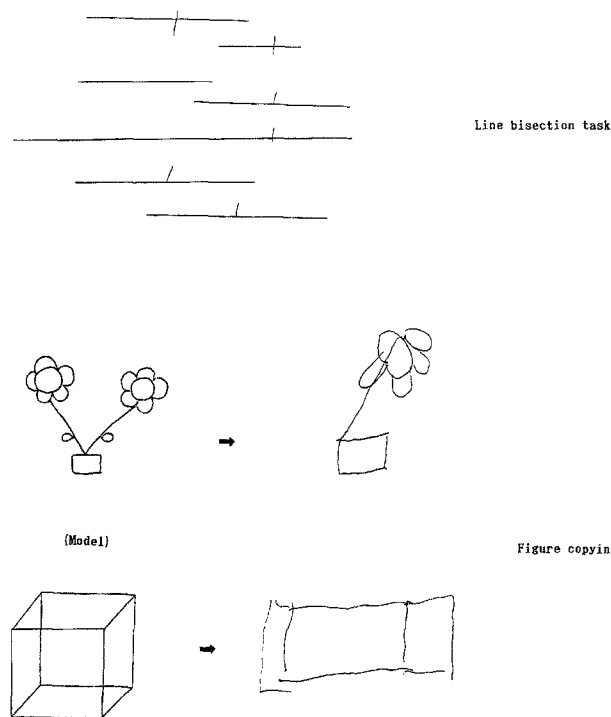


Fig. 1 Unilateral spatial neglect seen in some neuropsychological tasks

light touch, vibration, proprioception, graphaesthesia, and stereognosis was intact.

Neuropsychological examination

The patient was disoriented with respect to time and place, and his total score on the Mini-Mental State Examination was 17/30; word fluency (animal naming) was 5/min, and his digit span retention was 6 for forward recall and 3 for reverse recall. On the WAIS-R, his verbal intelligence quotient (IQ) was 85 and his performance

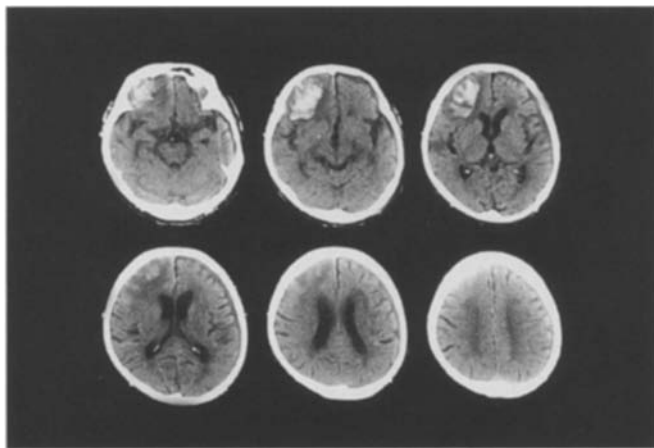


Fig. 2 A CT scan showing a right, frontal haemorrhagic contusion surrounded by oedema

IQ was below the limit of assessment with this test. Raven's coloured progressive matrices score was 11/36.

Unilateral spatial neglect of his left side was demonstrated on line bisection and figure copying tests (Fig. 1). An exploratory-motor neglect of his left side was noted by the exploratory-motor task; he was asked to move the 16 marbles on a board (43×34 cm) to the right edge and off using his right hand with eyes closed. On a perceptual-sensory task, extinction due to bilateral simultaneous stimulation was observed for all visual, auditory and tactile modalities. Aphasia, ideomotor apraxia, ideational apraxia and anosognosia were not observed, but there was severe motor impersistence.

CT revealed a right, frontal haemorrhagic contusion surrounded by oedema (Fig. 2). A ^{99m}Tc -hexamethyl-propylene-oxime (HM-PAO) single photon emission CT (SPECT) study was performed that same week, revealing a decrease in the regional cerebral blood flow around the haematoma in the frontal lobe (Fig. 3a).

Clinical course

The patient's left hemiparesis resolved within several days of its onset. Disorientation to time and place and task evidence of unilat-

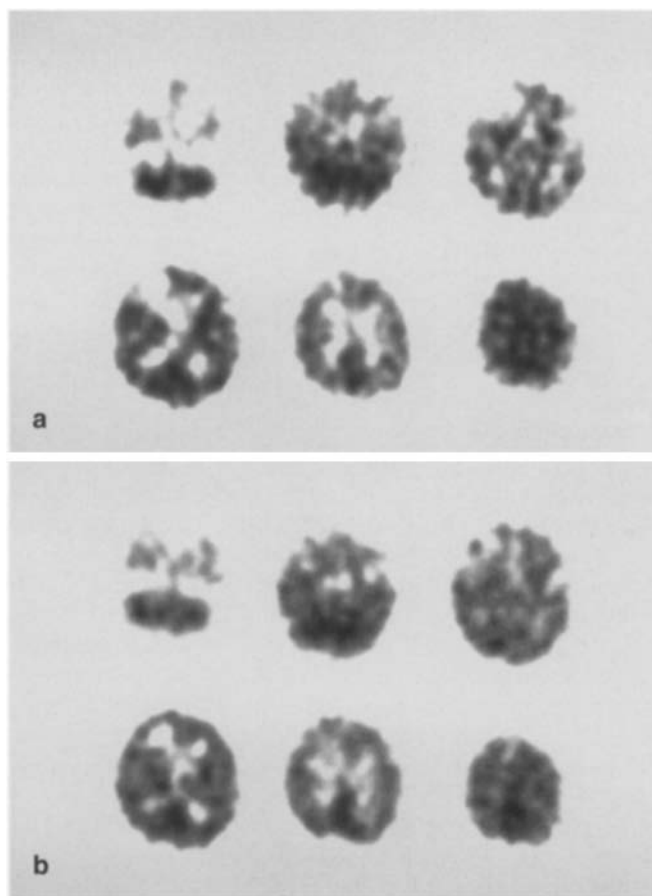


Fig. 3 **a** ^{99m}Tc -hexamethyl-propylene-oxime (HM-PAO) single photon emission CT (SPECT), performed in the first week after the injury, shows a decrease in the regional cerebral blood flow around the haematoma in the frontal lobe. **b** SPECT 3 weeks following the injury shows improvement in regional cerebral blood flow to the frontal lobe around the haematoma

eral spatial neglect also decreased in the 3 weeks following the injury, with improvement in regional cerebral blood flow to the frontal lobe around the site of the haematoma (Fig. 3 b).

Case 2

A 64-year-old, right-handed man, with an educational history of 12 years, was admitted to our hospital on 5 September 1994, suffering from a cerebral contusion sustained in a traffic accident on 2 September. CT demonstrated a right, unilateral, frontal haemorrhagic contusion.

On admission, he was somnolent (Glasgow Coma Scale score: 13) without motor paresis. He underwent a craniotomy for evacuation of the haematoma, and rapidly regained his normal level of consciousness a few days following the operation. He had full visual fields by confrontational testing, normal extraocular movements, and no paresis. Perception to pain, light touch, vibration, proprioception, graphaesthesia, and stereognosis was intact.

Neuropsychological examination

The patient was disoriented with respect to time and place, and anterograde amnesia and confabulation were observed. His score on the Mini-Mental State Examination was 14/30; word fluency was 1/min and digit span retention was 5 for forward and 2 for reverse recall. His Raven's coloured progressive matrices score was 3/36.

Unilateral spatial neglect on the left side was demonstrated on line bisection, line cancellation and figure-copying tests (Fig. 4).

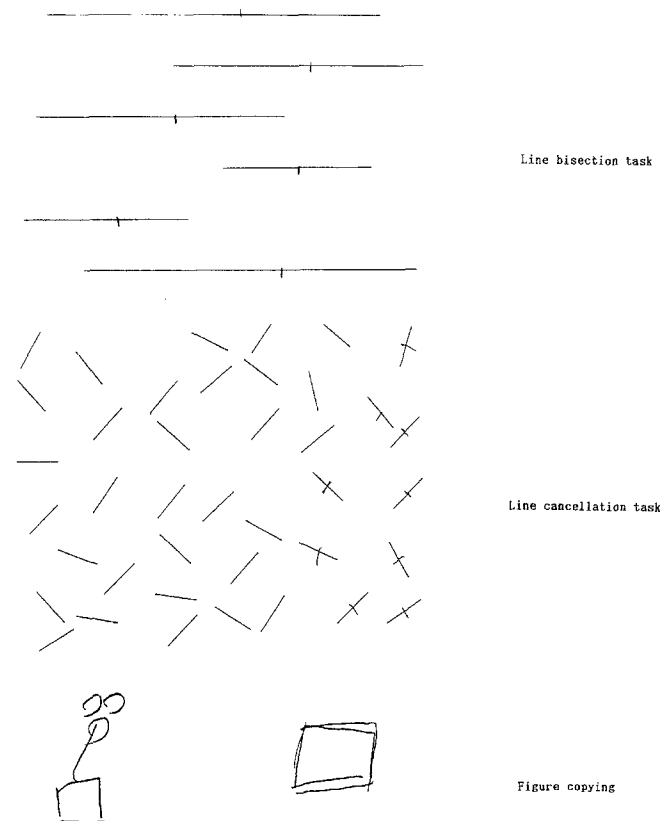


Fig. 4 Unilateral spatial neglect seen in some neuropsychological tasks

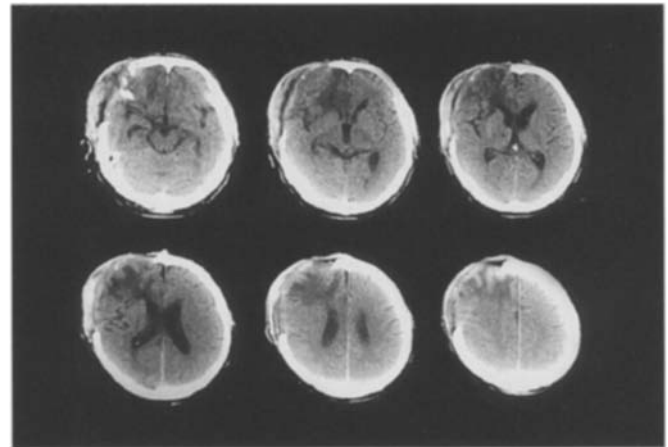


Fig. 5 A CT scan following craniotomy shows a right, frontal, haemorrhagic contusion surrounded by oedema (one month after surgery)

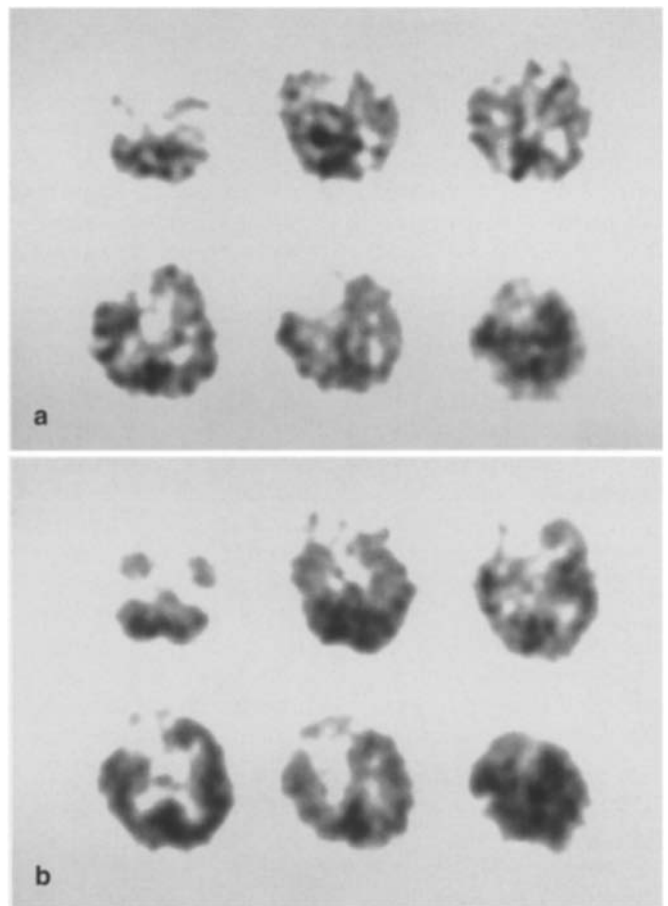


Fig. 6 **a** HM-PAO SPECT in the first week after injury shows a decrease in the regional cerebral blood flow to the frontal lobe around the haematoma. **b** SPECT 4 weeks following the injury reveals increasing regional cerebral blood flow to the frontal lobe around the haematoma

An exploratory-motor neglect of his left side was noted when the patient performed an exploratory-motor task with his eyes closed. On a perceptual-sensory task, extinction phenomenon due to bilateral simultaneous stimulation was observed in all visual, auditory and tactile modalities. Aphasia, ideomotor apraxia, ideational apraxia and anosognosia were not observed, but there was severe motor impersistence.

CT revealed a right, frontal, haemorrhagic contusion surrounded by oedema (Fig. 5). A HM-PAO SPECT study was performed that same week, revealing a decrease in the regional cerebral blood flow to the frontal lobe around the haematoma (Fig. 6a).

Clinical course

The patient's disorientation to time and place, anterograde amnesia and confabulation resolved within several weeks of their onset. A subsequent score on the Mini-Mental State Examination was 23/30; word fluency was 5/min and digit span retention was 5 for forward and 2 for reverse recall. His Raven's coloured progressive matrices score improved to 15/36. His performance on all tasks demonstrating unilateral spatial neglect improved in the 4 weeks following the injury, with increased regional cerebral blood flow to the frontal lobe around the site of the haematoma (Fig. 6b).

Discussion

Imamura and Uemura [6] have proposed several aetiological conditions for unilateral spatial neglect: (1) the lesion extends to the basal ganglia; (2) the lesion involves the occipital lobe as well as the frontal lobe; or (3) the subcortical lesion in the frontal lobe is extensive. In each of our patients, an extensive subcortical lesion was noted in the frontal lobe, but it did not involve the parieto-occipital lobe or the basal ganglia. Vallar et al. [15] have examined functional lesions in two patients with unilateral spatial neglect and subcortical vascular lesions using SPECT; they suggested that the right fronto-temporo-parietal cortex could have been the site of the causative lesion in these cases. However, we did not find a reduction of cerebral blood flow in the parieto-occipital junctions of our patients, even when the frontal lobe neglect was being observed. Therefore, we propose that the neglect was caused by a single lesion confined to the frontal lobe.

Concerning the mechanism of frontal lobe neglect due to subcortical lesions, Heilman et al. [5] have hypothesized that the increase in local pressure on the surrounding tissue caused by such lesions produces disconnection of the nerve fibres projecting to the cortex and or damage to the subcortical structures. Based on physiological and

anatomical findings in patients with unilateral spatial neglect, Mesulam [13] has described four cerebral regions that form a cortical network for directed attention. According to his review, the posterior parietal component integrates sensory inputs from the contralateral space and provides a sensory map; the limbic component in the cingulate gyrus plays a central role in providing motivation against the contralateral space; the frontal component integrates outputs relating to the start of movements and inhibition; and the reticular component provides the underlying level of arousal and vigilance observed in the above three regions. Clinically, unilateral spatial neglect associated with a frontal lobe lesion is characterized by the different modalities of neglect, such that the symptoms are mild and resolve early in most cases [6]. Binder et al. [1] indicated that the combination of abnormal cancellation and normal line bisection was always associated with a frontal or basal ganglia localization. Our two patients also showed severe unilateral spatial neglect on cancellation task and figure copying, yet showed minimal lateral shift on line bisection. Daffner et al. [2] reported a patient with unilateral spatial neglect resulting from two different strokes, one of which occurred in the right frontal lobe and the other in the right parietal lobe. This patient demonstrated dissociation between his exploratory-motor and perceptual-sensory neglect. Liu et al. [7] compared two patients with unilateral spatial neglect, one with a right parietal lesion and the other with a right frontal lesion; they observed that the neglect in the former was more prominent during perceptual-sensory tasks, while that in the latter was more prominent during exploratory-motor tasks.

In the early stages of their conditions, our patients demonstrated mild, unilateral spatial neglect with a combination of an exploratory-motor and a perceptual-sensory neglect; both of these manifestations resolved later. However, we could not determine any qualitative differences between these conditions because of their simultaneous resolutions. The regional CBF in the frontal lobe around the haematoma appeared to be improved on follow-up SPECT associated with recovery from the frontal lobe neglect.

We have reported two cases of unilateral spatial neglect caused by frontal lobe contusions, and have analysed its underlying mechanism using cerebral blood flow studies. The contusions were confined to the right frontal lobes on both CT and SPECT. We conclude that unilateral spatial neglect can be caused by isolated frontal lesions.

References

1. Binder J, Marshall R, Lazar R, Benjamin J, Mohr JP (1992) Distinct syndrome of hemineglect. *Arch Neurol* 49: 1187-1194
2. Daffner KR, Ahern GL, Weintraub S, Mesulam MM (1990) Dissociated neglect behavior following sequential strokes in the right hemisphere. *Ann Neurol* 28: 97-101
3. Damasio AR, Damasio H, Chui HC (1980) Neglect following damage to frontal lobe or basal ganglia. *Neuropsychologia* 18: 123-132
4. Heilmann MH, Valenstein E (1971) Frontal lobe neglect in man. *Neurology* 22: 660-664

5. Heilman KM, Valenstein E, Watson RT (1983) Localization of neglect. In: Kertesz A (ed) *Localization in neuropsychology*. Academic Press, New York, pp 471–492
6. Imamura Y, Uemura K (1989) Unilateral spatial neglect following damage to right frontal lobe. *Higher Brain Funct Res (Jpn)* 9:211–218
7. Liu GT, Bolton AK, Price BH, Weintraub S (1992) Dissociated perceptual-sensory and exploratory-motor neglect. *J Neurol Neurosurg Psychiatry* 55:701–706
8. Maeshima S, Hyoutani G, Terada T, Nakamura Y, Yokote H, Hayashi S, Komai N, Dohi N (1990) Effect of thalamic neglect on activities of daily living. *Sogo Rehabil* 18:445–450
9. Maeshima S, Shigeno K, Dohi N, Kajiwara T, Komai N (1992) A study of right unilateral spatial neglect in left hemispheric lesions: the difference between right-handed and non-right-handed post-stroke patients. *Acta Neurol Scand* 85:418–424
10. Maeshima S, Funahashi K, Ogura M, Itakura T, Komai N (1994) Unilateral spatial neglect due to right frontal lobe haematoma. *J Neurol Neurosurg Psychiatry* 57:89–93
11. Maeshima S, Dohi N, Nakai K, Funahashi K, Itakura T, Komai N (1994) A clinical study of unilateral spatial neglect in the patients with intracerebral hemorrhage. *Jpn J Rehabil Med* 31:391–397
12. Mesulam MM (1981) A cortical network for directed attention and unilateral neglect. *Ann Neurol* 10:309–325
13. Mesulam MM (1985) Attention, confusional states, and neglect. In: Mesulam MM (ed) *Principles of behavioral neurology*. Davis, Philadelphia, pp 125–168
14. Vallar G, Perani D (1986) The anatomy of unilateral neglect after right hemisphere stroke lesions. A clinical/CT-scan correlation study in man. *Neuropsychologia* 17:493–501
15. Vallar G, Perani D, Cappa SF, et al (1988) Recovery from aphasia and neglect after subcortical stroke: neuropsychological and cerebral perfusion study. *J Neurol Neurosurg Psychiatry* 51:1269–1276