

Multiple burr-hole operation for adult moyamoya disease

TETSURO KAWAGUCHI, M.D., SHIGEKIYO FUJITA, M.D.,
KOHKICHI HOSODA, M.D., YOSHITERU SHOSE, M.D., SEIJI HAMANO, M.D.,
MASAKI IWAKURA, M.D., AND NORIHIKO TAMAKI, M.D.

Department of Neurosurgery, Hyogo Brain and Heart Center at Himeji, Himeji, Japan; and Kobe University School of Medicine, Kobe, Japan

✓ Excellent results from multiple burr-hole operations for adult moyamoya disease are reported in this study. Ten patients had between one and four burr holes (mean 2.1) drilled in each hemisphere. In four patients new burr holes were added on the opposite side after depression of cerebral blood flow (CBF) was detected by follow-up single-photon emission computerized tomography imaging of the brain with *N*-isopropyl-p-[¹²³I]iodoamphetamine. The postoperative follow-up period ranged from 6 to 62 months (mean 34.7 months). Beginning at 6 months postsurgery, angiograms disclosed rich neovascularization at 41 of 43 burr holes, first from the middle meningeal artery, then from the superficial temporal artery.

Neovascularization did not occur at two burr holes at which there was subdural effusion and local cerebral atrophy, respectively. Progression of stenosis of the major vessels was seen in six patients. Moyamoya vessels were decreased at six sites in four patients. The CBF study revealed that the reactivity to acetazolamide improved in all six patients tested. Transient ischemic attacks disappeared in all six patients presenting with this symptom, and preoperative symptoms improved in both of the patients who presented with cerebral infarction and in both patients with intraventricular hemorrhage. There was no mortality or morbidity, and no new neurological deficits or rebleeding developed during the follow-up period. The authors strongly recommend the multiple burr-hole operation as the surgical treatment of choice for adult moyamoya disease because of its safety and effectiveness.

KEY WORDS • moyamoya disease • multiple burr-hole operation

MOYAMOYA disease is characterized primarily by angiographic findings of bilateral occlusion or stenosis at the terminal portion of the internal carotid artery (ICA) together with a vascular network at the base of the brain.^{19,32} It is also demonstrated by chronological changes on angiograms.⁴¹ This disease has clinical features, including repeated ischemic attacks or, especially in adult cases, bleeding.

The pathogenesis of moyamoya disease is still unclear, but its progression and poor prognosis are well known.⁴⁰ There are several operative treatments for this disease, which require general endotracheal anesthesia, with or without bypass surgery, and these are commonly associated with perioperative risk, including morbidity and mortality.

Recently a burr-hole opening method to ameliorate ischemia in the frontal lobe was reported as a supplementary operation for children⁴ and adults⁵⁰ with moyamoya disease. This method is usually used in combination with direct or indirect bypass surgery. Neovascularization was discovered unexpectedly on repeat angiograms after external ventricular drainage for patients with moyamoya disease.^{4,50} The collateral flow through the burr-hole portion was not, however, sufficient to cover the entire hemi-

sphere. We resolved this problem by making multiple burr holes with the patients under local anesthesia and had excellent results.

Clinical Material and Methods

Patient Population

Ten patients, four men and six women, with a mean age of 37.8 years (range 25–54 years), underwent a multiple burr-hole operation (Table 1). The initial symptoms were transient ischemic attack (TIA) in six patients, cerebral infarction in two, and intraventricular hemorrhage (IVH) in two. One to four burr holes (mean 2.1) were opened in each hemisphere of the patient. Eight patients had bilateral and two had unilateral surgery. The burr holes were opened in the middle cerebral artery (MCA) area at 36 sites in the 10 patients and in the anterior cerebral artery (ACA) area at seven sites in four patients. The mean follow-up period was 34.7 months (range 6–62 months). Follow-up angiography and single-photon emission computerized tomography (SPECT) studies of the brain with *N*-isopropyl-p-[¹²³I]iodoamphetamine (IMP) were obtained routinely more than 5 months after the operation.

Multiple burr-hole operation for moyamoya disease

TABLE 1
Clinical summary of 10 patients with adult moyamoya disease*

Case No.	Age (yrs), Sex	Type of Moyamoya	Presentation	Site (no. of burr holes)	Postop Follow Up (mos) (mean 34.7)	Initial CT or MR Image Findings
1	29, M	D	infarction	rt ACA (1), MCA (1) lt combined EDAS+ACA (2; 1+1)	62	infarction lt frontal white matter
2	28, M	P → D	TIA	rt — lt ACA (+1), MCA (2)	58	lacunae lt frontal white matter, bilat thalamus
3	54, M	D	TIA	rt MCA (1) lt MCA (2)	54	local atrophy lt frontal cortex
4	47, F	D	TIA	rt MCA (2) lt MCA (1)	50	lacunae bilat frontal white matter
5	38, F	D	IVH	rt MCA (2) lt MCA (2)	27	old small intracerebral hematoma rt thalamus, lt caudate head
6	27, F	D	IVH	rt ACA (1), MCA (2) lt ACA (1), MCA (2)	44	normal
7	44, M	P → D	infarction	rt MCA (+2) lt ACA (1), MCA (1)	30	infarction lt occipital lobe lacuna lt frontal white matter
8	40, F	P	TIA	rt — lt MCA (4)	9	normal
9	46, F	P → D	TIA	rt MCA (2) lt MCA (2)	7	normal
10	25, F	D	TIA	rt MCA (4) lt MCA (4)	6	normal

* Abbreviations: ACA = anterior cerebral artery; CT = computerized tomography; D = definite moyamoya; EDAS = encephalo-duroarteriosynangiosis; IVH = intraventricular hemorrhage; MCA = middle cerebral artery; MR = magnetic resonance; P = probable moyamoya; TIA = transient ischemic attack; — = side not drilled; + = holes added later.

Angiograms were assessed in terms of vessel count and extent of the opacified area. The IMP-SPECT findings were assessed by early imaging obtained after acetazolamide administration in six patients. Cerebral angiograms and IMP-SPECT studies were repeatedly performed.

Operative Indications

Nine patients were classified as having definite and one patient classified as having probable moyamoya disease by the diagnostic criteria established by the Research Committee on Spontaneous Occlusion of the Circle of Willis (Moyamoya disease) with the Ministry of Health and Welfare, Japan.^{17,51} Three patients initially diagnosed with probable moyamoya disease developed bilateral lesions during the follow-up period and were categorized for the purposes of this study as having definite moyamoya disease. The sites of the burr-hole operation were decided from angiographic and IMP-SPECT findings, using in particular the images obtained after acetazolamide administration.

Operative Method

The operating procedures were essentially the same as those for burr-hole openings for external ventricular drainage. The operation was performed using local anesthesia. The superficial temporal artery (STA) was located by Doppler ultrasonography to avoid sacrificing it at the time of skin incision. After trephination, the dura and arachnoid were opened widely preserving the meningeal arteries under microscope. The skin was sutured with 2-0 nylon thread, leaving a narrow margin to be sewn closed.

Results

Angiographic Findings

Sufficient neovascularization was found at angiography in all patients at 41 of the 43 burr holes (Table 2). The initial postoperative angiogram was obtained 2 to 23 months (mean 6.7 months) postsurgery. Neovascularization was ascertained on angiograms obtained 3 to 23 months (mean 9.2 months) after the operation. In two patients who had angiograms at an early stage, 2 and 6 months postsurgery, neovascularization was not seen. The volume of collateral flow from the neovascularization through the burr holes was in inverse proportion to the flow from the ICA (Fig. 1).

The extent of the opacified area at the capillary phase on the external carotid angiogram, which indicated the area perfused by neovascularization, was a mean of 35.8% of the frontal lobe and a mean of 51.4% of the parietal lobe in each hemisphere. The medial surface of both lobes (ACA area) was opacified in 12 hemispheres of seven patients. Two to nine (mean 4.3) cortical arteries (the fourth branches, approximately 1 mm in diameter) and two to 13 (mean 5.2) cortical veins (the third tributaries, approximately 1 mm in diameter) were seen at each burr hole on the external carotid angiogram. The neovascularization derived mainly from the meningeal arteries. The collateral flow from the STA developed later or was less related to the neovascularization. Dilation of the collateral vessels reached the maximum diameter between 6 and 12 months postsurgery. Neovascularization did not occur at two burr holes in two patients in whom there was subdural effusion or local cortical atrophy due to infarction.

Decrease in moyamoya vessels was found at six sites in four patients who had well-developed vessels. The pro-

TABLE 2
 Angiographic findings after multiple burr-hole operations in 10 patients with adult moyamoya disease*

Neovascularization†								
Case No.	Site	Total A / B	Opacified Area (%)		Donor Vessels		Progression of Stenosis	Decrease of Moyamoya Vessels
			Frontal Lobe (mean 35.8)	Parietal Lobe (mean 51.4)	No. of Cortical Arteries (mean 4.3)	No. of Cortical Veins (mean 5.2)		
1	rt	2 / 2	100, m	90, m	17	24	no	yes
2	lt	2 / 2	75, m	50, m	8	6	yes	no change
	rt	—	—	—	—	—	yes	not evaluated
3	lt	3 / 3	15	50	15	19	yes	no change
	rt	1 / 1	25, m	15	8	5	no	no change
4	lt	2 / 2	10	15	5	5	no	no change
	rt	2 / 2	25	65, m	7	10	yes	no change
5	lt	1 / 1	0	70, m	5	4	yes	no change
	rt	2 / 2	0	100, m	8	9	no	yes
6	lt	2 / 2	85, m	75, m	13	15	no	yes
	rt	3 / 3	20	25	11	16	no	no change
7	lt	3 / 3	40, m	85, m	8	12	no	yes
	rt	1 / 2	0	50, m	4	8	yes	no change
8	lt	2 / 2	50, m	35, m	11	15	no	no change
	rt	—	—	—	—	—	no	not evaluated
9	lt	4 / 4	25	25	12	14	yes	no change
	rt	2 / 2	25	25	10	9	no	no change
10	lt	1 / 2	0	10	2	2	yes	no change
	rt	4 / 4	75, m	50, m	16	22	no	yes
	lt	4 / 4	75, m	90, m	17	19	no	yes

* Abbreviations: A = number of burr holes through which neovascularization occurred; B = number of burr holes drilled; m = medial lobe was opacified; — = no holes drilled.

† In Cases 7 and 8, neovascularization had not appeared as of 6- and 2-month follow-up angiograms, respectively.

gression of stenosis in major vessels was seen in six patients on the follow-up angiograms. In three cases of probable moyamoya disease the lesion involved the contralateral side. There was no difference between definite and probable moyamoya disease in terms of the volume of neovascularization.

Single-Photon Emission Computerized Tomography Findings

Evaluation of IMP-SPECT findings was performed by using the cerebral-to-cerebellar activity ratios (C/C ratios)

to calculate the uptake count in the region of interest. The region of interest in the cerebellum and the frontal, temporal, parietal, and occipital areas was 5×5 pixels and was 3×3 pixels in the putamen and thalamus. Improvement in the early imaging was obtained after acetazolamide injection in six of six patients, although progression of stenosis was recognized in four patients. Improvement of cerebral blood flow (CBF) was clear in the vicinity of the burr hole. Improvement of reactivity to acetazolamide was seen for nine of 11 sides in the parietal lobe, six of 11 in the frontal lobe, and six of 11 sides in the basal ganglia (Table 3).

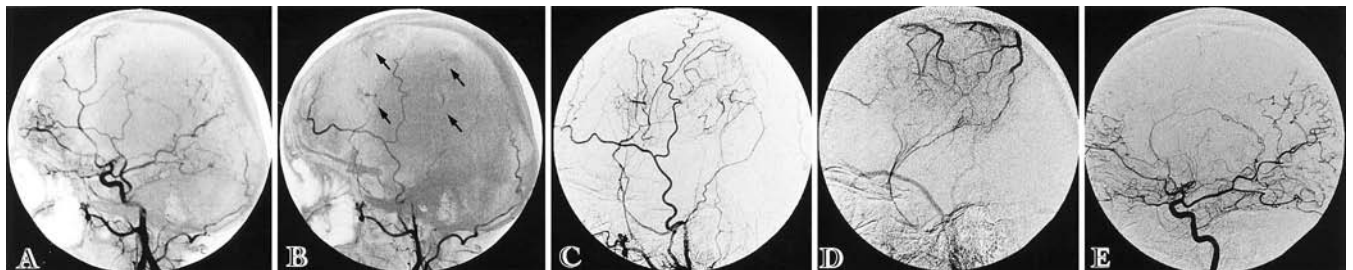


FIG. 1. Case 8. Pre- and postoperative angiograms. A: Preoperative angiogram of common carotid artery showing severe stenosis of the left middle cerebral artery and mild stenosis of the left internal carotid artery (ICA) and anterior cerebral artery (ACA). B: Two months postoperatively, neovascularization is still poor through the four burr holes (arrows). C: Postoperative left external carotid angiogram after 9 months showing marked neovascularization. D: Venous phase of left external carotid angiogram. E: Left internal carotid angiogram showing the progression of stenosis on the left ACA. The ICA flow volume is inversely proportional to the volume of collateral from the neovascularization.

Multiple burr-hole operation for moyamoya disease

TABLE 3

*Changes of IMP-SPECT findings after multiple burr-hole operations in six patients with adult moyamoya disease**

Case No.	Site	Reactivity to Acetazolamide Injection					
		Frontal	Temporal	Parietal	Occipital	Putamen	Thalamus
1	rt	+	±	+	+	±	+
	lt	+	+	+	—	±	+
4	rt	+	+	+	—	+	—
	lt	+	±	+	—	±	±
5	rt	±	±	+	+	+	±
	lt	+	±	+	+	—	+
8	rt	(not evaluated)					
	lt	—	±	+	—	—	±
9	rt	±	±	+	±	—	±
	lt	—	+	±	±	—	±
10	rt	±	—	±	+	±	+
	lt	+	—	+	+	+	+

* Abbreviations: IMP-SPECT = single-photon emission computerized tomography with *N*-isopropyl-p-[¹²³I]iodoamphetamine. + = increased; mean changed value ± standard deviation (SD); — = decreased; mean changed value ± SD.

Clinical Findings

Table 4 shows clinical outcomes. Transient ischemic attacks disappeared in all six patients presenting with this symptom; the frequent TIAs disappeared within 1 month after the operation in two and within 3 months in three patients. The preoperative neurological symptoms improved in two of two patients who presented with cerebral infarction and who underwent operation 1 month after the attack and in two of two patients who presented with IVH, who underwent operation 3 months after the ictus. Nine patients returned to their preoperative occupation. Improvement of clinical symptoms after surgery came earlier than the angiographic appearance of neovascularization.

There was no mortality or morbidity after the surgical procedures. No new neurological deficits appeared, except in one patient who showed progression of right MCA stenosis and who had a TIA before the second burr-hole operation, after which TIAs stopped. No rebleeding developed during the follow-up period.

Illustrative Cases

Case 8

This 40-year-old woman was admitted with complaints of frequent transient weakness and numbness in the right upper extremity and dysphasia. The IMP-SPECT showed decreased CBF and low reactivity to an acetazolamide injection in the left frontal and parietal lobes. Angiograms showed severe stenosis of the left MCA and moderate stenosis of the left distal ICA and left ACA (Fig. 1). A right carotid angiogram showed normal findings. Four burr holes were opened at the frontal and parietal areas. The patient's symptoms decreased in frequency immediately after surgery and disappeared within 1 month. An angiogram obtained 2 months postoperatively showed poor neovascularization, but 9 months after the operation a left carotid angiogram showed well-developed neovascu-

TABLE 4

*Clinical outcomes in 10 patients with adult moyamoya disease**

Case No.	Presentation	Symptom (Frequency of TIA)	Postop TIA Outcome	Return to Previous Occupation
1	infarction	aphasia, rt hemiparesis	improved, no TIA	yes
2	TIA	dysphasia, rt hemiparesis (once a day)	disappeared within 3 mos	yes
3	TIA	numbness of rt upper extremity (once a day, whenever drinking or excited)	disappeared within 3 mos	yes
4	TIA	dysphasia, weakness of rt upper extremity, numbness of lt face (twice a week)	disappeared within 3 mos	yes
5	IVH	dyscalculaion, dysphasia, memory disturbance	improved, no bleeding	yes
6	IVH	memory disturbance	improved, no bleeding	yes
7	infarction	aphasia, rt hemiparesis	improved (one TIA)	no
8	TIA	aphasia (once a day) weakness & numbness of rt upper extremity	disappeared within 1 mo	yes
9	TIA	dysarthria (twice a mo)	disappeared, no TIA	yes
10	TIA	numbness of lt upper extremity (once a day)	disappeared within 1 mo	yes

* Abbreviations: IVH = intraventricular hemorrhage; TIA = transient ischemic attack.

larization through the burr holes and the progression of left ACA stenosis. Postoperative IMP-SPECT with and without acetazolamide showed remarkable improvement (Fig. 2).

Case 10

This 25-year-old woman suffered from frequent transient left hemiparesis and dysphasia. Angiograms (Fig. 3) showed severe stenosis of the bilateral ICA and the presence of moyamoya vessels. An IMP-SPECT study obtained after acetazolamide administration disclosed low reactivity at the bilateral frontal and parietal lobes. Four burr holes were opened in each hemisphere. After the operation TIAs decreased, disappearing within 1 month. An angiogram obtained 6 months after the operation showed rich neovascularization through the four burr holes bilaterally and, notably, the moyamoya vessels were no longer engorged.

Case 4

This 47-year-old woman experienced transient motor weakness of the right upper extremity and speech disturbance. Angiograms (Fig. 4) showed severe stenosis of the bilateral ICAs. After an acetazolamide injection, IMP-SPECT findings showed hyporeactivity at the left frontal and parietal lobes. Two burr holes were made on the right

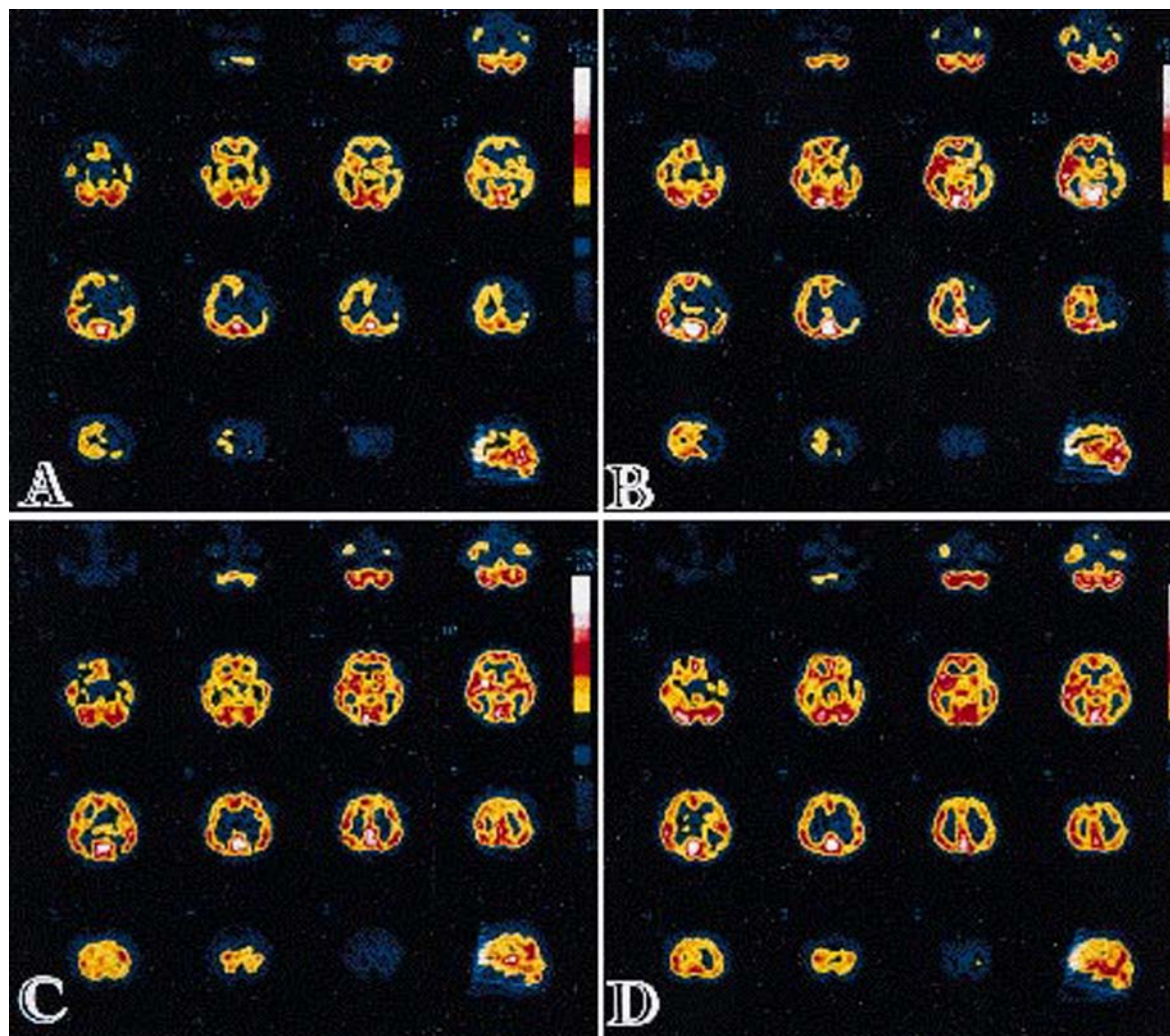


FIG. 2. Case 8. Pre- and postoperative single-photon emission computerized tomography with *N*-isopropyl- $[^{123}\text{I}]$ iodoamphetamine (IMP-SPECT) findings. Upper: Preoperative IMP-SPECT images without (A) and with (B) an acetazolamide injection showing low uptake area in the left frontal and parietal lobes. Lower: Postoperative IMP-SPECT images without (C) and with (D) an acetazolamide injection showing remarkable improvement in the left hemisphere.

and one on the left side. After the operation the patient's TIAs disappeared. Although the development of collateral vessels and improvement of IMP-SPECT findings were slight 5 months later, an angiogram obtained 55 months postsurgery showed considerable amounts of neovascularization filling the branches of the MCA through each burr hole and the progression of bilateral ICA stenosis. Improvement of reactivity to an acetazolamide injection was seen on IMP-SPECT scans.

Discussion

Surgical Treatment of Moyamoya Disease

Surgical treatment of moyamoya disease is classified into direct and indirect bypass methods. Direct surgical treatment includes STA-MCA anastomosis,¹² occipital artery-MCA anastomosis,²⁷ and vein grafts.¹⁰ Indirect sur-

gical treatment includes encephaloduroarteriosynangiosis (EDAS),^{23,24} encephalomyoarteriosynangiosis,^{11,45} encephaloarteriosynangiosis,^{2,29,30} and transplantation of the omentum.¹³ In addition, combined operative procedures such as STA-MCA anastomosis-encephalomyosynangiosis^{15,27,32} and a new modified operative method used with the galea¹⁸ have been reported. These operative procedures must be performed using general endotracheal anesthesia and pose the inevitable risk of low perfusion due to perioperative hypotension and hypercapnia, as well as risks associated with general endotracheal anesthesia.^{27,34,35} Because these procedures require a craniotomy, there is the possibility of postoperative intracranial hematoma.¹⁰ An STA-MCA anastomosis is the surest bypass method, but retrograde flow to the proximal MCA sometimes causes stagnation of blood followed by cerebral infarction; however, an excessive shunt flow might cause intracerebral hemorrhage.^{42,48}

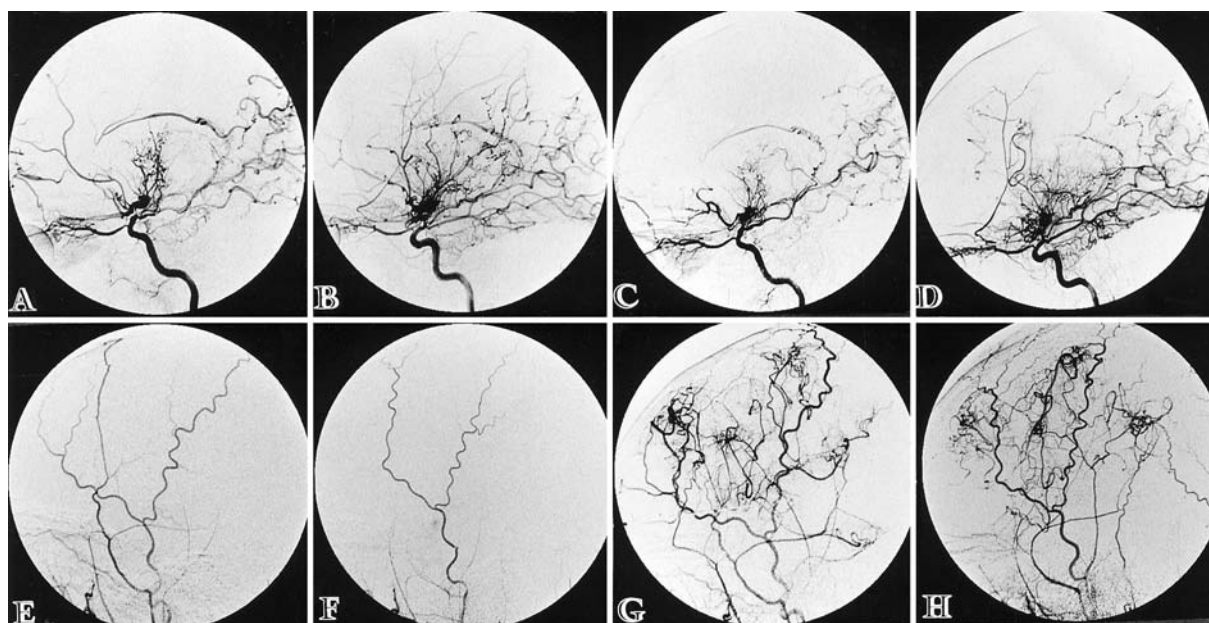


FIG. 3. Case 10. Pre- and postoperative angiograms. Preoperative right (A) and left (B) internal carotid angiograms show severe stenosis of the internal carotid artery and moyamoya vessels. Engorgement of the moyamoya vessels has disappeared in the postoperative right (C) and left (D) internal carotid angiograms. Preoperative right (E) and left (F) external carotid angiograms show a small amount of spontaneous collateral flow. Postoperative right (G) and left (H) external carotid angiograms show rich neovascularization.

Although no collateral flow developed from the STA in some cases of direct or indirect operations, neovascularization from the dural arteries was demonstrated at the craniotomy portion.^{1,14,25,26,38} The multiple burr-hole operation is an indirect surgical treatment. Its procedures are simple and safe because it can be performed with the patient under local anesthesia.

Factors Preventing Neovascularization

Neovascularization occurred at every burr hole except in the portion in which there was subdural effusion and in the area of focal atrophy. Three factors account for the lack of neovascularization. The first is mechanical; the long distance between the dura and brain surface due to cortical atrophy disturbed development of neovascularization from the dural arteries. The new vessels could not reach the recipient vessels on the brain surface. The second factor is low oxygen demand. In the atrophic portion both CBF and cerebral metabolic rate of oxygen (CMRO₂) are low,^{6,20,31} and these areas do not need the new vessels. The third factor is the presence of chemicals such as the angiogenetic factor that induce angiogenesis.^{7,36,37,43} We performed a burr-hole operation for an elderly patient with atherosclerosis and misery perfusion, but no neovascularization occurred. This suggests the existence of an angiogenetic factor.

Donor Arteries and Course of Neovascularization

The donor arteries of neovascularization and the course of development differed from those in other forms of indirect bypass surgery. The main donor artery was the STA in EDAS and the muscular branch of the profound temporal

artery in encephalomyoarteriosynangiosis, whereas in the multiple burr-hole operation, the dural artery was the main donor. The neovascularization occurred first from the dural arteries then from the STA. In most cases the appearance of neovascularization was seen on angiograms obtained within 6 months after the operation. At that time collateral flow from the STA had not yet developed sufficiently. Twelve months after the operation, neovascularization had occurred from the STA in all patients.

Range of Area Perfused by Neovascularization

The range of area perfused by neovascularization was 35.8% of the frontal lobe and 51.4% of the parietal lobe in each hemisphere. The mean area perfused by neovascularization through one burr hole was approximately 38.3% of one lobe. The neovascularization perfused the ACA area in 12 hemispheres of seven patients. The range of perfused area depends on the flow volume from neovascularization and the demand of the recipient cerebral cortex. Neovascularization did not develop in the medial frontal and parietal lobes perfused via leptomeningeal anastomoses by the posterior cerebral artery (PCA). The capacity of flow volume from the neovascularization would be larger than the measured value.

Time to Clinical Improvement

Clinical improvement of the symptoms, including cessation of TIAs, occurs earlier than the angiographic appearance of neovascularization. In two patients TIAs stopped within 1 month and in three they disappeared within 3 months postoperatively, whereas neovascularization was ascertained on angiograms obtained at a mean of

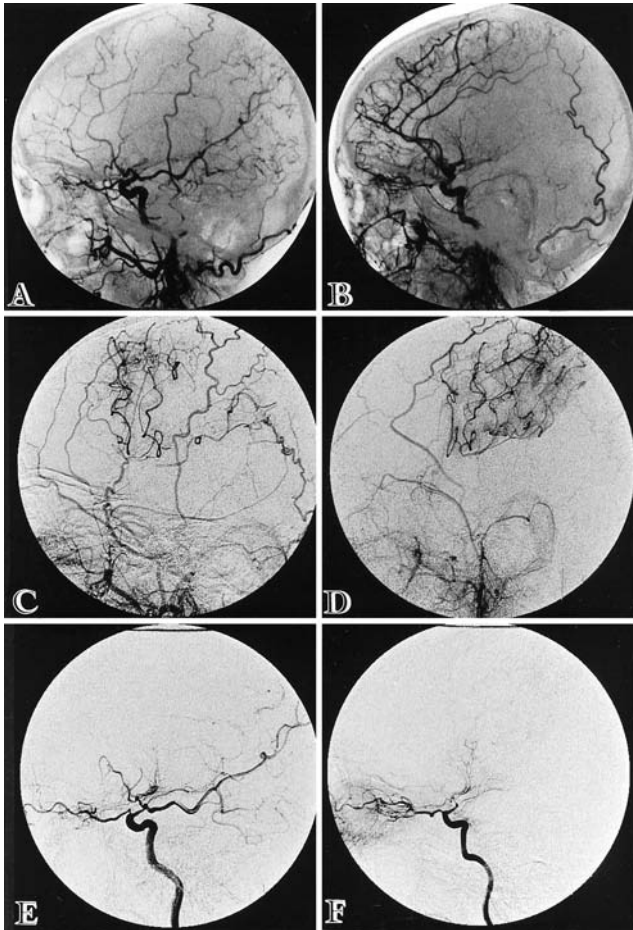


FIG. 4. Case 4. Pre- and postoperative angiograms. Preoperative right (A) and left (B) common carotid angiograms show severe stenosis of the internal carotid artery (ICA). Postoperative right (C) and left (D) external carotid angiograms show a sufficient volume of neovascularization. The progression of stenosis of the ICAs can be seen on the right (E) and left (F) internal carotid angiograms.

6.7 months after the operation in six patients who presented with TIAs. Other investigators have also reported this phenomenon.^{43,44} This time gap between clinical and angiographic improvement is explained by formation of granulation starting within 1 day after injury, as has been shown in rabbit microangiograms.⁴⁴ Before neovascularization becomes visible on angiography, volume sufficient to improve the clinical symptoms would flow into the cortex.

Effectiveness of Surgery for Prevention of Rebleeding

In adult moyamoya disease the goal of treatment is to prevent ischemic attacks and bleeding from the moyamoya vessels. There is no doubt that both direct and indirect bypass surgeries prevent ischemic symptoms.^{11,12,16,24,25,27-29,45,46} The annual reports of the Cooperative Study on Occlusion of the Circle of Willis in Japan, 1980 and 1982, disclosed that rebleeding occurred in 57 (33%) of 175,³³ and 18 (36.7%) of 49⁴⁹ patients with moyamoya disease

who experienced hemorrhagic stroke and rebleeding attacks. The etiology of moyamoya disease is still unclear, but moyamoya vessels are considered to be one of the collateral pathways that develop as the result of chronic cortical ischemia. Improvement of cortical ischemia therefore results in the reduction of the volume of moyamoya vessels following the prevention of bleeding. The effectiveness of a decrease of moyamoya vessels in the prevention of rebleeding has been reported after direct and indirect extracranial-intracranial bypass.^{27,47} Matsushima, *et al.*,²⁵ reported no bleeding in three patients who underwent EDAS during a 39-month follow-up period. Wanifuchi, *et al.*,⁴⁷ also reported findings showing the rebleeding rate after bypass surgery at 20% (two of 10 patients), whereas the rebleeding rate without operation was 46% (six of 13 patients). In contrast, rebleeding from moyamoya vessels in spite of a decrease in their volume has been reported after both direct and indirect surgical bypasses: Nishimoto and Takeuchi³² reported the rebleeding rate after bypass surgery was 10% (four of 40) and the rebleeding rate without surgery was 9% (three of 34). Yonekawa and Kawano⁵² reported 33% (18 of 55), and 11% (five of 46) rebleeding rates, and Suzuki, *et al.*,⁴² reported 25% (three of 12), and 21% (four of 19) with and without surgery, respectively. Nakagawa, *et al.*,³⁰ found minor rebleeding in 25% (two of eight patients) after bypass surgery, one of whom showed no diminution in the volume of basal moyamoya vessels. To prevent rebleeding, a sufficient flow volume from neovascularization is necessary to reduce the flow in all the moyamoya vessels. In our study, the angiographic appearance rate of neovascularization was 95% (41 of 43 burr holes) for all patients and decreases in well-developed moyamoya vessels were seen at six of 18 sites (in four of 10 patients). This percentage of improvement was similar to that for the combined surgical approach. Wanifuchi, *et al.*,⁴⁷ in an angiographic evaluation of 25 operative sites (20 indirect surgery; four direct surgery; one combined) showed neovascularization from the external carotid artery (ECA) at 22 sites (88%) and decreased basal moyamoya vessels at 11 sites (44%) postoperatively.

Although the moyamoya vessels did not disappear completely, in one patient engorgement of these vessels had disappeared after the operation. In two patients with IVH, no rebleeding took place during the follow-up period. This suggests that the flow volume of the neovascularization through the multiple burr holes could reduce excessive blood flow in the moyamoya vessels and hemodynamic stress at the basal ganglia.

Progression of Main Vascular Occlusion

Progression of stenosis of the major vessels was noted in six of the 10 patients. The reason for this was considered to be both the increase in the collateral pathways through the multiple burr holes and the natural course of moyamoya disease.⁴⁰ The volume of collateral flow from the neovascularization was inversely proportional to the flow volume from the ICA. Progression of stenosis was also seen in the area not perfused by the collateral pathways. Probable (unilateral) moyamoya disease is reported to progress to definite (bilateral) disease because the lesion involves the contralateral vessels.^{8,21,22}

Multiple burr-hole operation for moyamoya disease

Cerebral Blood Flow Studies

Many CBF studies, including xenon-enhanced computerized tomography,^{9,31} IMP-SPECT,⁵ and positron emission tomography (PET),^{6,20} have been used to investigate moyamoya disease. The PET study found that the CBF decreased, and the cerebral blood volume (CBV) and oxygen extraction fraction (OEF) significantly increased, but that the CMRO₂ showed no significant change compared with the control value.^{6,31} An elevated CBV represents dilation of the vascular beds and is coincident with low reactivity to acetazolamide in IMP-SPECT studies. The acetazolamide challenge test has shown low reactivity of the cortex and basal ganglia in moyamoya disease.⁵ In the ischemic area the vessels of the leptomeningeal anastomosis are considered to dilate maximally and the collateral vascular beds to enlarge to compensate for the reduced CBF;⁶ therefore there is no reserve dilation of the vessels after the administration of acetazolamide in the ischemic area.⁴⁶ A PET study indicated that neovascularization developed when the cortex was under misery perfusion (decreased CBF and increased OEF and CBV), which was corrected by bypass surgery.^{3,31} The improvement of PET findings in childhood moyamoya disease has been reported both for the cortex and the basal ganglia after indirect or combined bypass surgery.⁶

We defined the operative indication and burr-hole placement using angiographic and IMP-SPECT findings, especially the acetazolamide challenge test results.^{34,39,46} A normal or slightly decreased CBF with low reactivity to acetazolamide injection is the most suitable indication for placement of the burr hole. Patients in whom a large mass due to infarction or hemorrhage is revealed on computerized tomography or magnetic resonance imaging should be excluded. In these cases the CBF markedly decreased, and reactivity after an acetazolamide injection disappeared. The improvement of IMP-SPECT findings for CBF and reactivity to an acetazolamide injection in both the cortex and basal ganglia show the effectiveness of the multiple burr-hole operation for ischemic insults and bleeding.

Comparison With Standard Indirect Bypass Surgeries

First, the multiple burr-hole operation is technically simple and can be performed with the patient receiving local anesthetic, whereas the standard indirect surgeries require craniotomy and general endotracheal anesthesia, procedures that cause various complications during the perioperative period.^{24,45} Second, the donor vessels and course of neovascularization are different, as we have discussed in this paper. The time until angiographic appearance of neovascularization after operation is 6 to 12 months in both the multiple burr-hole operation and other indirect surgical techniques.^{24,25} Third, the time to clinical improvement after operation is the same as that of standard indirect bypass surgeries (within 1–6 months).²⁴ Fourth, the standard indirect bypass surgeries improve the CBF in the MCA area only because the recipient area cannot be preselected,^{24,45} whereas the multiple burr-hole operation can improve the CBF in any area (ACA, MCA, and PCA). Last, concerning the CBF from neovascularization, the multiple burr-hole operation is superior to the standard indirect surgeries, if the number of burr holes

increases to more than two or three. The multiple burr-hole operation is in no way inferior to the standard indirect bypass surgeries.

Conclusions

The multiple burr-hole operation is a simple, safe procedure that is performed using local anesthetic. The recipient area can be preselected and, if necessary, other types of indirect or direct bypass surgery can be added because the multiple burr-hole operation does not injure any branches of the ECA. We strongly recommend the multiple burr-hole operation as the method of choice for treating adult moyamoya disease.

References

1. Ausman JJ, Moore J, Chou SN: Spontaneous cerebral revascularization in a patient with STA-MCA anastomosis. Case report. **J Neurosurg** 44:84–87, 1976
2. Balagura S, Farris WA: Treatment of moyamoya disease by cerebroarteriosynangiosis. **Surg Neurol** 23:270–274, 1985
3. Baron JC, Bousser MG, Rey A, et al: Reversal of focal 'misery-perfusion syndrome' by extra-intracranial arterial bypass in hemodynamic cerebral ischemia. A case study with ¹⁵O positron emission tomography. **Stroke** 12:454–459, 1981
4. Endo M, Kawano N, Miyasaka Y, et al: Cranial burr hole for revascularization in moyamoya disease. **J Neurosurg** 71:180–185, 1989
5. Hoshi H, Ohnishi T, Jinnouchi S, et al: Cerebral blood flow study in patients with moyamoya disease evaluated by IMP SPECT. **J Nucl Med** 35:44–50, 1994
6. Ikezaki K, Matsushima T, Kuwabara Y, et al: Cerebral circulation and oxygen metabolism in childhood moyamoya disease: a perioperative positron emission tomography study. **J Neurosurg** 81:843–850, 1994
7. Imaizumi T, Hashi K, Nakamura T, et al: [Angiogenic properties of various tissues utilized for synangiosis in moyamoya disease.] **No Shinkei Geka** 17:515–520, 1989 (Jpn)
8. Inoue T, Matsushima T, Nagata S, et al: [Two pediatric cases of moyamoya disease with progressive involvement from unilateral to bilateral.] **No Shinkei Geka** 19:179–183, 1991 (Jpn)
9. Ishii R, Ichikawa A, Takeuchi S, et al: Hemodynamic evaluation after surgical treatment for Moyamoya disease. **Jpn J Stroke** 8:200–207, 1986
10. Ishii R, Koike T, Takeuchi S, et al: Anastomosis of the superficial temporal artery to the distal anterior cerebral artery with interposed cephalic vein graft. Case report. **J Neurosurg** 58:425–429, 1983
11. Karasawa J, Kikuchi H, Furuse S, et al: A surgical treatment of "moyamoya" disease "Encephalo-myo-synangiosis." **Neurol Med Chir** 17:29–37, 1977
12. Karasawa J, Kikuchi H, Furuse S, et al: Treatment of moyamoya disease with STA-MCA anastomosis. **J Neurosurg** 49:679–688, 1978
13. Karasawa J, Kikuchi H, Kawamura J, et al: Intracranial transplantation of the omentum for cerebrovascular moyamoya disease: A two-year follow-up study. **Surg Neurol** 14:444–449, 1980
14. Karasawa J, Kikuchi H, Kobayashi K, et al: Evaluation of angiographical changes after ST-MC anastomosis in "moyamoya" disease. **Surg Cereb Stroke** 10:313–317, 1980
15. Karasawa J, Touho H, Ohnishi H, et al: Long-term follow-up study after extracranial-intracranial bypass surgery for anterior circulation ischemia in childhood moyamoya disease. **J Neurosurg** 77:84–89, 1992
16. Kawamura T, Imaizumi S, Sakurai Y, et al: [Effect of various

- surgical procedures for moyamoya disease in children and adults.] **No Shinkei Geka** 22:933-938, 1994 (Jpn)
17. Kawano T, Fukui M, Hashimoto N, et al: Follow-up study of patients with "unilateral" moyamoya disease. **Neurol Med Chir** 34:744-747, 1994
 18. Kinugasa K, Mandai S, Tokunaga K, et al: Ribbon encephaloduro-arterio-myo-synangiosis for moyamoya disease. **Surg Neurol** 41:455-461, 1994
 19. Kitamura K, Fukui M, Oka K, et al: Moyamoya disease, in Vinken PJ, Bruyn GW, Klawans HL (eds): **Handbook of Clinical Neurology. Vol 55: Vascular Diseases. Part III.** Amsterdam: Elsevier, 1989, pp 293-306
 20. Kuwabara Y, Ichiya Y, Otsuka M, et al: Cerebral hemodynamic change in the child and the adult with moyamoya disease. **Stroke** 21:272-277, 1990
 21. Matsushima T, Fukui M, Fujii K, et al: Two pediatric cases with occlusions of the ipsilateral internal carotid and posterior cerebral arteries associated with moyamoya vessels: "unilateral" moyamoya disease. **Surg Neurol** 33:276-280, 1990
 22. Matsushima T, Take S, Fujii K, et al: A case of moyamoya disease with progressive involvement from unilateral to bilateral. **Surg Neurol** 30:471-475, 1988
 23. Matsushima Y, Fukui N, Tanaka K, et al: A new surgical treatment of moyamoya disease in children: a preliminary report. **Surg Neurol** 15:313-320, 1981
 24. Matsushima Y, Suzuki R, Ohno K, et al: Angiographic revascularization of the brain after encephaloduroarteriosynangiosis: a case report. **Neurosurgery** 21:928-934, 1987
 25. Matsushima Y, Suzuki R, Yamaguchi T, et al: [Effects of indirect EC/IC bypass operations on adult moyamoya patients.] **No Shinkei Geka** 14:1559-1566, 1986 (Jpn)
 26. Mishima Y, Yagura H, Hakuba A, et al: Surgical treatment for moyamoya disease. Study on postoperative angiographical findings. **Surg Cereb Stroke** 10:265-269, 1980
 27. Miyamoto S, Kikuchi H, Karasawa J, et al: Pitfalls in the surgical treatment of moyamoya disease. Operative techniques for refractory cases. **J Neurosurg** 68:537-543, 1988
 28. Nagai S, Miyasaka Y, Yoshida T, et al: Effect of indirect cerebrovascular anastomosis in adult moyamoya patients. **Surg Cereb Stroke** 21:127-132, 1993
 29. Nakagawa Y, Gotoh S, Shimoyama M, et al: Reconstructive operation for moyamoya disease. Surgical indication for the hemorrhagic type, and preferable operative methods. **Neurol Med Chir** 23:464-470, 1983
 30. Nakagawa Y, Ikota T, Ohtsuka K, et al: Indication of reconstructive operation for moyamoya disease and ideal operative methods. **Surg Cereb Stroke** 10:230-235, 1981
 31. Nariai T, Suzuki R, Matsushima Y, et al: Surgically induced angiogenesis to compensate for hemodynamic cerebral ischemia. **Stroke** 25:1014-1021, 1994
 32. Nishimoto A, Takeuchi S: Abnormal cerebrovascular network related to the internal carotid arteries. **J Neurosurg** 29:255-260, 1968
 33. Nishimoto A, Ueda K, Homma Y: **The Research Committee on Spontaneous Occlusion of the Circle of Willis (Moyamoya Disease) of the Ministry of Health and Welfare, Japan. Annual Report 1983.** Osaka: National Cardiovascular Center, 1984, pp 66-74
 34. Rogg J, Rustigliano M, Yonas H, et al: The acetazolamide challenge: Imaging techniques designed to evaluate cerebral blood flow reserve. **AJR** 153:605-612, 1989
 35. Sato S, Kwak R, Kadoya S, et al: Operative evaluation of four cases of moyamoya disease. **Surg Cereb Stroke** 10:255-259, 1981
 36. Schweigerer L, Neufeld G, Friedman J, et al: Capillary endothelial cells express basic fibroblast growth factor, a mitogen that promotes their own growth. **Nature** 325:257-259, 1987
 37. Shweiki D, Itin A, Soffer D, et al: Vascular endothelial growth factor induced by hypoxia may mediate hypoxia-initiated angiogenesis. **Nature** 359:843-845, 1992
 38. Spetzler RF, Roski RA, Kopaniky DR: Alternative superficial temporal artery to middle cerebral artery revascularization procedure. **Neurosurgery** 7:484-487, 1980
 39. Sullivan HG, Kingsbury TB IV, Morgan ME, et al: The rCBF response to diamox in normal subjects and cerebrovascular disease patients. **J Neurosurg** 67:525-534, 1987
 40. Suzuki J, Kodama N: Moyamoya disease—a review. **Stroke** 14:104-109, 1983
 41. Suzuki J, Takaku A: Cerebrovascular "moyamoya" disease. Disease showing abnormal net-like vessels in base of brain. **Arch Neurol** 20:288-299, 1969
 42. Suzuki SO, Matsushima T, Ikezaki K, et al: Surgical treatment for adult patients with moyamoya disease—with special reference to hemorrhagic type. **Surg Cereb Stroke** 20:463-467, 1992
 43. Takahashi A, Houkin K, Kamiyama H, et al: Elevated levels of basic fibroblast growth factor in the cerebrospinal fluid of patients with moyamoya disease. **Jpn J Stroke** 16:201-205, 1994
 44. Takasato Y, Matsushima Y, Nariai T, et al: A study of ameliorated cases at early postEDAS period in moyamoya disease. **Jpn J Stroke** 10:25-31, 1988
 45. Takeuchi S, Tsuchida T, Kobayashi K, et al: Treatment of moyamoya disease by temporal muscle graft "encephalo-myo-synangiosis." **Childs Brain** 10:1-15, 1983
 46. Vorstrup S, Brun B, Lassen NA: Evaluation of the cerebral vasodilatory capacity by the acetazolamide test before EC-IC bypass surgery in patients with occlusion of the internal carotid artery. **Stroke** 17:1291-1298, 1986
 47. Wanifuchi H, Takeshita M, Izawa M, et al: Management of adult moyamoya disease. **Neurol Med Chir** 33:300-305, 1993
 48. Watanabe K: Effect of STA-MCA anastomosis for moyamoya disease to child and adult cases. **Surg Cereb Stroke** 10:251-254, 1981
 49. Yamaguchi T, Tashiro M, Minematsu K, et al: **The Research Committee on Spontaneous Occlusion of the Circle of Willis (Moyamoya Disease) of the Ministry of Health and Welfare, Japan. Annual Report 1980.** Osaka: National Cardiovascular Center, 1981, pp 13-22
 50. Yasukawa K, Okudera H, Hongo K, et al: [Adult moyamoya disease with transcranial internal carotid-external carotid (EC-IC) anastomosis through burr hole.] **No Shinkei Geka** 18:373-378, 1990 (Jpn)
 51. Yonekawa Y: Diagnostic criteria for spontaneous occlusion of the circle of Willis ("moyamoya" disease), in Yonekawa Y (ed): **The Research Committee on Spontaneous Occlusion of the Circle of Willis (Moyamoya Disease) of the Ministry of Health and Welfare, Japan. Annual Report 1989.** Osaka: National Cardiovascular Center, 1990, p 184
 52. Yonekawa Y, Kawano T: Follow-up studies of 409 cases registered as "spontaneous occlusion of the circle of Willis"—is surgical treatment effective for the prevention of repeated stroke?, in Yonekawa Y (ed): **The Research Committee on Spontaneous Occlusion of the Circle of Willis (Moyamoya Disease) of the Ministry of Health and Welfare, Japan. Annual Report 1986.** Osaka: National Cardiovascular Center, 1987, pp 15-18

Manuscript received April 28, 1995.

Accepted in final form September 11, 1995.

Address reprint requests to: Tetsuro Kawaguchi, M.D., Department of Neurosurgery, Hyogo Brain and Heart Center at Himeji, 520 Saisho-kou, Himeji, 670 Japan.