

Notable Cases

Amputation of a useless limb

Robert L Pearce and Jane Fraser

Hemiplegia caused by a cerebrovascular accident is a major cause of paralysis of the upper limb. Although amputation of a flail upper limb has been considered by some as a treatment option after brachial plexus injuries, it is generally not contemplated in the management of stroke victims. We discuss the effect of a paralysed arm on quality of life in relation to an elderly man with hemiplegia who requested amputation of his paralysed "useless" upper limb. Clinical and ethical factors were taken into consideration, particularly the issue of informed consent.

Clinical record

A 70-year-old man was referred for treatment of basal-cell carcinoma on his face. He had a left hemiparesis as a result of a cerebrovascular accident (right internal capsular haemorrhage with cortical involvement) at the age of 65. He was right-hand dominant. His hemiplegia did not affect his facial muscles and his speech was unimpaired. He walked with the aid of a stick.

In the course of discussion, he sought advice regarding amputation of his paralysed arm. Although he was coping reasonably well after his stroke, he still occasionally became angry and frustrated with his paralysed arm, because it made dressing difficult. He lived with his wife and was fairly independent, but she often had to assist him with dressing, as it took a long time and he found it tiring.

He had spastic paralysis in all muscles of the affected arm, with contractures in all joints distal to the elbow. There was no evidence of voluntary movement in the left upper limb. Marked spasticity in his left arm and leg was associated with left hyperreflexia and a left extensor plantar response. Sensation was present, although diminished, in the left hand. Because of contractures in the paralysed

hand, he lived constantly with a bad odour from this hand, which was almost impossible to wash.

A resting splint maintaining functional wrist extension, thumb abduction and metacarpophalangeal extension, to be used at night, had been tried previously but without success, as the contractures were too well established. He complained of a cold feeling in his left arm and also a dragging pain extending down the arm. The pain was relieved by supporting the arm in a sling, but using a sling added to discomfort across his neck and shoulders.

The patient's medical history included increasing dyspnoea on exertion after the stroke and occasional angina, although a chest x-ray and electrocardiogram showed no significant abnormalities. He was mildly hypertensive and a prostatectomy for adenocarcinoma had been performed several years before the stroke.

After this preliminary discussion, the advice of a gerontologist and opinions of surgical colleagues, especially orthopaedic surgeons, were sought. None had ever had a similar request for amputation of a limb after a stroke. Some considered that it was unnecessary and possibly unjustified.

Despite these varied opinions the patient was still keen to proceed. Consultations for assessment were arranged. These included consultations with his general practitioner, a neurologist, a psychiatrist, an anaesthetist and a physiotherapist experienced in stroke rehabilitation. In each case the consultant was aware of the need to provide the patient with arguments to enable him to give fully informed consent.

The most important preoperative (and postoperative) assessments were performed in the physiotherapy department at Hollywood Private Hospital, where gait, coordination and balance were recorded. Functional assessments

of the contralateral and dominant upper and lower limbs were normal. A video recording of the patient's posture and gait was obtained for comparison after the operation (Figures 1 and 2).

With the benefit of fully informed consent, we proceeded with a routine amputation of the paralysed left arm above the elbow, leaving a stump with about 20 cm of humerus and adequate anterior and posterior myocutaneous flaps for closure without tension. Despite these precautions, some superficial blistering appeared close to the wound during the early postoperative phase. This was associated with oedema in the skin flaps but no other evidence of infection, drainage or discharge. No further deterioration occurred after hyperbaric oxygen treatment, and healing was then uncomplicated.

Postoperative recovery and rehabilitation went according to plan, with the physiotherapist playing an integral role. Along with normal daily living and social skills, the patient's gait, coordination and balance were further assessed at one, three and six months after the operation. A further video recording to demonstrate posture and gait and his ability to stand unaided from a sitting position was obtained at 12 months.

Results

Objective assessment after three years found no significant change in his standing posture (Figures 1-3), which consists of a broad-base support, asymmetrical weightbearing (he stands on the unaffected leg), lateral flexion of the trunk with rotation to the left and flexion of the left hip, and head held in the midline.

Similarly, after three years his gait remained unchanged, although it was observed that he appeared slower and had less exercise tolerance than at the time of operation. He remains mobile with the aid of a walking stick, circumducts the left leg with no heel strike, pivots around his rigid left leg and does not step through with the right leg.

We used the Berg Balance Scale (a

Hollywood Private Hospital, Perth, WA.

Robert L Pearce, FRCS, FRACS, Aesthetic and Reconstructive Plastic Surgeon.

Jane Fraser, Manager, Physiotherapy Services.

No reprints will be available. Correspondence: Dr R L Pearce, Hollywood Private Hospital, Monash Avenue, Nedlands, WA 6009.

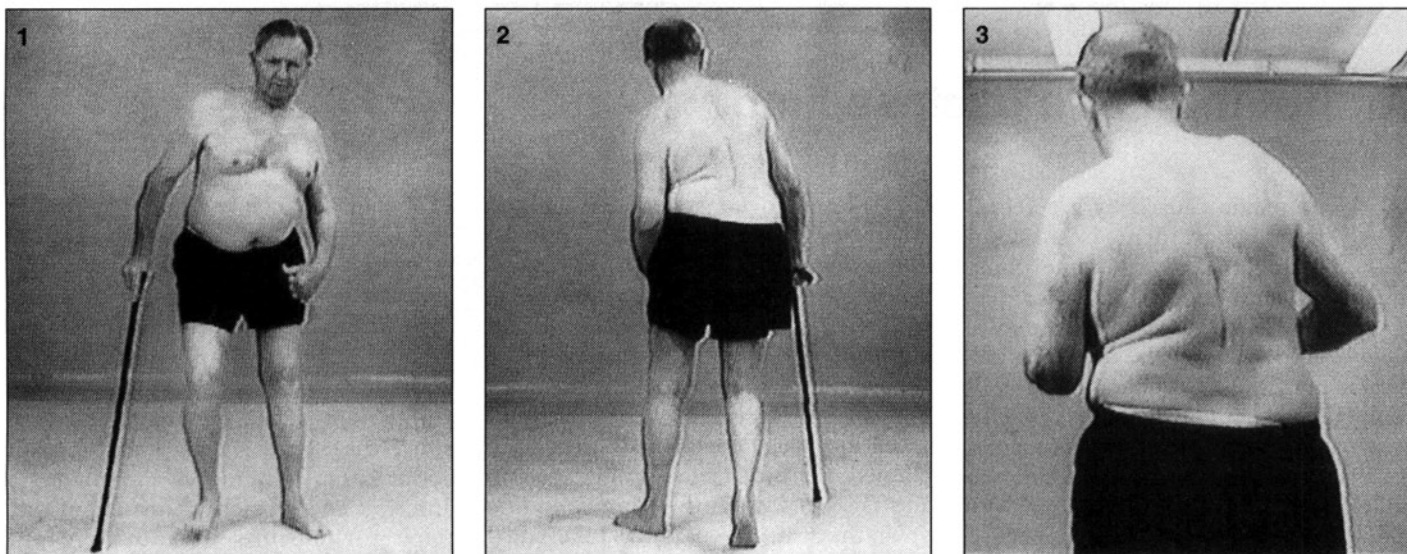


Figure 1: Video images of the 70-year-old man with left hemiplegia. Front view showing broad-based gait before operation, with marked lateral flexion and rotation of the trunk. Figure 2: Posterior view showing trunk posture and the paralysed left arm before operation, with his affected leg flexed at the hip joint. Figure 3: Three years after the operation, showing the upper-limb amputation and no significant postural improvement.

comprehensive test of mobility and balance, with a maximum score of 56)¹ to test his balance, which gave the following results:

Before operation (Oct 1992)	44/56
After operation (Nov 1992)	34/56
At 3-year follow-up (Nov 1995)	32/56

Shoulder posture on the side of the amputation has not been adversely affected and limb function on his dominant side remains essentially unaffected.

The patient's subjective assessment after three years is that having his arm amputated was the correct decision. Dressing is now easier. There is no longer any odour, and no pain or discomfort from the need to wear a sling. He feels his balance has improved and he has not had a fall since the operation. He sleeps better at night and without sedation. He has not returned to playing bowls but continues to drive his own car.

Discussion

Amputation of a limb is a drastic measure under any circumstance. Nevertheless, it is the treatment of choice in a wide variety of conditions, including neoplastic disease, severe trauma and vascular complications, and chronic lymphoedema, particularly when the distal part of the limb is involved. Amputation is not usually considered in the management of stroke victims. However, surgical procedures, including tenolysis, tendon transfers and tendon

lengthening, are occasionally performed on the non-functional upper limb after stroke to correct spastic flexion contractures of the joints, particularly to relieve pain or allow adequate hygiene.²

The mental attitudes of stroke victims to their unresponsive limbs are well documented.³ These can be expected to change over a period of months after a stroke from anxiety and disbelief to anger or depression, frustration and disownment. Finally, the average patient demonstrates resignation and acceptance of the useless limb. Our patient, having reached the stage of acceptance of his disability, regarded his left arm as a nuisance. Louis Pasteur is known to have expressed the agony of many such patients when he observed his useless arm and groaned "If only I could have it off".⁴

Informed consent was particularly important in this case because of the patient's medical history and the risk of postoperative complications. Both subjective and objective assessments were considered essential, the latter being reinforced by a comprehensive team approach.^{5,6}

Assessment during the early postoperative phase showed no evidence of significant improvement in the patient's posture, gait or balance as measured on the Berg scale. The effect of a major anaesthetic and surgical procedure was a degree of diminished incentive and physical activity which did not recover.

His measured deterioration in balance and the lack of improvement in posture and gait are considered to be the direct result of this relatively brief period of immobilisation rather than a complication of the upper-limb amputation. However, we assessed his capacity for independence in self-care and daily living activities to be unaltered. Our patient maintains a positive and optimistic outlook, having successfully discarded what he regarded as an impediment.

In conclusion, although the end result has proved successful and justified the procedure in this patient, amputation in the management of hemiplegia should never be performed routinely or without balanced consideration of all the pertinent clinical factors and risks.

References

1. Harada N, Chui V, Damron-Rodriguez J, et al. Screening for balance and mobility impairment in elderly individuals living in residential care facilities. *Phys Ther* 1995; 75: 462-469.
2. Ryerson SD. Hemiplegia resulting from vascular insult or disease. In: Umphred DA, editor. *Neurological rehabilitation*. 2nd ed. Chapter 22. St Louis: C V Mosby, 1990: 657-658.
3. Waters RL. Upper extremity surgery in stroke patients. *Clin Orthop Clin Res* 1978; 131: 30-37.
4. Vallery-Radot R. *The life of Pasteur*. London: Archibald Constable, 1906: 160.
5. McNeill PM, Walters JD, Webster IW. Ethics decision making in Australian hospitals. *Med J Aust* 1994; 161: 487-488.
6. Hancock L. *Defensive medicine and informed consent*. Canberra: AGPS, 1993: 31.

(Received 3 Jul 1995, accepted 8 Feb 1996)