

Epilepsy surgery in the setting of periventricular leukomalacia and focal cortical dysplasia

Article abstract—We report an infant who had successful epilepsy surgery for intractable infantile spasms in the setting of bilateral periventricular leukomalacia and remote germinal matrix hemorrhage. Although MRI gave evidence of a diffuse cerebral insult and EEG showed hypsarrhythmia, focal epileptogenicity was suggested by previous partial seizures with onset over the right temporoparietal-occipital region and PET hypometabolism in that same area. Right temporoparietal and lateral occipital resection at 15 months resulted in seizure freedom and dramatic developmental progress at 1-year follow-up. Histopathologic examination of resected tissue showed cortical dysplasia, possibly due to the same insult that also resulted in the bilateral periventricular leukomalacia. From an etiologic perspective, this is one of very few reported cases strongly implicating acquired focal cortical dysplasia in response to a prenatal insult. From a clinical perspective, the case illustrates that the spectrum of potential surgical candidacy in infants may be broader than usually suspected.

NEUROLOGY 1996;46:839-841

E. Wyllie, MD; Y. Comair, MD; P. Ruggieri, MD; S. Raja, MD; and R. Prayson, MD

Chugani et al.¹ reported seizure-free outcome after cortical resection in patients with intractable infantile spasms due to focal cortical dysplasia identified by MRI or PET. We report an infant who had successful epilepsy surgery for intractable infantile spasms in the setting of bilateral periventricular leukomalacia and remote germinal matrix hemorrhage.

Case report. The patient was conceived after maternal treatment with clomiphene citrate for infertility. During the first trimester, no maternal trauma, illness, x-ray exposure, or drug ingestion occurred, but pregnancy was complicated by cervical incompetence. Early labor was successfully treated at 25.5 weeks gestation with terbutaline, magnesium sulfate, and cervical cerclage. The vaginal birth was uneventful at 38 weeks with high Apgar scores and no perinatal complications. Birth weight was 3.4 kg. The infant was discharged to home on day 2 and did well until 2 months old, when seizures began.

From 2 to 7 months old, partial seizures occurred in clusters several times a day. Seizures variably involved right eyelid twitching, right or bilateral limb stiffening and trembling, labored respiration, facial grimacing, or eye rolling. Many EEG seizures were recorded over the right temporoparietal-occipital region at 2.5 and 4 months. A single EEG seizure over the *left* temporoparietal-occipital region was recorded at 5 months old. Failed medications included phenobarbital, carbamazepine, phenytoin, valproate, and pyridoxine.

Infantile spasms replaced the partial seizures at 7 months old and occurred in clusters several times a day despite treatment with adrenocorticotrophic hormone, phenobarbital, phenytoin, clonazepam, and felbamate. EEG at 7 and 13 months showed hypsarrhythmia with generalized electrodecrement during spasms (figure 1). Interictal sharp waves were multifocal but tended to be more frequent over the right temporoparietal-occipital region. Sleep spindles were decreased over the right hemisphere.

Delayed development was first noted at age 3 months. The infant made noticeable developmental gains during a single brief seizure-free interval for 2 weeks at 7 months old, but these were lost when the spasms recurred. At 13

months, he smiled responsively but did not coo or babble, he could sit only briefly without support, and he would not reach for objects or hold his bottle while feeding. Visual attentiveness seemed decreased, but there was no evidence of hemianopia. Muscle tone, strength, and deep tendon reflexes were normal with no evidence of hemiparesis. Head circumference was at the 60th percentile for age.

MRI at ages 2.5, 7, and 13 months showed volume loss and abnormal signal in bilateral periventricular white matter, worse in the right parietal region, with enlargement of the atrium of the right lateral ventricle (figure 2). The white matter hyperintensity was pronounced and well-defined on spin density and T₂ images. In contrast with the normal increased T₂ signal of association fibers in infants this age, the white matter changes in our patient extended inferiorly to the ependymal surface and laterally along the atrial margins. A small area of abnormal signal in the right caudate-thalamic groove was consistent with previous germinal matrix hemorrhage. There was no evidence of cortical abnormality in the right temporoparietal-occipital region or elsewhere.

Interictal PET with 18-fluorodeoxyglucose at 13 and 15 months old showed hypometabolism over the right temporoparietal and lateral occipital region (figure 3). Electro-corticography with bilateral subdural electrode strips provided no significant additional information.

Resection of right temporoparietal and lateral occipital cortex was performed at 15 months old. Histopathologic examination of resected tissue showed cortical dysplasia with disruption of the alignment and positioning of neurons within the cortex and increased numbers of heterotopic neurons in the molecular layer and deep white matter. Rare large balloon-type neurons with peripheralized Nissl substance were present within cortical layer 6.

Recovery was uneventful with no new postoperative deficits. A few days after surgery, the infant had four brief isolated head nods but none thereafter. One year after surgery, at 27 months old, the child remained seizure free on weaning doses of antiepileptic medication.

Postoperative developmental progress was dramatic. By 18 months old he walked, ran, and climbed on furniture, and by 22 months he said "mama" and pointed to body

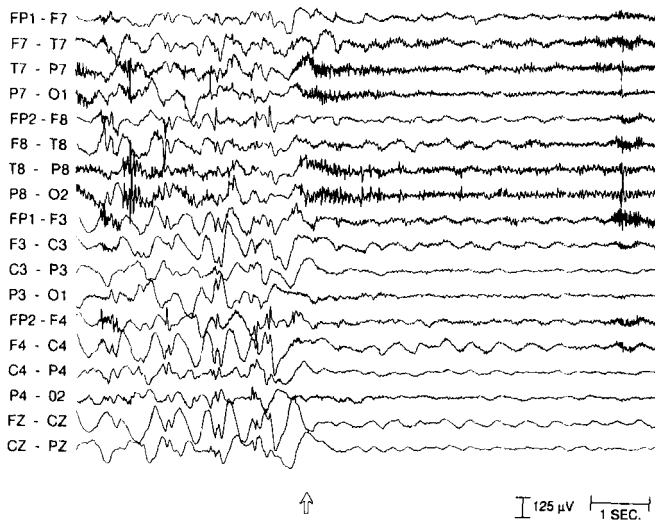


Figure 1. EEG at the start of an infantile spasm (arrow) showing a diffuse electrodecremental pattern replacing the hypsarrhythmia.

parts. He became sociable, interactive, and playful. His parents described him as "a new kid."

Discussion. Some patients with infantile spasms and periventricular leukomalacia have a benign course with resolution of seizures after corticosteroid therapy.² However, our patient had features of catastrophic epilepsy with persistent intractable spasms in the second year of life and severe developmental delay. Serious concerns about the child's long-term developmental outcome lead to referral for epilepsy surgery evaluation. Reversibility of the developmental delay was suggested by the infant's dramatic developmental progress during a single brief seizure-free interval.

By 7 months old, the patient had several features traditionally suggesting a multifocal or diffuse epileptogenic process, including infantile spasms, hypsarrhythmia, developmental delay, and periventricular leukomalacia. However, other features suggested

a focal epileptogenic zone, including early partial seizures with EEG onset predominantly over the right temporoparietal-occipital region, PET hypometabolism in that same area, predominance of sharp waves over the right temporoparietal-occipital region, decreased spindles over the right hemisphere, and MRI evidence that the periventricular white matter loss was greatest in the right temporoparietal-occipital region. One of the most important clues was that the early seizures were partial with regional EEG onset. For infants with catastrophic epilepsy, early video EEG during the phase with partial seizures is critical because regional EEG seizures are typically lost with the evolution to infantile spasms.

Chugani et al¹ showed that focal epileptogenic lesions may manifest as infantile spasms with hypsarrhythmia, and our patient's seizure-free outcome after focal cortical resection confirmed this. However, the criteria for identification of surgical candidates with infantile spasms remain in evolution. In most cases, MRI evidence of a severe insult to both cerebral hemispheres would speak against the advisability of epilepsy surgery. Our case was unusual in that other features suggested a focal epileptogenic zone, despite MRI evidence of a diffuse insult.

Although not visible on preoperative MRI, focal cortical dysplasia was suspected preoperatively based on clinical features and PET and then confirmed by histopathologic analysis of resected tissue. We believe that the focal cortical dysplasia was causally related to the remote intraventricular hemorrhage. If the bleed occurred during the time of late neuronal migration at or before 20 weeks gestation,³ then the sequence of events could have been intraventricular hemorrhage, acute hydrocephalus, damage to bilateral periventricular white matter and radial glial cells worst in the right temporoparietal-occipital region, and disruption of neuronal migration in that area due to degeneration of the guiding radial glial fibers. The timing of the prenatal hemorrhage in this case was unknown, but reactive gliosis

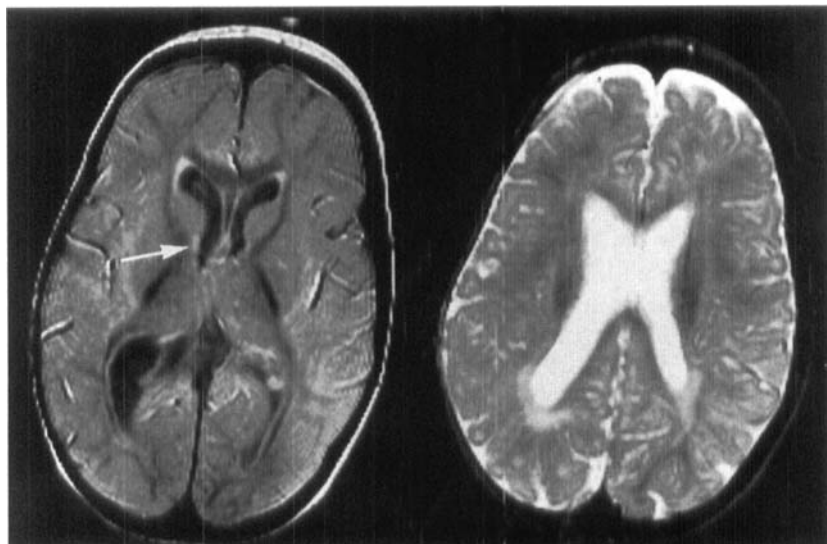


Figure 2. MRI at 15 months old showing bilateral periventricular white matter loss and abnormal signal, worse in right parietal region. The left image also showed a focal area of gliosis with increased signal in the right caudate-thalamic groove (arrow), consistent with remote right germinal matrix hemorrhage. Left image, TR 3,500/TE 22; right image, TR 3,500/TE 120.

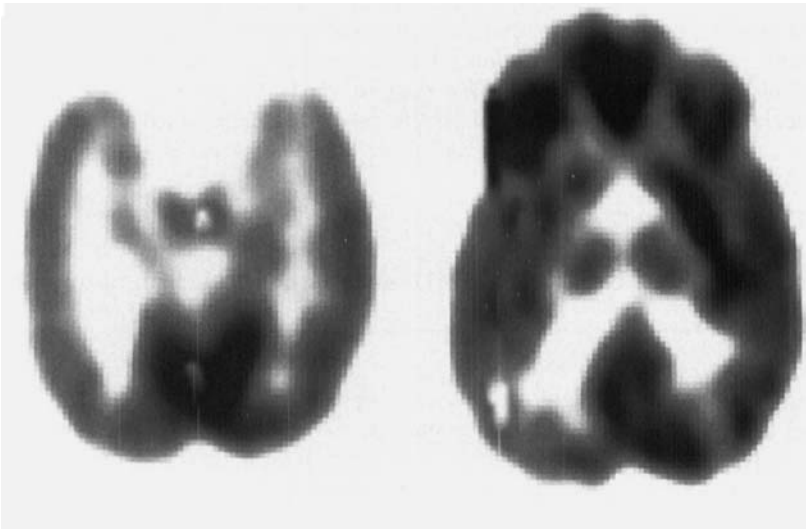


Figure 3. 18-Fluorodeoxyglucose-PET showing hypometabolism over the right temporoparietal and lateral occipital region.

as seen on our patient's MRI may be present histopathologically after prenatal damage as early as 20 weeks gestation.⁴ An acute insult could have occurred during the brief window between the final stages of neuronal migration and the early stages when cerebral insults may result in reactive gliosis, or the bleed could have been an acute event superimposed on a more chronic ischemic process continuing across both epochs. Perhaps because the disturbance probably occurred late in neuronal migration, the microscopic focal cortical dysplasia did not involve gross structural abnormality detectable by MRI.

Others have suggested that prenatal insults may be a cause of acquired cortical dysplasia.^{5,6} However, the very few clearly documented cases are limited almost exclusively to parabiotic twin pregnancies with fetofetal transfusion⁷ or early fetal co-twin demise.^{8,9} An additional case¹⁰ documented focal pachygyria at the margin of a congenital vascular anomaly, with the focal abnormality of neuronal migration presumably due to gradual perfusion failure. Our case also implicates focal cortical dysplasia acquired during a prenatal ischemic event, in association with intraventricular hemorrhage.

Appreciation of the possible mechanisms of acquired focal cortical dysplasia may lead to increased recognition of the possibilities for successful epilepsy surgery in atypical clinical settings. Although the identification of infantile surgical candidates is challenging, the potential rewards are great because of the developmental progress that may occur when the spasms are abolished.

Acknowledgments

We thank William Dobyns, MD, and Charles Truwit, MD, for thoughtful criticism and suggestions and for review of the manuscript and neuroimaging. We also thank Mark Gabr, MD, for kindly referring the patient to our institution.

From the Departments of Neurology (Dr. Wyllie), Neurosurgery (Dr. Comair), Neuroradiology (Dr. Ruggieri), Nuclear Medicine (Dr. Raja), and Neuropathology (Dr. Prayson), The Cleveland Clinic Foundation, Cleveland, OH

Received April 5, 1995. Accepted in final form June 14, 1995.

Address correspondence and reprint requests to Dr. Elaine Wyllie, Head, Pediatric Epilepsy Program, The Cleveland Clinic Foundation/Desk S51, 9500 Euclid Avenue, Cleveland, OH 44195.

References

1. Chugani HT, Shields WD, Shewmon DA, Olson DM, Phelps ME, Peacock WJ. Infantile spasms. I. PET identifies focal cortical dysplasia in cryptogenic cases for surgical treatment. *Ann Neurol* 1990;27:406-413.
2. Cusmai R, Ricci S, Pinard JM, Plouin P, Fariello G, Dulac O. West syndrome due to perinatal insults. *Epilepsia* 1993;34:738-742.
3. Sidman RL, Rakic P. Development of the human central nervous system. In: Haymaker W, Adams R, eds. *Histology and histopathology of the nervous system*. Springfield, IL: Charles C. Thomas, 1982:3-145.
4. Roessmann U, Gambetti P. Pathological reaction of astrocytes in perinatal brain injury. Immunohistochemical study. *Acta Neuropathol* 1986;70:302-307.
5. Sarnat HB. Disturbances of late neuronal migrations in the perinatal period. *Am J Dis Child* 1987;141:969-980.
6. Palmieri A, Andermann E, Andermann F. Prenatal events and genetic factors in epileptic patients with neuronal migration disorders. *Epilepsia* 1994;35:965-973.
7. Bordarier C, Robain O. Microgyric and necrotic cortical lesions in twin fetuses: original cerebral damage consecutive to twinning? *Brain Dev* 1992;14:174-178.
8. Barth PG, van der Harten JJ. Parabiotic twin syndrome with topological isocortical disruption and gastroschisis. *Acta Neuropathol* 1985;67:345-349.
9. Norman MG. Bilateral encephaloclastic lesions in a 26 week gestation fetus: effect on neuroblast migration. *Can J Neurol Sci* 1980;7:191-194.
10. Watanabe M, Tanaka R, Takeda N, Ikuta F, Oyanagi K. Focal pachygyria with unusual vascular anomaly. *Neuroradiology* 1990;32:237-240.

Neurology[®]

Epilepsy surgery in the setting of periventricular leukomalacia and focal cortical dysplasia

E. Wyllie, Y. Comair, P. Ruggieri, et al.
Neurology 1996;46:839-841
DOI 10.1212/WNL.46.3.839

This information is current as of March 1, 1996

Updated Information & Services	including high resolution figures, can be found at: http://www.neurology.org/content/46/3/839.full.html
References	This article cites 9 articles, 0 of which you can access for free at: http://www.neurology.org/content/46/3/839.full.html##ref-list-1
Citations	This article has been cited by 4 HighWire-hosted articles: http://www.neurology.org/content/46/3/839.full.html##otherarticles
Permissions & Licensing	Information about reproducing this article in parts (figures, tables) or in its entirety can be found online at: http://www.neurology.org/misc/about.xhtml#permissions
Reprints	Information about ordering reprints can be found online: http://www.neurology.org/misc/addir.xhtml#reprintsus

Neurology® is the official journal of the American Academy of Neurology. Published continuously since 1951, it is now a weekly with 48 issues per year. Copyright Copyright 1996 by the Advanstar Communication Inc.. All rights reserved. Print ISSN: 0028-3878. Online ISSN: 1526-632X.

