

# Oculopalatal Myoclonus after the One-and-a-half Syndrome with Facial Nerve Palsy

---

Mitchell Jay Wolin, MD,<sup>1</sup> Robert G. Trent, MD,<sup>2</sup> Patrick J. M. Lavin, MD,<sup>3</sup>  
Wayne T. Cornblath, MD<sup>4</sup>

**Purpose:** The one-and-a-half syndrome is an eye movement disorder characterized by a unilateral gaze palsy and an ipsilateral internuclear ophthalmoplegia. The authors describe a previously unrecognized association between the one-and-a-half syndrome and oculopalatal myoclonus (OPM).

**Methods:** Five clinical cases are presented, with pertinent physical findings and radiologic studies.

**Results:** A previously unrecognized association of the one-and-a-half syndrome with subsequent development of OPM appears to exist. Involvement of the facial nerve in patients with the one-and-a-half syndrome may be a predictor of the subsequent development of OPM.

**Conclusion:** Patients with the one-and-a-half syndrome and facial nerve palsy should be followed closely for possible future development of OPM.  
*Ophthalmology* 1996;103:177-180

The "one-and-a-half syndrome" is an eye movement disorder characterized by a unilateral gaze palsy and an ipsilateral internuclear ophthalmoplegia. Typically, the only remaining horizontal eye movement is abduction of the contralateral eye with abducting nystagmus (overshoot dysmetria). The syndrome is caused by a lesion in the lower part of the dorsal pontine tegmentum ipsilateral to the gaze palsy and the ipsilateral internuclear ophthalmoplegia.<sup>1</sup>

Oculopalatal myoclonus (OPM) (tremor) is a condition in which the palate and eyes oscillate rhythmically, although not always in synchrony. Other parts of the body also may be affected by tremors. The disorder usually develops several months after brain stem or cerebellar infarction.<sup>2</sup>

To our knowledge, there are no previous reports of an association between OPM and the one-and-a-half syndrome. We report five patients in whom the one-and-a-half syndrome preceded the development of OPM by a variable period of time.

---

Originally received: February 27, 1995.

Revision accepted: August 7, 1995.

<sup>1</sup> Anderson Eye & Ear Associates, PA, Anderson, South Carolina.

<sup>2</sup> Private practice, Camden, South Carolina.

<sup>3</sup> Department of Neurology and Ophthalmology, Vanderbilt University Medical Center, Nashville.

<sup>4</sup> W. K. Kellogg Eye Center, University of Michigan, Ann Arbor.

Presented in part at the International Society of Neuro-Ophthalmology, Williamsburg, Virginia, June/July 1992.

Each author states that he has no proprietary interest in the development of marketing of this or a competing (instrument/drug/piece of equipment).

Reprint requests to Mitchell Jay Wolin, MD, Medicus, Anderson Eye & Ear Associates, PA, 1655 East Greenville St, Anderson, SC 29622-1226.

## Case Reports

---

**Case 1.** A 42-year-old black man had an extensive left-sided pontine infarction caused by a hypertensive hemorrhage. Results of examination showed a left-sided one-and-a-half syndrome with a left-sided lower-motor neuron facial nerve palsy, Horner syndrome, and a right hemiplegia.

Four months later, results of examination demonstrated vertical oscillations of the eyes and rhythmic bilateral palatal movements, consistent with OPM.

**Case 2.** A 44-year-old black man had a right-sided brain stem hemorrhage (Fig 1). Results of examination showed a right-sided one-and-a-half syndrome with a right-sided, lower-motor

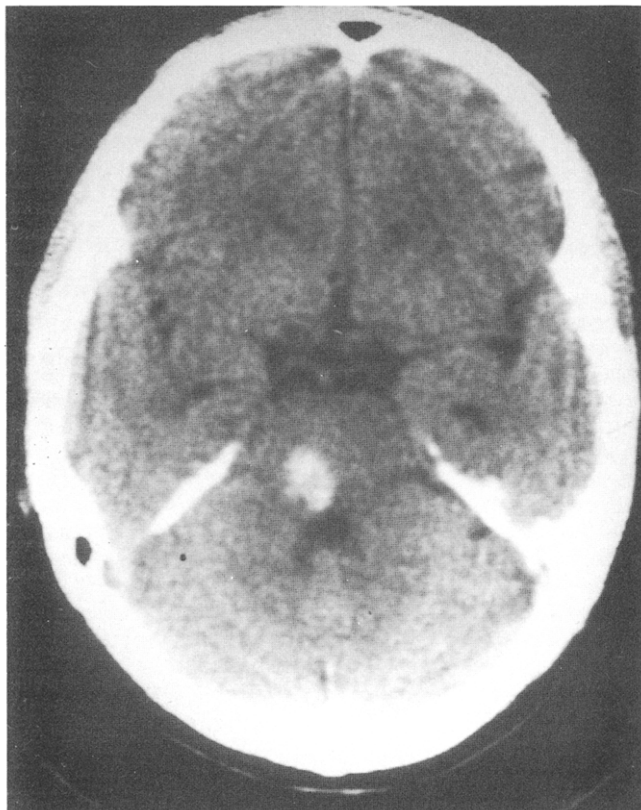


Figure 1. Case 2. Right pontine hemorrhage is seen in the brain stem on computed tomography scan.

neuron facial nerve palsy and a left hemiparesis. Six months later, the patient had rhythmic tinnitus in the left ear. Results of examination demonstrated vertical oscillations of both eyes and rhythmic bilateral palatal movements.

**Case 3.** A 44-year-old black woman, who was involved in a motor vehicle accident, had an incidental brainstem arteriovenous malformation (AVM) discovered by computed tomography. An intraventricular hemorrhage later developed. Magnetic resonance imaging scan showed hemorrhage ventral to the fourth ventricle at the level of the pontomedullary junction surrounding the AVM (Fig 2). Results of examination showed a left-sided one-and-a-half syndrome and a left-sided lower-motor neuron facial palsy. Two years later, vertical oscillations of both eyes and rhythmic bilateral palatal movements, consistent with OPM, developed.

**Case 4.** An 86-year-old woman had a pontine hemorrhage 3 years before examination. Residua from the stroke included a left-sided hemiparesis, right-sided facial nerve palsy, and abnormal eye movements. The right eye lacked any horizontal movement and was esotropic. The left eye could abduct approximately 40°. Elevation of the left eye was mildly limited, and the patient had spontaneous pendular vertical ocular oscillations as well as oscillations of the tongue, palate, platysma, and part of the left side of the face. In addition, she had loss of sensation of the left side of her face, dysarthria, right-sided facial myokymia, and right-sided upper-limb dysmetria.

**Case 5.** A 76-year-old woman had a brainstem ischemic stroke, which resulted in double vision. Results of examination approximately 3 months after the stroke showed a left-sided one-and-a-half syndrome, a left-sided facial nerve palsy, and a

skew deviation with a right hypertropia. The patient had upbeat nystagmus on upgaze and pendular nystagmus on primary, right, and left gaze. Over the next month, the patient noticed vertical oscillopsia. Results of examination showed a vertical pendular nystagmus that increased on right and left gaze. The patient had associated palatal involuntary oscillations.

## Discussion

Each of our patients initially had ocular motility findings consistent with the "one-and-a-half syndrome." In all of our patients, the brain stem damage extended beyond the localized area of the paramedian pontine reticular formation and the medial longitudinal fasciculus (Fig 3). All five patients had coexisting facial nerve palsies, and three patients had a contralateral hemiplegia. One patient had Horner syndrome. Oculopalatal myoclonus later developed in all of these patients, with an interval varying from 4 months to 3 years, although the exact time of onset was unknown (Table 1).

The one-and-a-half syndrome is a condition in which the abducens nucleus or paramedian pontine reticular formation and the ipsilateral medial longitudinal fasciculus are damaged. This combination results in an ipsilateral gaze palsy and loss of ipsilateral adduction but preservation of contralateral abduction and abducting "nystagmus." Vertical gaze is spared, although skew deviation frequently co-exist. Gaze-evoked nystagmus, Horner syndrome, and impaired convergence also may co-exist.<sup>1</sup> The area of damage is in the caudal dorsal pontine tegmentum.

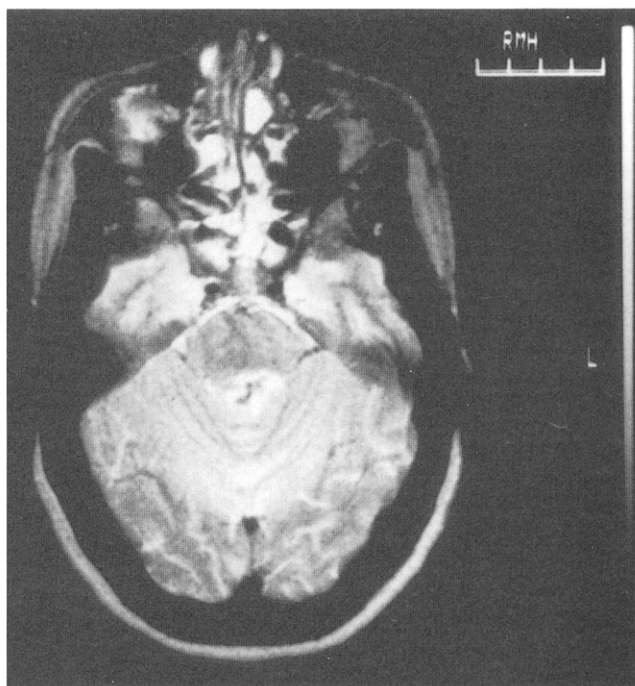


Figure 2. Case 3. On T2-weighted magnetic resonance imaging (TR 2000, TE 100), an arteriovenous malformation with hemorrhage surrounding the fourth ventricle is seen.

Table 1. Localization and Timeframe of Patients

Case No.	Side of Lesion	Side of One-and-a-half Syndrome	Side of Facial Palsy	Time to Development of Myoclonus
1	L pons	L	L	4 mos
2	R brainstem	R	R	6 mos
3	Ventral to 4th ventricle (midline)	L	L	2 yrs (first observed by MD)
4	R midbrain	R	R	3 yrs (first observed by MD)
5	L pons	L	L	4 mos

L = left; R = right; MD = medical doctor.

The most common causes of the one-and-a-half syndrome are brain stem infarction, multiple sclerosis, and miscellaneous causes, such as gliomas and AVMs.<sup>1</sup> Contralateral hemiplegia may occur if the corticospinal tract is involved. Hemianesthesia with medial lemniscus involvement. The extensive damage seen in our patients closely fits the syndrome of lateral tegmental brain stem hemorrhage, as described by Caplan and Goodwin.<sup>3</sup> This complex includes ipsilateral gaze palsy, ipsilateral internuclear ophthalmoplegia, ipsilateral miosis, cerebellar ataxia of the ipsilateral limb (appendicular ataxia), contralateral hemiplegia, and dense contralateral hemisensory loss. Although this syndrome was described with hemorrhage, it can occur with infarction.<sup>4</sup>

Oculopalatal myoclonus is associated with histologic changes in the inferior olivary nuclei, characterized by hypertrophic degeneration. The anatomic substrate for OPM is a "triangle" formed by the ipsilateral dentate nucleus, the contralateral inferior olive, and the contralateral red nucleus. This pathway is referred to as the dentato-rubro-olivary pathway and travels from the dentate nucleus in the cerebellum through the superior cerebellar peduncle and crosses to the opposite side along the red nucleus, reaching the inferior olivary nucleus via the central tegmental tract.<sup>5</sup> Transynaptic degeneration is pre-

sumed to result in OPM. Most causative lesions are supra-olivary in location. Magnetic resonance imaging may show evidence of inferior olivary hypertrophy, or it may be normal.<sup>6,7</sup>

Patients with OPM may be particularly symptomatic from the oscillopsia, or they may have a clicking tinnitus caused by rhythmic movement of the tensor tympani and/or stapedius muscles, although the exact etiology of this symptom is still undetermined.<sup>8</sup> The soft palate movements usually persist during sleep, whereas the pendular ocular oscillations typically do not.<sup>9</sup> In the "essential" form of OPM, the eyes are spared. Although paralysis of lateral eye movement has been associated with subsequent development of OPM,<sup>10</sup> to our knowledge there are no previous descriptions of OPM associated with the one-and-a-half syndrome. Infarction of the pontine tegmentum ultimately can result in olivary hypertrophy and OPM.<sup>11</sup> The pontine tegmentum is also the area of damage in the one-and-a-half syndrome. Therefore, it is not surprising that OPM may subsequently develop in a patient with the one-and-a-half syndrome. All of our patients had coexisting facial nerve palsies. In patients with a one-and-a-half syndrome, the facial nerve may be injured where its fascicle sweeps around the abducens nucleus near the floor of the fourth ventricle where its nucleus lies close to the central tegmental tract. In this case, OPM may develop (Fig 3). Because of the proximity of the facial nerve nucleus to the central tegmental tract, the coexistence of a facial nerve palsy with a one-and-a-half syndrome may be a predictor of subsequent OPM. However, one cannot establish from this limited retrospective review the predictive value of the facial nerve involvement. Nevertheless, there appears to be an association of the one-and-a-half syndrome with subsequent development of OPM that has not been reported.

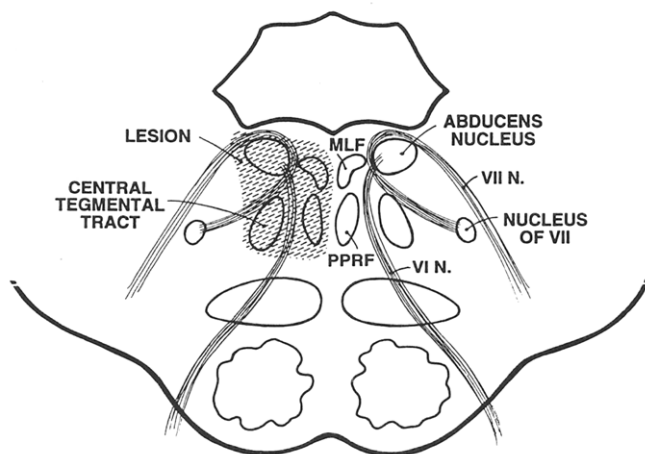


Figure 3. Drawing of the anatomy.

## References


1. Wall M, Wray SH. The one and a half syndrome—a unilateral disorder of the pontine tegmentum: a study of 20 cases and review of the literature. *Neurology* 1983;33:971–80.
2. Miller NR. Walsh and Hoyt's Clinical Neuro-ophthalmology. 4th Edition. vol 2, Baltimore: Williams and Wilkins, 1985;712–15, 920–1.

3. Caplan LR, Goodwin JA. Lateral tegmental brainstem hemorrhages. *Neurology* 1982;32:252-60.
4. Hommel M, Gato JM, Pollack P, et al. Magnetic resonance imaging and the "one-and-a-half" syndrome: a case report. *J Clin Neuroophthalmol* 1987;7(3):161-4.
5. DeBlecker J, Van Landegem W, Crevits L, De Reuck J. Unusual CT and MRI findings in palatal myoclonus. *Acta Neurol Scand* 1992;85:150-3.
6. Pierot L, Cervera-Pierot P, Delattre J, et al. Palatal myoclonus and inferior olivary lesions: MRI-pathologic correlation. *J Comput Assis Tomogr* 1992;16(1):160-3.
7. Dubinsky RM, Hallett M, DiChiro G, et al. Increased glucose metabolism in the medulla of patients with palatal myoclonus. *Neurology* 1991;41:557-62.
8. Litman RS, Hausman SA. Bilateral palatal myoclonus. *Laryngoscope* 1982;92:1187-9.
9. Deuschl G, Mischke G, Schenck E, et al. Symptomatic and essential rhythmic palatal myoclonus. *Brain* 1990;113:1645-72.
10. Lawrence WH, Lightfoote WE. Continuous vertical pendular eye movements after brain-stem hemorrhage. *Neurology* 1975;25:896-8.
11. Zarranz J, Fontan A, Forcadas I. MR imaging of presumed inferior olivary hypertrophy in palatal myoclonus. *AJNR* 1990;11:1164.

---

### Centennial Advertisement

From the *Columbus Pharmacal Co. Catalogue*, Columbus, Ohio. The C. & I. Ophthalmometer.\*



The superior of all instruments for measuring corneal astigmatism; has stood the test of time and is considered the standard of the profession.

Universal in adjustment. Accurate in its findings. Quick in results. Illuminated by electricity. Highly finished in enamel. Strong and durable. Price, \$80.00. Price net cash, \$75.00. A full descriptive circular sent on application.

\* Centennial advertisement provided courtesy of the Museum of Ophthalmology, Foundation of the American Academy of Ophthalmology, San Francisco, California