

- glucose metabolism, and electrical activity in pediatric brain death: case report. *J Neurosurg* 1993;79:752-755
8. Meyer MA. Blood flow and glucose metabolism. *J Neurosurg* 1994;81:644-645
 9. Tsuchida T, Sadato N, Nishizawa S, et al. 99mTc-HMPAO SPECT in the brain death—a case report. *Kaku Igaku* 1993;30:663-667
 10. Altman DI, Perlman JM, Powers WJ, et al. Preservation of brainstem and cerebral blood flow (CBF) in two asphyxiated newborn infants with clinical brain death. *Pediatr Res* 1987;21:487a
 11. Sandler MP, Videlefsky, Delbeke D, et al. Evaluation of myocardial ischemia using simultaneous dual isotope imaging with Tc-99m MIBI/18F-FDG SPECT. *J Nucl Med* 1995;36:35P

that contrary to widespread practice, CT cannot absolutely be relied on for the detection of acute intracerebral hematoma.

Nakada T, Kwee IL. Computed tomography-negative acute thalamic hematoma. *J Neuroimag* 1996;6:119-121

Computed tomography (CT) has long been accepted to be a reliable diagnostic method for the detection of acute intracerebral hematoma [1-4]. Described here is a case of acute thalamic hematoma that was not detected by CT but was unequivocally diagnosed by magnetic resonance imaging (MRI).

Case Report

A 79-year-old white woman presented with acute left-sided weakness. Her medical history was remarkable for hypertension, for which she received treatment. The general physical examination on admission revealed unremarkable findings. The neurological examination revealed the following noteworthy findings. The patient had a fluctuating level of consciousness with normal language function. The left pupil was pinpoint but reactive to light. The eyes tended toward downgaze and the midline. There was a marked left abducens pseudopalsy. Upgaze was limited and invoked serpentine eye movements. The patient had a left flaccid hemiplegia and hemisensory loss involving the face, arm, and leg. The deep tendon reflexes were slightly increased on the left and the Babinski sign was present on the left. Cerebellar function was within normal range. Non-contrast-enhanced CT on admission (Fig 1, top) exhibited a faint area of low density in the right thalamus and minor mass effect. Results of laboratory studies including complete blood cell count, routine coagulation parameters (prothrombin time, partial thromboplastin time, and bleeding time), standard blood chemistry panel, and urinalysis were within normal range. Specifically, there was no anemia (hemoglobin, 12.2 gm/dl [normal, 12-16 gm/dl]; hematocrit, 38.2% [normal, 37-47%]) that could potentially mask the findings of hematoma on CT. A tentative diagnosis of "top of the basilar artery syndrome" associated with rostral basilar artery territory infarction was made. Totally unexpectedly, MRI obtained 12 hours after the admission CT clearly outlined a round mass lesion in the right thalamus, the relaxation properties of which strongly suggested a fresh hematoma. The T1-weighted images (Fig 1, middle) showed an isointense lesion with mass effect, whereas the T2-weighted images (Fig 1, bot-

tom) exhibited a lesion with a low-intensity core surrounded by a high-intensity rim. Nevertheless, the patient's clinical condition rapidly improved over the ensuing 4 days to a residual mild left abducens pseudopalsy and left hemiparesis. Non-contrast-enhanced CT repeated on the seventh day of admission (Fig 2, top) showed minor density changes in the right thalamus, but was still negative for hematoma. In contrast, T1-weighted MRI on the same day showed a significant increase in the intensity of the lesion (Fig 2, middle), an evolutionary change that is virtually pathognomonic for subacute hematoma. Subsequently, the patient was discharged to a rehabilitation center.

Discussion

The MRI findings of parenchymal hemorrhage have been extensively described by various authors [4, 5]. On T1-weighted images, acute parenchymal hematoma is isointense with respect to the brain. As deoxyhemoglobin in the hematoma is oxidized to methemoglobin, marked T1 shortening and hence, an increase in intensity on T1-weighted images ensue. The process of T1 shortening (on the order of days) is especially characteristic of the progression of a parenchymal bleed from the acute to subacute phases, and is virtually diagnostic. The appearance of fresh blood on T2-weighted images is somewhat more diverse and depends on several factors including the field strength of the imager. In principle, however, a hematoma is hypointense with respect to brain during the early phase of hemorrhage, a finding that is more conspicuous in higher-field studies.

The changes in relaxation characteristics documented on serial MRI were unequivocally diagnostic of acute hematoma in the thalamus, presumably hypertensive in origin. In contrast, both the CT on admission and on day 7 were negative for fresh hemorrhage. The remote possibility exists that the bleed occurred between the initial CT and the MRI obtained 12 hours later. However, the patient's neurological condition did not exhibit any worsening corresponding to additional hemorrhage. Additionally, from what is known about the longitudinal CT changes in acute hemorrhage, at least, the second CT would have been expected to be positive for hematoma. Complete resolution of high density on CT for relatively large acute hematoma documented on MRIs within 7 days would be extremely unusual.

This case report clearly illustrates that contrary to widespread practice, CT may not be absolutely reliable for the detection of acute intracerebral hematoma. Without the MRI findings, the present patient was very

Computed Tomography-Negative Acute Thalamic Hematoma

Tsutomu Nakada, MD, PhD

Department of Neurology
University of California, Davis
VANCSC
150 Muir Road
Martinez, CA 94553

Ingrid L. Kwee, MD

Department of Neurology
University of California, Davis

ABSTRACT

A case of acute thalamic hematoma not detected by computed tomography (CT) but unequivocally diagnosed by magnetic resonance imaging (MRI) is presented. A 79-year-old woman presented with acute left hemiparesis. The results of CT obtained on admission as well as on the seventh hospital day were negative for a hematoma. By contrast, serial MRIs exhibited chronological changes in the relaxation properties characteristic of acute hematoma in the thalamus. The case illustrates

Received Mar 28, 1995, and in revised form Aug 3. Accepted for publication Aug 7, 1995.

Address correspondence to Dr Nakada.

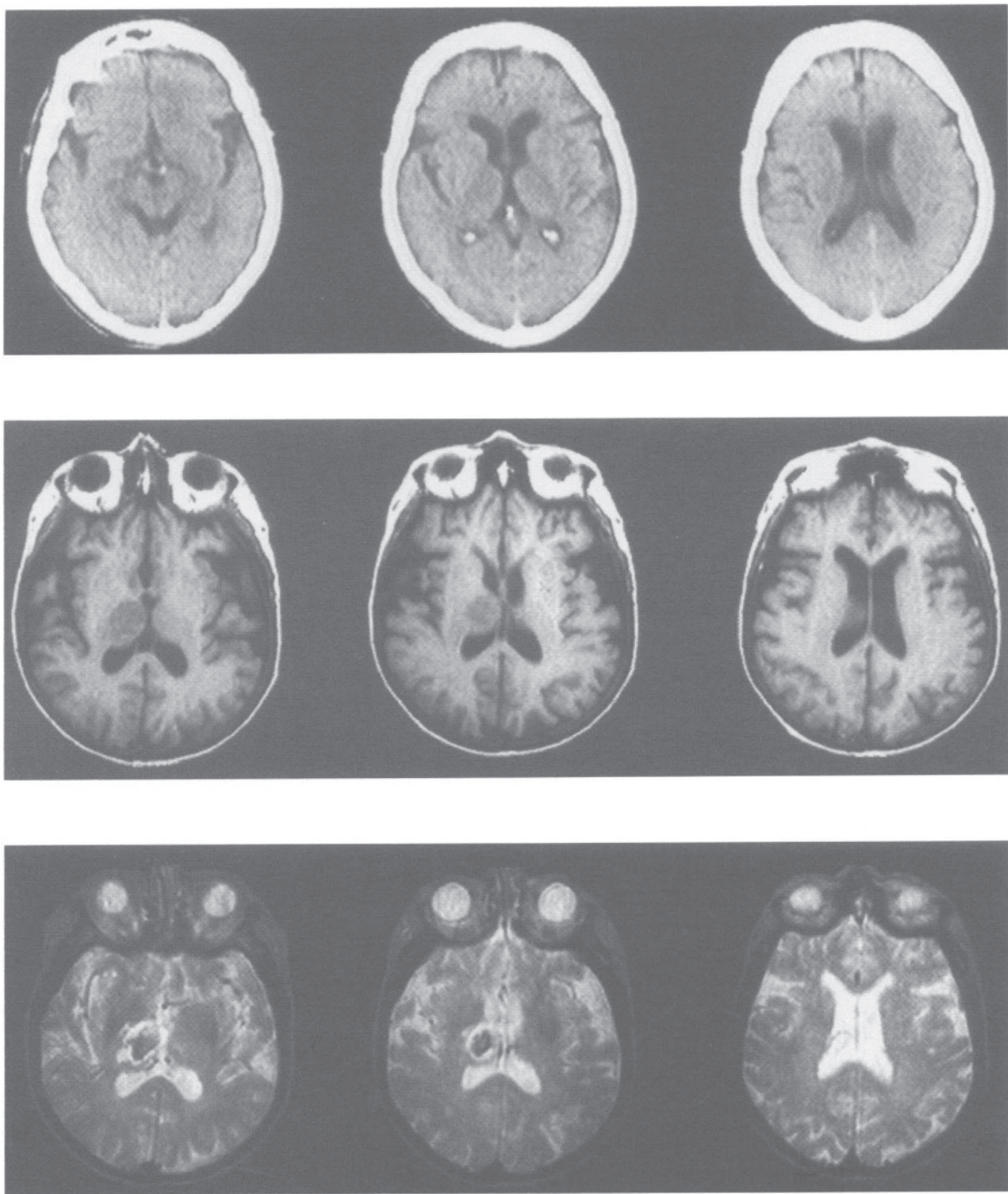


Fig 1. Non-contrast-enhanced CT (*top*) scan and T1-weighted (TR 580/TE 11) (*middle*) and T2-weighted (TR 2000/TE 70) (*bottom*) MRIs (spin-echo images at 1.5 T) of the patient on admission. CT was negative for acute parenchymal hemorrhage, while T2-weighted images were suggestive of acute hematoma.

likely to have been given the original diagnosis of “top of the basilar artery syndrome” associated with rostral midbrain/thalamic infarction. Of note is the lack of potential mitigating factors, such as anemia, accounting for the apparent negative CT findings. This is a single case report and the presented patient may represent an extremely rare case of “CT-negative” acute

hematoma. However, considering the fact that confirmation of “CT-negative” acute hematoma by other means, such as surgical exploration or immediate pathological evaluation, is almost never done, primarily due to the strong reliance on CT sensitivity for fresh blood, it is possible that “CT-negative” acute hematoma may be a more common entity. As in the case of petechial

hemorrhage where MRI is found to be more sensitive than CT, MRI may be considered to be the study of choice in the case of overt hematoma. The clots that exhibit simultaneous T1 and T2 shortening, a pathological condition that is potentially difficult to detect by spin-echo imaging, can also be detected better by gradient-echo imaging [7]. Further investigation is strongly warranted.

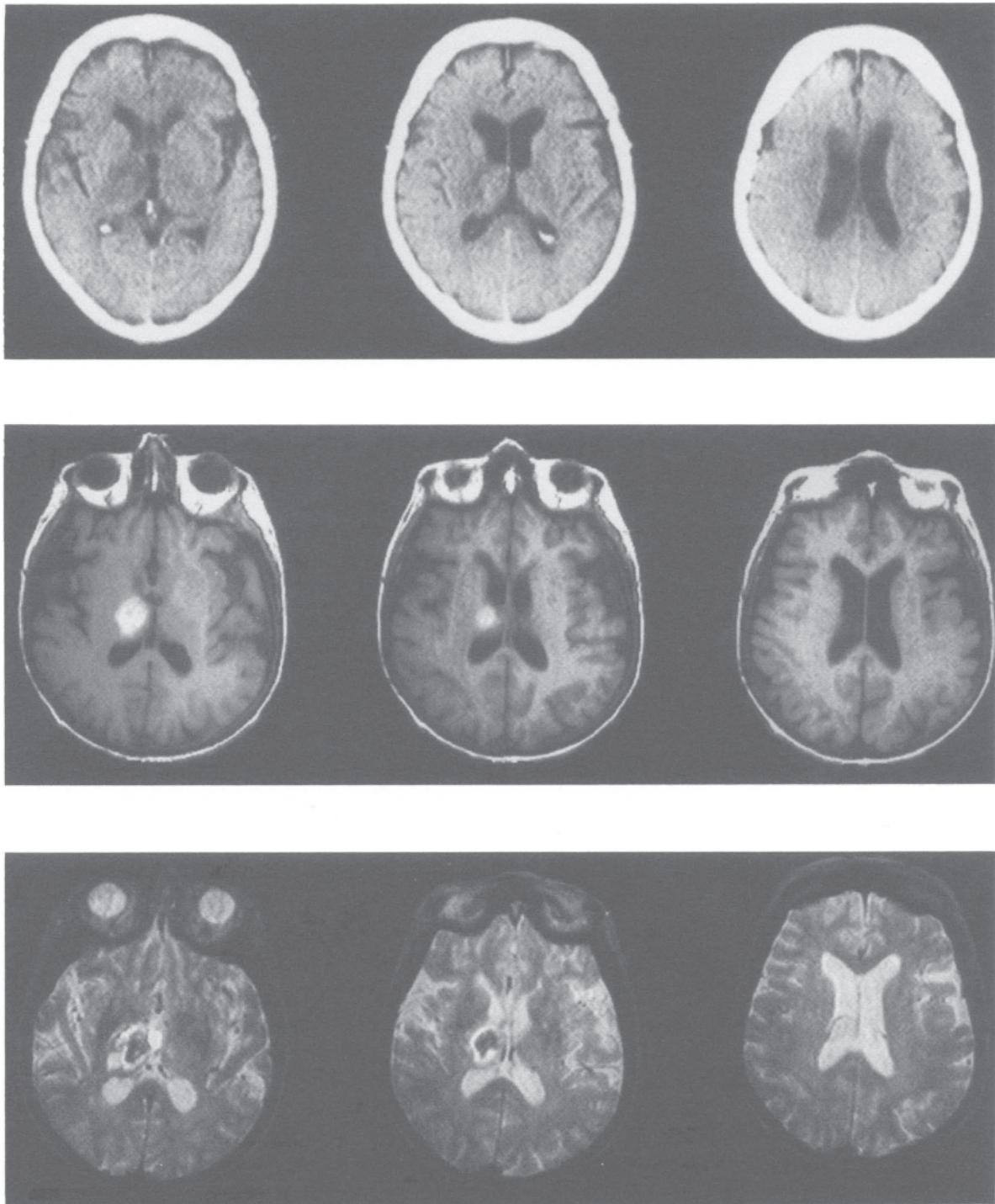


Fig 2. Images obtained on the seventh day of hospitalization. Non-contrast-enhanced CT (*top*) consistently showed negative findings for acute parenchymal hemorrhage. MRI (*middle, bottom*) exhibited a clear-cut lesion in the right thalamus, the relaxation characteristics of which were virtually pathognomonic of acute hemorrhage.

References

1. Hayward RD, O'Reilly GVA. Intracerebral hemorrhage. Accuracy of computerised transverse axial scanning in predicting the underlying aetiology. *Lancet* 1976;1:1-4
2. New PFJ, Aronow S. Attenuation measurement of whole blood and blood fractions in computed tomography. *Radiology* 1976;121:635-640
3. Mason WG Jr, Latchaw RE, Yock DG Jr. Spontaneous hemorrhage during computed tomography. *AJR* 1980;135:181-183
4. Longo M, Fiumara F, Pandolfo I, D'Avella N. CT observation of an ongoing intracerebral hemorrhage. *J Comput Assist Tomogr* 1983;7:362-363
5. Bradley WG Jr. Intracranial hemorrhage. In: Patrain CL, Price RR, Patton JA, et al, eds. *Magnetic resonance imaging*. 2nd ed. Philadelphia: WB Saunders, 1988:217-230
6. Young SW. *Magnetic resonance imaging: basic principles*. 2nd ed. New York: Raven, 1988:148-149
7. Weingarten K, Filippi C, Zimmerman RD, Deck MD. Detection of hemorrhage in acute cerebral infarction. Evaluation with spin-echo and gradient echo MRI. *Clin Imaging* 1994;18:43-55