

Distinctive Forms of Partial Retrograde Amnesia after Asymmetric Temporal Lobe Lesions: Possible Role of the Occipitotemporal Gyri in Memory

Paul J. Eslinger,¹ Amy Easton,¹ Lynn M. Grattan,² and Gary W. Van Hoesen³

¹Division of Neurology, Laboratory of Neuropsychology and Cognitive Neuroscience, College of Medicine, Pennsylvania State University, The Milton S. Hershey Medical Center, Hershey, Pennsylvania 17033, ²Department of Neurology, Neurobehavior Diagnostic and Research Laboratory, University of Maryland School of Medicine, Baltimore, Maryland 21201, and ³Departments of Anatomy and Neurology, University of Iowa College of Medicine, Iowa City, Iowa 52242

We tested the hypothesis that partial forms of retrograde amnesia were associated with highly asymmetric lesions to the inferior and anterior-medial temporal lobe. Postencephalitic subjects EK and DR were both impaired on standardized retrograde memory tests, but showed strikingly different profiles in cognitive tasks of name stem completion, name:face matching, temporal ordering, forced choice recognition, and occupational judgments of famous names and faces from the past 3 decades. EK sustained left inferior and anterior-medial temporal lobe lesion with a small right temporal polar lesion, and showed near-complete loss of retrieval, knowledge, and familiarity associated with famous names but minimal deficiencies with famous faces. DR sustained right inferior and anterior-medial temporal lobe lesion and showed a milder retrograde loss limited to utilizing famous face prompts in name stem completion, name:face matching, occupational judgments, and forced choice recognition. These impairments were also different from the memory retrieval deficit, but intact recognition shown by a case of ruptured anterior communicating artery aneurysm with presumed basal forebrain damage. We hypothesize that EK's extensive loss of famous name knowledge was related to left inferior temporal lobe damage, particularly in the lateral and medial occipitotemporal gyri. This region in the left temporal lobe may serve as a critical processing area for retrograde memory that permits activation of established semantic, temporal, and visual (i.e., facial) associations biographically dependent on the category of proper names. On the basis of connectional anatomy patterns in the nonhuman primate, this region receives extensive hippocampal output and is interconnected with the temporal polar region and cortical association areas, which have been implicated in retrieval and storage aspects of retrograde memory. In the right hemisphere, the occipitotemporal gyri may serve an important role in famous face processing as part of a bilateral neural network.

Anatomical studies of human amnesia have focused to a large extent on the anterograde component of memory processing and have collectively identified several components of this neural system. Structures include the medial temporal region, the basal forebrain, the anterior and medial thalamus, mammillary bodies, portions of limbic cortex and interconnecting pathways such as the fornix, mammillothalamic tract, and ventral amygdalofugal pathway, in conjunction with sensory association cortices (e.g., Corkin, 1984; von Cramon et al., 1985; Mishkin and Appenzeller, 1987; Graff-Radford et al., 1990; Squire and Zola-Morgan, 1991). Although damage to several of these cerebral regions has also been associated with retrograde amnesia (e.g., Sanders and Warrington, 1975; Cohen and Squire, 1981; Warrington and McCarthy, 1988; Squire et al., 1989; Barr et al., 1990; Kapur, 1993; Markowitsch et al., 1993; Schnider et al., 1994), much less is known about the neural substrate and cognitive characteristics of retrograde memory. Therefore, in the ensuing experiments and discussion, we emphasize retrograde memory processes in relation to focal cerebral lesion, particularly of the temporal lobe.

Extensive loss of retrograde memory, extending through virtually all premorbid decades of the patient's life, was observed in patient Boswell (initially described as DRB; Damasio

et al., 1985). Boswell sustained limbic system lesions after herpes simplex encephalitis that were bilateral and extensive. Most prominently affected were the allocortices (hippocampal formation proper), mesolimbic cortices (parahippocampal gyrus, posterior orbital frontal lobe, anterior cingulate gyrus), other paralimbic cortices (temporal pole, insula), anterolateral and inferior temporal cortices (including the inferior temporal gyrus, and medial and lateral occipitotemporal gyri), and subcortical limbic nuclei and pathways (amygdala, septum, nucleus accumbens, fornix, and other elements of the basal forebrain). On standardized tests of famous face, famous name, and public events knowledge from prior decades, Boswell's recall performance was zero and recognition level was at chance. Provision of verbal cues in phonemic or semantic forms and multiple choice response options did not aid recall or recognition memory at all. Even when he was provided the correct answer to a series of items and then retested immediately afterward, Boswell showed no benefit of priming to conscious retrieval or recognition. Similar but less extensive retrograde amnesia was observed in another postencephalitic case, patient SS (Eslinger and Cermak, 1988). Although he was impaired in comparison to normal controls, SS showed some preservation of prior famous face, famous name, and public events knowledge on standardized retrograde memory tests (approximately 45% correct across decades), with some benefit noted from verbal cueing procedures. CT scan revealed the cerebral lesions to involve bilateral portions of the limbic system and temporal cortex in a similar but less extensive pattern than Boswell. In particular, there was greater sparing of inferior temporal cortical structures.

More recently, we reported a case (LD) of *partial retrograde amnesia* after herpes simplex encephalitis, where lesions were markedly asymmetric, affecting primarily the right temporal lobe in its polar, medial, lateral, and inferior aspects (Eslinger et al., 1993). LD was impaired in recall of famous faces and public events from the 5–6 year interval prior to her illness. However, she was able to offer many verbal descriptions, including those that provided structure to her personal past, such as place of birth, schools attended, and other family highlights. These verbal facts appeared isolated from any sense of personal experience that would emanate from a broader (probably nonverbal) knowledge base. She consistently reported and otherwise showed no recent or remote knowledge from nonverbal domains. Despite her level of impairment, she showed clear benefit from verbal cueing procedures on retrograde memory tasks, moderately improving her performance levels. Unlike Boswell, LD demonstrated personal and public historic knowledge, but it was restricted to verbal facts (i.e., partial retrograde amnesia). In light of the strikingly asymmetric pattern of temporal lobe damage, the cognitive data indicated an important role for the right temporal lobe in certain aspects of retrograde memory and supported the hypothesis that the neural substrate for retrograde

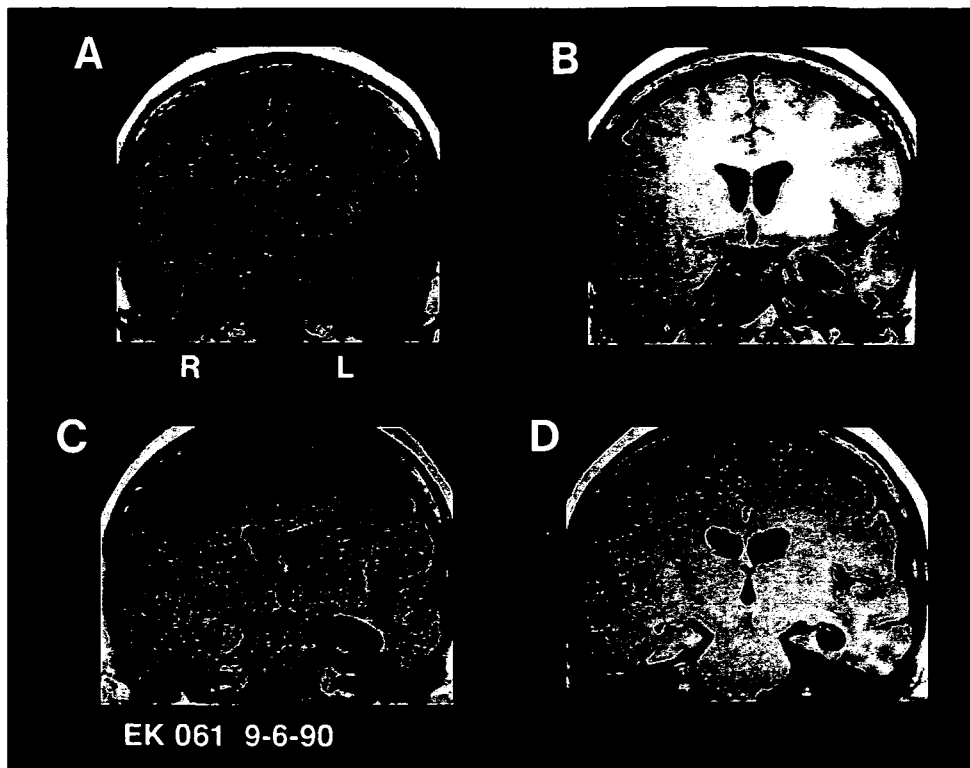


Figure 1. T₁ MRI scan in coronal plane for EK showing extensive left medial, inferior, and anterolateral temporal lobe lesion.

memory necessarily includes both left and right temporal lobe regions.

A partial form of retrograde amnesia has also been described in the postencephalitic patient of Warrington and McCarthy (1988). Experimental cognitive tests demonstrated that the patient retained many aspects of retrograde memory despite a clinically evident retrograde amnesia and failure on public event and facial recognition measures. CT scan revealed the patient's lesion to be highly asymmetric, with much greater involvement of the right than left inferior and anterior-medial temporal lobe (McCarthy and Warrington, 1992) in a pattern similar to patient LD. Although the specific retrograde memory tasks varied between the two patients, a similar beneficial effect of verbal cueing procedures was evident, with both patients doubling their recognition memory scores for past famous faces and public events. These results suggested that while free recall of retrograde memory was impaired, several domains of retrograde knowledge appeared to be intact or minimally affected. Hence, this form of partial retrograde amnesia may be specific to isolated right or predominant right inferior and anterior-medial temporal lobe lesions, and we suspect, quite different from that associated with comparable left temporal lobe lesions. If supported, this formulation would argue for a neural model of retrograde memory that encompasses both temporal lobes but with different functional specialization.

To test this hypothesis, we compared the relative contributions of left and right inferior and anterior-medial temporal lobe lesions to retrograde amnesia by studying two patients with contrasting asymmetric lesions after herpes simplex encephalitis. Although subjects were initially administered a standardized retrograde memory battery, the focus of this study was on experimental probes of past famous face and famous name knowledge with cueing, matching, ordering, forced choice, and multiple choice judgment techniques, suggested in part by the work of Warrington and McCarthy (1988). We hypothesized that because of their different roles

in retrograde memory, damage to the right and left temporal lobes would cause different profiles of impairment, with primary difficulty in retrograde name knowledge after left temporal lobe lesion but difficulty in retrograde face knowledge after right temporal lobe lesion. Furthermore, we wished to study these relative contributions in nonepileptic subjects with focal cerebral damage to limbic system and related structures that encompassed the inferior and anterior-medial temporal lobe. Thus, subjects with cerebral damage from herpes simplex encephalitis were targeted. Damage from herpes simplex encephalitis, though, can extend beyond the temporal lobe to another memory-related structure—the posterior ventromedial frontal lobe and basal forebrain region. Therefore, we attempted to control for this by studying a case of amnesia after rupture and surgical correction of an anterior communicating artery aneurysm, where basal forebrain damage is often implicated. Comparison was also made to performance of normal controls.

Materials and Methods

Subjects

Patient EK

EK is a 47-year-old right-handed woman who was studied 2 years after herpes simplex encephalitis. She completed 15 years of education, previously worked as a seamstress, and was a housewife at the time of her illness. Lesion localization from MRI scan indicated highly asymmetric lesions affecting predominantly the left temporal lobe. T₁ slices in the coronal plane are presented in Figure 1. The left-sided lesion included the medial temporal region (particularly amygdala, hippocampus, entorhinal cortex, and parahippocampal gyrus, including Brodmann's areas 28, 34, and 35), the temporal pole (area 38), anterolateral and inferior temporal cortices (anterior 22, 21, 20), lateral and medial occipitotemporal gyri (area 36, medial 20, and anterior-medial 37), and to a lesser extent the anterior insula and minimally to the posterior ventromedial frontal lobe (area 25) and basal forebrain. The lesion in the right temporal lobe was restricted to the inferior medial polar region (area 38) and did not affect the entorhi-

nal cortex, parahippocampal gyrus, hippocampus, or inferior temporal cortices.

Neuropsychological testing indicated a low average to average range of measured intellect (WAIS-R verbal IQ = 84 and performance IQ = 96). Learning and anterograde memory measures from the Wechsler Memory Scale—Revised indicated a general memory index of 76 (6th percentile), with a verbal memory index of 60 (< 1st percentile), visual memory index of 132 (98th percentile), and delayed memory index of 88 (21st percentile). Hence, visual learning and retention varied from the very superior range for immediate recall (Visual Reproduction I = 98th percentile) to average for 30 min delayed recall (Visual Reproduction II = 65th percentile). While the latter score may suggest some increased or faster forgetting, the score remained well within the average range and commensurate with level of Performance IQ and visual perceptual-spatial measures. The same pattern was observed with other standardized visual memory measures, including the Benton Visual Retention test (Sivan, 1992) and Rey-Osterrieth complex figure. In comparison, EK showed strikingly impaired verbal learning and retention with short stories (Logical Memory I = 1st percentile; Logical Memory II = 4th percentile), paired associates, and word lists. On the Warrington Recognition Memory test, EK's recognition of words was impaired (34 out of 50, < 5th percentile), while recognition of faces was within the average range (45 out of 50, 58th percentile). EK was not aphasic in the classic sense. Her conversational skills were fluent and nonparaphasic, with logical and well-directed responses. Formal assessment with the Multilingual Aphasia Examination (Benton, 1976) also indicated a normal range of reading and aural comprehension, repetition, and writing. Other measures of general semantic knowledge and processing (e.g., WAIS-R Vocabulary, Picture Arrangement, pattern of differential verbal encoding with the Craik-Tulving levels-of-processing procedure) were also within the average range, though a modest postlesion decline (i.e., from average to low average in several measures) was likely. Some naming difficulties were evident, but this varied according to task parameters. Picture naming of verbs, category naming, and sentence completion naming from the German Test of Word Finding (1990) were average, while picture naming of nouns and descriptive naming were mildly impaired. EK's lexical retrieval of category-specific items ranged from 53% correct for inanimate objects to 83% correct for fruits and vegetables and 100% correct for other foods (Dr. J. Hart, personal communication).

On standardized testing of remote memory (Albert et al., 1979), EK was severely impaired. On the famous faces portion of the battery, her score was zero, even with phonemic and semantic cueing procedures. Despite her inability to generate identifying names for facial stimuli, EK appeared to recognize many faces by giving correct associations such as "He was a President" (Carter), "He was shot, oh my" (Kennedy), and "He played movie roles where he was in trouble" (James Dean). To control for the influence of any name retrieval deficiencies, EK was queried directly about each personality on the test, being given the name and asked to provide any information she knew about them. She identified only 3 of 68 names (1920s through 1980s), all recent U.S. presidents (Reagan, Carter, Kennedy). On the recall portion of the remote memory battery, performance was zero with and without cues, and on the recognition portion, performance did not exceed chance levels (17 of 48 correct). This pattern obtained for famous faces and public events through the 1980s as well and remained consistent over 2 years of testing; hence, no temporal gradient was clearly evident. Despite these measured impairments of retrograde memory, EK maintained a sense of personal history and recognition of family members, personal effects, and photos. She readily recalled her spouse and children, their ages, current school levels, and work activities. However, her ability to retrieve and even recognize highly specific verbal information (i.e., names of people, places, and events) was extremely limited. On word association tasks meant to probe past personal experiences (adapted from Crovitz and Schiffman, 1974), EK described details of moving to a Caribbean island with her spouse to undertake missionary work and the birth of three children there (in response to "family"). She also described the difficult choice during high school of whether to pursue nurse's training, which one particular teacher encouraged her to do, but she was unable to finance (in response to "schooling"). These recollections were verified by her spouse in a separate session. More extensive studies of autobiographical memory are being conducted separately. Although EK was not working outside the home at the time

of her illness, she returned to almost all daily activities, including driving about town by herself. Therefore, her overall memory profile can be described as a severe verbal amnesia in anterograde and retrograde compartments, with significant impairment on standardized remote memory tests that required naming of past famous faces, verbal recall of past famous events, and verbal recognition of past public events.

Patient DR

DR is a 57-year-old right-handed man, a skilled laborer with 10 years of education, who was studied 1 year after herpes simplex encephalitis. Lesion localization studies from MRI scan indicated cerebral damage limited entirely to the right (see Fig. 2). Damage was evident in the medial temporal region (particularly amygdala, hippocampus, entorhinal cortex, and parahippocampal gyrus (areas 28, 34, and 35), the temporal pole (area 38), anterolateral and inferior temporal cortices (anterior 22, 21, 20), lateral and medial occipitotemporal gyri (area 36, medial 20, and anterior-medial 37), and to a lesser extent the anterior insula and minimally to posterior ventromedial frontal lobe (area 25). The location and extent of damage along the inferior surfaces of the temporal and frontal lobes was reconstructed in Figure 3 with the aid of standardized brain templates (Damasio and Damasio, 1989) and proportional anatomic grid system (Talairach and Tournoux, 1988). Many of the lesion differences between DR and EK are evident from this figure.

Neuropsychological testing indicated a low average to average range of measured intellect (WAIS-R verbal IQ = 89 and performance IQ = 93). Memory testing with the WMS-R showed a general memory index = 91 (27th percentile), with verbal memory index = 90 (25th percentile), visual memory index = 95 (37th percentile), and delayed memory index = 82 (11th percentile). The retention of visual reproductions was noted to drop from the 48th (average) to the 9th percentiles (borderline), and more extensive measure of visual memory, such as the Visual Retention Test of Benton (Sivan, 1992) showed marked difficulties (1 correct, 17 errors when 5 correct and 7 errors were expected). On the Warrington Recognition Memory test, DR's recognition of new faces was impaired (36 out of 50, 5–10th percentile), while recognition of words was above average (47 out of 50, 75–90th percentile). His return to work was troublesome as it entailed reading blueprints and installing large appliances for regional businesses. Although he continued to know the equipment well and had prospered in this work for 20 years, his installations were now slowed by the need to frequently recheck blueprints and keep the spatial plans in mind. However, there was no evidence of aphasia, apraxia, or complex visual disorder such as prosopagnosia, neglect, visual agnosia, or impaired visual spatial judgment, and he recognized words, objects, family members, and friends without difficulty. Standardized retrograde memory assessment (Albert et al., 1979) indicated significant impairment relative to controls. On the famous faces portion, DR correctly identified 37.5% of the items (30% recognition for faces from the 1980s) without cues. However, identification improved to 87.5% with semantic and phonemic cueing procedures. Recall performance was 34% correct without cues and 36% correct with the semantic cues. Recognition performance was 48% correct. No temporal gradient was evident. However, DR did not appear to have clinically obvious difficulties in retrograde memory. Autobiographical recall was confirmed as accurate by family members. For example, on the word association task, he recounted an episode of getting sunburned after spending the day at a particular creek when he was 7 years old (in response to "sun"), and purchasing a particular model car as his first brand-new automobile 12 years ago (in response to "desire"). Therefore, his overall memory profile can be described as a moderate nonverbal anterograde amnesia and moderate retrograde amnesia to standardized testing.

Patient SAM

SAM is a 42-year-old right-handed man, a semiskilled laborer with 13 years of education, who was examined 1 year after surgical correction of a ruptured anterior communicating artery (ACoA) aneurysm. Measured intellect was average (WAIS-R verbal IQ = 92 and performance IQ = 92). Assessment of anterograde memory with the WMS-R showed a general memory index = 82 (11th percentile), verbal memory index = 83 (12th percentile), visual memory index = 84 (13th percentile), and delayed memory index = 60 (< 1st percentile). SAM has not shown any evidence of aphasia, visual perceptual dis-

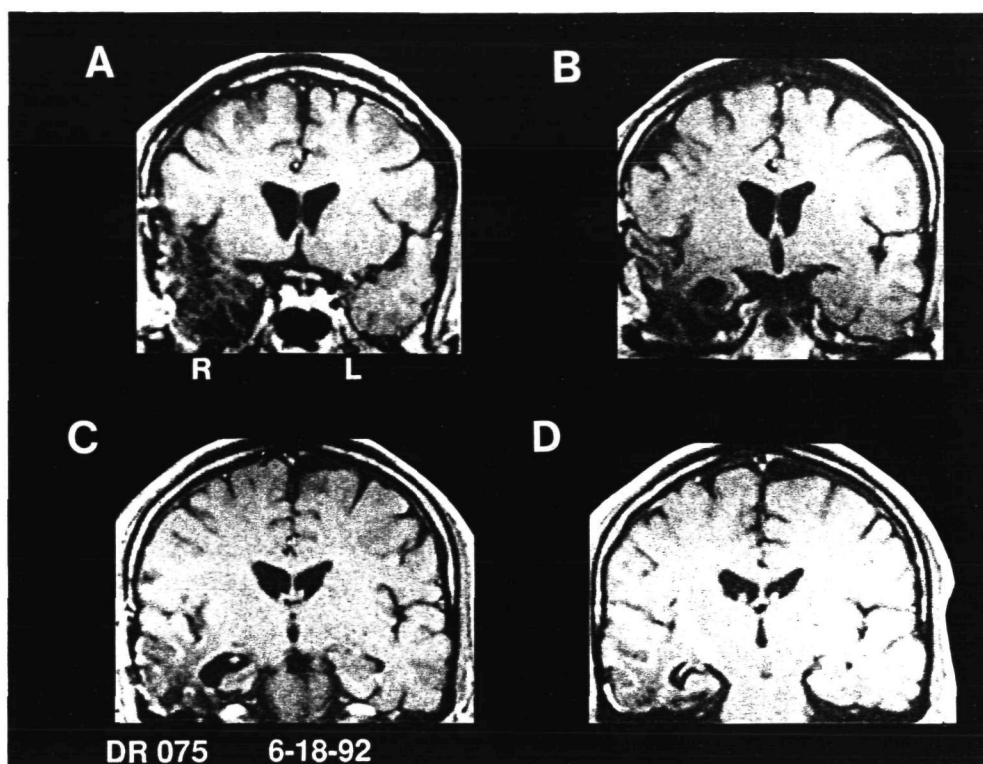


Figure 2. T₁ MRI scan in coronal plane for DR showing extensive right medial, inferior, and anterolateral temporal lobe lesion.

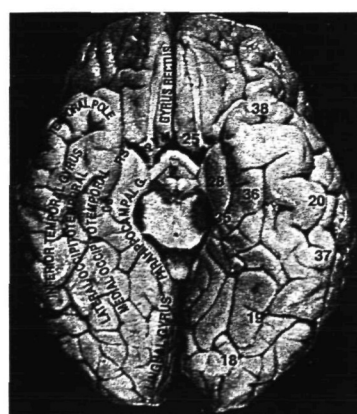
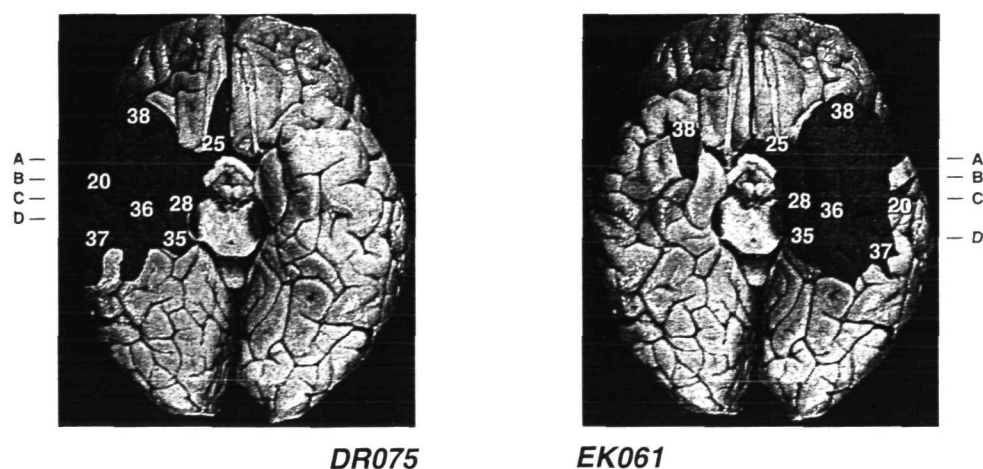


Figure 3. Summary of location and extent of lesions along the inferior temporal and frontal lobes for experimental subjects EK and DR, who both suffered cerebral damage from herpes simplex encephalitis. Lesions are reconstructed on a normal brain image that is labeled with selected anatomic landmarks and Brodmann's areas above. Lesion areas are shaded with the affected Brodmann's areas highlighted in white. A-D sidebars indicate location of cuts from MRI scans in Figures 1 and 2. CS, collateral sulcus; PVM, posterior ventromedial frontal lobe; RS, rhinal sulcus.



turbance, or frontal cortical dysfunction such as perseverations, loss of cognitive flexibility, disorganization, and loss of self-regulation. His postoperative course was typical for ruptured anterior communicating artery aneurysm with unusual confabulations and significant amnesia during the first month after surgery, with continuing improvement since that time. Assessment of retrograde memory (Albert et al., 1979) in the chronic recovery phase indicated significant impairment but clear benefit from verbal cueing procedures. On the famous faces portion, SAM was 56% correct without cues and 94% correct with cues. This pattern obtained for famous faces through the 1980s as well. On both the recall (50% correct) and recognition (56% correct) portions of the retrograde memory battery, performance levels were impaired. In the chronic phase, SAM has clinically evident anterograde memory impairment but little apparent retrograde amnesia, especially with his socially gregarious style of probing for more cues and information while joking and rephrasing conversation. The pattern of findings was consistent with posterior ventromedial frontal lobe dysfunction involving the basal forebrain region.

Normal Controls

Normal control subjects were recruited for this study and administered experimental tasks. Mean age was 55.8 years (range, 45–61 years) and mean educational level was 12.50 years (range, 8–18 years). All were right handed; five were female and three were male.

Experimental Tasks

The experimental retrograde memory tasks were designed to probe knowledge of past famous faces and famous names. Given the age of the experimental subjects, almost all stimuli were drawn from the decades of the 1960s through the 1980s, with a few items from the 1950s. The tasks utilized cueing, matching, temporal ordering, forced choice recognition, and multiple choice judgment techniques, as follows:

(1) *Completion of famous name stems.* The first name and first letter of the last name of a famous person was presented on an individual card. Subjects were required to complete the full name for the 44 stimulus items. Examples included “Dan Q,” “Albert E,” and “Ronald R.”

(2) *Naming of famous faces with name stem cues.* On this task, 18 famous name stems were presented along with a picture of the famous face and subjects were required to complete the name stem cue.

(3) *Name:face matching.* These stimuli were presented under two conditions. In task 1 the complete famous name stimulus was presented first for a period of 15 sec, followed by presentation of three pictures for multiple choice selection. General age, sex, and occupational status was comparable across the three facial stimuli. For example, the name of Margaret Thatcher was presented on a card for 15 sec, followed by pictures of Barbara Bush, Golda Meir, and Margaret Thatcher. The location of the correct face was semirandom, with equal probabilities associated with the first, second, and third photo positions. Task 2 required subjects to first view a single famous face for a period of 15 sec, followed by three names for multiple choice recognition. The three names were equated for similarity of general age, sex, and occupational status.

(4) *Temporal ordering.* Twenty pairs of famous names and twenty pairs of famous faces were presented for temporal order judgments. Subjects were required to judge which member of the pair was famous before the other. Members of each pair differed in the time period of initial popularity by one to three decades (spanning the 1950s through the 1980s).

(5) *Forced choice recognition.* Subjects were required to choose the famous name or famous face when each was mixed with two unfamiliar but comparable stimuli on 17 trials. Location of correct items was counterbalanced across the three stimulus positions.

(6) *Occupational judgment.* Subjects were required to judge the occupation of a series of 36 persons, based on their name or their face. A multiple-choice array was provided, consisting of politicians (domestic and foreign), athletes, entertainers-actors, military leaders, and civil rights-religious leaders.

(7) *Familiarity ratings.* Subjects were asked to rate their sense of familiarity with a series of 36 famous names and then 36 famous faces chosen from the 1950s to 1980s. The Likert scale ranged from 0 (no familiarity at all) to 6 (very familiar) and a rating was recorded immediately after each stimulus was presented.

Table 1

Summary of experimental retrograde memory scores (percentage correct)

Task	EK (L > R Temporal lobe lesion)	DR (R Temporal lobe lesion)	Normal controls (SD)	SAM (ACoA aneurysm)
Name stem completion	7%	95%	97% (1.6)	98%
Face naming with name stem cue	17%	89%	98% (2.3)	100%
Name:Face matching (chance: 33%)				
Face prompt	50%	63%	100%	100%
Name prompt	63%	94%	100%	100%
Temporal ordering (chance: 50%)				
Names	50%	100%	95% (5.0)	90%
Faces	90%	94%	97% (2.3)	90%
Forced choice recognition (chance: 33%)				
Names	33%	87%	100%	100%
Faces	94%	67%	96% (3.5)	94%
Occupational judgement (chance: 20%)				
Names	44%	100%	99% (1.3)	100%
Faces	80.5%	89%	98% (2.5)	100%

L, left; R, right; SD, standard deviation; ACoA, anterior communicating artery aneurysm rupture and surgical clipping.

Results

Retrieval of Famous Names

The results for experimental and control subjects are summarized in Table 1. EK, with predominant left temporal lobe lesion, demonstrated profound inability to complete famous name stems (7% correct). When the name stem was paired with its associated face, EK showed only a very modest improvement (17% correct). Hence, her retrieval of famous names continued to be markedly impaired (>5 SDs below normal controls), even with highly salient verbal cues and paired facial stimuli. In contrast, DR, with right temporal lobe lesion, performed at a level comparable to normal controls on the name stem completion task (95% correct), but was mildly impaired when facial stimuli were provided (89% correct). SAM, with amnesia attributed to basal forebrain damage after ACoA aneurysm, was as proficient as normal controls on these tasks.

Name:Face Matching

In these tasks the complete famous name was presented either as the stimulus item or in multiple choice display for response selection. EK showed modest beneficial effects of both face and complete name cueing on name:face matching. Her performance levels were somewhat above the 33% chance level, but still markedly impaired relative to controls. In contrast, DR showed a highly dissociated pattern of name:face recognition memory. When presented with the famous face prompt, DR was clearly impaired in choosing the associated name (63% correct); however, when presented with the famous name first, his facial recognition was comparably better and very close to the normal control level. SAM was entirely normal on name:face matching.

Forced Ordering and Recognition

In the temporal ordering and forced choice recognition tasks there was no requirement to retrieve names or identify faces,

Table 2
Familiarity ratings for past famous names and famous faces during the occupational judgement task

Task	EK (L > R Temporal lobe lesion)			DR (R Temporal lobe lesion)			Normal controls			SAM (ACoA aneurysm)		
	Mean	(SD)	(Range)	Mean	(SD)	(Range)	Mean	(SD)	(Range)	Mean	(SD)	(Range)
Names	0.36	(0.72)	(0-3)	5.00	(0.99)	(3-6)	5.59	(0.41)	(4.6-6)	5.72	(0.45)	(5-6)
Correct items	0.43	(0.81)	(0-3)	—	—	—	5.60	(0.74)	(3-6)	—	—	—
Incorrect items	0.30	(0.66)	(0-2)	—	—	—	4.0	(<i>n</i> = 1)	—	—	—	—
Faces	2.43	(1.96)	(0-6)	4.06	(1.35)	(0-6)	5.41	(0.66)	(3.6-6)	5.64	(0.79)	(2-6)
Correct items	2.81	(1.95)	(0-6)	4.38	(0.98)	(3-6)	5.56	(0.98)	(1-6)	—	—	—
Incorrect items	0.86	(1.07)	(0-3)	1.50	(1.29)	(0-3)	0.50	(0.7)	(0-2)	—	—	—

Data are familiarity ratings that ranged from 0 (no familiarity at all) to 6 (very familiar). —, subjects were correct on every item of the occupational judgement task; hence, there is no basis for comparison of correct versus incorrect responses. L, left; R, right; SD, standard deviation; ACoA, anterior communicating artery aneurysm rupture and surgical clipping.

but simply to order or indicate recognition. Under these response conditions, several other dissociations emerged. EK performed in or near the normal range in temporal ordering of famous faces (90% correct) and forced choice selection of famous versus nonfamous faces (94% correct), but only at chance levels in temporal ordering (50% correct) and forced choice selection (33% correct) of famous names. DR's temporal ordering responses for famous names and faces were comparable to controls. However, he showed a significant impairment in forced choice face recognition (67% correct) with comparatively better (but still below the normal range) forced choice name recognition (87% correct). SAM demonstrated mild difficulties on these tasks, but still performed with $\geq 90\%$ accuracy.

Occupational Judgment

In multiple-choice occupational judgments of past famous names (presented in full form), EK was severely impaired (44% correct) relative to controls (as well as DR and SAM), although somewhat above chance levels due to her comparatively good classification of recent U.S. presidents' names. A much higher level of occupational judgment for famous faces was evident (80.5% correct), but even this level was below the normal range. DR showed entirely normal occupational judgments for famous names (100% correct), with mild impairment for famous faces (89% correct). SAM's performance levels were all within normal limits.

Familiarity Ratings

Results of familiarity ratings are summarized in Table 2, where we also compared the ratings on correct versus incorrect occupational judgment responses for names and faces. EK's familiarity ratings for famous names was near zero on the 0-6 scale (mean = 0.36) and significantly below normal controls ($p < 0.001$), the other experimental subjects ($p < .001$ in comparison to DR and SAM) and her ratings for famous faces ($p < 0.001$). Her familiarity ratings for correct (mean = 0.43) versus incorrect (mean = 0.30) occupational judgment responses to famous names were not statistically different ($p = 0.58$), but a distinct familiarity difference was indicated for correct (mean = 2.81) versus incorrect (mean = 0.86) face responses ($p < 0.016$). Despite this difference, EK's overall familiarity ratings even to famous faces was below normal control and other experimental subject levels ($p < 0.001$). DR's familiarity ratings were much closer to normal controls on both names and faces, but these were statistically lower ($p < 0.001$) for both series of stimuli. Unlike the other subjects, though, his familiarity ratings to famous faces (mean = 4.06) was significantly lower than to famous names (mean = 5.00) ($p < 0.001$). Despite this difference, he maintained distinct familiarity differences for his correct (mean = 4.38) versus

incorrect (mean = 1.50) face responses. SAM was no different from controls on familiarity ratings.

Discussion

In these studies of retrograde memory in patients with focal limbic system and inferior temporal lobe lesions, the famous name and face stimuli, spanning primarily the past 3 decades, were not presented to elicit autobiographic or episodic memories. The emphasis was on a cognitive approach toward establishing what recognition and unique biographical data from the retrograde memory system were available to these patients. Unlike most object names and pictures, the names and faces of famous persons have a high degree of associative specificity that encompasses interconnected semantic (e.g., name, occupation), visual (e.g., facial, physical characteristics, gender), auditory (e.g., voice), and temporal (e.g., facts and features that change and also can be compared over time epochs) knowledge stores. The organization of this system remains controversial, with some views favoring a distributed, interconnected semantic memory model and others postulating a localized, multimodal model of knowledge storage for specific names and for specific faces. The experimental probes in this study indicated different forms of partial retrograde amnesia that can be attributed to left and right temporal lobe lesions and different roles for these cortical regions in retrograde memory processes. While prior studies have suggested either a right or left temporal lobe role in person identification (e.g., Ellis et al., 1989; Kapur et al., 1994), our data support a model of bilateral temporal processing.

The emphasis on temporal cortical structures is important to clarify. Both EK and DR suffered cerebral damage from herpes simplex encephalitis, which involved in typical fashion a large extent of temporal cortical and subcortical structures, including the temporal pole, amygdala, hippocampus, entorhinal and parahippocampal cortices, medial and lateral occipitotemporal gyri, and anterior portions of the inferior temporal gyrus. As is common, additional damage to the basal forebrain-posterior ventromedial frontal cortex and anterior insula was present in the two subjects, though in asymmetric and minimal fashion. Of these additional structures, only the basal forebrain-posterior ventromedial frontal region has been implicated in memory, usually on the basis of damage from ruptured anterior communicating artery aneurysms. Thus, we included a case with clear amnesia after ruptured aneurysm and found virtually no deficits in the experimental retrograde memory measures (the exception being mild difficulties with temporal ordering judgments). On this basis, the remainder of discussion is focused on temporal lobe structures.

Left Temporal Lobe

Cases EK and DR had contrasting temporal lobe lesions and very different forms of partial retrograde amnesia. EK showed

almost complete loss of spontaneous and cued retrieval, familiarity and knowledge about famous person names, at least to conscious appreciation. This severe defect was evident whether EK was engaged in retrieving famous person names or utilizing such names to evoke associated biographic knowledge in temporal, lexical-semantic, and visual domains. Hence, her impairment is quite different from and much more severe than the naming and name-retrieval difficulties described in other cases (e.g., Damasio and Tranel, 1993; Shallice and Kartsounis, 1993). EK could not spontaneously generate a single person's name from facial pictures or questions, and fared little better with semantic and phonemic cues. Her highest performance level was 17% correct when name stems and facial cues were both presented. This defect was also disproportionately severe in comparison to nonbiographical lexical categories and, hence, is not simply a generic naming or lexical processing impairment. Furthermore, EK was not "agnostic" for proper names, as she correctly classified famous names as male or female with 95% accuracy. Therefore, EK could perceive and discriminate, but not utilize famous person names to make temporal, occupational, and even famous versus nonfamous recognition judgments. Her familiarity ratings for famous person names were extremely low and showed no statistical difference on the few correct responses she offered in the occupational judgment task. In contrast, her handling of facial stimuli was either entirely normal or mildly below the normal range. The latter difficulties were noted on tasks of temporal ordering, occupational judgment, and familiarity ratings of famous faces and ranged close to normal, but cannot be entirely dismissed. It is arguable, as discussed later, that a modest famous face recognition and familiarity defect occurred after her particular location of left temporal lesion, right temporal polar lesion, or a combination of both. Activation of the left temporal region has been reported on famous face recognition tasks in normals undergoing PET study (Sergent et al., 1992; Kapur et al., 1995).

Right Temporal Lobe

In contrast to EK, DR's unilateral lesion to the right inferior and anterior-medial temporal lobe was associated with comparatively milder retrograde memory impairment, primarily in utilization of facial prompts in name stem completion and name:face matching tasks, to forced choice recognition (faces > names) and to occupational judgments of famous faces. This pattern of performance was similar in many respects to case RFR, whose lesion after herpes simplex encephalitis was highly asymmetric, with greater involvement of the right than left inferior and anterior-medial temporal lobe (Warrington and McCarthy, 1988). Recent PET data from normal volunteers and evoked potential recordings in surgical epilepsy patients support an important role for the inferior temporal lobe and occipital-temporal junction in face processing tasks. Common areas of activation included the lateral and medial occipitotemporal gyri as well as more anterior and lateral temporal cortices bilaterally (Sergent et al., 1992, 1993; Haxby et al., 1993; Allison et al., 1994). These areas demonstrated greatest activity during facial identification tasks in comparison to face-gender categorization, famous name recognition, and object categorization tasks. The highest levels of activation during famous face recognition were recorded from the right inferior medial and anterior-medial temporal lobe, but left temporal activation was also observed (Sergent et al., 1992). These data suggest that while there may be hemispheric asymmetry in face recognition, the neural substrate for facial recognition is quite likely bilaterally distributed in the inferior temporal and occipital regions. For example, DR's right temporal lobe lesion did not cause prosopagnosia and based on his preserved cognitive abilities, his lesion can be considered

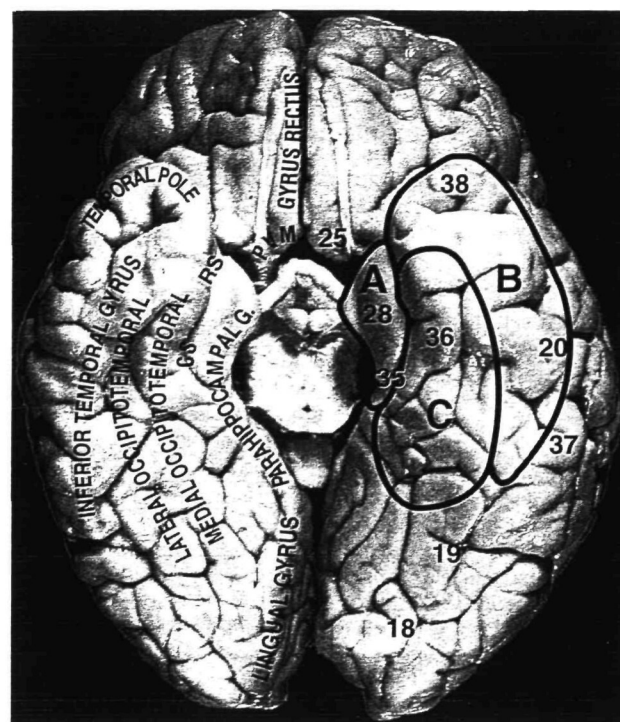


Figure 4. Lines demarcate proposed sectors of the inferior temporal lobe with behavioral relevance to memory processing. A, medial sector. B, polar and anterolateral sector; C, inferior sector of medial and lateral occipitotemporal gyri.

to be less destructive to the network for past famous face knowledge than EK's left temporal lobe lesion was to famous name knowledge. It is important to confirm the relative magnitude of these effects with experimental retrograde memory tasks that are more difficult for normal controls than the current protocol. On more difficult tasks, DR may show a more extensive deficit. Nevertheless, these data would support a model of bilateral but asymmetric neural organization of biographically salient memory in the temporal lobes. Bilateral lesions located more posteriorly than DR's and EK's damage appear to be crucial for isolated loss of access to facial knowledge (Damasio et al., 1982; Ettlin et al., 1992; Sergent et al., 1992). This was confirmed recently in our laboratory through study of patient BT, whose bilateral inferior occipital lobe lesions caused a striking prosopagnosia. While his famous name recognition and knowledge were normal on all of the experimental retrograde memory tests, famous face recognition and familiarity ratings were zero, with chance performance levels under the other conditions. As is common in prosopagnosia, BT's visual memory impairment extended beyond faces to other categories of visually complex stimuli with specific, storied members (e.g., cars, houses, certain animal classes such as cats and dogs). It is possible that DR's partial nonverbal retrograde amnesia also affected these visual categories.

A Model for the Neural Substrate of Famous Name Knowledge

Based upon analysis of EK's lesion, possible anatomic correlates for the severe loss of famous name knowledge include (A) the medial temporal complex, (B) the polar-anterolateral temporal cortices, and (C) the occipitotemporal cortices (see Fig. 4). These correlates are considered, obviously, for the left hemisphere since DR did not show such deficits after comparable, extensive right temporal lobe lesion.

The medial temporal complex, particularly the amygdala,

COMPUTATION AND STORAGE OF PERSON-SPECIFIC KNOWLEDGE
(Cortical-Hippocampal-Limbic)

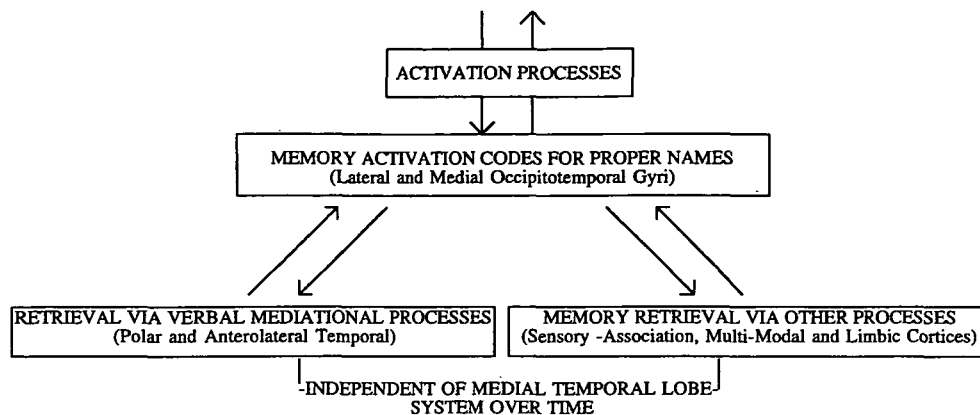


Figure 5. Anatomic-behavioral model of the proposed role for the medial and lateral occipitotemporal gyri in processing of famous name knowledge associated with retrograde memory and in relation to other temporal lobe sectors and various cortices implicated in memory storage and retrieval.

hippocampus, entorhinal cortex, and parahippocampal gyrus, are unlikely neural candidates to account for EK's profound retrograde amnesia for famous names because of the lack of such deficits even after bilateral damage to this complex (Corbin, 1984; Zola-Morgan et al., 1986; Squire, 1987). The human cases available to date, though, do not rule out a role for this region in certain aspects of retrograde memory processes, particularly retrieval of comparatively recent events and information. Recent data from the experimental monkey model supports the eventual independence of retrograde memory from the medial temporal complex as well (Zola-Morgan and Squire, 1990). The polar and anterolateral temporal cortices have been implicated in retrieval of previously acquired knowledge, including personal-episodic and public biographical domains (Terzian and Dalle Ore, 1955; Horel et al., 1984; Kapur et al., 1992; Damasio and Tranel, 1993; Markowitsch et al., 1993). While Kapur et al. (1992) and Markowitsch et al. (1993) have emphasized the role of the temporal polar region in retrieval of remote memory, Damasio and Tranel (1993) have suggested that left anterolateral cortices (Brodmann's areas 21 and 20 in particular) may mediate verbal retrieval processes for nouns that denote discrete visual entities including faces of family members and public figures. From PET study of normal volunteers, Sergent et al. (1993) also report data supporting a specific role for the lateral left temporal lobe in verbal mediation of famous name retrieval. However, EK's retrograde memory impairment extended much beyond name retrieval processes and cannot be attributed to either naming deficiencies or a general semantic memory impairment. She suffered profound loss of the recognition of past famous names which, we propose, precluded activation of associated temporal, semantic and facial knowledge, while such knowledge remained accessible through other (nonverbal) mediational processes such as temporal ordering and forced-choice recognition of famous faces. The notion of a multimodal, distributed knowledge system subserving person identification, accessible through famous names and faces, is suggested by the models of Damasio (1989), Valentine et al. (1991) and Burton and Bruce (1993). An alternative possibility is that the knowledge specifically associated with famous names was selectively damaged in EK and, hence, stored separately from the knowledge associated with famous faces, which remained operational. EK's more extensive deficit may be related to the additional involvement of the left inferior temporal cortices, particularly in the lateral and medial occipitotemporal gyri, which has been damaged in several cases of profound retro-

grade amnesia (Penfield and Mathieson, 1974; Damasio et al., 1985; Eslinger and Cermak, 1988; Schnider et al., 1994).

This prominent region of the inferior temporal lobe (encompassing Brodmann's areas 36, medial 20 and possibly the anterior-medial portions of 37) is located lateral to the parahippocampal gyrus and collateral sulcus but medial to the inferior temporal gyrus. In the older literature the area is known as the fusiform gyrus. It is generally demarcated laterally by the posterior part of the inferior temporal sulcus but lies entirely medial to it (Barr, 1979; Talairach and Tournoux, 1989; Ono et al., 1990; Carpenter, 1991). The connective anatomy and functional correlates of this area are poorly understood, but certain characteristics drawn from its similarity to proximal parahippocampal and inferior temporal cortices (i.e., von Bonin and Bailey's area TF, TH, and TE in the monkey) favor an important role in memory. First, on this basis, the lateral occipitotemporal region would be an area of prosocortex (area TF) that is reciprocally interconnected with the hippocampus and most importantly receives substantial hippocampal output via direct subicular and indirect entorhinal cortex projections (Rosene and Van Hoesen, 1977; Kosel et al., 1982). The medial occipitotemporal gyrus would correspond to area TH and have similar connections. Second, this area is reciprocally interconnected with the temporal polar region and anterolateral temporal cortices (Seltzer and Pandya, 1976; Markowitsch et al., 1985), which have been implicated in certain retrieval processes. Third, this area likely receives and reciprocates projections to sensory-specific and multimodal association cortices (Van Hoesen, 1982; Pandya and Seltzer, 1982). Hence, similar to the posterior parahippocampal gyrus in the monkey, the lateral and medial occipitotemporal gyri in humans may be positioned to be influenced by computations of new experiences from hippocampal processing, by interaction with anterior temporal cortices that have been implicated in verbal retrieval processes, and by multimodal interaction with sensory association and limbic lobe cortices including the frontal lobe, for both storage and retrieval operations (see Fig. 5) (Van Hoesen and Pandya, 1975; Van Hoesen et al., 1975; Seltzer and Pandya, 1976; Van Hoesen, 1982). On the basis of these purported anatomic linkages, this region would be suited to storage of information processed and consolidated by hippocampal-cortical mechanisms and accessible via multimodal channels, eventually becoming independent of the medial temporal complex, as suggested for retrograde memory (Zola-Morgan and Squire, 1990). This hypothesis is consistent with human cases of profound

retrograde amnesia with lesion localization (Penfield and Mathieson, 1974; Damasio et al., 1985; Eslinger and Cermak, 1988; Schnider et al., 1994). In the left hemisphere, such information might include proper names with unique activation codes that impart biographic knowledge bound by temporal-spatial parameters to discrete entities stored in both cerebral hemispheres, such as faces, historical facts, possibly voices, even emotional states and highly salient actions. However, whether such storage is limited to person names and limited to the lateral and medial occipitotemporal gyri or possibly includes more extensive portions of inferolateral temporal cortex (area 20) remains to be determined. Our impression is that EK's defect and the range of processing usually associated with this region extends beyond person names to many other proper name categories, including specific animal, fictional and cartoon characters, monuments, and buildings. Within this model, impaired retrograde memory involving famous name *retrieval* may arise from damage not only to the occipitotemporal region, but also to the various access sites and input pathways that emanate from limbic system and cortical processing areas to this region. However, profound loss of famous name *knowledge* in the absence of aphasia, we propose, is selectively associated with the left occipitotemporal gyri.

Summary

The findings indicate that there are different forms of partial retrograde amnesia associated with asymmetric temporal lobe lesions. Based upon anatomic analysis of the lesion sites, we have proposed that the region of the lateral and medial occipitotemporal gyri may mediate a crucial role in retrograde memory processing, particularly recognition and biographical associations to famous names in the left hemisphere, and to a lesser degree, recognition and biographical associations to famous faces in the right hemisphere. Hence, a model of bilateral access and storage for retrograde memory is supported. Further cognitive and lesion studies of the inferior temporal region in human brain are needed to confirm and elaborate its role in memory, including autobiographic knowledge and other storied entities.

Notes

Special thanks to Claire Flaherty for help in recruiting and testing normal control subjects, Tricia Spitler for careful preparation of the manuscript, Dr. Justine Sergent, and Dr. John Hodges for thoughtful discussion of the findings.

Address correspondence to Paul J. Eslinger, Ph.D., Division of Neurology, Laboratory of Neuropsychology & Cognitive Neuroscience, The Milton S. Hershey Medical Center, 500 University Drive, Hershey, PA 17033.

References

Albert MA, Butters N, Levin JA (1979) Temporal gradients in the retrograde amnesia of patients with alcoholic Korsakoff syndrome. *Arch Neurol* 36:211-216.

Allison T, Ginter H, McCarthy G, Nobre AC, Pace A, Luby M, Spencer DD (1994) Face recognition in human extrastriate cortex. *J Neurophysiol* 71:821-825.

Barr ML (1979) *The Human nervous system*, 3d ed. Hagerstown, MD: Harper & Row.

Barr WB, Goldberg E, Wasserstein J, Novelly R (1990) Retrograde amnesia following unilateral temporal lobectomy. *Neuropsychologia* 28:243-255.

Benton AL (1976) *The Multilingual aphasia examination*. Iowa City: Department of Neurology, The University of Iowa.

Burton AM, Bruce V (1993) Naming faces and naming names: exploring an interactive activation model of person recognition. *Memory* 1:457-480.

Carpenter MB (1991) *Core text of neuroanatomy*, 4th ed. Baltimore, MD: Williams and Wilkins.

Cohen NJ, Squire LR (1981) Retrograde amnesia and remote memory impairment. *Neuropsychologia* 19:337-356.

Corkin S (1984) Lasting consequences of bilateral medial temporal lobectomy: clinical course and experimental findings in H.M. *Semin Neurol* 4:249-259.

Crovitz HF, Schiffman H (1974) Frequency of episodic memories as a function of their age. *Bull Psychonom Soc* 4:517-518.

Damasio AR (1989) The brain binds entities and events by multiregional activation from convergence zones. *Neural Comput* 1:123-132.

Damasio AR, Tranel D (1993) Nouns and verbs are retrieved with differently distributed neural systems. *Proc Natl Acad Sci USA* 90:4957-4960.

Damasio AR, Damasio H, Van Hoesen GW (1982) Prosopagnosia: anatomic basis and behavioral mechanisms. *Neurology* 32:331-341.

Damasio AR, Eslinger PJ, Damasio H, Van Hoesen GW, Cornell S (1985) Multimodal amnesia syndrome following bilateral temporal and basal forebrain damage. *Arch Neurol* 42:252-259.

Damasio H, Damasio AR (1989) *Lesion analysis in neuropsychology*. New York: Oxford UP.

Ellis AW, Young AW, Critchley EMG (1989) Loss of memory for people following temporal lobe damage. *Brain* 112:1469-1483.

Eslinger PJ, Cermak L (1988) Anatomic correlates of retrograde amnesia. *Soc Neurosci Abstr* 14:1289.

Eslinger PJ, Damasio H, Damasio AR, Butters N (1993) Nonverbal amnesia and asymmetric cerebral lesions following encephalitis. *Brain Cognit* 21:140-152.

Ettlin TM, Beckson M, Benson DF, Langfitt JT, Amos EC, Pineda GS (1992) Prosopagnosia: a bihemispheric disorder. *Cortex* 28:129-134.

German DJ (1990) Test of adolescent/adult word finding. Allen, TX: DLM.

Graff-Radford NR, Tranel D, Van Hoesen GW, Brandt JP (1990) Diencephalic amnesia. *Brain* 113:1-25.

Haxby JV, Grady CL, Horwitz B, Salerno J, Ungerleider LG, Mishkin M, Schapiro MB (1993) Dissociation of object and spatial visual processing pathways in human extrastriate cortex. In: *Functional organization of the human visual cortex* (Guyls SB, Ottoson D, Roland PE, eds), pp 329-340. Oxford: Pergamon.

Horel JA, Voytko ML, Salsbury KG (1984) Visual learning suppressed by cooling the temporal pole. *Behav Neurosci* 98:310-324.

Kapur N (1993) Focal retrograde amnesia in neurological diseases: a critical review. *Cortex* 29:217-234.

Kapur N, Ellison D, Smith MP, McLellan DL, Burrows EH (1992) Focal retrograde amnesia following bilateral temporal lobe pathology. *Brain* 115:73-85.

Kapur N, Katifi H, El-Zawawi H, Sedgwick M, Barker S (1994) Transient memory loss for people. *J Neurol Neurosurg Psychiatry* 57:862-864.

Kapur N, Friston KJ, Young A, Frith CD, Frackowiak RSJ (1995) Activation of human hippocampal formation during memory for faces: a PET study. *Cortex* 31:99-108.

Kosel KC, Van Hoesen GW, Rosene DL (1982) Non-hippocampal cortical projections from the entorhinal cortex in the rat and rhesus monkey. *Brain Res* 244:201-213.

Markowitsch HJ, Emmans D, Irle E, Streicher M, Preilowski B (1985) Cortical and subcortical afferent connections of the primate's temporal pole: a study of rhesus monkeys, squirrel monkeys, and marmosets. *J Comp Neurol* 242:425-458.

Markowitsch HJ, Calabrese P, Haupts M, Durwen HF, Liess J, Gehlen W (1993) Searching for the anatomical basis of retrograde amnesia. *J Clin Exp Neuropsychol* 15:947-967.

McCarthy RA, Warrington EK (1992) Actors but not scripts: the dissociation of people and events in retrograde amnesia. *Neuropsychologia* 30:633-644.

Mishkin M, Appenzeller T (1987) The anatomy of memory. *Sci Am* 256:80-89.

Ono M, Kubik S, Abernathy CD (1990) *Atlas of the cerebral sulci*. New York: Thieme.

Pandya DN, Seltzer B (1982) Association areas of the cerebral cortex. *Trends Neurosci* 5:386-390.

Penfield W, Mathieson G (1974) Memory. Autopsy findings and comments on the role of the hippocampus in experiential recall. *Arch Neurol* 31:145-154.

Rosene DL, Van Hoesen GW (1977) Hippocampal efferents reach

- widespread areas of cerebral cortex and amygdala in the rhesus monkey. *Science* 198:315-317.
- Sanders HL, Warrington EK (1975) Retrograde amnesia in organic amnesic patients. *Cortex* 11:397-400.
- Schnider A, Regard M, Landis T (1994) Anterograde and retrograde amnesia following bitemporal infarction. *Behav Neurol* 7:87-92.
- Seltzer B, Pandya DN (1976) Some cortical projections to the parahippocampal area in the rhesus monkey. *Exp Neurol* 50:46-160.
- Sergent J, Ohta S, MacDonald B (1992) Functional neuroanatomy of face and object processing. A positron emission tomography study. *Brain* 115:15-36.
- Sergent J, MacDonald B, Zuck E (1993) Access to stored biographic information from faces and proper names: a PET study. *Soc Neurosci Abstr* 19:1284.
- Shallice T, Kartsounis LD (1993) Selective impairment of retrieving people's names: a category-specific disorder. *Cortex* 29:281-291.
- Sivan AB (1992) Benton visual retention test, 5th ed. San Antonio, TX: Psychological Corporation.
- Squire LR (1987) *Memory and brain*. New York: Oxford UP.
- Squire LR, Zola-Morgan S (1991) The medial temporal lobe memory system. *Science* 253:1380-1386.
- Squire LR, Haist F, Shimamura AP (1989) The neurology of memory: quantitative assessment of retrograde amnesia in two groups of amnesic patients. *J Neurosci* 9:828-839.
- Talairach J, Tournoux P (1988) *Co-planar stereotaxic atlas of the human brain: 3-dimensional proportional system: an approach to cerebral imaging*. Stuttgart: Thieme.
- Terzian H, Dalle Ore G (1955) Syndrome of Kluver-Bucy reproduced in man by bilateral removal of the temporal lobe. *Neurology* 5:373-380.
- Valentine T, Bredart S, Lawson R, Ward G (1991) What's in a name? Access to information from people's names. *Eur J Cognit Psychol* 3:147-176.
- Van Hoesen GW (1982) The parahippocampal gyrus. *Trends Neurosci* 5:345-350.
- Van Hoesen GW, Pandya DN (1975) Some connections of the entorhinal (area 28) and perirhinal (area 35) cortices of the rhesus monkey. I. Temporal lobe afferents. *Brain Res* 95:1-24.
- Van Hoesen GW, Pandya DN, Butters N (1975) Some connections of the entorhinal (area 28) and perirhinal (area 35) cortices of the rhesus monkey. II. Frontal lobe afferents. *Brain Res* 95:25-38.
- von Bonin G, Bailey P (1947) *The neocortex of Macaca mulatta*. Urbana, IL: University of Illinois Press.
- von Cramon DY, Hebel N, Schuri U (1985) A contribution to the anatomical basis of thalamic amnesia. *Brain* 108:993-1008.
- Warrington EK, McCarthy RA (1988) The fractionation of retrograde amnesia. *Brain Cognit* 7:184-200.
- Zola-Morgan SM, Squire LR (1990) The primate hippocampal formation: evidence for a time-limited role in memory storage. *Science* 250:288-290.
- Zola-Morgan S, Squire LR, Amaral DG (1986) Human amnesia and the medial temporal region: enduring memory impairment following a bilateral lesion limited to field CA1 of the hippocampus. *J Neurosci* 6:2950-2967.