

Antiphospholipid Syndrome Associated With Seizures

AARON MILSTONE, MD, ALEXANDER FAN, and HOWARD FUCHS, MD, Nashville, Tenn

ABSTRACT: Antiphospholipid antibodies have been associated with thrombosis, fetal wasting, and thrombocytopenia. We discuss a case of antiphospholipid syndrome with the rarely recognized presentation of generalized tonic-clonic seizure during pregnancy. This case emphasizes the need for evaluation of possible hypercoagulable states in young adults with cerebrovascular events or newly diagnosed seizures.

AUTOANTIBODIES found in the antiphospholipid syndrome may have specificity for cardiolipin or interfere with *in vitro* coagulation. Anticardiolipin antibodies (aCLs) can be measured directly by quantitative assay; lupus anticoagulant (LA) must be detected indirectly by prolonged partial thromboplastin time (PTT), kaolin clotting time, or Russell's viper venom test (RVVT). Lupus anticoagulant and aCLs bind negatively charged or neutral phospholipids¹; they have been found in patients with and without associated autoimmune disease, most notably with systemic lupus erythematosus.² These polyclonal antibodies have become a subject of interest in the medical literature because their presence has been associated with increased risk of vascular occlusion.

Antiphospholipid syndrome is commonly associated with arterial or venous thrombosis, cardiac valvular abnormalities, fetal wasting, thrombocytopenia, or cerebrovascular events.³ One report also proposed an association between the presence of LA and late-onset seizures.⁴ Our case shows a link between seizures, cerebral infarction, and LA.

CASE REPORT

A 32-year-old woman came to a local hospital with her first generalized tonic-clonic seizure at 36 weeks of pregnancy. Her medical history was significant for migraines and two spontaneous first-trimester abortions. She denied diabetes mellitus, hypertension, or smoking. There were no focal neurologic findings or signs of embolic phenomena on physical examination. Initial laboratory data revealed a hematocrit of 41%, platelet count of 381,000, a prothrombin time of 12 seconds, and a partial thromboplastin time of 26 seconds. Noncontrasted computed tomography of the head showed a focal area of hemor-

rhage in the left frontal centrum semiovale (Fig 1), initially thought to be due to an arteriovenous malformation. A healthy child was delivered by emergency cesarean section. The patient was started on phenobarbital and, later, phenytoin for seizure control, but therapeutic levels of antiepileptic medications failed to suppress the seizures.

One week later the patient was referred to Vanderbilt University Medical Center for further evaluation of her condition. A cerebral arteriogram showed no evidence for the suspected arteriovenous malformation but did show multiple filling defects within the right middle cerebral arterial branches and total occlusion of the temporal occipital artery. There was also a filling defect within a major transitional branch of the middle cerebral artery in the rolandic area (Fig 2). The left middle cerebral artery and anterior cerebral vasculature were unaffected.

Results of an electroencephalogram were nonfocal. A transesophageal echocardiogram showed no thrombi, vegetations, or right-to-left shunts. Laboratory test results included the following: a negative antinuclear antibody

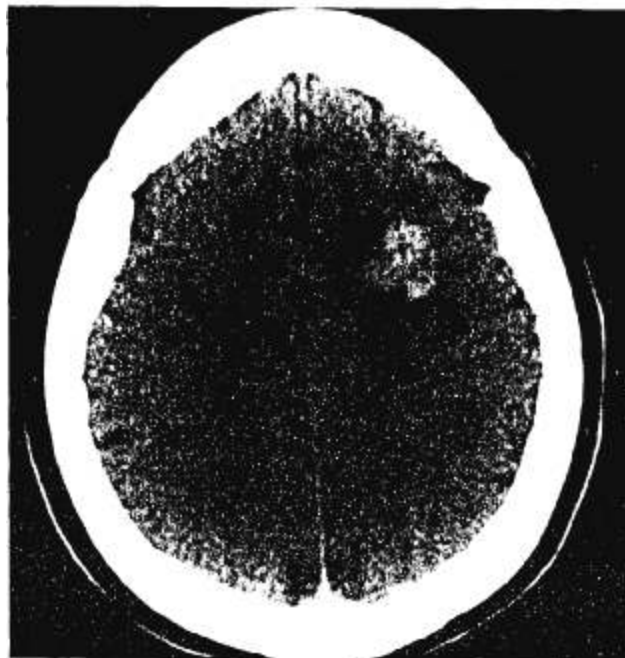


FIGURE 1. Noncontrasted computed tomography shows focal hemorrhage in left frontal centrum semiovale.

From the Department of Internal Medicine, Vanderbilt University Medical Center, Nashville, Tenn.

Reprint requests to Aaron Milstone, MD, B-512 The Vanderbilt Clinic, Vanderbilt University Medical Center, Nashville, TN 37232.

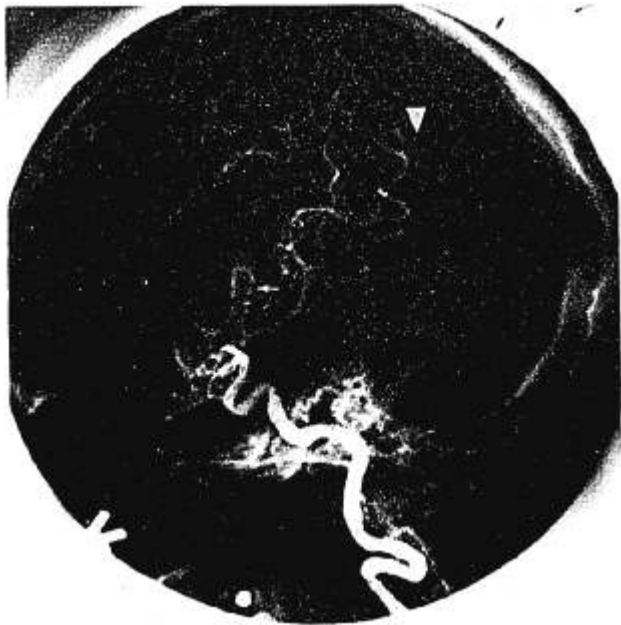

FIGURE 2. Cerebral arteriogram shows total occlusion of the temporal occipital artery (arrowhead) and thrombus in transitional branch of middle cerebral artery (arrow).

titer, nonreactive rapid plasma reagin, and normal protein C and S activity. Antithrombin III activity was normal. Dilute thromboplastin time was 1.2 seconds (normal). Anticardiolipin antibody IgG and IgM levels were 4.1 GPL (normal, 0 to 23) and 4.3 MPL (normal, 0 to 11), respectively. RVVT time was 1.8 seconds (normal, 0.8 to 1.2 seconds). In view of the medical history, angiographic findings, and abnormal RVVT result, a diagnosis of antiphospholipid syndrome was made. In spite of a small episode of acute cerebral bleeding, anticoagulation with warfarin sodium (Coumadin) was initiated to prevent further thrombosis. Anticonvulsants were gradually discontinued, and no further seizure activity has occurred.

DISCUSSION

Neurologic manifestations of antiphospholipid syndrome that are well recognized include migraine headaches, amaurosis fugax, chorea, and stroke. Stroke is often the initial manifestation and is the best described. Echocardiographic evidence⁵ of mitral valvular lesions, mitral valve prolapse, mitral regurgitation, and aortic valvular abnormalities has been implicated as sources for cerebrovascular events. However, many patients show no evidence of cardiac pathology following cerebrovascular events, suggesting the role of in situ thrombosis as a causative mechanism. In the Antiphospholipid Antibodies in Stroke Study Group (APASS),⁶ angiography was done in 49 of 128 patients. Half of those studied had intracranial lesions; middle cerebral artery occlusions were the most common. Arterial ischemic events were responsible for most strokes, with hemorrhage being distinctly

uncommon. In this patient, a hemorrhagic infarction was most likely due to necrosis after an intravascular thrombus.

Seizure has rarely been recognized as the initial symptom of antiphospholipid syndrome^{4,6,7} and was not reported in the APASS. The initial report linking antiphospholipid antibodies to seizures showed the presence of LA (but not aCLs) in patients with late-onset seizures.⁴ Subsequent reports have shown that LA has a stronger link to thrombotic events than do aCLs.^{8,9} Our patient had seizures as the first manifestation of antiphospholipid syndrome, presumably due to intracranial in situ thrombosis. The diagnosis was confirmed by angiography and the presence of LA as detected with prolonged RVVT time despite a normal PTT. It is possible that the patient's normal PTT was due in part to increased clotting factor levels associated with pregnancy.⁹

The incidence of stroke in young adults is estimated to be 62 per 100,000,¹⁰ with one study showing that 27% are idiopathic strokes and 31% are embolic.¹¹ It is possible that antiphospholipid syndrome is one underlying cause of idiopathic or embolic cerebrovascular accidents in this population. Our case underscores the need to evaluate the presence of antiphospholipid antibodies in young adults with cerebral events. Furthermore, this case raises the question of whether the presence of LA and aCLs ought to be evaluated in young adults with newly diagnosed seizures. One study has shown that cerebrovascular events account for 14% of all late-onset seizures, with another 38% having no detectable underlying cause.¹² Again, are antiphospholipid antibodies an underlying cause of seizures in this age group?

This case provides evidence for a link between cerebrovascular events, seizures, and the presence of the lupus anticoagulant. Given that cerebrovascular events commonly cause seizures, it is important that hypercoagulable states be considered in young adults with newly diagnosed seizures or strokes. Newer assays for detecting antiphospholipid antibodies allow us to investigate further their role in strokes and seizures, as well as therapeutic implications.

References

1. Levine SR, Deegan MJ, Futrell N, et al: Cerebrovascular and neurologic disease associated with antiphospholipid antibodies: 49 cases. *Neurology* 1990; 40:1181-1189
2. Babikian VL, Levine SR: Therapeutic considerations for stroke patients with antiphospholipid antibodies. *Stroke* 1992; 23(suppl): 133-136

3. Hess D: Stroke associated with antiphospholipid antibodies. *Stroke* 1992; 23(suppl): 123-128
 4. Inzelberg R, Korczyn AD: Lupus anticoagulant and late onset seizures. *Acta Neurol Scand* 1989; 79:114-118
 5. Chartash EK, Lans DM, Paget SA, et al: Aortic insufficiency and mitral regurgitation in patients with systemic lupus erythematosus and the antiphospholipid syndrome. *Am J Med* 1989; 86:407-412
 6. Antiphospholipid Antibodies in Stroke Study Group (APASS). *Stroke* 1990; 21:1268-1273
 7. Muraoka I, Adachi N, Ogashiwa M, et al: Cerebral hemorrhage in a case of antiphospholipid antibody syndrome. *Brain and Nerve* 1993; 45:263-266
 8. Ghirardello A: Antiphospholipid antibodies (aPL) in systemic lupus erythematosus. Are they specific tools for the diagnosis of aPL syndrome? *Ann Rheum Dis* 1994; 54:140-142
 9. Petri M: Diagnosis of antiphospholipid antibodies. *Rheum Dis Clin North Am* 1994; 20:443-469
 10. Schoenberg BS, Whisnant JP, Taylor WF, et al: Strokes in women of childbearing age: a population study. *Neurology* 1970; 20:187-189
 11. Hart RG, Miller VT: Cerebral infarction in young adults: a practical approach. *Stroke* 1983; 14:110-114
 12. Dam AM: Late-onset epilepsy: etiologies, types of seizure, and value of clinical investigation, EEG, and computerized tomography scan. *Epilepsia* 1985; 26:227-231
-