

Case Report

Cerebral Ischemia After Venous Air Embolism in the Absence of Intracardiac Defects

Concezione Tommasino, Roberto Rizzardi, Luigi Beretta, Marco Venturino, and
Susanna Piccoli

University of Milano, Institute of Anesthesia and Intensive Care, Scientific Institute H San Raffaele, Milano, Italy

Summary: Cerebral air embolism occurred in a patient undergoing posterior fossa surgery performed in the sitting position for acoustic neuroma removal. The patient experienced two episodes of venous air embolism, as evidenced by precordial Doppler, end-tidal carbon dioxide reduction, and oxygen desaturation. In both cases, air was aspirated from the central venous catheter; during the second episode there was arterial hypotension and electrocardiogram changes, and air bubbles were visualized in the cerebellar arteries. The patient did not regain consciousness after surgery and developed early tonic-clonic convulsions and electroencephalogram status epilepticus, which was treated with barbiturate coma. Intracardiac septal defects were not detected by transesophageal echocardiography, and computerized tomography of the brain demonstrated multifocal discrete ischemic areas in the cerebral hemispheres. The patient died 6 days after surgery without having regained consciousness. This case appears to represent the occurrence of transpulmonary passage of venous air embolism. **Key Words:** Complication—Cerebral ischemia—Embolism—Venous air embolism.

One of the hazards of neurosurgical procedures in the sitting position is venous air embolism (VAE) (1). When the embolus is large, venous air causes pulmonary insufficiency and/or cardiovascular alterations. In only very few cases do systemic embolization and organ injury occur, usually due to the presence of a patent foramen ovale or to an atrial septal defect (paradoxical air embolism) (2-5).

We report a case of multifocal cerebral ischemia subsequent to VAE that occurred during an upright neurosurgical procedure in a patient in whom no

evidence of any intracardiac defect could be detected.

CASE REPORT

A 63-year-old white man was scheduled for elective surgical removal of a left acoustic neuroma in the sitting position. Neurological examination revealed left hypoacusia and hypoesthesia in the territory of the left ophthalmic and maxillary nerves. Preoperative biochemical and hematological profiles, electrocardiogram, and chest x-ray films were all unremarkable.

Before induction of anesthesia, a central venous catheter was inserted via the right internal jugular

Address correspondence and reprint requests to Dr. Concezione Tommasino, Anesthesiology, H San Raffaele, Via Olgettina, 60, 20132 Milan, Italy.

vein for fluid administration and air removal. The position of the tip within the right atrium was confirmed, in the final sitting position, on chest x-ray film. Intraoperative monitoring included electrocardiogram (ECG), blood pressure monitoring via intraarterial catheter zeroed at the external auditory meatus and noninvasive sphygmomanometer, precordial Doppler (TC2-64B, EME, Germany) (6), end-tidal carbon dioxide (ETCO₂), SpO₂, end-tidal volatile anesthetic agent, arterial blood gases (ABGs), rectal temperature, and urine output. Anesthesia was induced with fentanyl (0.01 mg) and thiopental (4 mg/kg) and was maintained with isoflurane (0.4–1% end tidal) in oxygen:air (FiO₂ = 0.45), and boluses administration of fentanyl (0.75 mg, total dosage). Muscle relaxation was induced and maintained with pancuronium bromide. The peripheral SpO₂ was 98% or higher, and the ETCO₂ was 30–32 mm Hg. Thirty minutes after induction of anesthesia, basal ABG monitoring showed pH at 7.48, P_aCO₂ at 34 mm Hg, and P_aO₂ at 218 mm Hg.

During surgery there were two episodes of VAE. The first occurred during the muscular dissection, and it was detected by a change in the precordial Doppler, ETCO₂ reduction from 30 to 20 mm Hg, oxygen desaturation (SpO₂ from 100 to 92%), and moderate systemic hypotension; systolic blood pressure (BP) decreased from 120 to 76 mm Hg (lowest recorded value). This VAE resolved promptly, and there were no changes in the ECG during this episode. Air was aspirated through the atrial catheter (~7 cc air), and the subsequent ABG showed pH at 7.39, P_aCO₂ at 40 mm Hg, and P_aO₂ at 172 mm Hg (FiO₂ = 1).

The second episode of VAE occurred after accidental opening of the transverse sinus; it was confirmed by the precordial Doppler, ETCO₂ reduction from 30 to 15 mm Hg, oxygen desaturation (from 98 to 90%), and severe hypotension; systolic BP decreased from 110 to a low of 54 mm Hg. Phenylephrine was administered, and systolic BP remained <60 mm Hg for <10 min. Air was aspirated through the atrial catheter (~15 cc air), and the subsequent ABG showed pH at 7.34, P_aCO₂ at 46 mm Hg, and P_aO₂ at 265 (FiO₂ = 1). The arterial BP gradually returned to the level prior to the VAE episode. The ECG showed alterations of the S-T segment that lasted almost 30 min. After the second VAE episode (as well as in the 24 h following surgery) laboratory tests performed for serum electrolytes

(Na⁺, K⁺, Ca²⁺) and CPK were in the normal range. During the second VAE episode, air bubbles were visualized in the cerebellar arteries.

In the recovery room, the patient did not awaken from anesthesia, and he was transferred to our neurosurgical intensive care unit (NICU). The patient was comatose, his pupils were small and equally reactive to light, and neurologic examination revealed abnormal flexion to painful stimuli. The P_aO₂ was 81 mm Hg at an FiO₂ of 0.6, and the patient's lungs were ventilated in the assisted mode with a positive end-expiratory pressure (PEEP) level of 7 cm H₂O. Computed tomography (CT) brain scan performed soon after the surgical procedure revealed pneumocephalus. On the same day, the patient underwent transesophageal bidimensional echocardiography (2-D TEE, Sonos 1000; Hewlett Packard) with contrast; 10 ml of agitated saline with microbubbles was injected through the right atrial catheter during continuous 2-D TEE visualization of the cardiac chambers. The examinations were performed at zero end-expiratory pressure and twice at a PEEP level of 10 cm H₂O. The injection was performed just before the release of PEEP. This study did not demonstrate a patent foramen ovale, interatrial septal defects, or right-to-left shunt on color Doppler imaging.

The remainder of the patient's hospital course was characterized by tonic-clonic convulsions with electroencephalogram (EEG) status epilepticus, which occurred the day of surgery. Control of the seizure activity was achieved only after general anesthetic levels of barbiturate (barbiturate coma) were achieved. Sensory evoked potentials performed 1 day after surgery revealed normal brain stem auditory evoked potentials (BAEPs) on the right side and absent BAEPs on the left side (left acoustic neuroma). Somatosensory evoked potentials with stimulation of the median nerve at the wrist revealed no peripheral or cortical response to right-sided stimulation. There was a small nonreproducible cortical response to stimulation on the left.

A CT brain scan performed 3 days after surgery demonstrated bilateral, multifocal ischemic areas of recent origin and of variable sizes at the cortical and subcortical levels (Fig. 1). The patient died 6 days after the neurosurgical procedure without having regained consciousness. Autopsy was not performed.

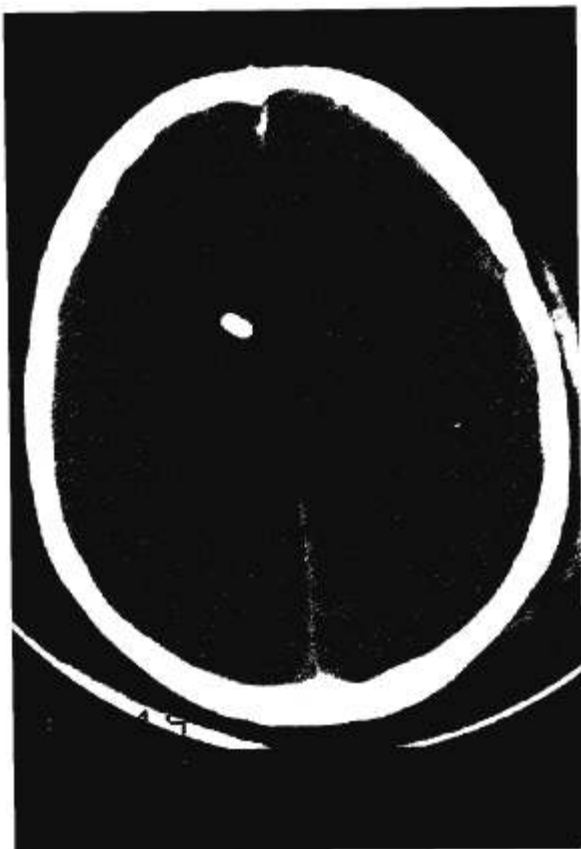


FIG. 1. CT brain scan taken 3 days after the surgical procedure shows bilateral multifocal ischemic areas.

DISCUSSION

Cerebral emboli subsequent to venous air embolism in the sitting position are relatively rare (7), and in the majority of the cases, the cerebral emboli reported in the literature are of paradoxical origin (2–5). In patients with no obvious congenital cardiac defect, the passage of embolized air from right to left circulation generally occurs through a patent foramen ovale; in such cases, the estimated risk of paradoxical air embolism in the sitting position is 6–12% (4,7,8). Detection of intracardiac septal defects is possible by transesophageal two-dimensional contrast echocardiography, which can also be helpful in selecting the neurosurgical operative position with a lower incidence of venous air embolism (8,9).

The patient described in this case report experienced a paradoxical air embolus since air was seen in the cerebellar arteries, but he had no evidence of

atrial septal defect, patency of the foramen ovale, or right-to-left shunt as evaluated by 2-D TEE. Although we cannot exclude the presence of a very small patent foramen ovale, which can occur when right-sided circulatory pressure increases (8,10), the 2-D TEE study, performed under conditions meant to simulate VAE occurrence (10), did not evidence the presence of right-to-left shunt.

In the absence of intracardiac defects permitting right-to-left shunting, the other possible explanation for VAE is that the air in the venous system crossed to the systemic circulation through the pulmonary vascular bed, via physiologic arteriovenous anastomoses or through the filtering capability of the lung (11–13).

Under normal conditions, the lungs are an important physiologic filter for venous air emboli. Some factors, however, might compromise the capability of the lungs to trap venous bubbles, including large volumes of venous air, the use of vasodilators, and anesthetic agents (13–18). When the total volume of venous air infused is large, the filter capability of the lung is impaired and transpulmonary passage of venous air emboli occurs (13,14,17).

Butler and Hills demonstrated in dogs that when air infusion is increased to 0.4 ml/kg/min, transpulmonary passage of air emboli occur in 71% of animals (13). However, the threshold doses for the transpulmonary passage of bolus injection of air into the pulmonary artery in the dog can be as small as 0.05 ml/kg (15,18). The bubble breakthrough phenomenon may involve a degree of species specificity (17), and although the occurrence of cerebral air embolism via the pulmonary vasculature is controversial (19), cerebral air embolism has been reported in patients with no intracardiac defects at autopsy (20–22). Direct documentation of transpulmonary passage of air in humans is lacking; however, a recent case report demonstrated that this phenomenon can indeed occur. In a patient operated on in the sitting position and with no evidence of intracardiac right-to-left shunt, intraoperative 2D-TEE clearly documented the occurrence of transpulmonary passage of venous air embolism (23).

Pulmonary vasodilators can enhance transpulmonary passage of air (13), and the filtering capacity of the lungs is impaired by volatile anesthetics (16). In a dog model during halothane-induced anesthesia, the threshold for transpulmonary passage of air was

lower than with i.v. anesthetic agents (15,18). The mechanisms by which anesthetics influence the threshold for transpulmonary passage of air are unknown, but passage may be mediated through effects on pulmonary blood flow at the level of arterioles, shunt vessels, or capillaries. Volatile anesthetic agents have a pulmonary vasodilating effect (24), and the possibility that they can enhance the transpulmonary passage of air in humans is a matter of interest (25), especially because this phenomenon has been reported in experimental settings (15,18). In our patient, the use of isoflurane and/or the episodes of intraoperative hypotension could have played a role in enhancing transpulmonary passage of venous air.

The ischemic areas on the CT brain scan were not mainly localized at the level of watershed zones, and the intraoperative short-lasting systemic hypotension subsequent to the VAE episodes seems unlikely to be totally responsible for the occurrence of the cerebral ischemia, although it could have worsened it. With the patient in the sitting position, air crossing to the systemic arterial circulation migrates up to the carotid and vertebral arteries and to the cerebral-cerebellar hemispheres; in our case this was confirmed by visualization of air bubbles in the cerebellar arteries. The air bubbles in the arteries produce an immediate but transient block, which is responsible for the ischemic damage. The localization of the air emboli and the extent of the cerebral ischemia determine the degree of neurological deficit. Distribution of cerebral air emboli is more common at the level of supratentorial structures, and the neurologic condition of the patient (postoperative coma and status epilepticus) and the tomographic appearance of the ischemic areas in the brain likely confirm such a distribution.

The passage of air from the venous to the arterial circulation, regardless of the pathway involved, must be considered a serious intraoperative event. Clinicians should attempt all necessary maneuvers to reduce the complications from the VAE. Intraoperatively, the anesthesiologist should support the cardiovascular system so that the ischemic injury can be reduced and/or avoided, and the surgeon should flood the field with saline to submerge the area of air entry. Jugular pressure of the anterior neck can be applied, assuring carotid flow. In the postoperative period in the presence of focal or generalized neurologic deficits, the patient should be

considered at risk of cerebral ischemia and adequately treated.

In conclusion, the present case illustrates the occurrence of cerebral emboli subsequent to severe episodes of venous air embolism in a patient operated on in the sitting position. The patient did not have intracardiac defects on bidimensional transesophageal contrast echocardiography. He failed to emerge from anesthesia. In the absence of right-to-left shunting at the atrial level, we speculate that the cerebral emboli were due to transpulmonary movement of VAE into the left side of the heart.

REFERENCES

1. Michenfelder JD, Miller RH, Gronert GA. Evaluation of an ultrasonic device (Doppler) for the diagnosis of venous air embolism. *Anesthesiology* 1972;36:164-7.
2. Buckland RW, Manners JM. Venous air embolism during neurosurgery: a comparison of various methods of detection in man. *Anaesthesia* 1976;31:633-43.
3. Root B, Levy MN, Pollack S, Mortimer L, Kalindi P. Gas embolism death after laparoscopy delayed by "trapping" in portal circulation. *Anesth Analg* 1978;57:232-7.
4. Gronert GA, Messick JM, Cucchiara RF, Michenfelder JA. Paradoxical air embolism from a patent foramen ovale. *Anesthesiology* 1979;50:548-9.
5. Liu S, Holley HH, Stulberg SD, Cohen B. Failure to awaken after general anaesthesia secondary to paradoxical venous embolus. *Can J Anaesth* 1991;38:335-7.
6. Tommasino C, Beretta L, Dell'Acqua A, Rizzardi R, Ferrari da Passano C. Doppler transcranico per il monitoraggio dell'embolia gassosa negli interventi neurochirurgici in posizione seduta. *Minerva Anestesiol* 1992;58:1311-4.
7. Matjasko J, Petrozza P, Cohen M, Steinberg P. Anesthesia and surgery in the seated position: analysis of 554 cases. *Neurosurgery* 1985;17:695-702.
8. Cucchiara RF, Seward JB, Nishimura RA, Nugent M, Faust RJ. Identification of patent foramen ovale during sitting position craniotomy by transesophageal echocardiography with positive airway pressure. *Anesthesiology* 1985;63:107-9.
9. Guggiari M, Lechat Ph, Garen-Colonne C, Fusciardi J, Viars P. Early detection of patent foramen ovale by two-dimensional contrast echocardiography for prevention of paradoxical air embolism during sitting position. *Anesth Analg* 1988;67:192-4.
10. Cucchiara RF, Nishimura RA, Black S. Failure of preoperative echo testing to prevent paradoxical air embolism: report of two cases. *Anesthesiology* 1989;71:604-7.
11. Emerson LV, Hempleman HV, Lentle RG. The passage of gaseous emboli through the pulmonary circulation. *Resp Physiol* 1967;3:213-9.
12. Baskin SE, Wozniak RF. Air embolism occurring during hemodialysis. *N Engl J Med* 1975;293:184-5.
13. Butler BD, Hills BA. The lung as a filter for microbubbles. *J Appl Physiol* 1979;47:537-43.
14. Butler BD, Hills BA. Transpulmonary passage of venous air emboli. *J Appl Physiol* 1985;59:543-7.
15. Yahagi N, Furuya H. The effects of halothane and pento-

- barbital on the threshold of transpulmonary passage of venous air emboli in dogs. *Anesthesiology* 1987;67:905-9.
16. Katz J, Leiman BC, Butler BD. Effects of inhalational anaesthetics on filtration of venous gas emboli by the pulmonary vasculature. *Br J Anaesth* 1988;61:200-5.
 17. Vik A, Brubakk AO, Hennessy TR, Jenssen BM, Ekker M, Slordahl SA. Venous air embolism in swine: transport of gas bubbles through the pulmonary circulation. *J Appl Physiol* 1990;69:237-44.
 18. Yahagi N, Furuya H, Sai Y, Amakata Y. Effect of halothane, fentanyl, and ketamine on the threshold for transpulmonary passage of venous air emboli in dogs. *Anesth Analg* 1992;75:720-3.
 19. Black S, Cucchiara RF, Nishimura RA, Michenfelder JD. Parameters affecting the occurrence of paradoxical air embolism. *Anesthesiology* 1989;71:235-41.
 20. Marquez J, Sladen A, Gendell H, Boehnke M, Mendelow H. Paradoxical cerebral air embolism without an intracardiac septal defect. *J Neurosurg* 1981;55:997-1000.
 21. Ahmat KP, Riley RH, Sims C, House AK, Cooke OT. Fatal air embolism following anesthesia for insertion of a peritoneovenous shunt. *Anesthesiology* 1989;70:702-4.
 22. Albin MS, Ritter RR, Pruett CE, Kalff K. Venous air embolism during lumbar laminectomy in the prone position: report of three cases. *Anesth Analg* 1991;73:346-9.
 23. Bedell EA, Berge Kh, Losasso TJ. Paradoxical air embolism during venous air embolism: transesophageal echocardiographic evidence of transpulmonary air passage. *Anesthesiology* 1994;80:947-50.
 24. Mathers J, Benumof J, Wahrenbrock EA. General anesthetics and regional hypoxic pulmonary vasoconstriction. *Anesthesiology* 1977;46:111-4.
 25. Drummond JC. Of venous air embolism, aminophylline, and volatile agents [Letter]. *Anesthesiology* 1984;60:389.