

AFTERIMAGES, JONATHAN WIRTSCHAFTER, EDITOR

Ocular Ischemic Syndrome in a Child With Moyamoya Disease and Neurofibromatosis

JANET L. BARRALL, MD,¹ AND C. GAIL SUMMERS, MD^{1,2}

Departments of ¹Ophthalmology and ²Pediatrics, University of Minnesota, Minneapolis, Minnesota, USA

Abstract. Ocular ischemic syndrome is extremely rare in childhood. Patients with moyamoya disease may be particularly susceptible to the development of ocular ischemia due to the associated carotid occlusion. A 19-month-old boy presented with neurofibromatosis and signs of ocular ischemia. At 29 months of age, he developed dense right vitreous hemorrhage and eventually lost vision in that eye due to phthisis. At almost six years of age, he developed an acute hemiplegia and was then diagnosed with moyamoya disease. This rare instance of childhood ocular ischemia in conjunction with moyamoya disease and neurofibromatosis demonstrates the serious ocular and systemic sequelae of occlusive vascular disease. (*Surv Ophthalmol* 40:500-504, 1996)

Key words. angiography • magnetic resonance imaging • moyamoya disease • neurofibromatosis • ocular ischemic syndrome

Ocular ischemic syndrome (OIS) usually occurs in elderly patients with carotid obstruction and significant systemic illness, most frequently hypertension, diabetes mellitus, or cardiac disease.¹⁸ Ocular ischemic syndrome is unusual in childhood, presumably because carotid obstruction rarely occurs in young patients.

Moyamoya disease, an idiopathic vascular disorder of the central nervous system in children and young adults, can occur following carotid obstruction. Neurofibromatosis has been reported in association with moyamoya disease. We present the unusual case of a child with neurofibromatosis who developed both moyamoya disease and ocular ischemia. The occurrence of ocular ischemic syndrome in a child is unexpected, and therefore may go unrecognized.

Case Report

A 19-month-old boy with a presumed diagnosis of neurofibromatosis type 1, based on seven cafe-au-lait spots greater than 1.5 cm in diameter, 13 cafe-au-lait spots less than 1.5 cm in diameter, and

axillary freckling, was referred to our institution for ophthalmologic examination in 1987. There was no history of strabismus or reduced vision. Family history was negative for the findings of neurofibromatosis. The left eye was normal. Neither eye had lens opacities or Lisch nodules of the iris. The right eye contained a combined hamartoma of the retina and retinal pigment epithelium, involving the macula. Neovascularization of the optic disk was noted, in addition to arteriovenous communications, marked venous dilatation, venous beading, and severe arteriolar attenuation (Fig. 1). The retinal periphery was incompletely vascularized and new vessels extended into the vitreous. A small amount of vitreous hemorrhage was present inferiorly. The etiology of the retinal changes was unknown. Computed tomography (CT) and magnetic resonance imaging (MRI) were notable for non-visualization of the right internal carotid artery (Fig. 2). The right carotid artery was presumed to be absent. The optic nerves were also slightly enlarged and have remained unchanged without treatment.

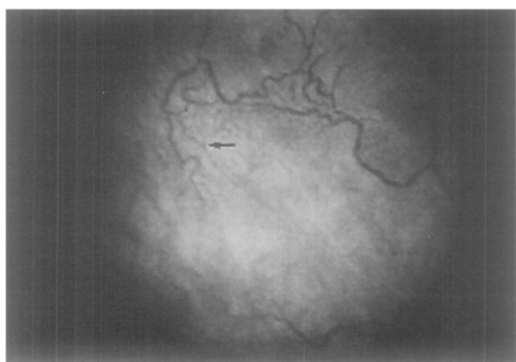


Fig. 1. Photograph of mid-peripheral retina shows venous dilation, venous caliber irregularity, severe arteriolar narrowing and arteriovenous communication (arrow).

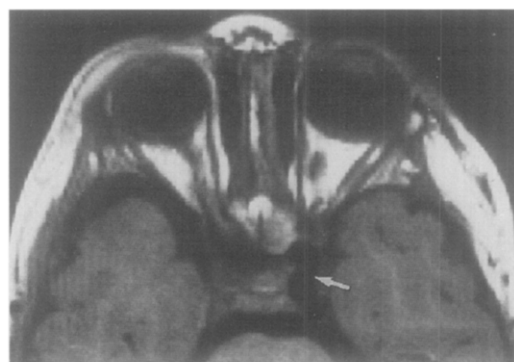


Fig. 2. Magnetic resonance imaging shows nonvisualization of the right internal carotid artery and a patent left internal carotid artery (arrow).

At 29 months, grating visual acuity was 20/100 in the right eye and 20/80 in the left. Due to the potential for amblyopia related to the right macular hamartoma, the left eye had been patched for three hours each day with good compliance. A right esotropia was first noted at 34 months of age. The patient, who had previously cooperated with patching, now objected strongly to occlusion of the left eye, and there was no central fixation with the right eye. Dense vitreous hemorrhage was present, and the retina was attached by B-scan ultrasonography. A vitrectomy was performed due to the potential for amblyopia from the hemorrhage. Additionally, cryotherapy, air-fluid gas exchange, and scleral buckling were used to treat a peripheral inferior retinal break that was noted intraoperatively. Best postoperative vision was light perception. A cyclitic membrane with hypotony rapidly developed, followed by retinal detachment, and phthi-

sis. The child is now nine years old, and the left eye has remained normal.

At almost six years of age, the patient suffered an acute left hemiplegia. A diagnosis of moyamoya disease was made when angiography demonstrated right carotid occlusion and moyamoya vessels (Figs. 3 and 4). Review of the CT scan performed at 19 months showed a right carotid foramen (Fig. 5), suggesting that the carotid artery had developed, but was occluded.¹⁶ A right myodural synangiosis was performed in an attempt to re-establish perfusion of the right cerebral hemisphere. Six months later, cerebral angiography disclosed a patent bypass from the right external carotid artery into the right middle cerebral artery. Three years later, the patients' strength in his left extremities had improved by 50%. Gait remained abnormal due to a left foot drop.

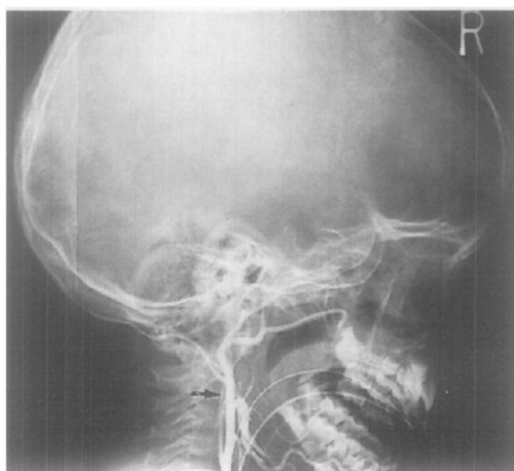


Fig. 3. Carotid angiography demonstrates extremely attenuated proximal right internal carotid occlusion (arrow) and absence of distal perfusion.

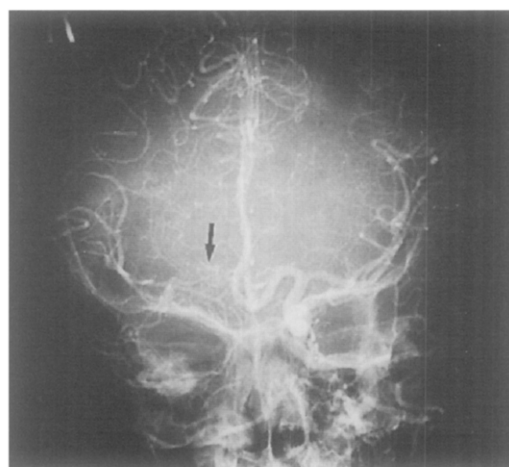


Fig. 4. Carotid angiography demonstrates a patent left internal carotid artery and the smaller abnormal moyamoya vessels on the right (arrow).

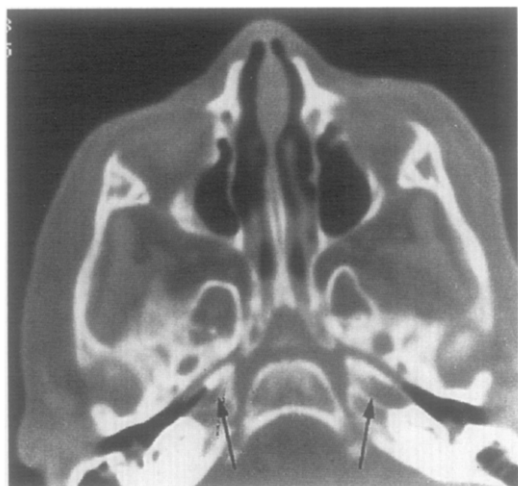

Fig. 5. Computed tomography shows the development of bilateral carotid foramina (arrows).

Discussion

In 1963 Kearns and Hollenhorst reported a series of patients with "venous stasis retinopathy" associated with carotid stenosis.⁹ In the same year, Hedges also described retinal venous changes associated with carotid occlusion.⁷ Knox reported cases of "ischemic ocular inflammation" in conjunction with carotid disease;¹⁰ many of these patients also exhibited the retinal features described by Kearns and Hollenhorst. Smith had already described the occurrence of neovascular glaucoma in the setting of carotid occlusive disease.²¹ Today, the term "ocular ischemic syndrome" is used to encompass these many manifestations that result from chronic insufficiency of carotid or ophthalmic artery flow.

Panocular ischemia can cause pain and decreased vision, and myriad clinical signs.^{8,22,24} Anterior segment signs include episcleral venous congestion, corneal edema, uveitis, abnormally low intraocular pressure, rubeosis iridis, neovascular glaucoma, and cataract. Pupils may be dilated, sluggish, or nonreactive. Posterior segment signs include narrowed arterioles, dilated and irregular veins, neovascularization of the disk and/or retina, arteriovenous communications (anastomoses), retinal hemorrhages, cotton-wool spots, spontaneous retinal arterial pulsations, and vitreous hemorrhage, presumably from neovascularization. Ophthalmodynamometry frequently reveals abnormally low central retinal artery perfusion pressure. Fluorescein angiography shows delayed and patchy choroidal filling, and an increase in arteriovenous transit time.² Retinal blood vessels may stain, and the optic disk may also show late staining. Areas of

retinal capillary nonperfusion can frequently be identified.

OIS typically occurs in older patients. In a series of 43 patients, age at presentation ranged from 50–86 years, with a mean of 64.5 years.² A male predominance was reported, with a male to female ratio of 2:1. Associated systemic diseases, in decreasing order of frequency, included systemic arterial hypertension, diabetes mellitus, ischemic heart disease, cerebrovascular accident, and peripheral vascular disease, all of which are diseases associated with atherosclerosis.¹⁹ The ocular ischemic syndrome is thought to be a rare ocular manifestation of carotid atherosclerosis that usually occurs in elderly individuals who also have generalized atherosclerosis affecting other major organs. A significant increase in five-year mortality has been demonstrated, with cardiac disease accounting for approximately half the deaths.¹⁹

Although the great majority of cases of OIS occurs in elderly patients with atherosclerosis, cases have rarely been reported in other settings. Duker reported a case of OIS secondary to spontaneous carotid dissection in a 64-year-old male.¹⁵ To our knowledge, ocular ischemia has not been previously reported in a child as young as 19 months or in a patient with moyamoya disease.

Patients with OIS have not only significantly increased mortality, but also a poor visual prognosis. In the series by Sivalingam et al, 43% of patients had 20/50 or better acuity on initial presentation.¹⁸ However, 58% of their patients had count fingers or worse vision one year after presentation, despite maximal treatment that included panretinal photocoagulation with carotid endarterectomy or superficial temporal artery-middle cerebral artery bypass. Visual prognosis was worse for eyes with rubeosis iridis on initial presentation. Eighty-two percent of eyes with rubeosis at or within three months of presentation had no better than count fingers vision at one-year follow up.

Carotid occlusion can be associated with moyamoya disease, a central nervous system vasculopathy that occurs in all ethnic groups, but has been most frequently reported in the Japanese population. Moyamoya disease can occur at any age, but is most common in children.¹ Females may be more susceptible. Either unilateral or bilateral carotid stenosis with development of collateral vessels ("moyamoya vessels") is characteristic. Patients may be asymptomatic, or there may be severe neurological deficits. While adults more commonly have hemorrhagic events, children tend to present with ischemic events resulting in stroke. Moyamoya disease, a frequent cause of stroke in children, may be present for some time before symptoms occur.

In a review of 86 children with onset of acute hemiplegia, Solomon et al described three patients with stenosis of the origin of the internal carotid artery (Group III in their series of patients with occlusive vascular disease) with acute hemiplegia; two also had a history of recurrent generalized seizures.²⁰ A minority of the 122 patients with acute hemiparesis, reported by Aicardi et al did not have seizures at the time of their neurological presentation, and eight of the 24 angiograms showed arterial occlusion, compared to no angiographic abnormalities in the group with associated seizures.¹ Diagnosis is confirmed with angiography or MRI that shows carotid stenosis or occlusion, and the typical abnormal vascular collaterals.³ Histopathologic examination of affected cases has shown thickening of the carotid intima, with a distinct lack of inflammation.¹¹

The nomenclature of moyamoya disease is inconsistent in the literature. It has been reported to occur in association with a variety of diseases,^{6,11} including neurofibromatosis.^{15,23} The term "moyamoya phenomenon" has been suggested for those cases that occur in association with another disease. These cases are frequently unilateral and are sometimes called "atypical moyamoya."

Given the many ocular signs associated with carotid occlusion and the frequent occurrence of carotid occlusion in moyamoya disease, one might expect that patients with moyamoya would be particularly susceptible to the development of ocular ischemia. Surprisingly, there are few reports of ocular abnormalities in moyamoya disease. Noda et al studied four patients with moyamoya disease and reported visual field defects (homonymous hemianopsia).¹⁴ There were few abnormal intraocular findings with only one patient having cortical lens opacities and another showing temporal disk pallor. Visual disturbances resulting from central nervous system pathology are more common. Miyamoto reported visual disturbances in 43 of 178 patients with moyamoya disease.¹² As our case report demonstrates, patients can have carotid occlusion or OIS for several years before neurological signs develop.

Various vascular lesions have been reported in numerous sites (including the central nervous system) in patients with neurofibromatosis. These lesions are thought to result from Schwann cell proliferation within arteries.¹⁷ Retinal astrocytic and combined hamartomas of the retina and retinal pigment epithelium have been reported in association with both type 1 and type 2 neurofibromatosis, but are unusual.⁴ To our knowledge, there are no previous reports of carotid occlusion resulting in both moyamoya disease and ocular isch-

emia in a patient with neurofibromatosis. Moadel et al recently reported a similar case of unilateral retinal ischemia in a child with neurofibromatosis.¹³ However, their case differs from our case report in several important respects. Although cerebral angiography was not performed, there was no evidence of carotid stenosis by Doppler flow studies in their patient. Nonetheless, color Doppler imaging did demonstrate reduced central retinal artery flow. Although not specified in this report, flow away from the probe would indicate retrograde filling from a collateral of the external carotid artery, and flow toward the probe would indicate filling from the internal carotid artery or a collateral in the proximal orbit. In addition, there was no evidence of moyamoya disease in their report. It remains unclear whether a single process leads to the neurofibromatosis associated ocular vasculopathy in the patient reported by Moadel and the patient reported herein. Clearly ocular ischemia in association with neurofibromatosis can occur both with and without moyamoya disease.

Our case is unusual in that ocular ischemia was present in a young child. In addition, this child also had neurofibromatosis that is known to be associated with both vasculopathy in general, and moyamoya disease in particular. Further studies may lead to a better understanding of the vascular changes in neurofibromatosis and moyamoya disease and any shared pathogenesis. Cases of OIS in children may be overlooked, as the index of suspicion for ocular changes is low in children with either neurofibromatosis or moyamoya disease. We suggest that the possibility of ocular ischemia be suspected in patients with neurofibromatosis or moyamoya disease. This is particularly important in children who are unlikely to report visual loss due to their young age. OIS, while best known as a disease of the elderly who have significant vascular disease, can also occur in patients with neurofibromatosis, and intracranial vaso-occlusive disease, regardless of age. Recognition of the vascular abnormalities in children can alert the clinician to the potential for both ocular and life-threatening consequences.

References

1. Aicardi J, Amsili J, Chevrie JJ: Acute hemiplegia in infancy and childhood. *Develop Med Chil Neurol* 11:162-173, 1969
2. Brown, GC, Magargal LE: The ocular ischemic syndrome: clinical, fluorescein angiographic and carotid angiographic features. *Int Ophthalmol* 11:239-251, 1988
3. Bruno A, Yuh WTC, Biller J, et al: Magnetic resonance imaging in young adults with cerebral infarction due to moyamoya. *Arch Neurol* 45:303-306, 1988
4. Destro M, D'Amico DJ, Garoudas ES, et al: Retinal manifestations of neurofibromatosis. *Arch Ophthalmol* 109: 662-666, 1991
5. Duker JS, Belmont JB: Ocular ischemic syndrome secondary

- to carotid artery dissection. *Am J Ophthalmol* 106:750-752, 1988
6. Gordon N, Isler W: Childhood moyamoya disease. *Developmental Med Child Neurol* 31:98-107, 1989
 7. Hedges TR Jr: Ophthalmoscopic findings in internal carotid artery. *Am J Ophthalmol* 55:1007-1012, 1963
 8. Kahn MBS, Green R, Knox DL, Miller NR: Ocular features of carotid occlusive disease. *Retina* 6:239-252, 1986
 9. Kearns TP, Hollenhorst RW: Venous stasis retinopathy of occlusive disease of the carotid artery. *Proc Mayo Clin* 38:304-312, 1963
 10. Knox DL: Ischemic ocular inflammation. *Am J Ophthalmol* 60:995-1002, 1965
 11. Malci Y, Enomoto T: Moyamoya disease. *Child's Nerv Syst* 4:204-212, 1988
 12. Miyamoto S, Kikuchi H, Karasawa J, et al: Study of the posterior circulation in moyamoya disease: visual disturbances and surgical treatments. *J Neurosurg* 65:454-460, 1986
 13. Moadel K, Yanuzzi LA, Ho AC, Ursekar A: Retinal vascular disease in a child with neurofibromatosis. *Arch Ophthalmol* 112:1021-1093, 1994
 14. Noda S, Hayasaka S, Setogawa T, Matsumoto S: Ocular symptoms of moyamoya disease. *Am J Ophthalmol* 103:812-816, 1987
 15. Okuno T, Prensky AL, Gado M: The moyamoya syndrome associated with irradiation of an optic glioma in children: report of two cases and review of the literature. *Ped Neurol* 1:311-316, 1985
 16. Quint DJ, Silbergleit R, Young WC: Absence of the carotid canals at skull base CT. *Radiology* 182:477-481, 1992
 17. Salyer WR, Salyer DC: The vascular lesions of neurofibromatosis. *Angiology* 25:510-519, 1974
 18. Sivalingam A, Brown GC, Magargal LE: The ocular ischemic syndrome III: Visual prognosis and the effect of treatment. *Int Ophthalmol* 15:15-20, 1991
 19. Sivalingam A, Brown GC, Magargal LE, Menduke H: The ocular ischemic syndrome II: mortality and systemic morbidity. *Int Ophthalmol* 13:187-191, 1989
 20. Solomon GE, Hilal SK, Gold AP, Carter S: Natural history of acute hemiplegia of childhood. *Brain* 93:107-120, 1970
 21. Smith JL: Unilateral glaucoma in carotid occlusive disease. *JAMA* 182:683-684, 1962
 22. Sturrock GD, Mueller HR: Chronic ocular ischemia. *Br J Ophthalmol* 68:716-723, 1984
 23. Tomsick BA, Lukin RR, Chambers AA, Benton C: Neurofibromatosis and intracranial arterial occlusive disease. *Neuroradiology* 11:229-234
 24. Young LHY, Appen RE: Ischemic oculopathy: a manifestation of carotid artery disease. *Arch Neurology* 38:358-361, 1981

Supported by an unrestricted grant from Research to Prevent Blindness, Inc., New York, New York, and the Minnesota Lions and Lioness Clubs.

Presented, in part, at the 20th annual meeting of the American Association for Pediatric Ophthalmology and Strabismus, Vancouver, British Columbia, Canada, June 20, 1994.

Dr. Barrall is now in Seattle, Washington.

Reprint Address: C. Gail Summers, MD, University of Minnesota, Department of Ophthalmology, Box 423, 490 Delaware St. SE, Minneapolis, MN 55455-0501