

2. Baram TZ, Butler IJ, Nelson MD Jr, McArdle CB: Transverse sinus thrombosis in newborns: Clinical and magnetic resonance imaging findings. *Ann Neurol* 1988;24:792-794.
3. Grossman R, Novak G, Patel M, et al: MRI in neonatal dural sinus thrombosis. *Pediatr Neurol* 1993;9:235-238.
4. Hanigan WC, Tracy PT, Tadriss WS, Wright RM: Neonatal cerebral venous thrombosis. *Pediatr Neurosci* 1988;14:177-183.
5. Medlock MD, Olivero WC, Hanigan WC, et al: Children with cerebral venous thrombosis diagnosed with magnetic resonance imaging and magnetic resonance angiography. *Neurosurgery* 1992;31:870-876.
6. Rivkin MJ, Anderson ML, Kaye EM: Neonatal idiopathic cerebral venous thrombosis: An unrecognized cause of transient seizures or lethargy. *Ann Neurol* 1992;32:51-56.
7. Shevell MI, Silver K, O'Gorman AM, et al: Neonatal dural sinus thrombosis. *Pediatr Neurol* 1989;5:161-165.
8. Wong VK, LeMesurier J, Franceschini R, et al: Cerebral venous thrombosis as a cause of neonatal seizures. *Pediatr Neurol* 1987;3:325-327.
9. Higashida RT, Helmer E, Van Halbach V, Hieshima GB: Direct thrombolytic therapy for superior sagittal sinus thrombosis. *AJNR Am J Neuroradiol* 1989;10:S4-S6.
10. Volpe JJ: *Neurology of the Newborn*, 3rd ed. Philadelphia, WB Saunders, 1995.
11. Barron TF, Gusnard DA, Zimmerman RA, Clancy RR: Cerebral venous thrombosis in neonates and children. *Pediatr Neurol* 1992;8:112-116.
12. Marciniak E, Wilson D, Mariari RA: Neonatal purpura fulminans: A genetic disorder related to the absence of protein C in blood. *Blood* 1985;65:15-20.
13. Di Rocco C, Ianelli A, Leone G, et al: Heparin-urokinase treatment in aseptic dural sinus thrombosis. *Arch Neurol* 1981;38:431-435.
14. Gettelfinger DM, Kokmen E: Superior sagittal sinus thrombosis. *Arch Neurol* 1977;34:2-6.
15. Boussier M, Chiras J, Bories J, Castaigne P: Cerebral venous thrombosis—A review of 38 cases. *Stroke* 1985;16:199-213.
16. Hanigan WC, Rossi LR, McLean JM, Wright RM: MRI of cerebral vein thrombosis in infancy: A case report. *Neurology* 1986;36:1354-1356.
17. Macchi RJ, Grossman RI, Gomori JM, et al: High field MR imaging of cerebral venous thrombosis. *J Comput Assist Tomogr* 1986;10:10-15.

Neonatal Cerebral Arterial Thrombosis: Protein C Deficiency

Protein C is a plasma protein that is thought to have both anticoagulant and fibrinolytic function when activated. Deficiency of protein C is autosomal dominantly inherited and sometimes coexists with protein S and antithrombin III deficiencies. Separate or combined deficiencies are manifested primarily by venous thrombosis. We report the first perinatal brain infarction due to an arterial thrombus (internal carotid artery) resulting solely from deficiency of protein C.

Case History

This 6-month-old girl was the 3525-g product of a full-term, uncomplicated pregnancy and was born via normal spontaneous vaginal delivery. Apgar scores were 9 at both 1 and 5 minutes.

Within the first 36 hours of life, she had two seizures, which seemed to originate in the right brain before generalization. The seizures were easily controlled with phenobarbital. Her neurologic examination was normal.

Cultures of cerebrospinal fluid, blood, and urine were negative, with her mother's cervical culture positive for group B *Streptococcus*. Pertinent negative laboratory results included urine amino acids, urine organic acids, drug screen, serum ammonia, and serum lactate.

Magnetic resonance imaging (MRI) revealed an infarct of the right caudate and internal capsule. Magnetic resonance angiography at 1 week of age revealed virtually absent flow signal in the right internal carotid artery, extending into the cavernous and supraclinoid portions. Aspirin, 20 mg every day, was started, and a repeat magnetic resonance angiography 4 weeks later demonstrated markedly improved though somewhat diminished flow (Figures 1 through 4).

Protein C levels, both functional and immunologic, were deficient when age corrected at both age 1 week (C functional, 0.18 U/mL; normal, 0.21 to 0.65 U/mL) and 5 months (C functional, 0.33 U/mL; C immunologic, 0.27 U/mL; normal, 0.37 to 0.81 U/mL), with normal protein S (total and free levels) and antithrombin III levels (Table 1). Tests for cardiolipin antibodies (IgG, IgM, IgA) were all negative.

At 5 months of age, she developed infantile spasms and was treated with adrenocorticotropic hormone (ACTH). MRI evaluation showed no change from the previous studies. By that time, a left hemiparesis was apparent.

Her father's protein C concentration was abnormally low, though he does not have a history of thrombotic disease (protein C activity, 0.53; normal, 0.60 to 1.40 U/mL; antigen, 0.56 U/mL; normal, 0.69 to 1.39 U/mL). Her mother's protein C was normal.

Discussion

Mammen et al¹ first described protein C deficiency in 1960. Protein C deficiency in pediatric thrombotic disease primarily involves newborns with disseminated intravascular coagulopathy or purpura fulminans. Children have been described with central nervous system venous thrombosis causing neurologic deficits.² Protein C deficiency in neonatal central nervous system arterial thrombosis has not been previously documented.

There are multiple reports relating deficiencies in protein C with venous thrombosis in children and adults. In adults, venous thrombosis is five to six times more common than arterial thrombosis. In children, stroke associated with protein C deficiency has been reported in the clinical context of a primary antiphospholipid syndrome.³ Israels and Seshia described a 17-month-old child with a transient hemiparesis during a febrile illness, with decreased protein C concentration and normal brain radionuclide scan and computerized tomographic scan. That child did not, as such, have a documented cerebral thrombosis.⁴ Protein C deficiency in adults has been found with central nervous system arterial thrombosis, but in all reports, it has been associated with a confounding medical history, such as prior chemotherapy.⁵

Our patient is the first neonate with an isolated protein C deficiency causing a cerebral arterial thrombosis. The magnetic resonance angiograms demonstrate the thrombosis and subsequent recanalization of the internal carotid artery 1 month later (Figures 1 through 4).

Table 1. Protein C Levels in Our Patient and Her Father

	Functional		Immunologic	
	Measured	Normal	Measured	Normal
Patient				
Age 1 wk	0.18*	0.21-0.65 [†]	—	—
Age 5 mo	0.33	0.37-0.81	0.27	0.37-0.81
Father				
Age 36 yr	0.53	0.60-1.40	0.56	0.69-1.39

*All values expressed as U/mL.

[†]Normal values from pooled serum controls.

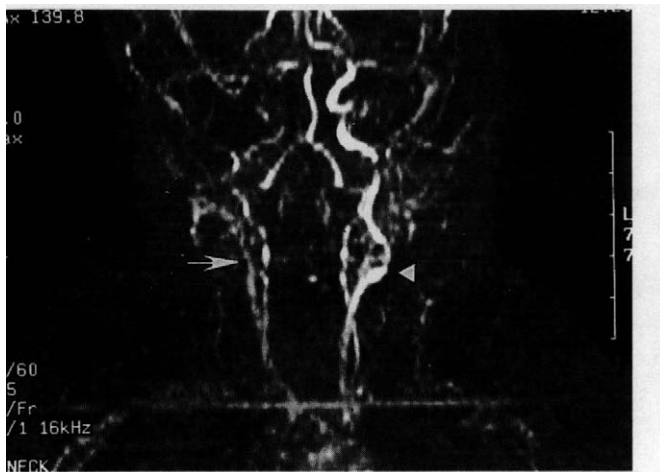


Figure 1. Magnetic resonance angiogram of the carotid and vertebral circulation in the neck at age 1 week shows diminished flow signal in the right common carotid artery compared with the left (arrow). No definite flow signal is seen in the right internal carotid artery or external carotid artery. Normal carotid bifurcation is seen on the left (arrowhead).

Protein C is a vitamin K-dependent protein that is activated by thrombin; it is thought to decrease fibrin production by inactivating factors V-A and VIII-A. In its activated form, in concert with protein S, it proteolyzes these factors. Inactivation of plasminogen factor inhibition accounts for its profibrinolytic activity.^{6,7}

Protein C, when measured by electroimmunoassay, is low in the newborn and increases via increased synthesis in the early years.⁸ Factors V and VIII are present in the newborn at normal adult concentrations. Therefore, an absolute deficiency of protein C tips the balance of an otherwise greater predisposition to neonatal thrombosis, because protein C is relatively deficient in the newborn. As a result, isolated protein C deficiency may be a greater-than-appreciated cause of neonatal stroke.

This patient demonstrates thrombosis of an internal carotid artery in the perinatal period due solely to an isolated protein C

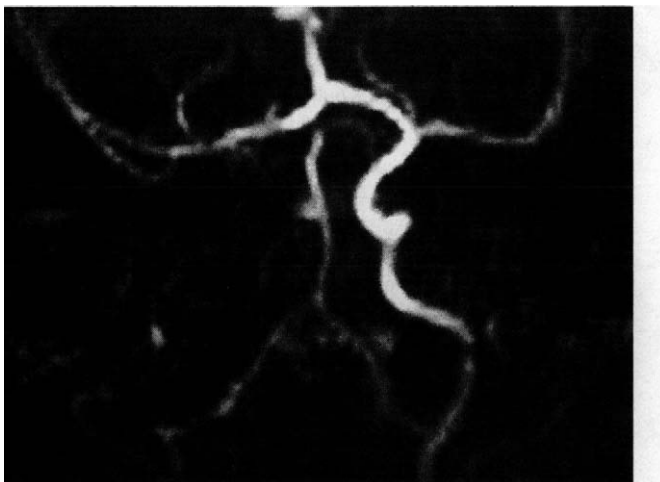


Figure 2. Magnetic resonance angiogram of the intracranial circulation at age 1 week shows no flow signal in the petrous, cavernous, or supraclinoid right internal carotid arteries. There is good flow signal in the right anterior and middle cerebral arteries, from crossover from the left internal carotid artery, through the anterior communicating artery.

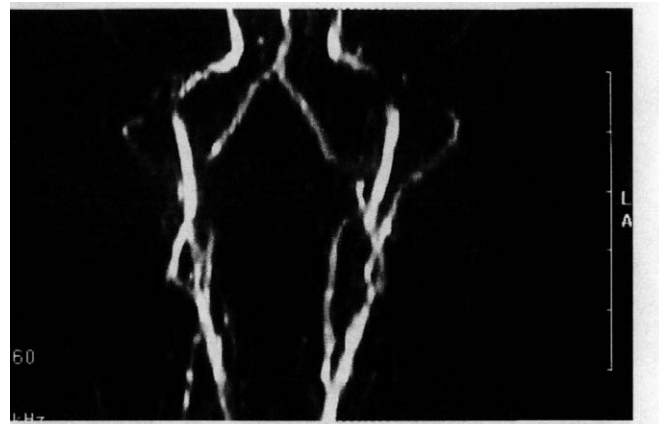


Figure 3. Magnetic resonance angiogram of the carotid and vertebral circulation in the neck at age 5 weeks demonstrates normal flow in the common, internal, and external carotid arteries bilaterally.

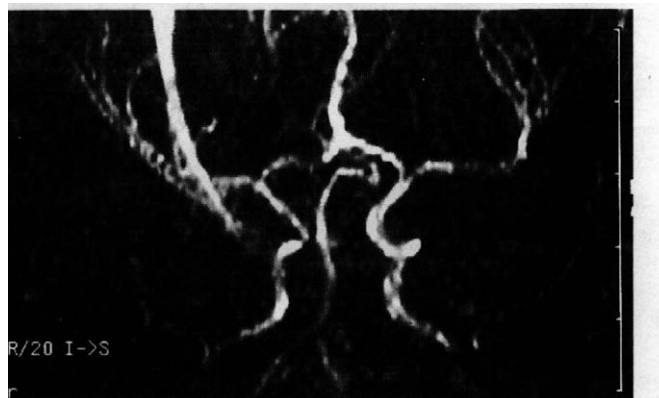


Figure 4. Magnetic resonance angiogram of the intracranial circulation at age 5 weeks demonstrates normal flow in the petrous, cavernous, and supraclinoid internal carotid arteries bilaterally, as well as the anterior and middle cerebral arteries.

deficiency, an autosomal dominant disorder. Whether aspirin contributed to the vascular recanalization is not known. Protein C deficiency is a potentially reversible cause of neonatal cerebral arterial thrombosis. Therefore, we suggest that protein C be assayed in all newborns with stroke and children whose clinical and family histories, examinations, and neuroradiologic testing is consistent with a stroke in the perinatal period.

Robert J. Gould, MD

Karen Black, MD

Steven G. Pavlakis, MD

Departments of Neurology, Pediatrics, and Radiology

North Shore University Hospital

Manhasset, New York

Cornell University Medical College

New York, New York

Received May 3, 1995. Received revised June 28, 1995. Accepted for publication June 29, 1995.

References

1. Mammen EF, Thoma WR, Seegers WH: Activation of purified prothrombin to autoprothrombin I or autoprothrombin II (platelet

- cofactor II or autoprothrombin II-A). *Thromb Diath Haemorrh* 1960;5:218.
- Voutsinas L, Gorey MR, Gould RJ, et al: Venous sinus thrombosis as a cause of parenchymal and intraventricular hemorrhage in the full-term neonate. *Clin Imaging* 1991;15:273-275.
 - Devilat M, Toso M, Morales M: Childhood stroke associated with protein C or S deficiency and primary antiphospholipid syndrome. *Pediatr Neurol* 1993;9:67-70.
 - Israels SJ, Seshia SS: Childhood stroke associated with protein C or S deficiency. *J Pediatr* 1987;562-564.
 - Matsushita K, Kuriyama Y, Sawada T, Uchida K: Cerebral infarction associated with protein C deficiency. *Stroke* 1992;23:108-111.
 - Nathan DG, Oski FA: *Hematology of Infancy and Childhood*. Philadelphia, WB Saunders, 1994, pp 1632-1635.
 - Isselbacher KJ, Braunwald E, Wilson JD, et al: *Harrison's Principles of Internal Medicine*. New York, McGraw-Hill, 1994, pp 1809-1810.
 - Karpatkin M, Mannucci PM, Bhogal M, et al: Low protein C in the neonatal period. *Br J Haematol* 1986;62:137-142.

Congenital Fumarase Deficiency Presenting With Hypotonia and Areflexia

Congenital fumarase deficiency was reported as a "new cause of mitochondrial encephalomyopathy" in 1986. In that first report, Zinn and colleagues¹ described a male infant presenting at a few weeks of age with poor feeding, lethargy, hypotonia, developmental delay, and cerebral atrophy. That infant died at age 9 months. Eight other infants²⁻⁷ have now been reported with this enzyme deficiency, usually presenting as a progressive disorder that is ultimately fatal. Isolated fumaric aciduria has also been reported in two adult siblings,⁸ but fumarase activity was not assayed in those patients. We report here the case of a now 6-year-old child who was initially referred because of hypotonia, delayed development, failure to thrive, and "cerebral palsy."

Case Report

This male infant was born at term to a 27-year-old gravida 1 para 0 mother. The pregnancy was complicated by leakage of amniotic fluid between the 6th and 7th month of gestation. Apgar scores were 9 (1 minute) and 9 (5 minutes). In retrospect, mother thought that the baby was floppy at birth, did not feed well, and breathed rapidly. The infant was discharged at 48 hours of age. He was readmitted to the hospital 2 days later because of poor feeding, poor color, and lethargy. His temperature was 36.5°C, pulse was 154 per minute, respirations were 64 per minute, and his blood pressure was 76/48 mm Hg. He was acidotic (arterial blood pH, 7.0), and he was given 70 mL of 5% albumin and 10 mEq of NaHCO₃ with partial correction of his acidosis. His blood count was unremarkable, but serum sodium was 156 mEq/L, other electrolytes being normal. Cerebrospinal fluid protein was 271 mg/dL and glucose was 101 mg/dL; cell count showed five white blood cells (96% mononuclear) and 571 red blood cells/ μ L. He was treated with ampicillin and gentamicin for presumed sepsis. Cerebrospinal fluid cultures and latex agglutination tests were negative, but blood cultures were positive for *Escherichia coli*. During his 10-day hospitalization, a number of metabolic tests were done, but no specific diagnosis was made.

He was evaluated by a neurologist at age 4 months because of hypotonia and poor weight gain. He was unable to bear weight, had a weak grasp, and had poor muscle tone. Tongue fasciculations were not present, and deep tendon reflexes could not be elicited. The serum creatine kinase level was normal. The conduction velocity in his peroneal nerve was 34 m/s, and a needle electromyogram was normal. By 15 months of age, he had been hospitalized for treatment of pneumonia and had two surgical procedures done (tympanostomy tubes and a feeding gastrostomy had been placed). He continued to make slow developmental progress.

The family moved to Pittsburgh when the child was about age 2.5 years. He was admitted to the Children's Hospital for vomiting and dehydration. The following test results were obtained: Na, 140 mEq/L; K, 5.3 mEq/L; Cl, 108 mEq/L; CO₂, 10 mEq/L; blood urea nitrogen, 10 mg/dL; glucose, 137 mg/dL; and venous pH, 7.16. The urine was positive for ketones. Blood lactate level was 2.0 mEq/L (normal, 0.7 to 1.8 mEq/L), pyruvate level was 0.12 mEq/L (normal, 0.03 to 0.08 mEq/L), and ammonia level and liver function tests were normal. Blood amino acids were normal; urine amino acids showed a slight increase in amino acid excretion; urine organic acids showed an elevation of 3-hydroxybutyrate and acetoacetate, consistent with physiologic ketosis.

He was first evaluated in our neurology department at age 3 years. His weight was below the 5th percentile, whereas height and head circumference were both at the 25th percentile. He appeared bright, alert, and interactive, but had almost continuous choreoathetoid movements of the upper extremities. He had difficulty extending his fingers. There was diffuse hypotonia and muscle wasting, especially in the legs. Deep tendon reflexes were absent, and Babinski reflex was present bilaterally. Blood lactate level was 1.4 mEq/L, and pyruvate concentration was 0.08 mEq/L. Serum creatine kinase level and plasma very long chain fatty acid levels were normal. Urine organic acids analysis detected an unusual MU 21.6 compound (possibly drug related); glutaric acid was not elevated. Aryl sulfatase A activity in blood lymphocytes was normal, as was biotinidase activity. A magnetic resonance imaging scan of the brain (Figure 1) was notable for enlarged ventricles and a thin corpus callosum. These findings suggested that this disorder resulted in diffuse central hypomyelination and cerebral atrophy. There were no areas of abnormal signal in the cortex, basal ganglia, or the brain stem. Nerve conduction tests and an electromyogram were done. Conduction velocity in the peroneal nerve was 37 m/s (normal > 42 m/s), in the ulnar nerve was 40 m/s (normal > 45 m/s), in the median (motor) nerve was 39 m/s (normal > 38 m/s), and in the median (sensory) nerve was 38 m/s (normal > 48 m/s). Stimulation of the posterior tibial nerve (conduction velocity 33 m/s; normal > 44 m/s) was associated with prolongation of distal latency (5.6 ms; normal < 3.5 ms). Needle electromyographic study was normal. This was felt to be consistent with a motor and sensory neuropathy, suggesting that the primary pathologic process involved segmental demyelination.

Muscle and sural nerve biopsies were done. On histologic examination of the muscle, there was atrophy of type II fibers on adenosine triphosphatase stains, although a few type I fibers were atrophic as well. There was no fibrosis, inflammation, lipid storage, or fiber type grouping, nor were there ragged red fibers. These findings suggested a neurogenic process. Examination of the peripheral nerve showed an increase in endoneurial connective tissue, without storage of abnormal material. Analysis of the distribution of myelinated fibers according to size showed no deviation from normal. The most dramatic finding was that most fibers were thinly myelinated (Figure 2). Myelin thickness ranged from one ninth to one fifth of the axon diameter (mean thickness was one seventh of axon diameter), rather than the normal ratio of one to four or one to three between myelin thickness and axon diameter. Onion bulb formation was not observed, nor was there evidence of axonal degeneration. The changes seen in the sural nerve suggested an impairment of myelination, rather than demyelination followed by remyelination. The patient's follow-up was in the neurology, gastroenterology, and cerebral palsy clinics, where he was enrolled in a program of physical and occupational therapy. He continued to make slow developmental progress, without any signs of regression.

At age 5 years, he remained interactive, attentive, and cooing. He still had severe hypotonia and wasting of the proximal muscles of his legs. Distal tone was slightly increased, and choreoathetoid movements were present. Tendon reflexes were depressed but present at his knees. Examination of his urine for organic acids revealed an elevation of lactate, fumarate, and 4-hydroxyphenylacetic acid. This was confirmed on a second urine specimen. At that time, blood lactate level was 5.4 mEq/L and pyruvate level was 0.26 mEq/L with a lactate-to-pyruvate ratio of greater than 20:1. Cerebrospinal fluid lactate level was 2.6 mEq/L, pyruvate concentration was 0.15 mEq/L, and cerebrospinal fluid glucose and protein levels were normal. Arterial blood gases were normal. A third urine sample was tested for organic acids and showed elevated fumarate, citrate, succinate, and 4-hydroxyphenylacetate.