

7. Klieser E, Lehmann E, Tegeler J. Double-blind comparison of 3 × 75 mg zotepine and 3 × 4 mg haloperidol in acute schizophrenics. *Fortschr Neurol Psychiatr* 1991;59:14-17.
8. Barnas C, Stuppäck CH, Miller C, Haring C, Sperner-Unterweger B, Fleischhacker WW. Zotepine: Treatment of chronic schizophrenic patients presenting with predominantly negative symptoms—a double-blind study versus haloperidol. *Fortschr Neurol Psychiatry* 1991;59:36-40.
9. Altar CA, Boyar WC, Wasley A, Liebman JM, Wood PL, Gerhardt SG. Dopamine neurochemical profile of atypical antipsychotics resembles that of D₁-antagonists. *Naunyn-Schmiedeberg's Arch Pharmacol* 1988;338:162-168.
10. Bolden C, Cusack B, Richelson E. Antagonism by antimuscarinic and neuroleptic compounds at the five cloned human muscarinic cholinergic receptors expressed in Chinese hamster ovary cells. *J Pharmacol Exp Ther* 1992;260:576-580.
11. Van Tol HHM, Bunzow JR, Guan H-C, et al. Cloning of the gene for a human dopamine D₄ receptor with high affinity for the antipsychotic clozapine. *Nature* 1991;350:610-614.
12. Uchida S, Honda F, Otsuka M, et al. Pharmacological study of [2-chloro-11-(2-dimethyl-aminomethoxy) dibenzo[b,f]thi-epine] (zotepine), a new neuroleptic drug. *Drug Res* 1979; 29:1588-1594.

Cervical Dystonia as a Probable Consequence of Focal Cerebral Lesion

To the Editor:

Cervical dystonia is a focal dystonia characterized clinically by painful spasmodic contractions of the neck muscles that result in an abnormal posture of the head. Usually the origin of the disorder is unknown; however, secondary forms of cervical dystonia have been described, mainly after trauma of the neck or induced by dopamine antagonists (1,2). Torticollis (rotation of the head) in combination with latero-, retro-, or anterocollis is the most common feature. Often these patients also have an associated tremor of the neck, head, or other body parts (3). The blood and radiological tests are normal in most patients. Secondary cervical dystonia due to intracranial lesions is very rare. We report a case of cervical dystonia probably caused by a lesion in the basal ganglia.

A 63-year-old man was referred to our center in November 1992 with torticollis to the right side. The symptoms started gradually a few weeks earlier, without fever, nausea, vomiting, or any antecedents of head or neck trauma. Initially, the patient complained of pain in the neck area that subsided in the course of the following weeks. There were no changes in the clinical picture during walking or standing, and the rotation of the neck did not disappear during sleep. He had to lie down on the left lateral side to accommodate the rotation of the head. More or less simultaneously with the onset of the torticollis, his family observed the appearance of mild masticatory movements of the mouth. The patient had no antecedents of systemic disease and no other neurological symptoms before the onset of the torticollis. He had never taken neuroleptics or any other medication previously, and there was no family history of movement disorders. On neurological examination, the patient presented with a rotation of the neck to the right side with a tilt of the head to the left and spasmodic contracture of

the left sternocleidomastoid muscle and of the right trapezius. His right shoulder was elevated. The active and passive rotation of the neck to the left side was limited to 45°. During examination, there were sporadic involuntary movements of the mouth, tongue, and chin muscles bilaterally. Moreover, sporadic movements of the head with increased rotation to the right side and jerky hyperextension of the neck were observed. The tendon reflexes were increased bilaterally, more pronounced on the left side with ankle clonus. The plantar reflex was in flexion bilaterally. The palmomental reflex was positive bilaterally. The remainder of the neurological examination showed no abnormalities. There was no neuropsychological deficit demonstrated by formal testing. Serum ceruloplasmin and copper levels were normal. Radiographs of the cervical spine showed diffuse degenerative changes from C3 to C7. Magnetic resonance imaging (MRI) of the cervical region was normal. Electromyography confirmed the spastic contracture of the left sternocleidomastoid muscle. Computed tomography (CT) scan of the brain revealed calcifications in the intracranial portion of the carotid arteries and a major low-density lesion in the right caudate and putamen nucleus involving the anterior part of the internal capsule with slight retraction of the right lateral ventricle compatible with brain infarction. An additional lacunar infarction was seen in the white matter in the left parietal region (Fig. 1).

Focal lesions in the CNS are known to cause dystonia. In the majority of the cases reported in the literature, the lesions are localized in the basal ganglia, mostly in the putamen and globus pallidus (4,5). In these cases, patients usually suffered from dystonia involving the limbs of one side of the body (hemidystonia). In some patients, dysarthria and dysphagia have been described as well. The time interval between the insult of the CNS and the onset of dystonia varies from a few days to 36 months, but cases of delayed onset of dystonia years after the cerebral infarction have also been reported (6). Usually the dystonia is asymmetric at onset, with slow progression to generalization over a period of months. The dystonia progressively deteriorates and remissions are exceptional (4). In most cases of secondary dystonia, lesions of the lenticular body or caudate have been found, but any basal ganglia structure or thalamus may be involved. The disruption of the striatopallidothalamic projection to the premotor cortex and the brainstem has been suggested to underlie symptomatic dystonia. An increase of the brainstem interneuron excitability has been suggested, due to an abnormal input from the basal ganglia (7-9).

Usually, the cause of cervical dystonia (torticollis) is unknown, with a greater prevalence in women, occurring mainly between the fourth and fifth decade of life. In most idiopathic cases, the symptoms have an insidious progression and diminish when the patient is in supine position (10,11). Usually, imaging of the brain (CT scan and MRI) is normal. Isolated cervical dystonia due to a focal lesion in the CNS is very rare and has been described only in a few patients. In these reported cases, the lesions were localized in the caudate, putamen, and in one case in the left centrum semiovale (12-16). One case with bilateral putaminal lesions presented with retrocollis (hyper-

A,B

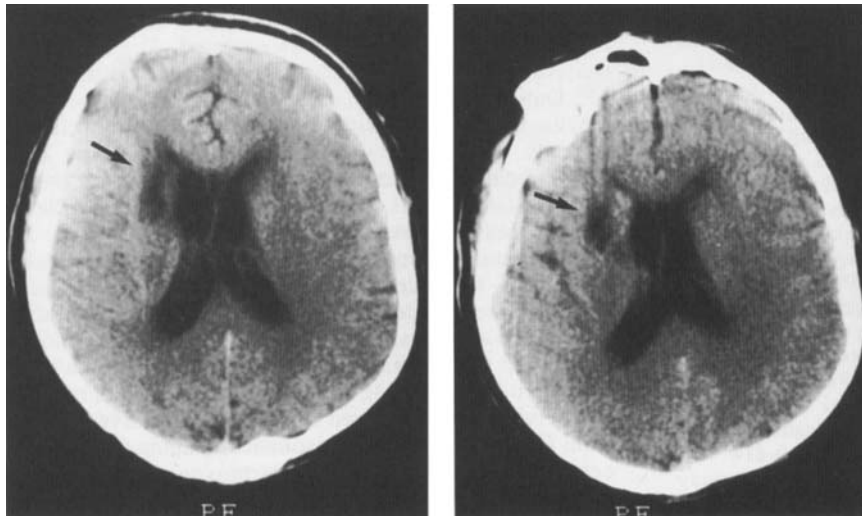


FIG. 1. A: Low-density lesion involving the right putamen nucleus and anterior part of the internal capsule (arrow). B: The same lesion involving also the right caudate nucleus (arrow).

extension of the neck) (17). In our case, the onset of the dystonia was gradual, did not disappear during sleep, and was associated with involuntary movements in the faciooral region. Oromandibular muscles tend to function in a synchronous manner, due to the left–right proximity. Furthermore, the patient had corticospinal tract signs at the left, most probably related to the internal capsule involvement. The CT scan revealed atheromatotic calcifications in the carotid arteries, a lacunar infarct in the white matter of the left parietal area, and a lesion in the right caudate and putamen nucleus compatible with infarction. However, the temporal relationship between onset of brain damage and onset of symptomatology remains unknown. The patient had a rotation of the head ipsilateral to the central lesion, as a consequence of a marked contracture of the left sternocleidomastoid muscle. It is interesting that the hitherto described cases in the literature have the direction of turn to the side opposite to the lesion. It is probable that the cervical dystonia in our patient is a consequence of the cerebral vascular incident, i.e., in the basal ganglia. This is an additional case of symptomatic focal dystonia and confirms the importance of carrying out brain imaging studies in the presence of atypical torticollis.

M. Schwartz

*P. P. De Deyn

*M. Van den kerchove

*B. A. Pickut

Department of Neurology
Bnai Zion Hospital, Haifa; and
Faculty of Medicine, Technion, Israel;

*Department of Neurology
General Hospital Middelheim
Departments of Neurochemistry and Behaviour and
Neurology
University of Antwerp
Antwerp, Belgium

References

1. Dystonic syndromes. In: Jankovic J, Tolosa E, eds. *Parkinson's disease and movement disorders*. Munich: Urban and Schwarzenberg, 1988:283–314.
2. Sheehy MP, Marsden CD. Trauma and pain in spasmodic torticollis. *Lancet* 1980;1:777–778.
3. Jankovic J, Leder S, Warner D, Schwartz K. Cervical dystonia: clinical findings and associated movement disorders. *Neurology* 1991;41:1088–1091.
4. Bhatt MH, Obeso JA, Marsden CD. Time course of postanoxic akinetic-rigid and dystonic syndromes. *Neurology* 1993;43:314–317.
5. Hawker K, Lang AE. Hypoxic-ischemic damage of the basal ganglia: case reports and a review of the literature. *Mov Disord* 1990;5:219–224.
6. Factor SA, Sanchez-Ramos J, Weiner WJ. Delayed onset dystonia associated with corticospinal tract dysfunction. *Mov Disord* 1988;3:201–210.
7. Tolosa E, Montserrat L, Bayes A. Blink reflex studies in focal dystonias: enhanced excitability of brainstem interneurons in cranial dystonia and spasmodic torticollis. *Mov Disord* 1988;3:61–69.
8. Huygen PLM, Verhagen WIM, Van Hoof JJM, Horstink NWIM. Vestibular hyperactivity in patients with idiopathic spasmodic torticollis. *J Neurol Neurosurg Psychiatry* 1989;52:782–785.
9. Lew H, Jordan C, Jerger J, Jankovic J. Acoustic reflex abnormalities in cranial-cervical dystonia. *Neurology* 1992;42:594–597.
10. Loewenstein D, Aminoff MJ. The clinical course of spasmodic torticollis. *Neurology* 1988;38:530–532.
11. Jahanshahi M, Marion M, Marsden CD. Natural history of adult-onset idiopathic torticollis. *Arch Neurol* 1990;47:548–552.
12. Maki Y, Akimoto H, Enomoto T. Injuries in the basal ganglia following head trauma in children. *Childs Brain* 1980;7:113–123.
13. Marsden CD, Obeso JA, Zarranz JJ, Lang AE. The anatomical basis of symptomatic hemidystonia. *Brain* 1985;108:463–483.
14. Isaac K, Cohen JA. Post-traumatic torticollis. *Neurology* 1989;39:1642–1643.
15. Biary N, Al Deeb SM, Aabed M. Post-traumatic dystonia. *Ann Neurol* 1991;30:297.
16. Molho ES, Factor SA. Basal ganglia infarction as a possible cause of cervical dystonia. *Mov Disord* 1993;8:213–216.
17. Shimpo T, Fuse S, Yoshizawa A. Retrocollis and oculogyric crisis in association with bilateral putaminal hemorrhages. *Rinsho Shinkeigaku* 1993;33:40–44.