

William C. Hanigan
Frank C. Powell
Tim C. Miller
Robert M. Wright

Symptomatic intracranial hemorrhage in full-term infants

Received: 31 October 1994

W. C. Hanigan (✉)
Department of Neurosurgery,
University of Illinois College of Medicine
at Peoria, P.O. Box 1649,
Peoria, IL 61656, USA
Tel.: (309) 655-2700
Fax: (309) 655-7138

F. C. Powell
Department of Radiology,
University of Texas Medical School
at Houston, 6431 Fannin,
Houston, TX 77225, USA

T. C. Miller
Department of Pediatrics,
University of Illinois College of Medicine
at Peoria, P.O. Box 1649,
Peoria, IL 61656, USA

R. M. Wright
Department of Radiology,
University of Illinois College of Medicine
at Peoria, P.O. Box 1649,
Peoria, IL 61656, USA

Abstract A retrospective analysis was undertaken in a consecutive series of 33 full-term infants (birth weight >2500 g and a minimum of 37 weeks gestational age) with symptomatic intracranial hemorrhage (ICH) admitted to a regional neonatal intensive care unit from January 1986 to December 1992. Eleven infants were born in our institution; 17 were male. The estimated local incidence of symptomatic ICH for the inborn population was 4.9/10 000 live births, with a regional incidence of 2.7/10 000 live births. Twenty-four (72.3%) infants presented with seizures, apnea, or respiratory distress. Five (15.1%) children developed ICH associated with extracorporeal membrane oxygenation, ventriculoperitoneal shunting, and cardiac surgery. There were two deaths (6.1%) associated with a grade IV periventricular hemorrhage (PVH) and cardiac surgery. Nine infants (27.3%) showed PVH, while an additional nine children developed

multifocal cortical hemorrhages. Eight infants (24.2%) showed extra-axial ICH, four children (12.1%) sustained lobar hemorrhages, and three children (9.1%) showed ICH associated with prenatal CNS abnormalities. Excluding five children with iatrogenic ICH, coagulopathies occurred in 9 of 28 infants (32.1%) and constituted a major determinant of the development of ICH. Neurosurgical intervention was limited to one infant with massive ICH and one child with hydrocephalus as a late sequela of ICH. Developmental follow-up was complete in 32 children with a mean and median duration of 3.4 years. Full-term infants with ICH associated with risk factors for hypoxic-ischemic injury showed a significantly greater risk of developmental delay compared to infants with uncomplicated ICH.

Key words Intracranial hemorrhage · Full-term infants

Introduction

The clinical characteristics of intracranial hemorrhage (ICH) in full-term infants have been described in several series or case reports [3, 8, 10, 11, 14, 22, 27, 28, 33, 34, 39, 45, 52, 53]. For the most part, these investigations emphasized the uncommon occurrence of periventricular hemorrhage (PVH) or the association of extra-axial hematomas with assisted delivery, although sporadic reports in-

cluded primary cortical or striatal hemorrhages [5, 9, 32, 38, 42, 49, 51]. With gradual regionalization of newborn care, increased use of noninvasive radiographic examinations suitable for neonates, and changes in obstetrical and neonatal therapy, clinical patterns of ICH may change over time and affect neurosurgical treatment [3, 18, 26, 28, 34, 44, 46]. This report will outline the incidence, clinical characteristics, treatment and long-term outcome in a consecutive series of 33 full-term infants with symptomatic ICH.

Materials and methods

A retrospective chart analysis was undertaken on infants of above 2500 g weight and 37 weeks gestational age admitted to a regional neonatal intensive care unit from January 1986 to December 1992. Children with radiographic evidence of ICH were identified and data on prenatal and obstetrical histories, age, sex, birth date, clinical presentation, and hospital course were recorded. Developmental follow-up was obtained through outpatient examinations, written reports, and a regional developmental follow-up program [18, 19].

For descriptive purposes, the children were grouped according to the location of ICH as determined by radiographic examinations. Risk factors for hypoxic-ischemic injury were identified and included toxemia, maternal hemorrhage, fetal distress, meconium passage, Apgar score of less than 7 at 5 min, congenital cardiac anomalies, hypoxic-ischemic encephalopathy, and respiratory distress with ventilatory assistance [18, 23, 40, 54]. The odds ratio for developmental delay was calculated for children with both ICH and these risk factors compared to children with ICH alone.

Results

General characteristics

Thirty-three full-term infants (17 male) with symptomatic ICH were included in the analysis. Eleven infants were born in our center. During the period of review, there were a total of 14 400 inborn full-term births, giving an incidence of ICH of 7.6/10 000 live births. However, in 4 of the 11 inborn infants the ICH was associated with therapeutic procedures; consequently, the corrected incidence of spontaneous symptomatic ICH in this center was 4.9/10 000 live births.

The Illinois North Central Perinatal Region, the referral base for this center, documented 81 000 live full-term births during the period under review [18]. Excluding one outborn infant with iatrogenic ICH, 21 infants were admitted for treatment, giving a corrected regional incidence of ICH of 2.7/10 000 live births.

Of the 22 outborn infants, one developed an iatrogenic hemorrhage associated with extracorporeal membrane oxygenation (ECMO) therapy. Four of 11 inborn infants sustained iatrogenic hemorrhages. Two of these hemorrhages were associated with ECMO therapy, one followed ventriculoperitoneal shunting for hydrocephalus, and one occurred during cardiac surgery.

During the period under review, there were 39 full-term infants in this regional center who underwent ECMO therapy; ICH occurred in three (7.7%) children. Two showed a grade I PVH; both children (cases 5 and 8) were developing normally at 2 and 3 years, respectively. One child (case 13) developed multiple cortical hemorrhages and showed severe developmental delay at 3 years' follow-up. One infant (case 18) undergoing surgery for correction of congenital cardiac anomalies developed an extensive cortical hemorrhage and died 1 day after neurosurgical intervention. The remaining child (case 15) developed multi-

ple small cortical hemorrhages following ventriculoperitoneal shunting for hydrocephalus associated with the Chiari II malformation. This patient showed mild developmental delay at 1-year follow-up.

Two children (6.1%) died during the period under analysis. One child (case 2) sustained a grade IV PVH, and one child died soon after surgical intervention.

Neurosurgical procedures were associated with ICH in three (9.1%) children. One child (case 32) required shunting following the development of hydrocephalus associated with prenatal CNS abnormalities. This child showed severe developmental delay at 3 years' follow-up. One child died soon after neurosurgical intervention following cardiac surgery, while one child with a Chiari II malformation developed multiple cortical hemorrhages following ventriculoperitoneal shunting and showed mild developmental delay at 1-year follow-up.

Nineteen children (57.6%) presented with seizures; three of these children developed seizures at 4 or more days following birth. Four children (12.1%) presented with apnea or irritability, while 7 (21.2%) showed hypotonia. One child presented with respiratory distress and the remaining two children with excessive cutaneous bruising.

Periventricular hemorrhage

Nine (27.3%) full-term infants developed PVH (Table 1). Six children were outborn; four had PVH diagnosed at 6 or more days after birth. Two underwent ECMO therapy, while an additional three children developed respiratory distress. Four infants required ventilatory assistance. Two children were diagnosed with hypoxic-ischemic encephalopathy (HIE), while one child showed multiple cardiac anomalies. Developmental outcome was related to grade of PVH; five children with low-grade PVH showed normal development, while four children with high-grade PVH showed severe developmental delay or died.

Intracerebral hemorrhage

Nine (27.3%) children showed multifocal intracerebral hemorrhages (Table 2). Five children were outborn. Four children showed disseminated intravascular coagulation (DIC), while two children developed ICH associated with ECMO therapy or cardiac surgery. The prognosis in this group was grim; only one child showed normal development (Fig. 1A), while a second child showed mild developmental delay. The remaining children demonstrated severe developmental delays.

Extra-axial hemorrhage

Eight (24.2%) infants showed extra-axial hemorrhages (Table 3). Seven underwent assisted deliveries, while three

Table 1 Clinical characteristics and developmental outcome in symptomatic full-term hypoxic-ischemic encephalopathy, *MRI* magnetic resonance imaging, *PDA* patent ductus arteriosus, *SVD* spontaneous vaginal delivery, *US* ultrasound
 infants with periventricular hemorrhage (*ASD* atrial septal defects, *C-section* cesarian section, *CT* computerized tomography, *ECMO* extracorporeal membrane oxygenation, *HIE*

Case no.	Sex	Birth weight (g)	Gestational age (weeks)	Apgar scores (1 min, 5 min)	Inborn/outborn	Prenatal history	Labor and delivery	Clinical presentation days	Ventilatory assistance	Hospital course	Radiological evaluation	Outcome
1	M	2840	40	8, 9	Inborn	–	SVD	Seizures, 18 h	–	–	US, CT: grade IV	Severe developmental delay, 6.5 years
2	F	4167	40	3, 3	Outborn	–	Fetal distress vacuum	Hypotonia at birth	–	HIE, pneumothorax, respiratory distress	CT: grade IV	Died, day 2
3	F	2650	38	3, 5	Outborn	–	SVD	Seizures, 12 h	2	HIE, respiratory distress	US, MRI: grade III	Severe developmental delay, 3 years
4	M	3660	38	3, 4	Outborn	–	Uterine rupture, C-section	Seizures, 9 days	–	–	US: grade I	Normal, 3 years
5	M	2835	38	9, 9	Inborn	–	SVD	Apnea, 30 min	5	ECMO, pulmonary hypertension	US: grade I	Normal, 3 years
6	M	4961	38	5, 6	Inborn	Maternal diabetes, well controlled	C-section (repeat)	Apnea at birth	5	–	US: grade I	Normal, 2 years
7	M	2625	37	7, 7	Outborn	Maternal diabetes well controlled	C-section (repeat)	Apnea, 5 days	–	Respiratory distress	US: grade I	Normal, 2 years
8	F	3317	40	5, 8	Outborn	–	SVD, meconium aspiration	Apnea, 6 days	7	ECMO, pulmonary hypertension	US: grade I	Normal, 2 years
9	F	3579	38	4, 6	Outborn	–	C-section, meconium stain	Apnea, 9 days	–	ASD, PDA, multiple organ failure	CT: grade IV	Severe developmental delay, 1 year

Table 2 Clinical characteristics and developmental outcome in symptomatic full-term infants with intracerebral hemorrhage (DIC disseminated intravascular coagulation, VSD ventricular septal defect)

Case no.	Sex	Birth weight (g)	Gestational age (weeks)	Apgar scores (1 min, 5 min)	Inborn/outborn	Prenatal history	Labor and delivery	Clinical presentation days	Hospital course	Radiological evaluation	Outcome
10	F	3147	38	2, 7	Outborn	Pre-eclampsia	Placental abruption C-section	Seizures at birth	HIE, PDA, DIC	US, MRI: sinus thrombosis, cortical hemorrhages,	Severe developmental delay, 3 years
11	F	3274	38	1, 2	Inborn	-	Maternal hemorrhage, fetal distress, C-section	Respiratory distress at birth	HIE, PDA, DIC, thrombocytopenia	MRI: multiple cortical hemorrhages	Severe developmental delay, 4 years
12	M	3260	41	1, 5	Outborn	-	Fetal distress, C-section	Seizures, 1 h	Group B streptococcal sepsis	MRI: multiple cortical hemorrhages	Severe developmental delay, 4 years
13	F	2920	38	7, 7	Inborn	Pre-eclampsia	Fetal distress, SVD	Respiratory distress at birth	Diaphragmatic hernia, ECMO	US, MRI: left parietal hemorrhages	Severe developmental delay, 3 years
14	M	2990	41	1, 2	Outborn	-	Fetal distress, SVD	Seizures, 1 day	-	MRI: multiple cortical hemorrhages	Severe developmental delay, 2.5 years
15	M	2771	37	6, 8	Inborn	Previous meningomyelocele	C-section	Irritability	Chiari II malformation, hydrocephalus	CT: multiple cortical hemorrhages	Mild developmental delay, 1 year
16	M	2765	40	8, 9	Outborn	-	SVD	Seizures, day 3	DIC	MRI: multiple cortical hemorrhages	Normal, 3.5 years
17	F	3430	41	1, 4	Outborn	Pre-eclampsia	Fetal distress, meconium aspiration, C-section	Seizures, 1 day	HIE, DIC	MRI: multiple hemorrhages, left parietal lobe	Severe developmental delay 1.5 years
18	M	2840	40	8, 9	Inborn	-	SVD	Hemorrhage during cardiac surgery	Truncus arteriosus, ASD, VSD, neurosurgical decompression	US: massive left cortical hemorrhage	Died, day 29

Table 3 Clinical characteristics and developmental outcome in symptomatic full-term infants with extra-axial hemorrhages (SAH subarachnoid hemorrhage)

Case no.	Sex	Birth weight (g)	Gestational age (weeks)	Apgar scores (1 min, 5 min)	Inborn/outborn	Prenatal history	Labor and delivery	Clinical presentation days	Hospital course	Radiological evaluation	Outcome
19	M	4298	43	6, 6	Outborn	-	Fetal distress, mid-forceps	Seizures at birth	HIE, pneumothorax	CT: SAH	Severe developmental delay, 6 years
20	M	3850	40	5, 5	Outborn	-	Failed forceps, vacuum extraction	Hypotonia, day 1	Hemophilia	MRI: bilateral subdural hemorrhage	Normal, 6 years
21	F	3230	40	9, 9	Outborn	Twin B	Fetal distress, meconium stain, vacuum extraction	Seizures, day 3	HIE, DIC	CT, MRI: intratentorial hemorrhage	Severe developmental delay, 5 years
22	M	3750	40	9, 9	Outborn	-	Vacuum extraction	Seizures, 8 h	Cephalhematoma, lipomeningomyelocele	MRI: quadrigeminal cistern hemorrhage	Normal, 5 years
23	M	2849	38	7, 7	Outborn	-	Fetal distress, failed forceps, vacuum extraction, C-section	Bruising, day 1	Isoimmune thrombocytopenia	CT: right frontal epidural hemorrhage	Normal, 4 years
24	F	2850	41	6, 8	Outborn	Maternal diabetes, well controlled	Mid-forceps	Seizures, 1 h	Pyloric stenosis	MRI: posterior fossa hemorrhage	Normal, 3,5 years
25	M	3402	40	1, 5	Inborn	-	Fetal distress, failed forceps, C-section	Hypotonia at birth	-	CT: subdural hemorrhages	Severe developmental delay, 4 years
26	F	4139	38	1, 6	Outborn	Pre-eclampsia	Fetal distress, SVD	Seizures, day 2	Left clavicular fracture	CT, MRI: subdural and intratentorial hemorrhages	Erb's palsy, normal, 3 years

Table 4 Clinical characteristics and developmental outcome in symptomatic full-term infants with lobar hemorrhages

Case no.	Sex	Birth weight (g)	Gestational age (weeks)	Apgar scores (1 min, 5 min)	Inborn/outborn	Prenatal history	Labor and delivery	Clinical presentation days	Hospital course	Radiological evaluation	Outcome
27	F	3660	40	7, 9	Outborn	Sepsis (?)	Low forceps	Seizures, 2 days	-	MRI: right frontal lobe	Normal, 6 years
28	F	3420	37	8, 9	Inborn	2 Spontaneous abortions	C-section (repeat)	Seizures, 1 day	-	MRI: left occipital lobe	Normal, 1 year
29	F	3600	41	7, 9	Inborn	-	SVD	Seizures, 1 day	Isoimmune thrombocytopenia	MRI: right temporal lobe hemorrhage	Normal, 3,5 years
30	M	2934	41	3, 5	Outborn	-	SVD	Seizures at birth	HIE, respiratory distress	MRI: left occipital lobe	Severe developmental delay, 3 years

Table 5 Clinical characteristics and developmental outcome in symptomatic full-term infants with prenatal CNS abnormalities (US ultrasound)

Case no.	Sex	Birth weight (g)	Gestational age (weeks)	Apgar scores (1 min, 5 min)	Inborn/outborn	Prenatal history	Labor and delivery	Clinical presentation days	Hospital course	Radiological evaluation	Outcome
31	F	2552	38	2, 3	Outborn	Fetal ventriculo-megaly	SVD	Seizures, 1 day	-	US, MRI: right cerebellar hemorrhage	Severe developmental delay, 4 years
32	M	2510	38	8, 9	Inborn	Fetal ventriculo-megaly	C-section	Hypotonia, 1 day	Ventriculo-peritoneal shunt	US, MRI: infratentorial and cerebellar hemorrhages	Severe developmental delay, 3 years
33	F	2820	39	9, 9	Outborn	-	C-section (repeat)	Bruising, 2 days	Isoimmune thrombocytopenia	MRI: bilateral hemorrhages in temporal lobe cysts	Lost to follow-up

showed coagulopathies. Five children showed normal development, although one of these children demonstrated a persistent Erb's palsy. Three children showed severe developmental delay.

Lobar hemorrhage

Four children (12.1%) developed lobar hemorrhages (Table 4). One child underwent an uneventful assisted delivery (Fig. 1B) and another showed DIC. There was no location bias and surgery was not required for any child. Follow-up angiography or magnetic resonance angiography in three children (not listed) failed to reveal vascular abnormalities. No child sustained a second hemorrhage and three of four children were developing normally.

Hemorrhage associated with prenatal CNS abnormalities

Three children (9.1%) showed ICH associated with prenatal CNS abnormalities (Table 5). Two children developed fetal ventriculomegaly diagnosed by ultrasound examination; both demonstrated posterior fossa hemorrhages at birth (Fig. 1C). One child with thrombocytopenia developed hemorrhages into cystic lesions of both temporal lobes. This latter child was lost to follow-up, while the former two children showed severe developmental delay.

Coagulopathies

Excluding five children with ICH associated with therapeutic anticoagulation or surgical intervention, coagulopathies were present in 9 of 28 (32.1%) full-term infants. DIC was prevalent in children with multifocal intracerebral hemorrhages, while hemophilia, DIC, or isoimmune thrombocytopenia were seen in children with extra-axial or lobar ICH or hemorrhages associated with prenatal CNS abnormalities.

Developmental outcome

Follow-up with a range of 1–6.5 years and a mean and median duration of 3.4 years was complete in 32 (96.9%) children. All children identified as having risk factors for hypoxic-ischemic injury showed two or more factors. Excluding five children with ICH associated with medical or surgical therapy, one child who died soon after a grade IV PVH (case 2), and three children with ICH associated with prenatal CNS abnormalities, 24 children were evaluable for outcome analysis. Eleven children with risk factors showed developmental delay, while two children with risk factors showed normal development; the latter group included one child with Erb's palsy (case 26). Ten children without risk factors showed normal development, while

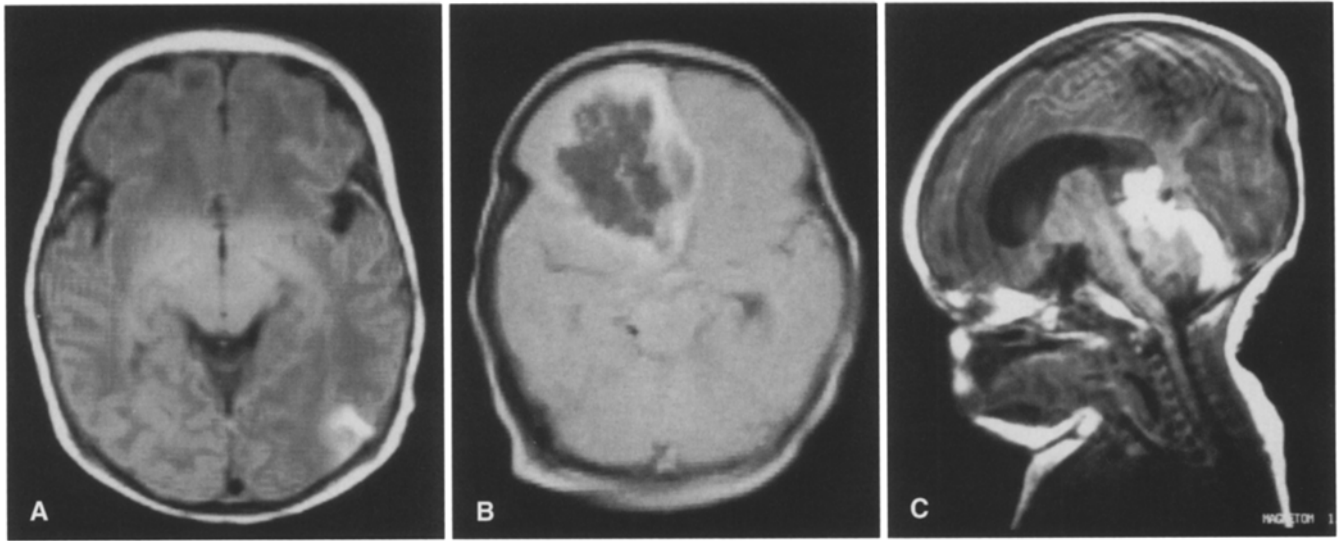


Fig. 1A–C Representative MR scans of several patterns of intracranial (ICH) in full-term infants. **A** Spin-echo axial MR image (TR 680 ms; TE 15 ms) of infant (case 16) taken 4 days after birth. Cortical hemorrhagic lesion was visualized in the left parietal region. **B** Spin-echo axial MR image (TR 1100 ms; TE 35 ms) of infant (case 27) taken 2 days after birth, showing a large right frontal lobar hemorrhage. **C** Spin-echo sagittal MR image (TR 600 ms; TE 15 ms) of infant (case 32) taken within 36 h after birth, demonstrating subtentorial and cerebellar hemorrhage

one child without risk factors demonstrated severe developmental delay (estimated risk=55; 95% CI=3.3–604.2).

Discussion

Epidemiology

One report estimated the incidence of symptomatic ICH in full-term infants in a regional center at 5.9/10 000 live births [44]; the present confirmed this calculation with an incidence of 4.9/10 000 live inborn births. Although regionalization for preterm infants was successful, the lower regional incidence for full-term infants of 2.9/10 000 live births may indicate changes in referral patterns or a lack of regional surveillance for outside treatment of infants with symptomatic ICH [18]. The lower estimate may also reflect the effect of maternal transport to this center. Two studies estimated the incidence of asymptomatic ICH in full-term infants [22, 29]. In a group of 506 healthy inborn infants, 19 (3.8%) showed sonographic evidence of PVH, while in a second group of 150 children (45 inborn) 2 of 33 (6.7%) asymptomatic infants showed ICH following computerized tomography. Extrapolation of these data to our local population of 14 400 live births suggested that 547–965 infants sustained an asymptomatic ICH during the study period. These numbers seem unreasonably elevated and additional studies must be undertaken to clarify the incidence of asymptomatic ICH in full-term infants.

Clinical presentation and neuroradiographic evaluation

The usual clinical presentations associated with ICH in these newborns were seizures, apnea, or respiratory distress; these signs occurred in 24 (72.3%) children. Focal

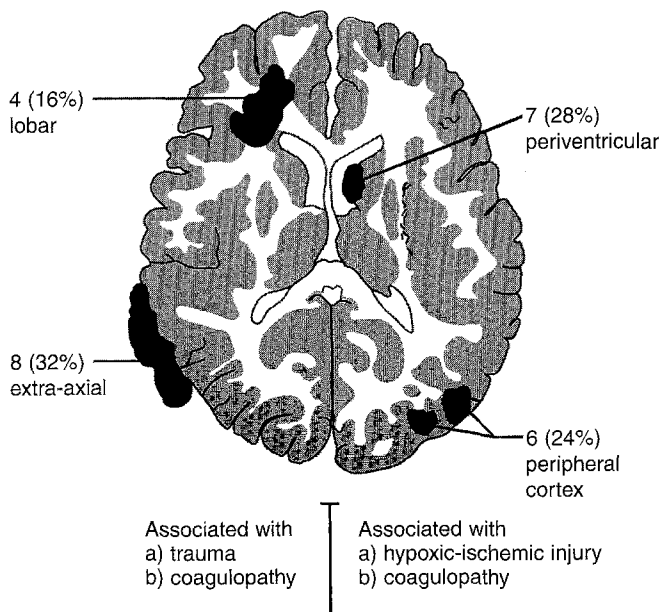


Fig. 2 Locations and clinical factors associated with ICH in 25 full-term infants. Data for five children with ICH associated with therapy and three children with ICH associated with prenatal CNS abnormalities were omitted from this figure

neurological deficits, pupillary asymmetry, ocular nerve palsies, or stuttering deterioration either due to initial injury or elevations in intracranial pressure were not seen in this series [52]. Seven (21.2%) children showed hypotonia consistent with hypoxic-ischemic injury, while coagulopathies resulted in excessive bruising in two infants.

This study was limited to an analysis of ICH and did not compare the sensitivity or specificity of various examinations for early radiographic abnormalities associated with perinatal asphyxia [1, 2, 4, 31, 48]. The value of cranial ultrasound for the diagnosis of PVH in either preterm or full-term infants justified its initial use in children with clinical signs [18, 22]. If PVH was demonstrated, additional radiographic studies were performed at the discretion of the attending neonatologist. If PVH was not found, MRI was usually performed due to its anatomical specificity as well as ability to allow estimation of the age of the hemorrhage [2]. The frequency of subsequent examinations varied and was not always under the control of the investigators. Routine MRI as a predictor for neurodevelopmental outcome was not proven [50], but occasionally demonstrated lesions not visualized in the early newborn period, which clarified the pathogenesis of the initial injury (case 3 in [17]).

Iatrogenic ICH and coagulopathies

Five (15.1%) of infants sustained ICH associated with medical or surgical therapy, particularly when anticoagulants were administered. While the incidence of ICH associated with ECMO was consistent with that in previous reports [7, 30], there was one death and one child with severe developmental disability as a result of all therapeutic interventions. The incidence of iatrogenic hemorrhages emphasized the risk of ICH associated with therapy as well as the potential alterations in clinical patterns of ICH specific for each regional center. The data also demonstrated that almost one-third of the remaining children showed coagulopathies. These disorders may be more frequent than previously recognized and were significant determinants of the development of ICH in our population [42, 52].

ICH by location

Periventricular hemorrhage

Although previous investigators indicated that PVH in full-term infants may originate from regions other than the germinal matrix, our radiographic data did not support their findings [10, 14, 38]. Four hemorrhages, however, occurred at 5 or more days following birth, which confirmed previous reports that these hemorrhages occurred at a later age than usually seen in preterm infants [5, 34]. The remainder of the clinical data in our series indicated that fac-

tors associated with the occurrence of PVH and outcome were similar to those in the preterm population [18].

Intracerebral hemorrhage

The high incidence of hypoxic-ischemic injury and the radiographic characteristics of ICH in this group of children suggested that these hemorrhages shared a common pathophysiology with the development of cortical laminar necrosis [4, 48]. Consistent with the newborn's extensive leptomeningeal vasculature, these multiple hemorrhages were usually subpial in location, not always confined to watershed zones, with variable intracerebral or subarachnoid spread [43]. The MR sequence characteristics, the age of the lesions, and the variable presence of mass effect or coagulopathy indicated that these hemorrhages may have represented hemorrhagic transformations of necrotic lesions in the cortical periphery [1, 5, 38, 48]. The poor outcome in most of these children reinforced this possibility.

Extra-axial hemorrhage

Two children in this group have been described in a previous report [17]. The occurrence of these hemorrhages associated with assisted delivery is well known, while the presence of coagulopathies in three children demonstrated an additional risk for development of ICH [11, 52].

Lobar hemorrhage

Although lobar hemorrhage as a separate clinical entity has not been described, tabular or radiographic evidence has been shown in 22 children. A review of the clinical and radiographic data of these children has been reported separately [21]. In the present series, no source of emboli was seen and sepsis in case 27 was not proven. One child underwent an uncomplicated assisted delivery without clinical evidence of external injury, while one child showed isoimmune thrombocytopenia. No evidence of a vascular abnormality was found and no child sustained a second hemorrhage. As in adults with lobar hemorrhages or children with multifocal cerebral hemorrhages, the radiographic distinction between primary hemorrhage and hemorrhagic transformation and an ischemic infarct was difficult [36, 37]. Surgical decompression was not required and outcome was related to the presence of associated risk factors for hypoxic-ischemic injury.

Prenatal CNS abnormalities

Two of the children with prenatal CNS abnormalities presented with sonographic evidence of fetal ventriculomegaly. MR scans taken within 36 h after birth showed ten-

torial or cerebellar hemorrhages which accounted for the ventriculomegaly. Although these hemorrhages may have been associated with labor, no clinical evidence suggested this possibility; neither child underwent assisted delivery or showed external signs of trauma or laboratory evidence of a coagulopathy. Documented cases of fetal ICH are rare, but several reports have described cerebellar hemorrhages with fetal ventriculomegaly in near-term pregnancies [15, 25]. In the third child, the presence of bilateral temporal lobe cysts indicated an in utero abnormality; hemorrhage into cysts of the subarachnoid space has been described, while the occurrence of isoimmune thrombocytopenia provided an additional etiology [24].

Other patterns of ICH

The development of ICH due to vascular abnormalities identified by radiography did not occur in our series. "Angiographically cryptic" arteriovenous malformations have been described following surgery in infants, but without identifiable diagnostic patterns, suggesting that the advisability of surgical treatment should be evaluated on an individual basis [16, 35]. Several reports have outlined the occurrence of thalamic or striatal hemorrhages in the newborn period which have been attributed to primary venous infarctions associated with coagulopathies or hypoxic-ischemic injury [42, 49]. This entity was not seen in our study.

Outcome and neurosurgical intervention

The criteria for outcome measures have been outlined in previous reports [18, 19]. Fifteen children with severe developmental delays showed abnormal findings on motor and cognitive scales, while one child with mild developmental delay gave an abnormal examination on the motor scale and a suspect examination on the cognitive scale. Major motor or cognitive deficiencies were not seen in children with normal development, but subtle impairments in information processing or attention were not evaluated in this study. Several investigations have shown diminished cognitive function following minor head injuries, and while this disability may develop in these children,

longer follow-up will be needed for complete analysis [6, 41].

The risk factors for hypoxic-ischemic injury have been defined in several reviews [23, 40, 54]. Not surprisingly, all affected children in our series showed two or more factors, which emphasized the severity of their illnesses. Despite reports suggesting that the presence of ICH may adversely affect development, and the implication that accessible hemorrhagic lesions should be removed, our analysis indicated that the risk of developmental delay was significantly higher in infants with ICH and these factors than in infants with isolated ICH [13, 41, 47]. In this series, no child with an accessible, uncomplicated ICH demonstrated developmental delay. Surgical decompression was required in only one child with a life-threatening elevation of intracranial pressure and one child with hydrocephalus as a sequela of ICH [17, 37].

Conclusions

This analysis of 33 full-term infants admitted to a neonatal intensive care unit over a 6-year period demonstrated a varied spectrum of ICH. Twenty-two children were out-born and five children sustained ICH associated with medical or surgery therapy. These data demonstrated the effects of regionalization on clinical patterns of ICH which were specific to this regional center as well as risks associated with advanced newborn care. Excluding ICH of iatrogenic origin, the occurrence of ICH was determined by developmental, vascular, traumatic, or pathophysiologic factors unique to the neonatal period (Fig. 2). Neurosurgical intervention, however, was required in two children for indications similar to those for adult patients. In full-term infants with symptomatic ICH, the occurrence of risk factors for hypoxic-ischemic injury resulted in significantly greater risk of developmental delay. The study underscored the need for accurate documentation of these factors in any evaluation of long-term developmental changes associated with ICH [12, 17, 20].

Acknowledgement The authors wish to thank Dr. Jean Aldag for statistical analyses and Mrs. JoAnna Gass for secretarial assistance.

References

1. Baenziger O, Martin E, Steinlin M, et al (1993) Early pattern recognition in severe perinatal asphyxia: a prospective MRI study. *Neuroradiology* 35:437-442
2. Bailey WG Jr (1993) MR appearance of hemorrhage in the brain. *Radiology* 189:15-26
3. Balériaux D, Ticket L, Dony D, et al (1980) The contribution of CT to perinatal intracranial hemorrhage including that accompanying apparently uncomplicated delivery at full term. *Neuroradiology* 19:273-277
4. Barkovich J (1993) MR and CT evaluation of profound neonatal and infantile asphyxia. *AJNR* 13:959-972
5. Bergman I, Bauer RE, Barmada MA, et al (1985) Intracerebral hemorrhage in the full-term neonatal infant. *Pediatrics* 75:488-496
6. Bohnen N, Jolles J, Twijnstra A (1992) Neuropsychological deficits in patients with persistent symptoms six months after mild head injury. *Neurosurgery* 30:692-696

7. Bui KC, LaClair P, Vanderkerhove J, et al (1991) ECMO in premature infants. Review of factors associated with mortality. *ASAIO Trans* 37:54-59
8. Cartwright GW, Culbertson K, Schreiner RL, et al (1979) Changes in clinical presentation of term infants with intracranial hemorrhage. *Dev Med Child Neurol* 21:730-737
9. Chaplin ER Jr, Goldstein GW, Norman D (1979) Neonatal seizures, intracerebral hematoma, and subarachnoid hemorrhage in full-term infants. *Pediatrics* 63:812-815
10. Donat JF, Okazaki H, Kleinberg F, et al (1978) Intraventricular hemorrhages in full-term and premature infants. *Mayo Clin Proc* 53:437-441
11. Fenichel GM, Webster DL, Wong WKT (1984) Intracranial hemorrhage in the term newborn. *Arch Neurol* 41:30-34
12. First LR, Palfrey JS (1994) The infant or young child with developmental delay. *N Engl J Med* 330:478-483
13. Govaert P, Vanhaesebrouck P, Praeter C de (1992) Traumatic neonatal bleeding and stroke. *Arch Dis Child* 67:840-845
14. Guekos-Thoeni U, Boltshauser E, Willi UV (1982) Intraventricular haemorrhage in full-term neonates. *Dev Med Child Neurol* 24:704
15. Hadi HA, Finley J, Mallette JQ, et al (1994) Prenatal diagnosis of cerebellar hemorrhage: medicolegal implications. *Am J Obstet Gynecol* 170:1392-1395
16. Hanigan WC, Brady T, Medlock M, et al (1990) Spontaneous regression of giant arteriovenous fistulae during the perinatal period. Case report. *J Neurosurg* 73:954-957
17. Hanigan WC, Morgan AM, Stahlberg LK, et al (1990) Tentorial hemorrhage associated with vacuum extraction. *Pediatrics* 85:534-539
18. Hanigan WC, Morgan AM, Anderson RJ, et al (1991) Incidence and neurodevelopmental outcome of periventricular hemorrhage and hydrocephalus in a regional population of very low birth weight infants. *Neurosurgery* 29:701-706
19. Hanigan WC, Morgan A, Shaaban A, et al (1991) Surgical treatment and long-term neurodevelopmental outcome for infants with idiopathic aqueductal stenosis. *Child's Nerv Syst* 7:386-390
20. Hanigan WC, Olivero WC, Miller TC (1993) Traumatic neonatal intracranial bleeding and stroke. *Arch Dis Child* 68:339
21. Hanigan WC, Powell FC, Palagallo G, Miller TC (1995) Lobar hemorrhages in full-term neonates. *Child's Nerv Syst* 11:276-280
22. Hayden CK, Shattuck KE, Richardson CJ, et al (1985) Subependymal germinal matrix hemorrhage in full-term neonates. *Pediatrics* 75:714-718
23. Hill A (1993) The predictive significance of clinical measures of brain injury in the newborn. *Clin Invest Med* 16:141-148
24. James HE (1989) Encephalocele, dermoid sinus, and arachnoid cyst. Encephaloceles and related malformations. In: McLaurin RL, Schut L, Venes JL, Epstein F (eds) *Pediatric neurosurgery*. Saunders, Philadelphia, pp 97-105
25. Jennett RJ, Daily WJR, Tarby TJ, et al (1990) Prenatal diagnosis of intracerebellar hemorrhage: case report. *Am J Obstet Gynecol* 162:1472-1475
26. Jocelyn LJ, Casiro OG (1992) Neurodevelopmental outcome of term infants with intraventricular hemorrhage. *Am J Dis Child* 146:194-197
27. Lacey DJ, Terplan K (1982) Intraventricular hemorrhage in full-term neonates. *Dev Med Child Neurol* 24:332-337
28. Leblanc R, O'Gorman AM (1980) Neonatal intracranial hemorrhage. A clinical and serial computerized tomographic study. *J Neurosurg* 53:642-651
29. Ludwig B, Brand M, Brockerhoff P (1980) Postpartum CT examination of the heads of full term infants. *Neuroradiology* 20:145-154
30. Matamoros A, Anderson JC, McConnell J, et al (1989) Neurosonographic findings in infants treated by extracorporeal membrane oxygenation (ECMO). *J Child Neurol* 4:S52-S61
31. McArdle CB, Richardson CJ, Hayden CK, et al (1987) Abnormalities of the neonatal brain: MR imaging. Part II. Hypoxic-ischemic brain injury. *Radiology* 163:395-403
32. Meidell R, Marinelli PV, Randall V, et al (1983) Intracranial parenchymal hemorrhage in a full-term infant. An unusual clinical presentation and ultrasonographic diagnosis. *Clin Pediatr* 22:780-783
33. Miller GM, Black VD, Lubchenco LO (1981) Intracerebral hemorrhage in a term newborn with hyperviscosity. *Am J Dis Child* 135:377-378
34. Mitchell W, O'Tuama L (1980) Cerebral intraventricular hemorrhages in infants: a widening age spectrum. *Pediatrics* 65:35-39
35. Mitnick JS, Pinto RS, Lin JP, et al (1984) CT of thrombosed arteriovenous malformations in children. *Radiology* 150:385-389
36. Molinari GF (1993) Lobar hemorrhages. Where do they come from? How do they get there? *Stroke* 24:523-526
37. Moulin T, Crépin-Leblond T, Chopard J-L, et al (1994) Hemorrhagic infarcts. *Eur Neurol* 34:64-77
38. Nanba E, Eda I, Takashima S, et al (1984) Intracranial hemorrhage in the full-term neonate and young infant: correlation of the location and outcome. *Brain Dev* 6:435-443
39. Palma PA, Miner ME, Morriss FH Jr, et al (1979) Intraventricular hemorrhage in the neonate at term. *Am J Dis Child* 133:941-944
40. Paneth N (1993) The causes of cerebral palsy. Recent evidence. *Clin Invest Med* 16:95-102
41. Rimel RW, Giordani B, Barth JT, et al (1981) Disability caused by minor head injury. *Neurosurgery* 9:221-228
42. Roland EH, Flodmark O, Hill A (1990) Thalamic hemorrhage with intraventricular hemorrhage in the full-term newborn. *Pediatrics* 85:737-742
43. Rorke LB (1992) Anatomical features of the developing brain implicated in pathogenesis of hypoxic-ischemic injury. *Brain Pathol* 2:211-221
44. Sachs BP, Acker D, Tuomala R, et al (1987) The incidence of symptomatic intracranial hemorrhage in term appropriate-for-gestation-age infants. *Clin Pediatr* 26:355-358
45. Scher MS, Wright FS, Lockman LA, et al (1982) Intraventricular hemorrhage in the full-term neonate. *Arch Neurol* 39:769-772
46. Schwartz RM, Luby AM, Scanlon JW, et al (1994) Effect of surfactant on morbidity, mortality, and resource use in newborn infants weighing 500 to 1500 g. *N Engl J Med* 330:1476-1480
47. Serfontein GL, Rom S, Stein S (1980) Posterior fossa subdural hemorrhage in the newborn. *Pediatrics* 65:40-43
48. Takahashi S, Higano S, Ishii K, et al (1993) Hypoxic brain damage: cortical laminar necrosis and delayed changes in white matter at sequential MR imaging. *Radiology* 189:449-456
49. Trounce JQ, Fawer C-L, Punt J, et al (1985) Primary thalamic haemorrhage in the newborn: a new clinical entity. *Lancet* 1:190-192
50. Van de Bor M, Ouden L den, Guit GL (1992) Value of cranial ultrasound and magnetic resonance imaging in predicting neurodevelopmental outcome in preterm infants. *Pediatrics* 90:196-199
51. Voit T, Lemburg P, Neuen E, et al (1987) Damage of thalamus and basal ganglia in asphyxiated full-term neonates. *Neuropediatrics* 18:176-181
52. Volpe JJ (1987) *Neurology of the newborn*. Saunders, Philadelphia, pp 282-310
53. Wehbreg K, Vincent M, Garrison B, et al (1992) Intraventricular hemorrhage in the full-term neonate associated with abdominal compression. *Pediatrics* 89:327-328
54. Yager JY (1992) Postnatal hypoxic-ischemic encephalopathy. In: Miller G, Ramer JC (eds) *Static encephalopathies of infancy and childhood*. Raven Press, New York, pp 265-282